

Honey-based therapy for paediatric burns and dermal trauma compared to standard hospital protocol

Eleftherios Smaropoulos, Spyridon Romeos, Chrissavgi Dimitriadou

Abstract

Aims: To compare honey-based ointments and dressings for the treatment of paediatric partial-thickness burns and skin lesions with results from cases treated with conventional methods. **Methods:** Eight children (eight months–13 years) were included in the study when admitted to the emergency room (ER). Five had partial-thickness burns (2–35% total body surface area [TBSA]). The three others had necrotic ulcers, circular skin lesions and deep cervical trauma. After stabilising the patients in the ER, honey-based products were applied. Parents were given instructions on how to apply the honey ointment and dressings at home. Patients were followed up weekly on an out-patient basis. Similar cases treated with povidone iodine were collated from hospital archives for comparison. **Results:** All honey cases had complete epithelialisation by the end of the second week, without any adverse effects. The povidone iodine group needed on average three weeks for epithelialisation and had prolonged hospitalisation. The home care by the parents provided stress-free healing for both children and parents. **Conclusions:** The honey-based therapy indicates a fast (19 days vs 25–31 days), cost-effective and patient-friendlier treatment method compared to povidone iodine. **Conflict of interest:** None.

KEY WORDS

Paediatrics
Burns
Antibacterial
Honey-based products

From September 2007 to September 2008, 168 children with burns or scalds were admitted to the emergency room (ER) in the Hippokration General Hospital, Thessaloniki, Greece.

As well as general hospitalisation, burns and scalds are a common reason for paediatric patients attending the ER. Extensive burns and scald lesions,

in particular, require lengthy hospital treatment which can cause distress to children and their families (Pardo, 2010). Their quality of life is effected not only while in hospital, but also afterwards due to poor cosmetic post-traumatic results.

To examine an alternative method of treatment compared to standard hospital protocol for partial-thickness burns and various types of skin damage, ointments and hydrogel net dressings using honey were used.

Throughout history, honey has been used in various cultures:

- ▶▶ Hippocrates (460–375 BC) used honey for cicatrisation of lesions
- ▶▶ The ancient Greeks and Romans used it as a local antiseptic in inflammations, skin lesions and dermal ulcers
- ▶▶ The Chinese used it for preventing the formation of cicatrix in buccal cavity and pharynx diseases
- ▶▶ Celsius and Aristotle used it to ease coughs and sore throats
- ▶▶ In 1759 Sir John Hill reported the value of honey in dealing with skin lesion complications and in the treatment of other kinds of lesions.

The use of honey in ancient wound management is also highlighted in translations of the *Edwin Smith Surgical Papyrus* (1700 BC): 'afterward stitching the lesion of scalp the head is covered with grease, and honey daily until the cicatrisation of lesion' (Feldman and Goodrich, 1999; van Middendorp et al, 2010).

To evaluate the wound healing progress of those patients treated with honey products, patients were followed up at weekly-intervals, where progress was documented and photographs taken to show the degree of epithelialisation and the absence of complications (such as wound infection, cicatrix).

Materials and methods

Burns were assessed following the rule of nines to classify their severity (Wilson et al, 1996). Eight children between the age of eight months and 13 years who were admitted to the ER without any underlying pathologies that might have influenced wound healing were included in the evaluation (Table 1).

For 2–3 days (cases 2, 3), or for a 2.5-month period (cases 5, 6, 7,

Eleftherios Smaropoulos is a Paediatric Surgeon; Spyridon Romeos and Chrissavgi Dimitriadou are Residents in paediatric surgery. All work at the paediatric surgery department, Hippokration General Hospital of Thessaloniki, Greece

Table 1

Details of the patients featured in this study

Patient	Age	Injury and wound localisation	TBSA (%)	Number of days taken for epithelialisation
1. Male	13 months	Scald caused by boiling water, affecting the left forearm with a circular extension	8	14
2. Male	22 months	Scald caused by boiling water on the left upper thorax extending from left shoulder to the base of the neck reaching the left nipple (Figure 1)	10	14
3. Female	2.5 years	Extensive scald of the neck and thorax, caused by boiling water (Figure 2)	18	21
4. Male	2 years	Burn from an iron, located to the upper surface of the arm	2	14
5. Female	18 months	Major partial-thickness scald from boiling water. Dermal damage implicated hands, limbs, neck, back and front thoracic area. The infant was in a critical condition due to metabolic and electrolyte disorders combined with pyrexia	35	21
6. Male	8 months	Haemangiomas lesions of the arm and thigh, presented with a necrotic ulcer of the right forearm lesion following systematic intradermal administration of interferon- α , which was administered with intention to evoke micro-embolisms into the haemangioma		10
7. Female	13 years	Surgical excision of a large abscess (4x4cm) in the right axillary region had resulted in a large skin deficit (Figures 3, 4)		30
8. Male	13 years	Multiple skin trauma and rupture of the spleen. After splenectomy, the patient was admitted to the children's intensive care unit where most of the skin deficits were handled, except a 10x10cm trauma of the left cervical area (Figures 5, 6), which was treated with the honey-based products		30

8), every hospitalised patient was treated according to local protocol. This protocol prescribes treatment with povidone iodine 10% solution (Betadine[®], Purdue), fusidic acid (Fucidin[®], Leo Pharma) and systemic antibiotics. Then the honey-based ointment and dressings were applied (L-Mesitran[®] Ointment and L-Mesitran Net dressings, Triticum). Three cases (6, 7, and 8) were initially hospitalised for surgical reasons and received the honey therapy as in-patients.

Case 5, who suffered from an extensive burn total body surface area (TBSA) of 35%, had a lengthy stay in hospital. Her parents consented that only the wound on her right leg (10x8cm, depth 0.5cm) should be treated with L-Mesitran Ointment in combination with L-Mesitran Hydro, while the rest of her body should be treated following standard protocol, i.e. povidone iodine 10%, paraffin gauzes and skin grafting.

The other patients were discharged from hospital after having received

clear instructions for the application of the honey-based products at home.

They were examined periodically as outpatients. Cases 1 and 4 started

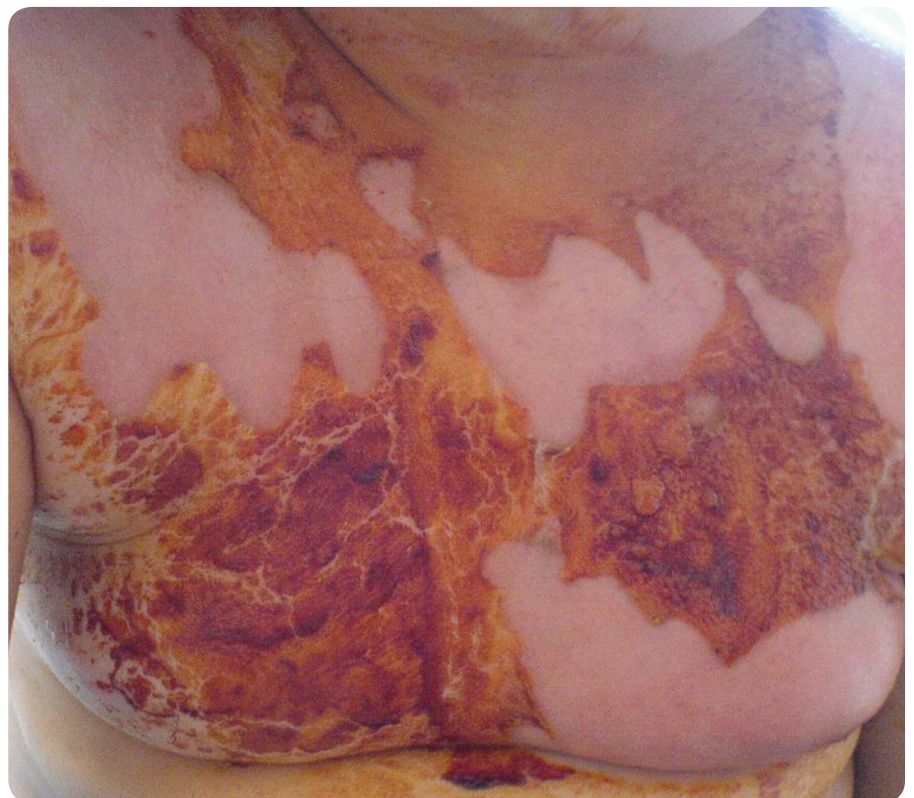


Figure 1. Case 3: extensive scald covering 18% TBSA due to boiling water.

with the honey-based products from the outset.

After cleaning the Wounds with normal saline (0.9%), a thin layer of the ointment was applied with a sterile spatula, with the hydrogel net dressing being applied directly onto the wound. Sterile gauzes were used to stabilise the dressings. The same method of application of ointment and dressings was performed daily by the parents at home.

The ointment and the reticular hydrogel dressings contain medical grade honey. This medical grade honey is sterilised by gamma-irradiation to eliminate *Clostridium* endospores that can be present in honey and cause wound botulism (Postmes, 1993).

The ointment contains 48% medical grade honey (water 17.1%, fructose 38.5%, glucose 31.8%, maltose 7.2%, sucrose 1.5%, hydro carbonates 4.0%, proteins, vitamins and minerals), Aloe vera, Calendula, cod liver oil, sunflower oil, vitamin E, and C, and Lanolin. The L-Mesitran Net dressing is a polyester weave impregnated with a polymer containing 20% medical grade honey. All the honey products are CE, TGA and FDA approved medical devices.

Results

The first case showed significant improvement after seven days and the wound was progressing to epithelialisation. There were no signs of infection in the scald and the infant appeared to tolerate the dressing changes without problems or pain. At follow-up one week later, there was 100% epithelial tissue, without scar formation.

The lesion of case 2 reduced in size after seven days. Only a tiny central region above the left nipple remained. The damage on the shoulder and at the base of the neck had healed, but was further treated with an ointment (Mederma®, Merz) for a better cosmetic result. At follow-up one week later, the central lesion had achieved complete epithelialisation. No signs of infection were observed and the cosmetic result was good.

The third patient had similar results. No infection was observed, and epithelialisation of the lesion was smooth with considerable improvement after seven days. In this case, due to the severity of the wound, honey treatment was continued for a third week resulting in complete healing and 100% epithelial tissue.

Granulation tissue was present in case 4's wound after seven days and by the second week there were explicit signs of epithelialisation without infection.

Case 5 had the honey-based therapy applied to her right leg only. The rest of her body (35% in total) was mainly treated with skin grafts and other traditional methods (povidone iodine 10% and paraffin gauzes). The right leg recovered swiftly, with the wound (measuring approximately 10x8cm with a depth of 0.5cm) healing completely. However, her back underwent two skin transplants with poor results. Tissue from the already healed leg was eventually used to harvest skin grafts for application on the child's back.

Case 6, the haemangioma ulcer, showed improvement with gradual epithelialisation at the focal necrotic area of the thrombosed venous complex, due to the interferon- α intradermal administration. This therapy is used traditionally in the hospital in cases of large haemangiomatic lesions, especially where gentle organs or tissues are involved, or surgical intervention is difficult. The outcome of the focal necrotic area was as expected, but cosmetic surgical intervention is still intended.

The wounds in case 7 had halved in size by the second week, and full healing was achieved after one month of continuous application of the honey-based products. Two months later only a small scar remained.

Ten days after starting treatment, case 8 experienced progressive granulation in the traumatic area, making it possible to suture the inner layers of the deep traumatic cavity, while continuing the medication. One

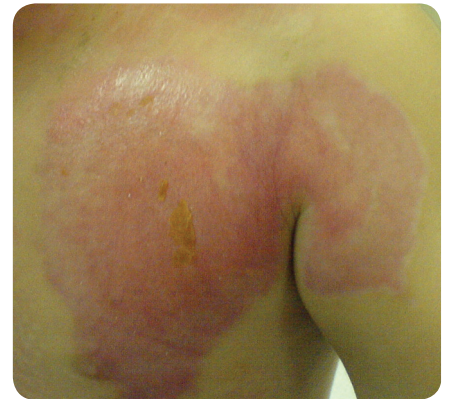

Figure 2. Case 3: the scald was fully healed after 14 days of honey treatment.

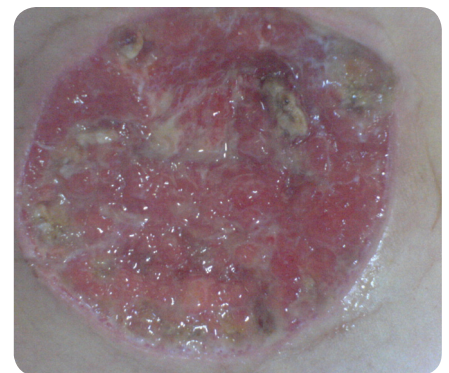

Figure 3. Case 7: lesion on the patient's right armpit at the start of honey treatment.

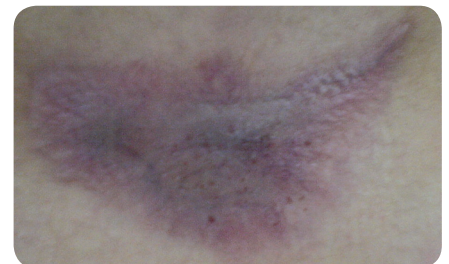

Figure 4. Case 7: the lesion healed after 30 days.

week later the wound edges were re-approximated. The final result after one month's treatment was excellent, with scar formation which was treated by conservative methods.

In each of the eight cases examined, there was no malodour and exudate was managed well. No adverse effects or allergies were observed. Furthermore, in all the cases the hospital's instructions were thoroughly followed by the parents. Their feedback was that dressing application and removal was a simple process with minimal discomfort for their children.

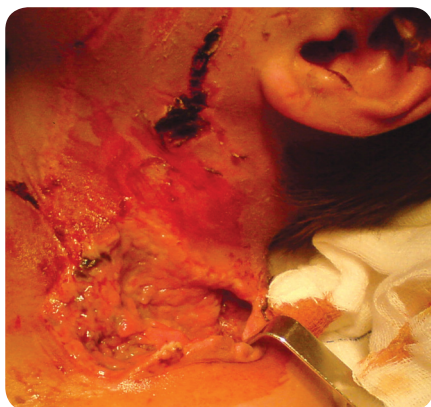

Figure 5. Case 8: 13-year-old boy's cervical wound on admission to the emergency department.

The parents were pleased because they could take part in their children's treatment and recovery, which helped to reduce stress levels. They were hesitant at the start of the home treatment, but all parents reported that after the first few days of applying the dressings on their children's injuries, they found the nursing procedure easy. They also reported that the treatment was emotionally fulfilling, because they could observe the wound healing process themselves and better reassure their children, who reported reduced or a complete lack of pain.

For all the cases who received honey treatment at home, there was no need for additional antibiotic therapy.

The results of the eight honey treated patients were compared to patients of similar age and severity of trauma. These patients were selected from the hospital archives. In four cases similar to cases 1–4, the healing time was approximately 6–12 days longer than in the honey group. Hospitalisation lasted for at least two-thirds of the time to complete healing. During that period, viral or nosomical infections were observed. Comparable cases required operations under general anaesthesia for re-approximation of the tissue gaps.

Case 5 (the severe burn case) became a double blind study in the same child. Here, the leg wound that healed after the honey treatment was eventually used for harvesting skin grafts for application on the child's back.

Discussion

To determine the optimal method of outpatient burn wound care, the clinician must consider the goals of outpatient management, i.e. rapid healing, prevention of infection, patient comfort, compliance, costs, maintaining full function and returning the patient to full productivity (Wyatt et al, 1990).

The traditional idea that silver sulfadiazine (SSD) cream is the product of choice for (minor) burns is still a reality in many intensive care units (ICUs), although its efficacy can be questioned (Miller, 2010). The authors of this paper argue that other methods could be superior and more cost-effective.

Honey is an inexpensive, simple and natural substance that has been successfully used to treat burn wounds (Efem, 1988; Molan, 1992; Cooper et al, 2002; Molan, 2006).

In 1998, Subrahmanyam randomly assigned 50 patients with less than 40% TBSA partial-thickness burns to one of two treatment groups. The groups were similar in gender, mean age, mechanism of injury, and burn surface area. Twenty-five patients were treated with pure, unprocessed, undiluted honey, and 25 patients were treated with SSD-impregnated gauze. By day 21, wound healing was complete in all of the patients in the honey-treated group and in only 21 of the 25 patients in the SSD-treated group ($p < 0.05$). Nevertheless, evidence exists that the use of SSD may place patients at increased risk of developing neutropenia, erythema multiforme, crystalluria, and methaemoglobinaemia (Subrahmanyam, 1998).

In a randomised comparative trial between honey and SSD with 150 patients who each had two wounds treated with either SSD or honey, the

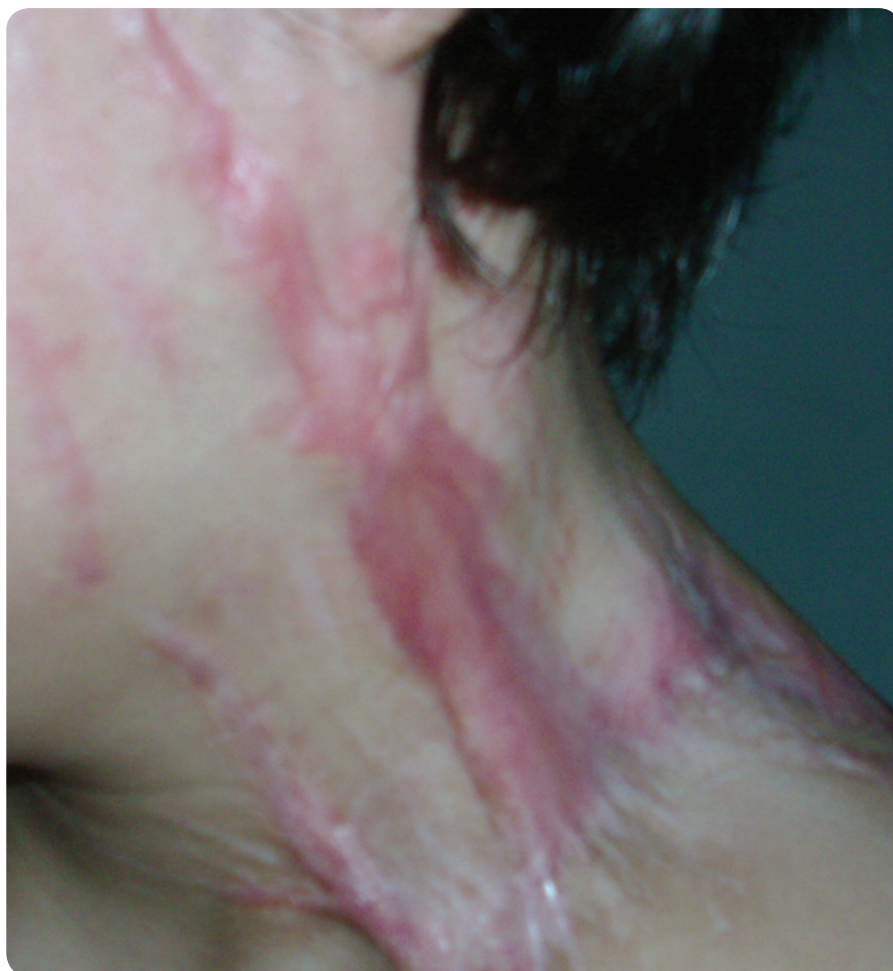

Figure 6. The same wound two months after epithelialisation.

rate of re-epithelialisation and healing of superficial and partial-thickness burns was significantly faster in the sites treated with honey than in the sites treated with SSD (13.47 ± 4.06 versus 15.62 ± 4.40 days, respectively; $P < 0.0001$). The sites treated with honey healed completely in less than 21 days, versus 24 days for the sites treated with SSD. Six patients had positive culture for *Pseudomonas aeruginosa* in the honey-treated sites, whereas 27 patients had positive culture in the SSD-treated sites. The results clearly showed greater efficacy of honey over SSD cream for treating superficial and partial-thickness burns (Malik, 2010).

In the small retrospective comparison evaluation ($n=8$) featured in this article, the mean burn epithelialisation time was 19 days. When compared retrospectively with the standard hospital protocol for medication such as povidone iodine 10% (Betadine) in similar lesions, the standard protocol shows delayed wound healing — roughly one month is needed for acceptable wound healing. This might be explained because of the local toxic effect on fibroblasts and keratinocytes leading to an inhibition of the healing process when using povidone iodine (Balin and Pratt, 2002; Wilson et al, 2005; Kaspar et al, 2006; Kataoka et al, 2006).

In vitro studies have demonstrated that honey has bioactivities that are beneficial in wound care. In work with cultures of leukocytes, honey has been shown to stimulate cytokine production and cytonocytes (Tonks et al, 2001, 2003).

The antimicrobial capacity of honey is based on its osmolarity (White, 2005), low PH (3.5), the presence of bioflavonoid and its capacity to produce hydrogen peroxide (Molan, 2001). Honey also stimulates the body's immune response through the production of cytokines, affects the mechanisms of B and T lymphocytes and stimulates the activity of phagocytes (Molan, 1999). Honey promotes wound debridement by autolysis, facilitating the

conversion of plasminogen in the wound into active plasmin (White, 2005). It decreases the wound malodour due to its high sugar content.

There is histological evidence of reduced numbers of inflammatory cells in wounds dressed with honey (Postmes, 1997). Honey also stimulates tissue growth (promotes the formation of healthy granulation tissue and re-epithelialisation) (Stephen-Haynes, 2005) and keratinocytes and fibroblast proliferation (DuToit and Page, 2009). Lastly, honey facilitates a moist wound healing environment (Lusby et al, 2002).

In the evaluation featured in this article, CE approved medical grade honey products with additional ingredients were used, and these products provided the same characteristics as described above for honey as a sole wound-healing agent. They provided a moist wound healing environment and were capable of speeding up wound healing compared to povidone iodine and other standard hospital protocol products retrospectively. *In vitro* research into Mesitran and Mesitran S using antibiotic resistant clinical isolates and extended-spectrum beta-lactamase (ESBL) strains of bacteriae showed both products to be highly effective (Stobberingh, 2010). The use of pure honey, however, can sometimes cause pain (Molan, 2006), but this did not occur in this evaluation.

Even though the patient number was small, the authors felt it was surprising that no wound infections were observed, considering the extent of some of the trauma. The honey treatment was responsible for the reduction (or prevention) of hospital stay, therefore reducing nosomical infections and thus speeding up healing time. Honey treatment prevented surgical procedures in the operating theatre.

The home care approach benefited both the patient and their parents. The role of parents is not to be underestimated in the healing process of paediatric patients (Zengerle-Levy,

2006). Parent participation in the care of hospitalised children improves the adverse aspects of staying in hospital, avoids parental separation and contributes to quality care for sick children (Coyne, 2008; Pardo, 2010). Clinically significant anxiety or depression is not uncommon in parents of burn victims (Phillips and Rumsey, 2008). In this evaluation, the stress of hospitalisation was replaced by the comfort of home, which was regarded as a major benefit for both parents and children, fitting in with the recommended family centred approach for paediatric injuries (Landolt et al, 2002).

The honey treatment was also cost-effective. The cost of one day of hospitalisation per paediatric patient in Hippokration Hospital is approximately 500 euros per day (this is an approximate estimation of the total cost of drugs, materials, nursing costs and doctor's fees). Reducing, or preventing, hospitalisation results in an immediate cost reduction for the healthcare system. The authors' estimation for this evaluation is that approximately 7,500 euros (for only 15 days hospitalisation) were saved on healthcare expenditure per patient.

Conclusion

The aim of the study featured in this article was to evaluate a better, quicker, safer and more cost-effective solution for paediatric burn and dermal trauma patients. The honey based products used in this evaluation:

- ▶▶ Were significantly more effective than standard conventional hospital protocol, and no adverse effects or allergies were observed
- ▶▶ Were effective in controlling or preventing infections — no infections were observed
- ▶▶ Provided a moist wound healing environment and speeded up healing (19 days vs 25–31 days) compared to conventional hospital protocol (povidone iodine)
- ▶▶ Prevented prolonged hospitalisation and thus nosomical complications
- ▶▶ Allowed home care by parents, reducing stress factors for both the child and their parents
- ▶▶ Were easy to use and resulted in

pain-free dressing changes, causing minimal discomfort for the patients

▶ Reduced healthcare costs.

The authors acknowledge that the sample size (n=8) of this retrospective comparative evaluation was small. However, the findings in one case where in the same patient on different body areas (leg and back) the honey treatment was more successful than the conventional treatment, give rise to be optimistic about having found a promising wound healing agent for paediatric burns and dermal trauma. **WUK**

Acknowledgements

The authors wish to thank the families and particularly the children for their participation. They also thank Xenofon Roussis, MD, PhD, paediatric surgeon, for his critical reviews throughout the writing of this article.

References

- Balin AK, Pratt L (2002) Dilute povidone-iodine solutions inhibit human skin fibroblast growth. *Dermatol Surg* 28(3): 210–4
- Cooper RA, Molan PC, Harding KG (2002) The sensitivity to honey of Gram-positive cocci of clinical significance isolated from wounds. *J Appl Microbiol* 93: 857–63
- Coyne I (2008) Disruption of parent participation: nurses' strategies to manage parents on children's wards. *J Clin Nurs* 17(23): 3150–8
- DuToit DF, Page BJ (2009) An *in vitro* evaluation of the cell toxicity of honey and silver dressings. *J Wound Care* 18(9): 383–9
- Efem S (1988) Clinical observations of the wound healing properties of honey. *Br J Surg* 75: 679–81
- Feldman RP, Goodrich JT (1999) The Edwin Smith Surgical Papyrus. *Childs Nerv Syst* 15(6–7): 281–4
- Kaspar D, Schwarz W, Claes L, Ignatius A (2006) Study of the toxicity of povidone-iodine for fibroblast-like cells (BALB-3T3) and primary human chondrocytes. *Arzneimittelforschung* 56(8): 605–11
- Kataoka M, Tsumura H, Kaku N, Torisu T (2006) Toxic effects of povidone-iodine on synovial cell and articular cartilage. *Clin Rheumatol* 25(5): 632–8
- Landolt MA, Grubenmann S, Meuli M (2002) Family impact greatest: predictors of quality of life and psychological adjustment in pediatric burn survivors. *J Trauma* 53(6): 1146–51
- Lusby PE, Coombes A, Wilkinson JM (2002) Honey: a potent agent for wound healing? *J Wound Ostomy Continence Nurses Soc* 29(6): 295–300
- Malik KI, Malik MA, Aslam A (2010) Honey compared with silver sulphadiazine in the treatment of superficial partial-thickness burns. *Int Wound J* 7(5): 413–7
- Miller AC, Rashid RM, Falzon L, Elamin EM, Zehtabchi S (2010) Silver sulfadiazine for the treatment of partial-thickness burns and venous stasis ulcers. *J Am Acad Dermatol* 17 Aug [Epub ahead of print]
- Molan PC (1992) The antibacterial activity of Honey. *Bee World* 73(2): 59–76
- Molan P (1999) The role of honey in the management of wounds. *J Wound Care* 8(8): 415–8
- Molan PC (2001). Honey as a topical agent for treatment of infected wounds. WorldWideWounds, available online at: www.WorldWideWounds.com
- Molan PC (2006) The evidence supporting the use of honey as a wound dressing. *Lower Extremity Wounds* 5(1): 40–54
- Pardo GD, García IM, Gómez-Cía T (2010) Psychological effects observed in child burn patients during the acute phase of hospitalization and comparison with pediatric patients awaiting surgery. *J Burn Care Res* 31(4): 569–78
- Phillips C, Rumsey N (2008) Considerations for the provision of psychosocial services for families following paediatric burn injury — a quantitative study. *Burns* 34(1): 56–62
- Postmes T, van den Bogaard AE, Hazen M (1993) Honey for wounds, ulcers, and skin graft preservation. *Lancet* 341(8847): 756–7
- Postmes TJ, Bosch MMC, Dutrieux R, Van Baare J, Hoekstra MJ (1997) Speeding up the healing of burns with honey. An experimental study with histological assessment of wound biopsies. In: Mizrahi A, Lensky Y, eds. *Bee Products: Properties, Applications and Apitherapy*. Plenum Press, New York NY, 27–37
- Stephen-Haynes J (2005) Implications of honey dressings within primary care. *Wounds UK Suppl* 1(3): 33–53
- Stobberingh EE (2010) Antibacterial activity of honey against ESBL-producing strains. Report by the department of Medical Microbiology University of Maastricht, Netherlands. (Data on file with the author)
- Subrahmanyam M (1998) A prospective randomised clinical and histological study of superficial burn wound healing with honey and silver sulfadiazine. *Burns* 24: 157–161
- Tonks A, Cooper RA, Price AJ, et al (2001) Stimulation of TNF- α release in monocytes by honey. *Cytokine* 14(4): 240–2
- Tonks AJ, Cooper RA, Jones KP, et al (2003) Honey stimulates inflammatory cytokine production from monocytes. *Cytokine* 21(5): 242–7
- van Middendorp JJ, Sanchez GM, Burridge AL (2010) The Edwin Smith papyrus: a clinical reappraisal of the oldest known document on spinal injuries. *Eur Spine J* 2010 Aug 10 [Epub ahead of print]
- White R, Cooper R, Molan P, eds (2005) *Honey: A modern wound management product*. Wounds UK, Aberdeen: 130–42, (1–23)
- Wilson RE (1996) Care of the burn patient. *Ostomy Wound Manage* 42(8): 16–8, 20–2, 24–6 *passim*; quiz 35–6
- Wilson JR, Mills JG, Prather ID, Dimitrijevic SD (2005) A toxicity index of skin and wound cleansers used on *in vitro* fibroblasts and keratinocytes. *Adv Skin Wound Care* 18(7): 373–8
- Wyatt D, McGowan DN, Najarian MP (1990) Comparison of a hydrocolloid dressing and silver sulfadiazine cream in the outpatient management of second-degree burns. *J Trauma* 30: 857–65
- Zengerle-Levy K (2006) Nursing the child who is alone in the hospital. *Pediatr Nurs* 32(3): 226–31, 237

Key points

- ▶▶ Honey products are more effective than conventional hospital protocol in the treatment of paediatric burns.
- ▶▶ Honey products prevent infection.
- ▶▶ Honey products speed up healing significantly.
- ▶▶ Home care reduces stress for young patients and their parents.
- ▶▶ Honey products reduce health care costs.