

# Use of a DACC-coated antimicrobial dressing in people with diabetes and a history of foot ulceration

This article describes two case reports using an innovative approach to the prevention and management of infection in diabetic foot wounds. In both case reports, Cutimed® Sorbact® (BSN medical) was successfully used to help prevent wound re-infection and enable the wounds to move on to complete healing. The dressings work on the principle of hydrophobicity, offering an alternative to the use of established antimicrobial products. Both wounds had a history of osteomyelitis and soft tissue infection in patients with predominantly neuropathic feet. These cases are part of an ongoing formal product evaluation which will be published later in the year.

Samantha Haycocks, Paul Chadwick, Karl Guttormsen

## KEY WORDS

Diabetic foot ulceration  
Infection  
Bioburden management  
DACC  
Cutimed® Sorbact®

More than 220 million people worldwide have diabetes (World Health Organization [WHO], 2011, [www.who.int/mediacentre/factsheets/fs312/en/](http://www.who.int/mediacentre/factsheets/fs312/en/)), and the lifetime incidence of diabetic foot ulceration (DFU) is estimated at 12–25%. One in every seven individuals with diabetes, and perhaps as many as one in every four, is likely to develop DFU (Setacci et al, 2009). Once ulceration has occurred, the systemic effects of diabetes impede the normal wound healing process.

The immunological impacts of diabetes render DFUs highly susceptible to infection. Acute wounds are a potential breeding ground for

pathogens because they do not have the protection of the normal flora (Hampton, 2010), and chronic wounds are characterised by a high bacterial count, the presence of more than one bacterial strain, the increased tendency to harbour drug-resistant organisms, and the presence of biofilms (Vowden et al 2008).

**Infection not only impairs healing, resulting in morbidity and hospitalisation, but in the absence of careful management can spread rapidly within the foot and lower limb causing tissue destruction and the necessity for amputation.**

Heightened bacterial burden in the wound increases the metabolic requirements of the tissues, stimulates a pro-inflammatory environment and encourages the in-migration of macrophages, leucocytes and monocytes, which can negatively impact on healing and subject the patient to an increased risk of developing infection (White, 2006).

Infection not only impairs healing, resulting in morbidity and hospitalisation, but in the absence

of careful management can spread rapidly within the foot and lower limb causing tissue destruction and the necessity for amputation. Gangrene, infection and a non-healing ulcer are the most common indications for amputation (Centre for Podiatric Medicine, 2006). More than 60% of non-traumatic amputations in the western world are performed on people with diabetes (Dalla Paola and Faglia, 2006). The economic impact of diabetes is significant. It is estimated that caring for patients with diabetes (2–3% of the population) consumes 5% of NHS resources and up to 10% of hospital in-patient resources (Mcintosh et al, 2003). Boulton (2004) goes on to suggest that 20% of the total expenditure is attributable to the management of foot problems.

Managing diabetic foot ulceration requires a number of principles which have been described by Edmonds and Foster (2000):

- ▶▶ Regular wound debridement to remove necrotic and non-viable tissue from within and around the wound
- ▶▶ Maintenance of a warm, moist environment for optimum wound healing
- ▶▶ Addressing pressure relief to reduce the pressure from the wound and its margins
- ▶▶ Infection control. The reduction of bioburden within the wound to

Samantha Haycocks is Advanced Podiatrist; Paul Chadwick is Principal Podiatrist; Karl Guttormsen is a Specialist Podiatrist, all at the Podiatry Department, Salford Royal Hospital, Salford



# Cutimed® Sorbact® Infection Management in a New Light

treat and prevent the development of active infection

- ▶ Holistic management. Looking at the person as a whole to manage risk factors such as poor blood supply, patient's health beliefs and education.

The two case reports described in this article explore a dressing which addresses one of the core principles of management outlined above; namely, the reduction of bioburden.

Reducing bacterial bioburden within the wound will result in improved healing and help prevent infection. Cutimed® Sorbact® (BSN medical Ltd) is an innovative wound dressing, coated in a fatty acid derivative called DACC (dialkylcarbamoylchloride), to which, in a moist environment, microbes bind (adsorb) irreversibly. It is effective in wounds where the primary goal is to reduce the bacterial burden (Ljungh et al, 2006). It may be used prophylactically, but is best used on unclean, colonised or infected exuding wounds.

Unlike other antimicrobial dressings which rely upon a chemically active agent to reduce bioburden, Cutimed Sorbact dressings offer an alternative approach to the management of increasing bacterial load in chronic wounds (Kammelander, 2008; Derbyshire, 2010; Hampton, 2010). Antimicrobial dressings containing silver and iodine depend on the use of ions which are donated to the wound and kill the bacteria therein. While there is no doubting the efficacy of silver-containing dressings in reducing bioburden, there have been some documented complications (Lansdown, 2002). In the use of higher levels of silver, greater clarification is required regarding silver toxicity. Lansdown (2004) comments that absorption of silver depends on the depth and extent of the wound, frequency, and mode of application. There has been a debate in the literature regarding the development of silver-resistant bacteria (Maillard and Denyer, 2006). However, this does not appear to

## Iconic Wound Care - Making Wound Care Easier

### Wound Bed

- Necrotic
- Infected
- Sloughy
- Granulating
- Epithelialising

### Wound Depth

- Shallow
- Deep
- Shallow or Deep

### Exudate Level

- Low
- Low to Moderate
- Moderate to High
- High to Very High

**Cutimed Sorbact - a SAFE and innovative antimicrobial dressings range for your Formulary.**



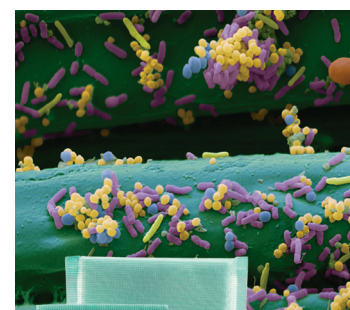
CUTIMED SORBACT is the only range of dressings coated with **DACC** that can reduce the bacterial load.<sup>1,2</sup>

In a moist environment, bacteria and fungi will **BIND** to the dressing helping to kick start the healing process.<sup>1,2</sup>

Dressings can be used **SAFELY** on all patients and on all moist wounds with none of the drawbacks of conventional antimicrobial dressings<sup>1,2</sup>:

- no cytotoxicity
- no bacterial toxin release
- no contraindications

Wound bacteria and fungi binding to Cutimed Sorbact



For further information please go to:  
**[www.cutimed.com](http://www.cutimed.com)** or contact us at  
**[advancedwoundcare.uk@bsnmedical.com](mailto:advancedwoundcare.uk@bsnmedical.com)**

1) Ljungh et al (2006) Using the principle of hydrophobic interaction to bind and remove wound bacteria. Journal of Wound Care, 15 (4): 175-80 2) Powell G (2009) Evaluating Cutimed Sorbact: using a Case Study Approach. British Journal of Nursing 18 (15): S30. S32-S36

be a problem in the diabetic foot (Percival et al, 2008). Silver products can cause skin staining to the wound and surrounding skin. A rare but more serious complication of using silver products is argyria, which occurs when cells absorb silver salts. This results in permanent discolouration of the skin. If the silver is absorbed by internal organs (argyrosis) it may impair their function (Parkes, 2006; Ahamed et al, 2010; Johnston et al, 2010).

Since the discovery of the natural element iodine in 1811 by the chemist Bernard Courtois, iodine and its compounds have been broadly used for prevention of infection and treatment of wounds. However, molecular iodine can be toxic for tissues, so formulations comprising combinations of iodine with carriers that decrease iodine availability were developed. Similarly, with iodine products complications have been reported. They can cause thyroid disruption. If patients have a history of a thyroid disorder, their thyroid function should be checked before and while using the product. Iodine dressings have a maximum dosage that may be used at any one time and a maximum length of time over which they can be used (Fletcher, 2006).

Other antibacterial agents are also available including honey and enzyme-based dressings such as Flaminal® (Ark Therapeutics). Recently, the use of honey as a topical wound antimicrobial has been revived. It has been shown to be clinically effective in a number of chronic wounds (Dunford et al, 2000). Honey contains flavanoids and is bacteriostatic. In addition, it produces hydrogen peroxide which affects bacterial growth (Dunford et al, 2000). A recent development in antimicrobial management of wounds is the use of enzymes to manage bacterial load. Flaminal, an alginate gel dressing containing a unique antimicrobial enzyme system, has been shown to kill antibiotic-resistant bacterial strains, including methicillin-resistant *Staphylococcus aureus* (MRSA), and promote wound healing (de la Brassinne et al, 2006).

Flaminal contains a glucose oxidase lactoperoxidase guaiacol (GLG) enzyme system, a version of the naturally occurring oxidase-peroxidase enzyme system, which has been shown in a number of studies to be bactericidal (De Smet et al, 2009). Flaminal combines strong antimicrobial activity with no cytotoxicity. The enzyme's glucose oxidase and lactoperoxidase control the bioburden in a similar way to honey. Honey works as an antimicrobial by using its 'built-in' glucose oxidase enzyme system for generating hydrogen peroxide (Molan, 2005). Hydrogen peroxide is a non-specific antimicrobial that kills all microorganisms (Russell, 2002). The antimicrobial effectiveness of hydrogen peroxide is increased greatly by peroxidase (White, 2006).

Honey contains sugars (glucose and fructose). With up to 40% glucose there is a theoretical risk of it adversely elevating the blood glucose level of diabetes when applied topically on a large open wound, but there have been no reported cases to date.

A slight stinging sensation on initial application has been reported. While this is not an issue in patients with neuropathy, honey may not be an appropriate treatment for very painful wounds (Dunford and Hanano, 2004).

This article looks at a novel way of managing increased wound bioburden without involving the donation of ions or other substances to a wound. It

uses DACC (Figure 1), a derivative of a natural fatty acid which works on the principle of hydrophobicity. Hydrophobic interaction is a basic physical principle, whereby hydrophobic organisms are attracted and bind to each other in an aqueous environment and are held together by the forces of surrounding water molecules. Most bacterial and fungal cells found in wounds express cell surface hydrophobicity (CSH) — the more pathogenic the bacteria, the more hydrophobic they tend to be (Doyle, 2000).

Upon direct contact with the wound bed, microorganisms including *Pseudomonas aeruginosa*, *Staphylococcus aureus* and *Candida albicans* are attracted to it in as little as 30 seconds (Ljungh et al, 2006).


In a moist environment, such as in the bed of a chronic wound, bacteria and fungi are attracted to the dressing, becoming irreversibly bound to it. On removal of the dressing, the bacteria, which cannot multiply once bound to the dressing, are lifted away. Cutimed Sorbact also binds harmful toxins released by bacteria that can impair healing (Ljungh et al, 2006).

The benefits of DACC technology include (Ljungh et al, 2006):

- ▶▶ Bacterial or fungal resistance does not develop
- ▶▶ No cytotoxicity
- ▶▶ As bacteria are not killed, there are no endotoxins released
- ▶▶ No known contraindications
- ▶▶ No risk of allergic reactions.

Cutimed Sorbact DACC-coated dressings can therefore be used as a primary dressing to line the wound bed, followed by a secondary dressing if necessary to maintain a moist wound environment, for exudate management, or for protection of the wound site.

The diabetic foot is a prime indication for use so long as moisture is present. If exudate levels are low, Cutimed Sorbact gel dressings are especially designed to bind microorganisms in all unclean, colonised and infected wounds, which are dry



**Figure 1. Bacteria and fungi binding to Cutimed Sorbact fibres by hydrophobic interaction.**



or have low levels of exudate. The hydrogel impregnation creates a moist wound environment and removes the bound bacteria which cannot multiply or 'escape'.

### Case report one

Mr C was a 51-year-old male with type 2 diabetes diagnosed in 2001. He had sensory neuropathy leading to a loss of feeling in both lower limbs. This was tested using a 10g monofilament and 128mgHz tuning fork. His peripheral circulation was intact with the dorsalis pedis and posterior tibial pulses palpable. He had a history of poor diabetes control. His average HbA1c was 9.8%.

In July 2006 he was admitted to hospital due to severe infection, necrosis and osteomyelitis to the right first metatarsal phalangeal joint. Following surgery and aggressive antibiotic therapy, he went on to heal in January 2007. Mr C continued to have recurrent breakdowns over the surgery site despite various off-loading devices and regular debridement. Mr C's job made it difficult for him to attend clinic as regularly as required.

In April 2009 he presented with ulceration over the right first metatarsal joint area due to excessive build up of callus and badly worn orthoses. At the follow-up appointment (7 May 2009) the area had blistered and there was erythema surrounding the wound and the foot was warm (Figure 2).

He was started on antibiotics (Co-amoxiclav 625mg tds) and the ulceration was dressed with a Cutimed Sorbact swab and a gentle, silicone foam dressing, Cutimed<sup>®</sup> Siltec (BSN medical Ltd).

The patient changed his own dressings between weekly podiatry reviews, and reported that the dressings were easy to apply and comfortable (Figures 3 and 4).

On 9 May 2009, the erythema had resolved and the ulceration size had decreased (Figure 4).



# Cutimed<sup>®</sup> Siltec

## Exudate Management in a New Light

### Iconic Wound Care

- Making Wound Care Easier

#### Wound Bed

- Necrotic
- Infected
- Sloughy
- Granulating
- Epithelialising

#### Wound Depth

- Shallow
- Deep
- Shallow or Deep

#### Exudate Level

- Low
- Low to Moderate
- Moderate to High
- High to Very High

**A range of foam dressings that offer the benefits of a gentle silicone wound contact layer, a super-absorbent layer and a highly breathable top film.**

- Pain-free, atraumatic dressing changes<sup>1</sup>
- Excellent exudate management<sup>2</sup>
- Minimal risk of maceration even under compression<sup>1,2</sup>



### Cutimed Siltec



For moderately to highly exuding wounds



### Cutimed Siltec L



For low to moderately exuding wounds



### Cutimed Siltec B



With a gently adhering border, for moderately exuding wounds

Heel and Sacrum shaped dressings also available.

For further information please go to:  
**[www.cutimed.com](http://www.cutimed.com)** or contact us at  
**[advancedwoundcare.uk@bsnmedical.com](mailto:advancedwoundcare.uk@bsnmedical.com)**

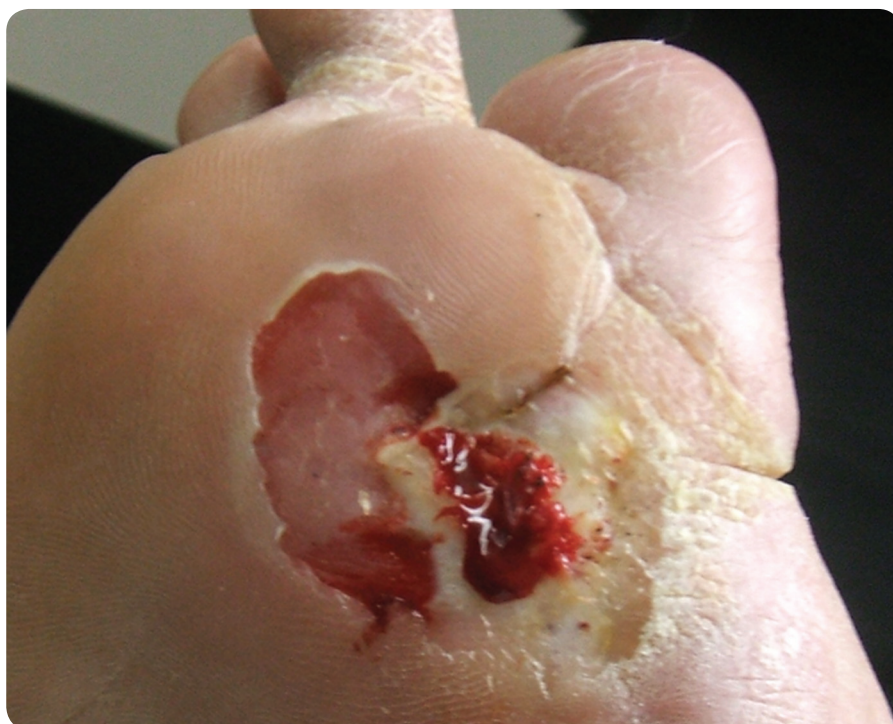

Figure 2. At the start of treatment with Cutimed Sorbact swabs.

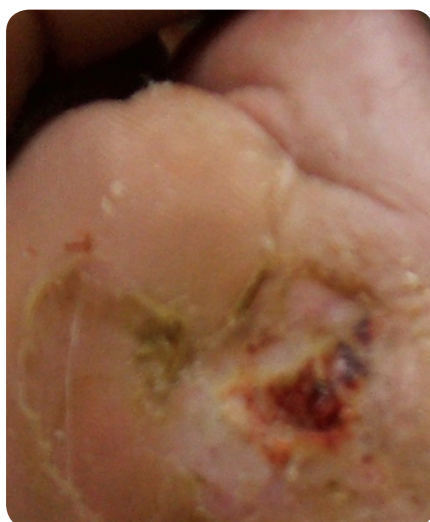

Figure 3. After one week of treatment with Cutimed Sorbact.

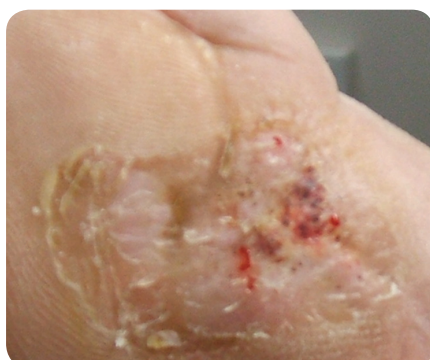

Figure 4. Ten days after starting treatment with Cutimed Sorbact.

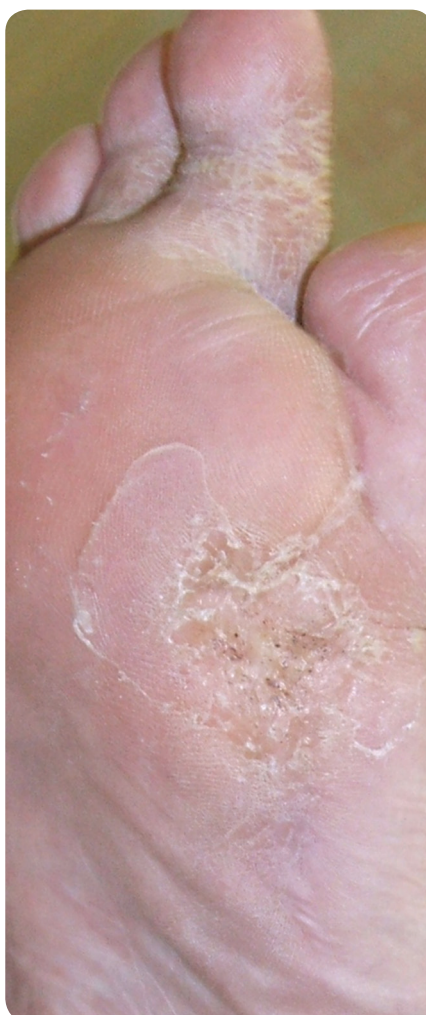

Figure 5. Healed wound on 11/06/09.

The wound went on to heal after five weeks' treatment with Cutimed Sorbact (Figure 5). There were no further clinical signs of infection during this time and the wound remains healed to date.

### Case report two

Mr C was a 63-year-old male with type 2 diabetes, which had been diagnosed in 1988. He had peripheral vascular disease with extensive calcification of the pedal vessels. He also had chronic kidney disease and was on dialysis three times a week. Sensory neuropathy was present in both feet and he had a history of *Clostridium difficile* and MRSA.

In 2006 he had a transmetatarsal amputation of the right foot due to extensive osteomyelitis. This went on to heal but in 2009 the foot re-ulcerated and osteomyelitis of the cuneiform was confirmed. Further surgical debridement of the infected bone was carried out. Despite regular debridement, appropriate off-loading devices and the use of advanced wound dressings, the wound remained open.

The wound was producing copious amounts of exudate and had several episodes of pseudomonas infection. Silver dressings were used to address the pseudomonas infection for two weeks. However, as silver dressings have to be used with caution in renal patients, as the excretion of any absorbed silver may be delayed, a DACC-coated dressing was started. The absorbent pad version was used due to the amount of exudate present (Figure 6). The dressing was changed three times a week by district nurses, with a weekly podiatry review. The dressing conformed well to the foot and the patient reported that it was comfortable. The Cutimed Sorbact pad managed the exudate and the pseudomonas infection resolved.

Cutimed Sorbact dressings were used for a six-month period.

The wound progressed to healing in December 2009.

# A new way to help assess wounds

## Key points

- » The immunological impacts of diabetes render DFUs highly susceptible to infection.
- » Reduction of bacterial bioburden within the wound will result in improved healing and help prevent infection.
- » DACC is a new antimicrobial technology utilised by Cutimed Sorbact wound dressings, to which, in a moist environment, microbes bind irreversibly. It is effective in wounds where the primary goal is to reduce the bacterial burden.
- » In such high risk patients with hard-to-heal and complex chronic wounds, these cases demonstrate that the use of a topical agent such as DACC from Cutimed Sorbact dressings can be safe and effective in managing the bacterial load to reduce the risk of infection.

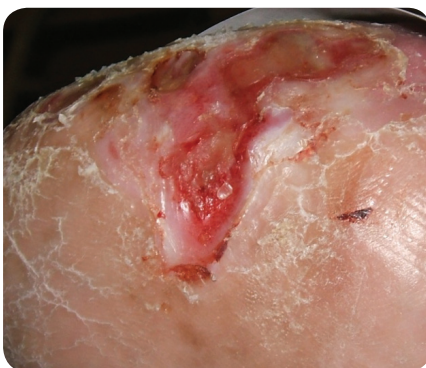

Figure 6. Start of treatment with Cutimed Sorbact Pad.

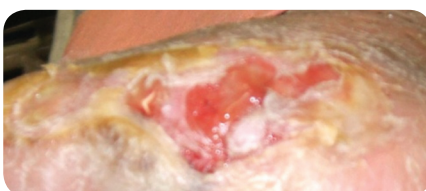


Figure 7. After one week's treatment with Cutimed Sorbact Pad.

## Iconic Wound Care Making Wound Care Easier

### Wound Bed

|  |                 |
|--|-----------------|
|  | Necrotic        |
|  | Infected        |
|  | Sloughy         |
|  | Granulating     |
|  | Epithelialising |

### Wound Depth

|  |                 |
|--|-----------------|
|  | Shallow         |
|  | Deep            |
|  | Shallow or Deep |

### Exudate Level

|  |                   |
|--|-------------------|
|  | Low               |
|  | Low to Moderate   |
|  | Moderate to High  |
|  | High to Very High |

**Free wound assessment tools  
available from**  
[advancedwoundcare.uk@bsnmedical.com](mailto:advancedwoundcare.uk@bsnmedical.com)



## Summary

The major benefits of antimicrobial dressings are that they can reduce bioburden, decrease the risk of infection, and create an environment that readily supports the normal sequence of wound healing (Mulder et al, 2007). It is established that infections may delay healing, cause failure of healing, and even cause wound deterioration (Dow et al, 1999). Microbial pathogens delay wound healing through several different mechanisms, such as persistent production of inflammatory mediators, metabolic wastes and toxins, and maintenance of the activated state of neutrophils which produce cytolytic enzymes and free oxygen radicals (Laato et al, 1988). This prolonged inflammatory response contributes to host injury and delays healing.

In such high risk patients with hard-to-heal and complex chronic wounds, these cases demonstrate that the use of a topical agent, such as DACC, coated onto Cutimed Sorbact dressings can be safe and effective in managing the bacterial load to reduce the risk of infection (Ljungh, 2006). These case reports also show that DACC, as an alternative antimicrobial option to reduce bacterial load, is useful for chronic wounds which require longer periods of antimicrobial dressing use than the two weeks described in the recent Best Practice Statement (Wounds UK, 2010), as no chemicals are donated into the wound bed from the dressing. In the authors' opinion, Cutimed Sorbact dressings are a safe and innovative newcomer to the antimicrobial dressing toolkit used by podiatrists. **WUK**

## References

- Ahamed M, Alsali MS, Siddiqui M (2010) Silver nanoparticle applications and human health. *Clin Chim Acta* 411(23–24): 1841–8
- Best Practice Statement: The use of topical antiseptic/antimicrobial agents in wound management. Wounds UK. Aberdeen 2010
- Boulton AJ (2004) The diabetic foot: from art to science. The 18th Camillo Golgi lecture. *Diabetologia* 47(8): 1343–53
- Centre for Podiatric Medicine (2006) *The Diabetic Foot*. Centre for Podiatric Medicine, Sydney, Australia. Available online at: [www.footinjury.com.au/pdf/diabeticfoot.pdf](http://www.footinjury.com.au/pdf/diabeticfoot.pdf) (last accessed 09 December 2009)
- Dalla Paola L, Faglia E (2006) Treatment of diabetic foot ulcer: an overview strategies for clinical approach. *Curr Diabetes Rev* 2(4): 431–47
- de la Brassinne, Thirion L, Horvat LI (2006) A novel method of comparing the healing properties of two hydrogels in chronic leg ulcers. *J Eur Acad Dermatol Venerol* 20(2): 131–5
- De Smet K, van den Plas D, Lens D, Sollie P (2009) Pre-clinical evaluation of a new antimicrobial enzyme for the control of wound bioburden. *Wounds* 21(3): 65–73
- Derbyshire A (2010) Innovative solutions to daily challenges: Cutimed Sorbact follow-up case studies. *Br J Community Nurs* 15(12): S42, 44–6
- Dow G, Browne A, Sibbald RG (1999) Infection in chronic wounds: Controversies in diagnosis and treatment. *Ostomy Wound Manag* 45(8): 23–40
- Doyle RJ (2000) Contribution of the hydrophobic effect to microbial adhesion. *Microbes Infect* 2: 391–400
- Dunford C, Cooper R, Molan P, White RJ (2000) The use of honey in wound management. *Nurs Standard* 15(11): 63–8
- Dunford CE, Hanano R (2004) Acceptability to patients of a honey dressing for non-healing venous leg ulcers. *J Wound Care* 13(5): 193–7
- Fletcher J (2006) Best Practice — Choosing an appropriate antibacterial dressing. *Nurs Times* 102(44): 46–9
- Edmonds ME, Foster VM (2000) *Managing the Diabetic Foot*. Blackwell Science Limited, Oxford
- Hampton S (2007) An evaluation of the efficacy of Cutimed Sorbact in different types of non healing wounds. *Wounds UK* 3(4): 1–6
- Hampton S (2010) How and when to use antimicrobial dressings. *Nurs Residential Care* 12(11): 522, 524, 526, 528–9
- Johnston HS, Hutchinson G, Hankin S, Stone V (2010) A review of the *in vivo* and invite toxicity of silver and gold particles: particle attributes and biological mechanisms responsible for the observed toxicity. *Crit Rev Toxicol* 40(4): 328–46
- Kammellander G, Locher E, Suess Burghart A, von Hallem B, Wipplinger P (2008) An investigation of Cutimed® Sorbact® as an antimicrobial alternative in wound management. *Wounds UK* 4(2): 10–18
- Laato MJ, Niinikoski C, Lundberg B, Gerdin (1988) Inflammatory reaction in blood flow and experimental wounds inoculated with *Staphylococcus aureus*. *Eur Surg Res* 20: 33–8
- Lansdown ABG (2002) Silver 1: Its antibacterial properties and mechanism of action. *J Wound Care* 13(1): 6–16
- Lansdown ABG (2004) A review of the use silver in wound care facts and fallacies. *Br J Nurs (Tissue viability Supplement)* 13(6): s6–19
- Ljungh A, Yanagisawa N, Wadström T (2006) Using the principle of hydrophobic interaction to bind and remove wound bacteria. *J Wound Care* 15(4): 175–80
- Maillard JY, Denyer SP (2006) Demystifying silver. In: European Wound Management Association (EWMA). Position Document: *Management of wound infection*. MEP Ltd, London: 7–10
- McIntosh A, Peters J, Young R, et al (2003) *Prevention and Management of Foot Problems in Type 2 diabetes: Clinical Guidelines and Evidence*. University of Sheffield, Sheffield
- Molan P (2005) Mode of action. In: White RJ, Cooper RA and Molan P, eds. *Honey: A modern wound management product*. Wounds UK, Aberdeen: 1–23
- Mulder GD, Cavorsi JP, Lee D (2007) Polhexamethylene biguanide. An addendum to current topical antimicrobials. *Wounds* 19(7): 173–82
- Parkes A (2006) Silver-coated dressing Acticoat. *J Trauma-Injury Infect Crit Care* 61(1): 239–40
- Percival SL, Wood SE, Nutekpor M, Bowler P, Radford A, Cochrane C (2008) Prevalence of silver resistance in bacteria isolated from diabetic foot ulcers and efficacy of silver containing wound dressings. *Ostomy Wound Management* 54(3): 30–40
- Powell G (2009) Evaluating Cutimed Sorbact using a case study approach. *Br J Nurs (Tissue Viability Supplement)* 18(15): S30, 32–6
- Russell AD (2002) Introduction of biocides into clinical practice and the impact on antibiotic-resistant bacteria. *Symp Ser Soc Appl Microbiol* 31: 121S–135S
- Setacci C, de Donato G, Setacci F, et al (2009) Diabetic patients: epidemiology and global impact. *J Cardiovasc Surg (Torino)* 50: 263–73
- Vowden P, Apelqvist J, Moffat C (2008) Wound complexity and healing. In: Position document: *Hard to heal wounds: a holistic approach*. MEP Ltd, London
- White RJ (2006) Delayed wound healing: what, when, why and in whom? *Nurs Stand (Suppl)* (1): 47–54