

The use of Medihoney™ Antibacterial Wound Gel on surgical wounds post-CABG

Patients undergoing coronary artery bypass graft (CABG) operations frequently have surgical leg wounds where veins have been harvested for grafting. Dehiscence of these wounds due to local infection can be a problem. Patients are often older and frequently have a combination of other medical problems which may impact on the wound healing process. The use of Medihoney™ Antibacterial Wound Gel in this patient group demonstrated that it was an effective antibacterial agent that also had a positive impact on the patients' quality of life through the reduction of wound symptoms including pain, odour and exudate.

Sharon Bateman, Tamsin Graham

KEY WORDS

Coronary artery bypass graft
Wound infection
Topical antimicrobial
Medihoney™
Quality of life

During elective coronary artery bypass graft (CABG) surgery, a key element of the procedure is the harvesting of the saphenous vein from the leg for use as a graft. The sternal wound and the saphenous vein harvest site are closed by primary intention using suturing and traditionally are dressed with a non-adherent dressing.

It was evident within the authors' cardiothoracic department (which undertakes about 100 procedures a month), that a small percentage of wounds were dehiscing as a result of localised wound infection (Figure 1). The standard treatment regimen of systemic antibiotics and a moist wound healing dressing such as an alginate was proving ineffectual and therefore it was altered to Medihoney™ Antibacterial Wound Gel (Medihoney Ltd, Reading) and the

progress of the wounds was monitored for between 1–2 months. Medihoney™ Wound Gel was selected as it is an antibacterial product effective against *Pseudomonas aureus*, *Staphylococcus aureus* and methicillin-resistant *S. aureus* but also has debriding, moist wound healing and odour control capabilities. In theory it appeared to meet all the patients' needs.

Background

Patients undergoing CABG surgery suffer with coronary artery disease. They are often older patients with a variety of associated conditions. Diabetes, obesity and being female have all been

identified as high-risk factors for wound infections in this patient population (Bhatia et al, 2003). There appears to be very little literature on infection rates and complications occurring in the graft sites of this patient group. Reports on the incidence of surgical leg wound site complications vary between 2–24% (Goldsborough et al, 1999).

It is well documented in the literature that as the skin ages its capacity to repair reduces (Desai, 1997). Ageing decreases the inflammatory response and the production of fibroblasts essential for the synthesis of collagen so older skin has less collagen

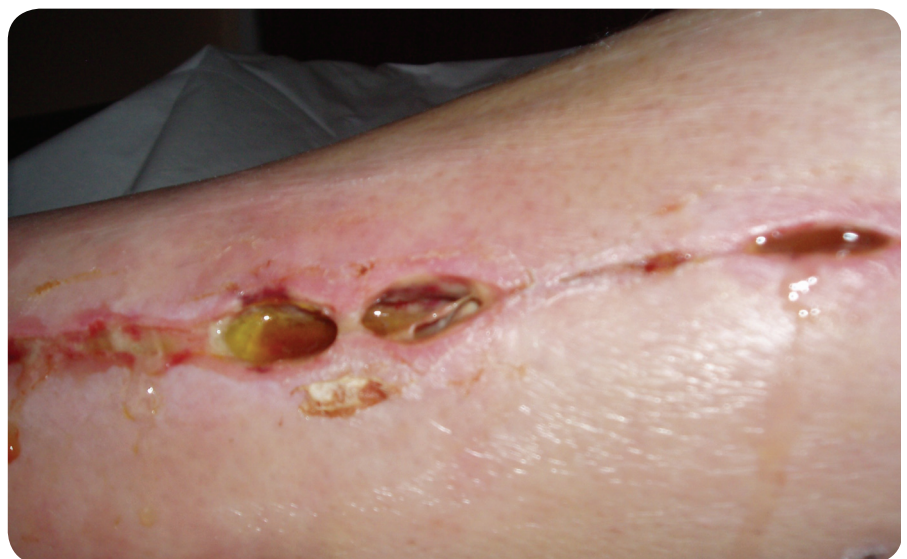

Figure 1. A dehiscid wound due to local wound infection following harvesting of the saphenous vein for use in a coronary artery bypass graft operation.

Sharon Bateman and Tamsin Graham are Nurse Specialists Cardiac Surgery, James Cook University Hospital, South Tees NHS Trust

and is less elastic (Lavker et al, 1986). Angiogenesis is also delayed and epithelialisation is slowed (Centre for Medical Education, 1992). In addition older people are less able to combat bacterial colonisation (Eaglstain, 1986) and mount a host response to pathogenic organisms. The point at which the host loses control over pathogenic organisms is termed 'critical colonisation' (Kingsley, 2003). Within the wound infection continuum (Figure 2) it is at this juncture of critical colonisation that the introduction of antimicrobial treatment to the wound bed is often advocated to assist the host in regaining control. Only if the patient becomes systemically infected or it is clinically indicated to do so, e.g. the patients are vulnerable to infection due to medical conditions or are undergoing complex surgical interventions such as CABG, should systemic antibiotic therapy be introduced (Kingsley, 2003).

Wound infection can lead to an increase in exudate level and, depending on the causative organism, tends to be synonymous with malodour (Edwards, 2000). The psychosocial effect of high exudate levels and malodour is well documented in the literature to have an adverse affect on quality of life and leads to anxiety, social isolation, and depression (Hyde et al, 1999). Malodour can also severely affect nutritional intake and appetite (Edwards, 2000).

It is critically important to determine the factors that may affect wound healing because if not then the success of the chosen wound dressing regimen may be adversely affected by both intrinsic and extrinsic factors that are independent of the dressing itself. The identification of such risk factors is a critical step in the patient assessment process and can be instrumental in achieving a successful wound healing outcome. In this patient evaluation programme the key factors of note were: age, wound infection, pain, associated disease processes, medication and the psychosocial effect of exudate and odour. However, selection of an appropriate wound dressing is also crucial to managing symptoms at the wound bed and to promote healing.

Using Medihoney™ as a topical antimicrobial
The challenge of wound care relates to two key areas: healing and/or managing

symptoms. Medical honey as contained in Medihoney™ Antibacterial Wound Gel has several key attributes: it deodorises,

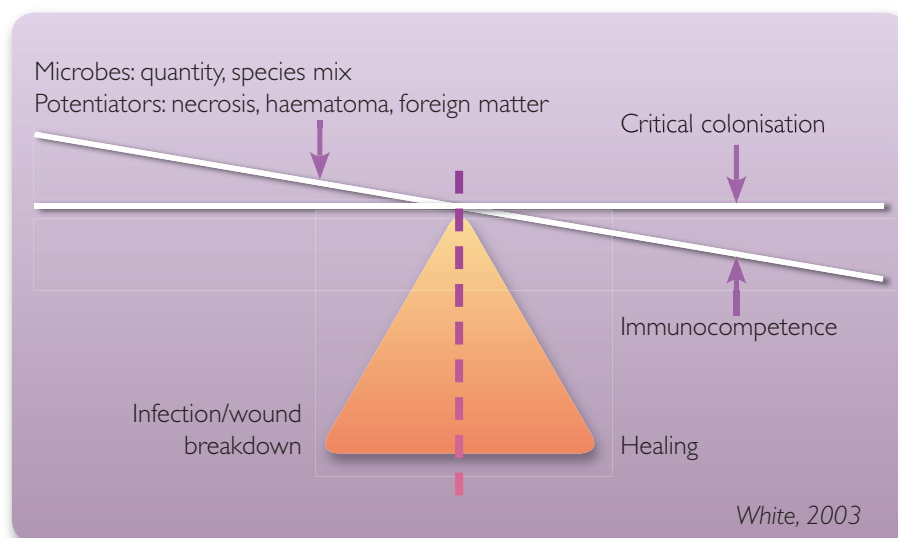


Figure 2. The wound infection continuum.

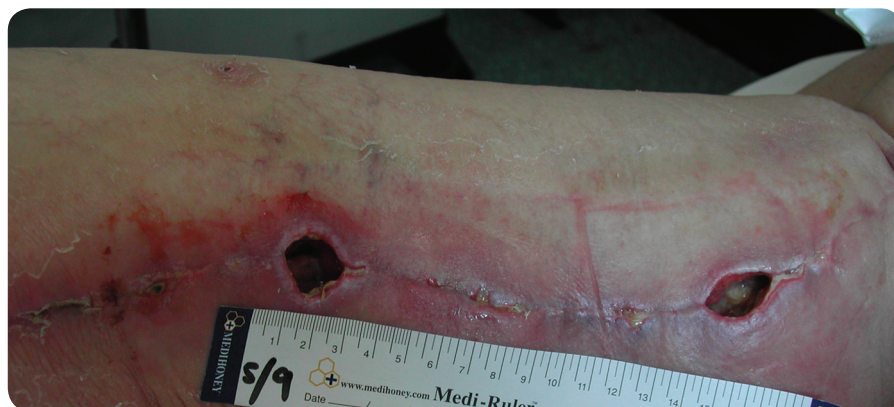

Figure 3. Patient 1 at initial wound assessment showing signs of localised wound infection, redness, and oedema to wound 1 on the left.

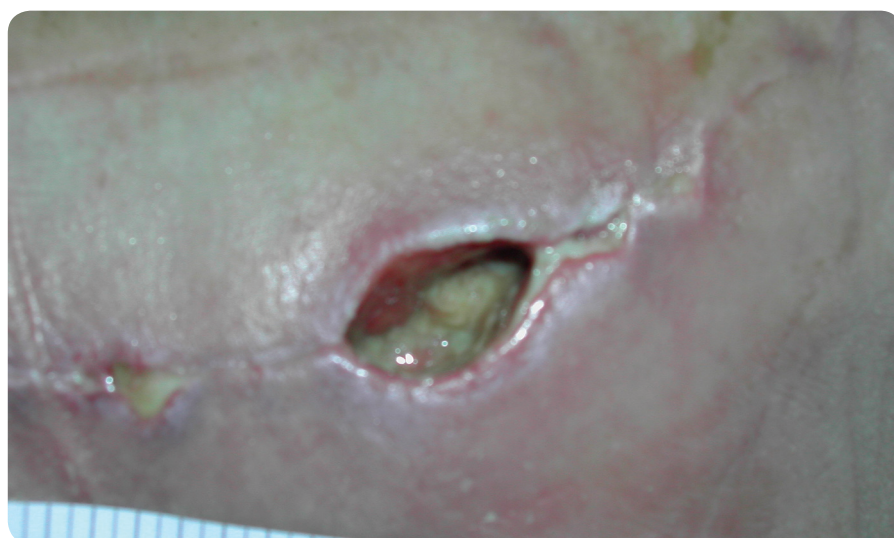


Figure 4. Patient 1 at initial wound assessment. Note presence of 60% sloughy tissue to the wound bed of wound 2.

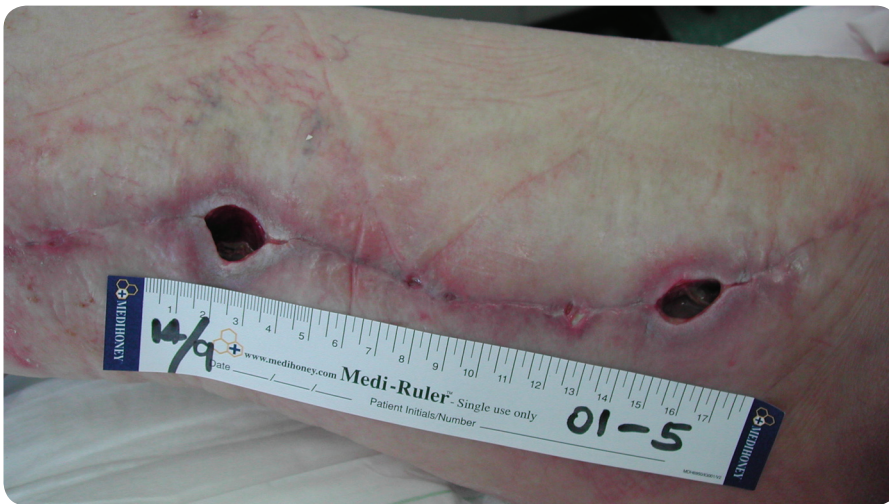

Figure 5. Patient 1, two weeks following treatment with Medihoney™ Antibacterial Wound Gel showing resolution of inflammation, redness and oedema which is indicative of the presence of wound infection.

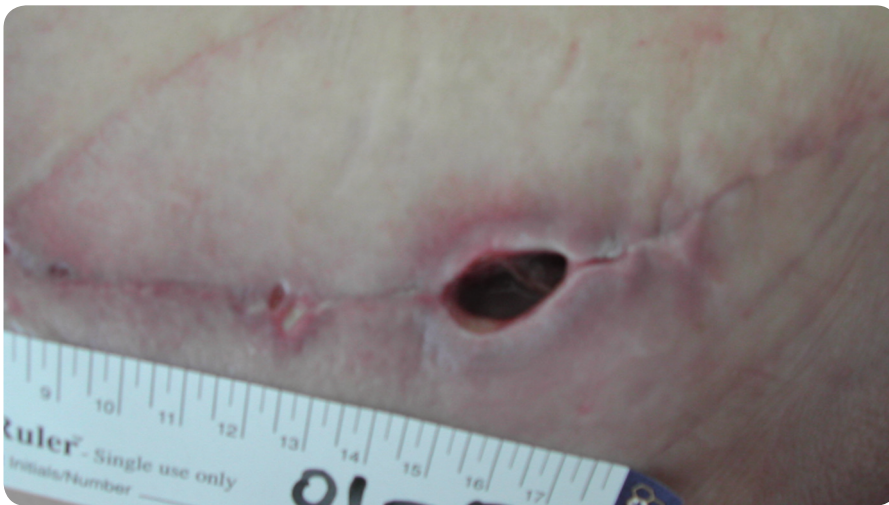


Figure 6. Patient 1. Wound 2 following two weeks of treatment with Medihoney™ Antibacterial Wound Gel. Note the resolution of the sloughy tissue to the wound bed leaving a granulating wound base with epithelial tissue at the margins.

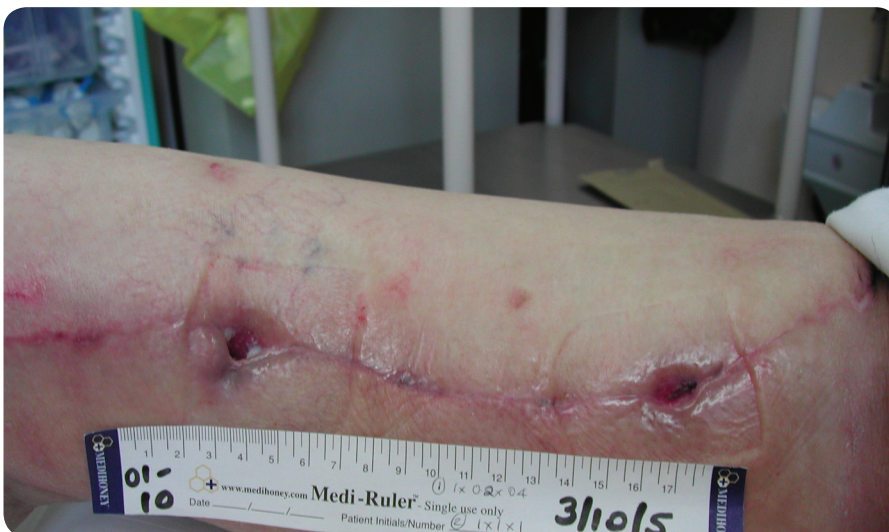

Figure 7. Patient 1 after four weeks treatment with Medihoney™ Antibacterial Wound Gel. Note the wounds have continued to decrease significantly in size and are granulating, indicating progression towards healing.

debrides, has an anti-inflammatory action and stimulates new tissue growth (Molan, 1999). In addition, only certain medical honeys, predominantly those from the *Leptospermum* plant from Australia and New Zealand as used in Medihoney™ Antibacterial Wound Gel, have the added advantage of being antibacterial and can be effective on antibiotic-resistant strains of bacteria (Molan, 2002).

When localised wound infection is present, the wound is placed into a state of persistent inflammation which can become uncomfortable for the patient. Associated problems such as increased exudate and malodour can be difficult to manage with topical dressings and can be distressing for the patient, adversely affecting their quality of life. Medihoney™ Antibacterial Wound Gel was considered to be a suitable wound treatment which could manage all these key symptoms.

The gel formulation was selected as it comes in an easy-to-use tube and the natural plant waxes that give the honey a thick consistency also provide protection at the wound bed.

Patient evaluation programme

Aims

The aim of this evaluation was to see how a medical honey would perform when used on post-operative surgical wounds with a view to changing dressing protocols within the unit. It was anticipated that this could improve the outcomes of patients undergoing cardiothoracic surgery.

The clinical challenge

In this evaluation, Medihoney™ Antibacterial Wound Gel was used:

- ▶▶ To resolve local wound infection
- ▶▶ To facilitate debridement of necrotic/sloughy tissue if present
- ▶▶ To promote the formation of granulation tissue
- ▶▶ To resolve pain and promote comfort
- ▶▶ To maintain a moist wound environment
- ▶▶ To resolve wound malodour.

The patients were monitored to see how effectively Medihoney™

Antibacterial Wound Gel progressed the wound to healing by measuring wound size and tissue type present, and how effectively it controlled the symptoms of pain, exudate, odour, discomfort and infection.

Patient population

Eight patients (male=4; female = 4; mean age=70 years) were randomly recruited into the clinical evaluation programme. All of the patients had cardiac disease, angina and hypertension. Two patients had noted peripheral vascular disease and five patients had suffered previous myocardial infarction. Other associated disease processes that may have influenced wound healing included diabetes mellitus (type 2) and morbid obesity.

Of the patients participating in the evaluation, six had undergone CABG surgery with a varied number of anastomoses per patient, one patient had mixed valves replaced, and one patient had CABG/valve replacement surgery. In all of the patients, the saphenous vein was harvested from either the right or left leg at either an upper or lower level for use as a graft.

Medihoney™ Antibacterial Wound Gel was selected as the active primary product of choice for all wounds in this programme. The gel was applied by squeezing a 3mm layer of honey from the tube directly onto the wound bed. An adhesive bordered non-adherent gauze dressing (Primapore®: Smith and Nephew, Hull) was then applied to cover the wound. Dressings were reapplied as required within the hospital environment or outpatients wound clinic. The length of the evaluation was dependent on the patient returning to the outpatient department's wound clinic, and so varied according to the patient's overall condition, and their ability to return to the clinic and give consent for further assessment of their wounds.

Wound assessment

At each assessment all wounds were recorded anatomically, measured using disposable measuring rulers and photographed depending on the

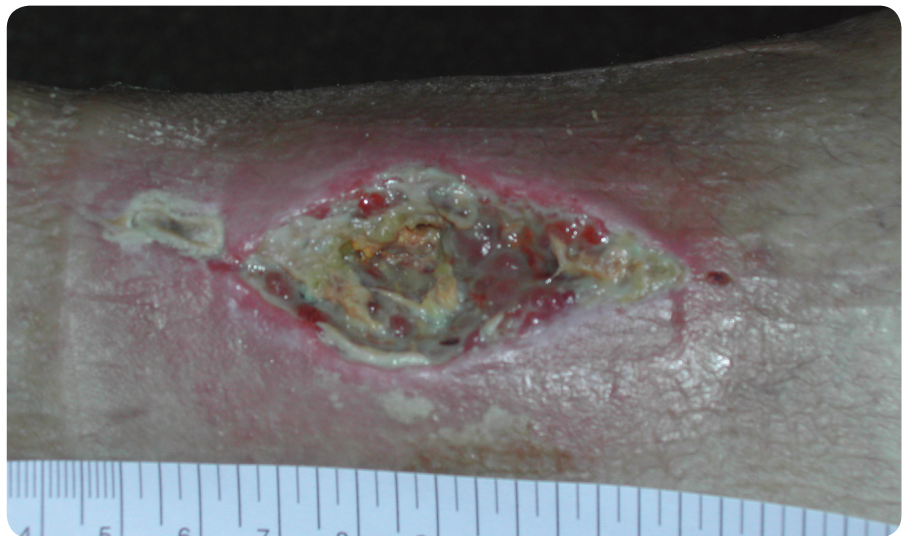

Figure 8. Patient 2 at wound assessment, before sharp debridement. Necrotic, sloughy tissue and green discoloration is present in parts.

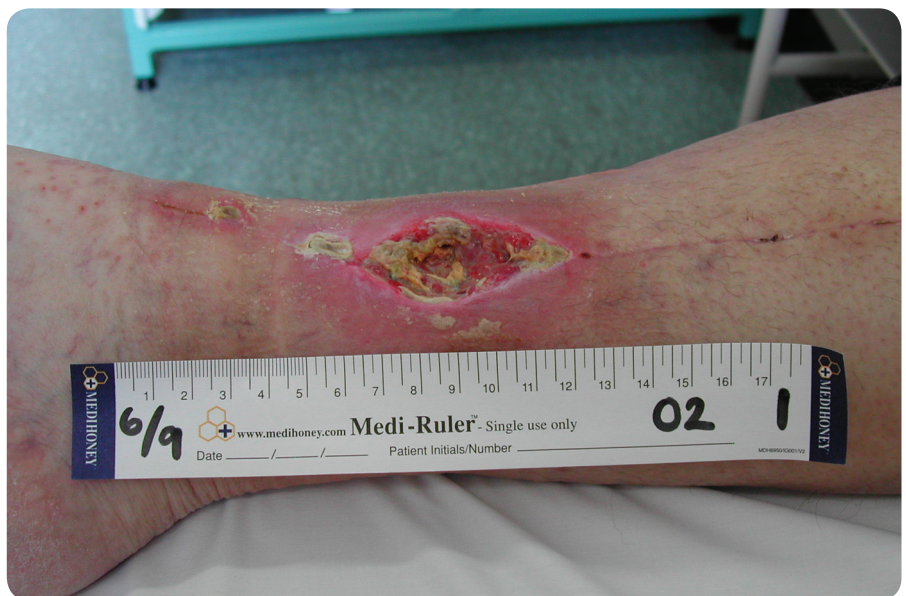

Figure 9. Patient 2 at wound assessment showing inflammation and oedema to surrounding tissues.

availability of camera equipment. The predominant tissue types present in the wound bed were noted, any signs of clinical wound infection observed, and swabs taken to monitor bacterial status, according to local protocol. Furthermore, some patients initially had raised white cell counts and C-reactive protein levels indicative of infection. Departmental policy also dictated that antibiotics were given to any patient with a swab result indicating bacterial colonisation irrespective of the topical dressing applied. The symptoms of exudate, odour and pain/comfort were assessed and the findings recorded using a Likert scale (1–5; with 1 being

the lowest rating indicating absence of symptoms). A numerical scale ranging from 0 to 10 was used for pain assessment to give the patient a wider choice of response between no pain (0) and severe pain (10). All wounds were reassessed using the same parameters at dressing change, with frequency of assessment varying according to the individual wounds.

Results

The results of the eight-patient evaluation are presented in *Table 1*. The findings demonstrated a significant reduction in wound size, pain, odour and exudate, indicating

that Medihoney™ Antibacterial Wound Gel reduced the bioburden of the wounds to enable them to progress towards healing.

The following two case reports from the evaluation demonstrate the effect of Medihoney™ Antibacterial Wound Gel on wounds which had been present for longer than two weeks and which showed no signs of healing.

Case reports

Patient 1

The patient presented with two cavities on the right upper thigh along the suture line of the saphenous vein harvest site. The patient's wounds had been present for 15 days and previously dressed with an alginate, gauze and an adhesive secondary dressing. At initial assessment, measurements were taken. Wound 1 measured 20x15x15mm and wound 2 25x15x 20mm. Both wound beds presented with 60% sloughy tissue, 20% granulation tissue and 20% epithelial tissue. Before the initial assessment, the wounds had been routinely swabbed and showed a very heavy growth of mixed enterobacteria and skin commensals. As a result, treatment with ciprofloxacin 500mg twice daily for 10 days and flucloxacillin 1g four times a day for five days had already been initiated. However on evaluation, there was still evidence of wound infection noted by the presence of redness, oedema and moderate pain recorded at the wound site (*Figures 3 and 4*). The wounds were moderately exuding leading to strikethrough and a mild malodour was noted. The wounds were redressed initially every two days for the first three weeks of the evaluation, gradually reducing to weekly for the final two weeks.

The outcome

Patient 1 was treated with Medihoney™ Antibacterial Wound Gel for a 5-week period. Within nine days the sloughy tissue had resolved leaving a 100% granulating, epithelialising wound bed. The wound dimensions had started to decrease in size, indicating a progression towards healing, but most importantly wound symptoms

All wounds that were treated with Medihoney™ Antibacterial Wound Gel during the evaluation period demonstrated a significant decrease in size (some to complete healing) and an improvement/ resolution of the key clinical symptoms which were monitored: pain/comfort, odour and exudate level.

were resolving. Pain at the wound site was initially assessed to be mild (3) but was reported to be absent (0) on completion of the evaluation. At dressing changes the wounds were assessed to be more comfortable, reducing from average (3) to excellent (1) within two weeks. Wound infection was resolving by week two, indicated by the recorded reduction in both exudate level (reducing from 3 to 1) and odour scores (reducing from 2 to 1). The resolution of inflammation, redness and slough can be seen in *Figures 5 and 6*.

At week 5, exudate and odour were absent (1), wound 1 had significantly decreased in size and measured 10x2x4mm, and wound 2 measured 10x10x8mm (*Figure 7*). The wounds were reported to be comfortable (1). As a result, the patient was successfully discharged into the primary care setting.

Patient 2

Patient 2 presented with one extensive cavity to the lower saphenous vein harvest site which had been present for four weeks. The wound was dressed with alginate and gauze as a secondary dressing. On entry into the evaluation, the wound measured 70x25x15mm. The wound bed consisted of 90% necrotic/sloughy tissue and there were visible signs of infection, noted by the green discoloration of the wound bed in areas, and redness, inflammation and oedema of the peri-wound area (*Figures 8 and 9*). A routine swab had previously been taken and sent for culture and sensitivity and showed no significant growth. However, the patient

was already taking flucloxacillin 500mg four times daily and ciprofloxacin 400mg twice a day at the start of the evaluation, initiated according to local protocol and due to the clinical signs of infection present in the wound.

On initial assessment, the patient was assessed as having moderate to severe pain (7) for which paracetamol 1g four times a day was taken. Both exudate levels and odour were high (4). Manual sharp debridement of the necrotic eschar was carried out before the application of Medihoney™ Antibacterial Wound Gel.

The outcome

Patient 2 was treated with Medihoney™ Antibacterial Wound Gel for seven weeks. Within 20 days the sloughy tissue had resolved leaving a 100% granulating, epithelialising wound bed. Some slough (20%) did represent for a seven-day period during the evaluation (at week 4). This can be common if pathogens become more virulent and the bacterial burden of the wound increases. At this time a repeat swab showed heavy growth of *S. aureus*, *Streptococcus B* and mixed enterobacteria. The patient was commenced on a further dose of systemic antibiotics — erythromycin, 500mg. The slough was resolved quickly (within a week) and at no time did this delay the progression of the wound towards healing, indicated by a continued reduction in wound dimensions.

The wound dimensions across the evaluation period showed a decrease in size; at week seven, the wound measured 28x8x2mm. Most importantly, the wound symptoms were resolving. Pain at the wound site initially assessed as moderate to severe (7) now was reported to be absent (0) and the wound was considered to be more comfortable at dressing changes (1) within three days of treatment with the gel. Both exudate levels and malodour decreased as the wound infection resolved during the seven weeks and peaked again during week four as the episode of infection reoccurred.

Discussion

All wounds that were treated with Medihoney™ Antibacterial Wound Gel during the evaluation period demonstrated a significant decrease in size (some to complete healing) and an improvement/resolution of the key clinical symptoms which were

monitored: pain/comfort, odour and exudate level.

Three of the patients in the study had initial pain scores of 7–9 indicating severe pain but all three reduced their pain rating within the first dressing change; one subject's rating reduced

from 7 to 0 within three days. All eight of the patients' pain scores reduced to 0 by the end of the evaluation (*Table 1*).

Six of the eight patients had discomfort of varying degrees (3–5/5) at the beginning of the evaluation with all reducing to good/excellent (1–2) by

Table 1
Results of eight patient clinical evaluation programme.

	Study period	Size	Tissue type	Presence of wound infection	Pain (0–10 no-pain–severe pain)	Comfort (1–5 excellent–poor)	Exudate (1–5 low/none–high)	Odour (1–5 mild–high)
Patient 1 initial assessment	5 weeks	20x15x15mm and 25x15x20mm	60% slough 20% granulation 20% epithelial	Yes	Mild to moderate (3–5)	Average (3)	Moderate (3)	Mild (2)
Patient 1 final assessment		10x2x4mm and 10x10x8mm	100% granulation/epithelial	No	None (0)	Excellent (1)	None (1)	Nil (1)
Patient 2 initial assessment	7 weeks	70x25x15mm	90% necrotic sloughy 10% granulation	Yes	Moderate to severe (7)	Average (3)	Moderate to high (4)	Moderate to high (4)
Patient 2 final assessment		28x8x2mm	100% granulation/epithelial	No	None (0)	Excellent (1)	None (1)	Nil (1)
Patient 3 initial assessment	5 weeks	120x20x15mm	90% necrotic/sloughy	Yes	Moderate to severe (7)	Average (3)	High (5)	Nil (1)
Patient 3 final assessment		115x8x2mm	100% granulation/epithelial	No	None (0)	Excellent (1)	None (1)	Nil (1)
Patient 4 initial assessment	5 weeks	80x15x15mm	50% necrotic/sloughy	Yes	Severe (9)	Poor (5)	High (4)	High (5)
Patient 4 final assessment		30x5x2mm	100% granulation/epithelial tissue	No	None (0)	Excellent (1)	None (1)	Nil (1)
Patient 5 initial assessment	4 weeks	60x50x50mm	20% necrotic	Yes	Mild (1)	Good (2)	Moderate to high (4)	Moderate (3)
Patient 5 final assessment		30x30x5mm	95% granulating 5% epithelialising	No	None (0)	Excellent (1)	None (1)	Nil (1)
Patient 6 initial assessment	3 weeks	2x2x15mm	80% epithelialising 20% granulating	Yes	Mild to moderate (4)	Average (3)	None (1)	Mild to moderate (2)
Patient 6 final assessment		2x2x5mm	90% epithelialising 10% granulating	No	None (0)	Good (2)	None (1)	Nil (1)
Patient 7 initial assessment	4 weeks	70x5x30mm and 10x10x10mm	35% sloughy 45% granulating 20% epithelialising	Yes	Moderate (4)	Good (2)	Low to moderate (2)	Moderate (3)
Patient 7 final assessment		10x2x2mm and healed	95% granulating 5% epithelialising	No	None (0)	Excellent (1)	None (1)	Nil (1)
Patient 8 initial assessment	1 day	80x10x30mm	20% granulating 50% epithelialising 10% sloughy	No	Mild to moderate (4)	Average (4)	Moderate (3)	Mild to moderate (2)
Patient 8 final assessment		60x10x25mm	40% granulating 60% epithelialising	No	Mild to moderate (3)	Excellent (1)	Low to moderate (2)	Nil (1)

the end. Exudate in all cases reduced to low or none and wound odour was removed in all patients.

Seven of the eight patients who had shown signs of wound infection on assessment had resolved this by the close of the evaluation period. Most cases were resolved within a couple of weeks through the use of the gel and systemic antibiotics where clinically indicated. Not all the patients were taking or prescribed antibiotics during the evaluation period. Antibiotic therapy was commenced according to swab results and clinical appearance of the wound. Not all patients were taking or prescribed antibiotics during the evaluation period. The patients had either finished taking a course of antibiotics before the commencement of honey, or had just started a short course of antibiotics.

It is unclear why Patient 2 presented with a negative swab before commencement of the evaluation when there were so many clinical signs of infection and confirmed by the later swab.

In the authors' past experience of these type of patients with critically colonised and infected wounds, it would seem that the wounds are often unreceptive to a short course of antibiotics. Biofilms and cleaning the wound by modulating the pH are all also unaffected by systemic antibiotics but can be affected positively through the use of antibacterial medical honey (Molan, 2005; Irish et al, 2006). It was difficult to determine the exact effects of the gel on the bacteria load, because of the coadministration of antibiotics but the use of Medihoney™ Antibacterial Wound Gel appeared to heal the wounds effectively.

The decision to continue with the use of the gel in these wounds once the signs of infection had resolved was made on the basis that honey also acts as a moist wound healing product which may assist granulation and epithelialisation (Molan, 2005) as well as acting as an antibacterial barrier to prevent infection (Lusby et al, 2002; Molan, 2002; Cooper,

2005). By considering the price of the honey and frequency of dressing change it was felt to be cost-effective to continue with the product until the wound had healed.

Conclusions

These results are a clear indication of the effectiveness of Medihoney™ Antibacterial Wound Gel in the management of wounds which are infected or are at risk of infection. The correlation in resolution of clinical signs and symptoms indicates the effectiveness of the treatment regimen. Due to the effectiveness on healing and patient and staff acceptability of the product, the use of medical honey has now become a regular dressing choice within the authors' cardiothoracic unit. **WUK**

References

- Bhatia JY, Pandey K, Rodrigues C, Mehta A, Joshi VR (2003) Post operative wound infection in patients undergoing coronary artery bypass graft surgery: a prospective study with evaluation of risk factors. *Ind J Med Microbiol* 21(4): 246–51
- Centre for Medical Education (1992) *The Wound Programme Dundee*. University of Dundee, Dundee
- Cooper R (2005) The antimicrobial activity of honey. In: White R, Cooper R, Molan P, Eds. *Honey: A Modern Wound Management Product*. Wounds UK, Aberdeen: 24–32
- Desai H (1997) Ageing and wounds: Part 2. Healing in old age. *J Wound Care* 6(5): 237–9
- Eaglstein WH (1986) Wound healing and ageing. *Dermatol Clin* 4: 481–4
- Edwards J (2000) Managing malodorous wounds. *J Comm Nurs* 14(4): 37–42
- Goldsborough, MA, Miller MH, Gibson J et al (1999) Prevalence of leg wound complications after coronary artery bypass grafting: determination of risk factors. *Am J Critical Care*
- Hyde C, Ward B, Horsfall J, Winder G (1999) Older women's experiences of living with chronic leg ulceration. *Int J Nurs Pract* 5(4): 189–98
- Irish J, Carter D, Blair S (2006) *Honey prevents biofilm formation in staphylococcus aureus*. Proceedings of the Eighth Asian Apicultural Association Conference. Perth, Australia
- Kingsley A (2003) the wound infection continuum and its application to clinical practice. *Ostomy Wound Management* Jul 49(7A Suppl): 1–7
- Lavker RM, Zheng PS, Dong G (1986) Morphology of aged skin. *Dermatologic Clinics* 4(3): 379–89
- Lusby PE, Coombes A, Wilkinson JM (2002) Honey: A potent agent for wound healing? *J Wound Ostomy Cont* 29(6): 295–300
- Molan P (1999) The role of honey in the management of wounds. *J Wound Care* 8(8): 415–8
- Molan P (2002) Re-introducing honey in the management of wounds and ulcers-theory and practice. *Ostomy Wound Management* 48(11): 28–40
- Molan P (2005) Mode of action. In: White R, Cooper R, Molan P (eds) *Honey: A Modern Wound Management Product*. Wounds UK, Aberdeen: 1–23
- White R (2003) Wound infection continuum. In: *Trends in Wound Care*. Vol 2. Quay Books, Wiltshire: 15

Key Points

- ▶▶ Elective coronary artery bypass graft involves the creation of a surgical wound on the leg when the saphenous vein is harvested for use as a graft.
- ▶▶ Comorbidities and the typical profile of a patient undergoing CABG mean that they could have an increased risk of infection as they are less able to mount a host response to pathogenic organisms.
- ▶▶ In a patient evaluation programme of eight post-CABG patients, the graft wound was treated with Medihoney™ Antibacterial Wound Gel to resolve local infection, promote formulation of granulation tissue, resolve pain, maintain a moist wound environment and reduce malodour.
- ▶▶ Medihoney™ was effective in all eight patients. The wounds all reduced in size and there was also a reduction in pain, odour and exudate. The wound gel had reduced the bioburden of the wounds enabling them to progress to healing.