

# OVERVIEW OF DIFFERENT DIABETIC FOOT PRESENTATIONS

Foot ulceration is a serious, but all too common, complication of diabetes mellitus; 12–25% of individuals with diabetes will develop a foot ulcer at some stage of their disease (O’Loughlin, 2010). This is concerning given that diabetic foot ulcers are widely acknowledged to be a source of major distress and morbidity as well as an enormous drain on healthcare resources (Jeffcoate et al, 2009). This article looks at the various diabetic foot presentations and stresses the importance of fostering a patient-centred, holistic approach towards treatment.

*Five-year mortality rates after new-onset diabetic ulceration are higher than those for several types of cancer, including prostate, breast, colon and Hodgkin’s disease*

The global prevalence of diabetes is increasing at an alarming rate and this will significantly impact on healthcare resources with costs estimated to account for as much as 7–13% of total worldwide healthcare expenditure by 2025 (IDE, 2005).

The costs associated with diabetic foot disease are not just financial — the personal costs to those affected by the devastating consequences of diabetic foot ulceration (DFU) or lower limb amputation must also be considered. Ribu et al (2007) undertook a multi-centre study comparing health-related quality of life in DFU patients, with a non-ulcerated diabetes group and the general population. The findings indicated that those with DFU reported poorer health-related quality of life than those with diabetes without foot ulceration, and the general population.

Furthermore, five-year mortality rates after new-onset diabetic ulceration have been reported between 43% and 55% and up to 74% for patients with lower-extremity amputation. To put this into context, these rates are higher than those for several types of cancer, including prostate, breast, colon, and Hodgkin’s disease (Robbins et al, 2008).

The pathogenesis of diabetic foot ulceration is often multifactorial — peripheral neuropathy (nerve dysfunction) and peripheral vascular disease are major factors in the development of diabetic foot ulcers. The combination of these and an increased risk of infection predispose people with diabetes to foot ulcers.

However, there are a large number of other risk factors leading to foot complications. These include uncontrolled cardiovascular risk factors, such as high blood pressure, high cholesterol and obesity. Smoking, increasing age, longer duration of diabetes and family history also play key roles (O’Loughlin, 2010) (*Figure 1*).

## *Peripheral neuropathy*

Prolonged hyperglycaemia can give rise to peripheral poly-neuropathy (peripheral nerve dysfunction) affecting the following pathways:

- ▶ Sensory pathways (loss of sensation)
- ▶ Motor pathways (impaired muscle function)
- ▶ Autonomic pathways (loss of control of autonomic nerves which can lead to dry skin, lack of sweating and oedema).

## *Sensory neuropathy*

Loss of protective sensation (sensory

CAROLINE MCINTOSH is a Senior Lecturer/ Head of Podiatry at the National University of Ireland, Galway

MARTINA LEONARD, Final Year Podiatry Student, Discipline of Podiatry, School of Health Sciences, National University of Ireland, Galway

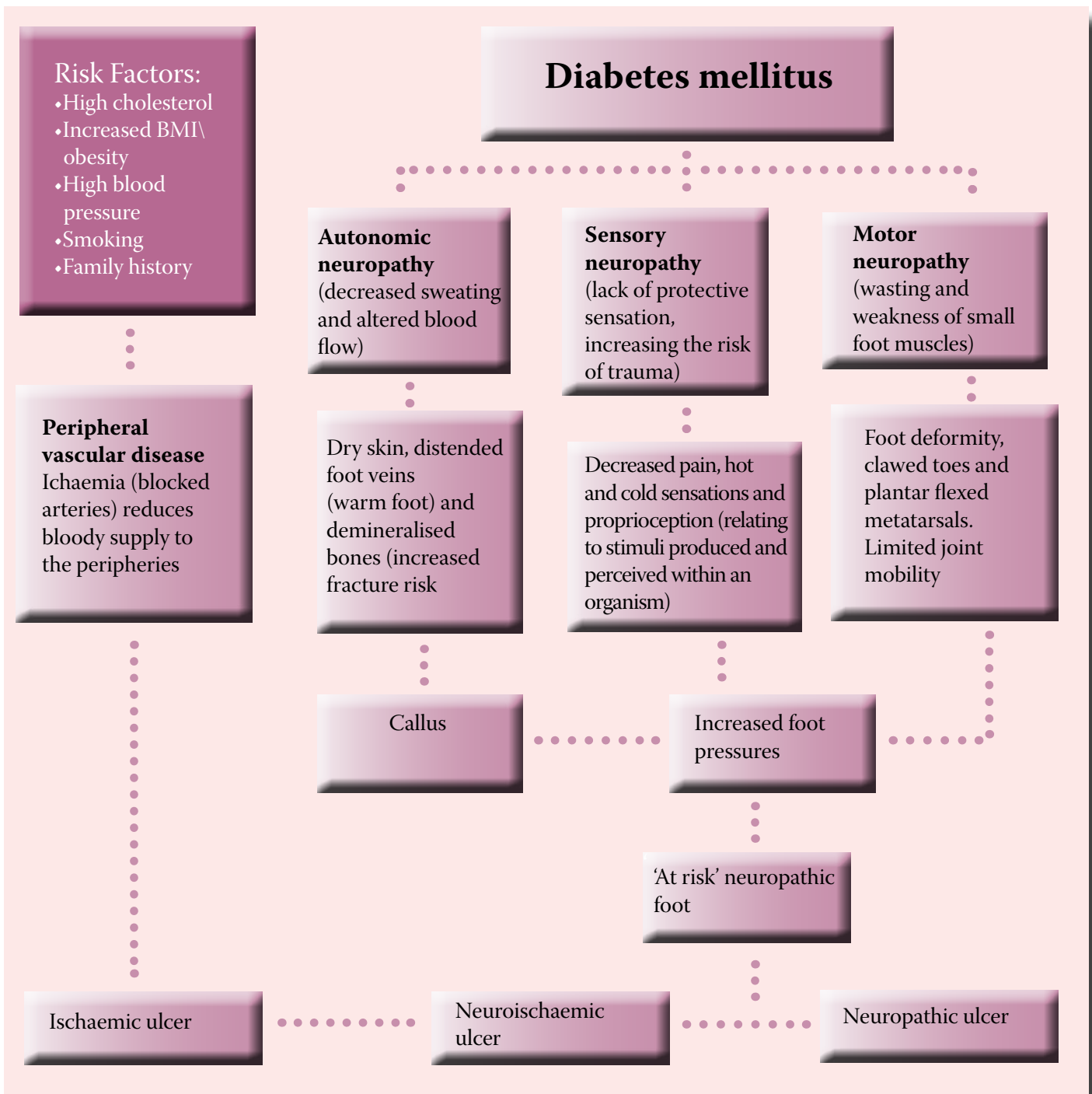


Figure 1.

### Causal pathway to diabetic foot ulceration.

loss) is a major cause of diabetic foot ulceration with as many as 45–60% of all diabetic ulcerations considered to be neuropathic (Frykberg et al, 2006). In the insensate foot, a number of factors increase the risk of ulceration, including ill-fitting/inappropriate footwear, inadvertent trauma and repetitive stress, particularly over weight-bearing areas of the foot (Figure 2).

#### Motor neuropathy

Structural changes/foot deformities are common in the diabetic foot mainly due to peripheral motor neuropathy (nerve dysfunction that gives rise to muscle weakness and muscular atrophy). Digital deformities, such as clawed toes, prominent metatarsal heads and pes cavus (high arch profile) are

commonly observed in the diabetic foot. Foot deformities are known to be causal factors in the pathogenesis of diabetic foot ulceration (Figure 1) (IDE, 2005).

#### Autonomic neuropathy

Autonomic neuropathy is a type of disease of the nerves mostly affecting the internal organs, such as the cardiovascular system. These nerves are not under a person's conscious control and function automatically

(autonomically). In the foot, autonomic neuropathy can lead to:

- ▶▶ Dry skin
- ▶▶ Fissures
- ▶▶ Callus
- ▶▶ Arteriovenous shunting (diversion of blood from an artery directly to a vein)
- ▶▶ Prominent dorsal veins
- ▶▶ Neuropathic oedema recalcitrant to diuretic therapy.

### Neuropathic ulceration

Individuals with peripheral neuropathy are at an increased risk of neuropathic foot ulceration. The features of neuropathic ulceration include:

- ▶▶ Ulceration with hyperkeratosed edges
- ▶▶ Usually painless
- ▶▶ Highly exudative and sloughy
- ▶▶ Irregular borders
- ▶▶ Surrounding skin may be macerated.

### Charcot's neuroarthropathy

Charcot's neuroarthropathy (see *Figure 3*) is usually associated with peripheral polyneuropathy, specifically autonomic and sensory changes. It is a progressive condition characterised by joint dislocation, fractures and severe destruction of the structure of the foot. Commonly, destructive changes are observed at the mid-foot or at the ankle. The patient may present with a 'rocker bottom' foot deformity. The rocker-bottom deformity is prone to increased pressure and ulceration (O'Loughlin, 2010).

### Peripheral vascular disease

Peripheral arterial disease rarely leads

to foot ulceration, but can significantly contribute to the chronicity of foot ulcers and increase infection and amputation risk in established diabetes-related foot ulcers (Frykberg et al, 2006). Arterial insufficiency is a pathogenic factor in up to 60% of diabetic patients with non-healing ulcers and in 46% of those undergoing amputation (O'Loughlin, 2010). Early aggressive treatment of lower extremity ischaemia is vital to prevent foot ulceration, necrosis, gangrene and lower extremity amputation.

### Ischaemic foot

The characteristic features of ischaemic ulceration (see *Figure 4*) include:

- ▶▶ Atrophic (thin) skin
- ▶▶ Anhydrotic (dry) skin
- ▶▶ Pale skin or in severe ischaemia an ischaemic rubor (red colour)
- ▶▶ Hair loss
- ▶▶ Cold/pulseless extremity
- ▶▶ Thickened toenails (onychauxis) or fungal toenails (onychomycosis)
- ▶▶ Loss of fibrofatty padding on the plantar aspect (sole) of the foot
- ▶▶ Ulcers develop on borders of feet, tips of toes, under thickened toenails or around the heels.

### Neuroischaemic foot

The presence of both peripheral neuropathy and peripheral arterial disease combined is commonly found in individuals with diabetes. In fact, it has been suggested that as many as 45% of people with DFU will present with elements of both arterial insufficiency and neuropathy, termed neuroischaemia (Baker et al, 2005).

The neuroischaemic limb is considered to be high risk for adverse outcomes, such as foot ulceration, necrosis and gangrene (NICE, 2004).

### Complications

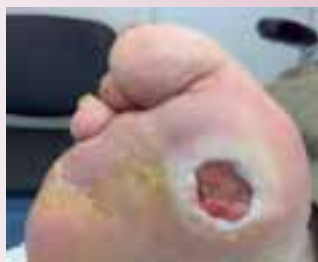#### Infection

The consequences of infection in DFU are devastating and can result in the end-stage complication of amputation (Ousey and McIntosh, 2008). Boulton et al (2008) have suggested that infected foot ulceration precedes about 60% of lower extremity amputation in diabetic patients. It is, therefore, imperative to be alert for signs of infection in treating the diabetic foot and if in doubt patients should be referred urgently to specialist foot care multidisciplinary teams (McIntosh and Newton, 2006).

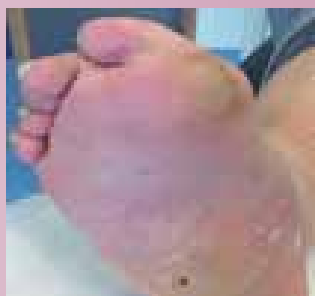#### Soft tissue infection

Clinical recognition of the signs of infection is important — pain or discomfort, swelling, warmth, and erythema can all indicate infection. However, diabetes-related complications of neuropathy and reduced arterial supply can frequently mask these signs and early recognition requires other criteria.

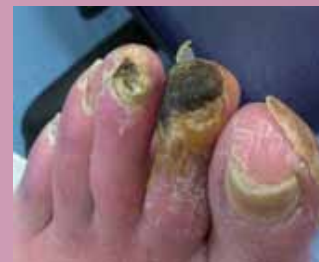McIntosh and Newton (2006) suggest additional signs, such as cellulitis, lymphangitis, purulent exudates and pus/abscess, to be synonymous with infection in the diabetic foot. Early management with intensive systemic antibiotic therapy is advised for non-healing progressive ulcers with signs of infection (NICE, 2004). To minimise the risk of contamination by surface



*Figure 2: A typical neuropathic DFU on a weight bearing area of the forefoot with macerated edges.*



*Figure 3: A Charcot foot with ulceration.*



*Figure 4: Ischaemic foot with ischaemic rubor (redness) and necrosis of second and third digits.*

pathogens, following debridement, a deep tissue swab should be taken for analysis with antibiotic therapy, amended according to results.

Bacterial burden is present in all ulceration, however, when this burden exceeds acceptable levels, and enters dermal and subcutaneous tissues, then infection ensues, further compounding the diabetic foot ulcer. Delayed wound healing in the neuroischaemic foot can rapidly give rise to spreading infection (cellulitis), which can progress to tissue death (necrosis) (McIntosh and Newton, 2006).

### *Osteomyelitis (bone infection)*

Bone infection in patients with DFU increases amputation risk eightfold (Boulton et al, 2008). When deep or extensive ulceration is overlying a bony prominence, or unresolving after six weeks when appropriate antibiotic therapy and off-loading have been adhered to, osteomyelitis should be investigated (*Figure 5*).

Unresolved local infection of soft tissue can spread by direct transfer from the infected cutaneous ulcer to underlying bone. Disruption of bone periosteum (the membrane that lines the outer surface of all bones) and/or joint capsules allows pathogenic bacteria to access the bone surface and/or joint cavity (Boulton et al, 2008).

If a sterile probe inserted into the wound reaches bone, osteomyelitis is indicated, with suspicions further intensified in 'sausage toe' presentations and unexplained high white blood cell count or inflammatory markers (Ousey and McIntosh, 2008). Diagnosis is confirmed with serial radiography (2–4 week intervals), with typical changes usually not apparent for 14 days indicating osteomyelitis. If X-rays prove inconclusive, then magnetic resonance imaging (MRI), nuclear medicine scans and/or bone biopsy should be considered (Boulton et al, 2008).

## *Treatment*

In terms of treatment, the prompt assessment and aggressive management of diabetic foot ulcers is imperative to reduce the risk of more serious complications.

*Figure 6* provides an overview of management strategies for DFU.

Initial investigations of the diabetic patient presenting with ulceration need to focus on the holistic assessment of the patient, taking into account their glycaemic control, vascular and neurological status, duration of disease, systemic wellness, including medical history and medication, and the patient's psychosocial state, which can impact the likelihood of concordance with treatment plans. Treatment should be guided by the findings from these investigations (Boulton et al, 2008).

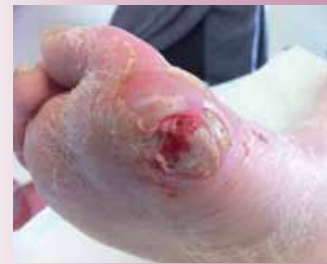### *Metabolic control — tight glycaemic control*

In the case of established foot ulcers, hyperglycaemia will impair wound healing and white blood cell function, thus increasing infection risk. Tight glycaemic control is, therefore, essential in preventing DFU and facilitating wound healing in established DFU. One important aspect in attaining good metabolic control is a balanced diet.

The recommended diet for patients with diabetes is high in fruit and vegetables and low in fat, sugar and salt (Diabetes UK, 2012), which additionally facilitates a good nutritional status, essential for wound healing, and assists in the management of dyslipidaemia. To improve healing, a referral to a dietician for dietary advice may be required.

### *Vascular control — controlling arterial risk factors*

Ousey and McIntosh (2008) suggest vascular control is staged via provision of pharmacological agents, lifestyle changes, such as quitting smoking, increased activity, revascularisation



*Figure 5: Diabetic ulceration with osteomyelitis in a neuroischaemic foot.*

and surgery. Urgent referral to the vascular team is imperative if the ulcerated limb presents in a vascular compromised state.

Ankle brachial pressure indices should be used to assess the status, with Marshall (2004) suggesting readings below 0.8 indicate some obstruction in the more proximal part of the artery to the lower limb and values below 0.5 indicating severe peripheral vascular disease. Revascularisation surgery may be required to restore the blood supply. Without an adequate blood supply, the nutrients and the amount of antibiotics and white blood cells delivered to the site of infection will be reduced, thus delaying healing and further compromising the limb.

### *Optimum wound care — debridement and dressings*

Winter (1962) produced a ground-breaking paper on wound healing. His finding that a moist wound bed is more conducive to wound healing, as epithelisation is retarded by dry scab and the underlying molecular and cellular abnormalities, is the evidence on which many wound bed preparations are still based today.

The acronym TIME is a systematic approach to optimising the local wound environment to facilitate wound management (Ousey and McIntosh, 2008). It stands for:

- ▶▶ **T**issue (viable and non-viable, necrotic and slough)
- ▶▶ **I**nfection/inflammation control
- ▶▶ **M**oisture (imbalance)



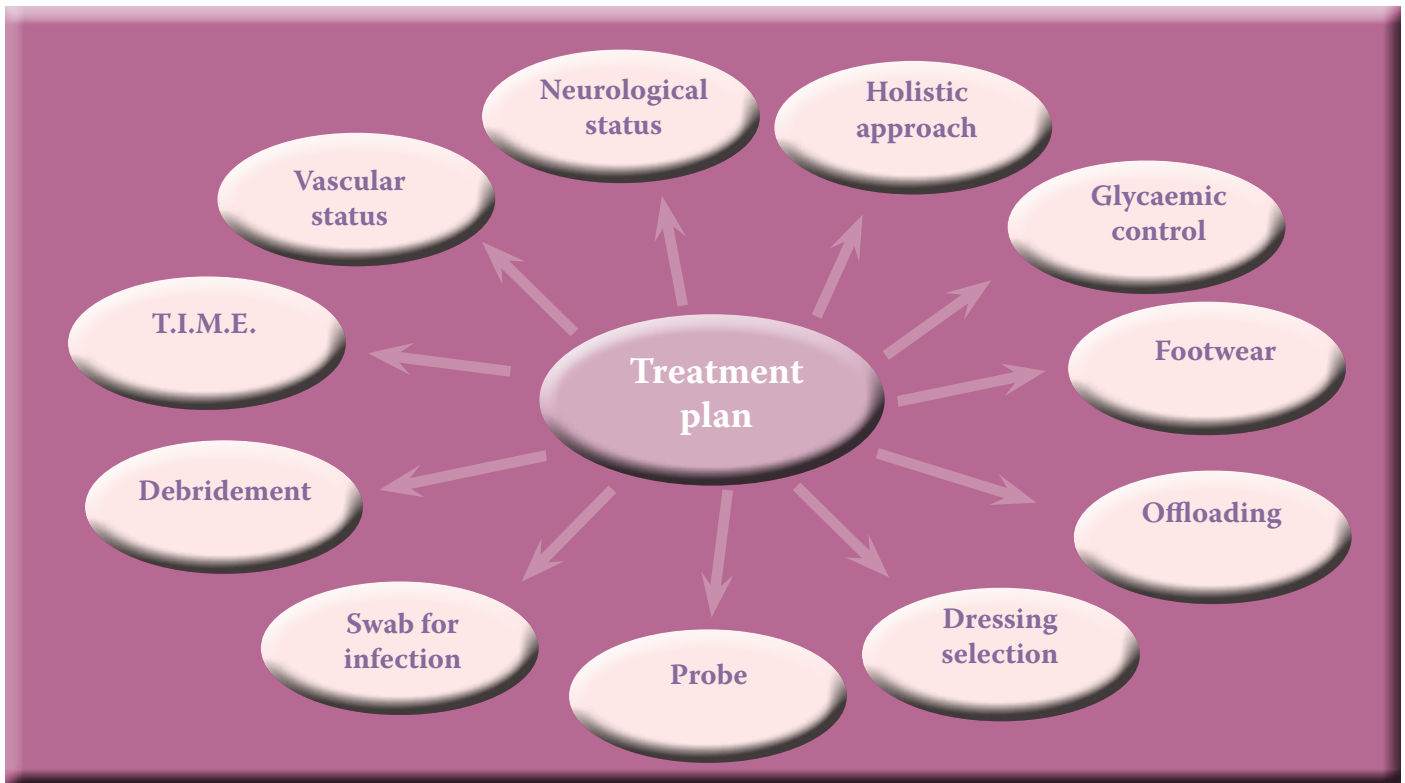


Figure 6.

### Overview of management strategies for DFU.

► **Edge** (epithelial advancement/ non-advancing or undermined).

Regular debridement of all hyperkeratotic, infected and nonviable tissue is advocated unless surgical revascularisation is required, where debridement may further traumatise compromised tissues (O' Loughlin, 2010). Dressings that create a moist wound healing environment are advised in order to assist healing, however, controlling exudate to maintain moisture balance must also be considered. Despite the plethora of dressings available, there is little evidence for the most appropriate dressing for DFU, therefore, selection should be based on the presenting wound (NICE, 2004).

Consideration should be given to the volume of exudate and the ability of the dressing to cope with these levels, the condition of the surrounding skin, bacterial burden, non-adherent properties and patient-related factors, such as footwear, mobility levels and the desire to bathe. Current trends

suggest the avoidance of antimicrobial dressings unless infection is present (Best Practice Statement, 2010).

#### *Mechanical control — offloading, footwear*

Elevated plantar pressures are common in the diabetic foot due to the effects of sensory, motor and autonomic neuropathy. These pressures can contribute to the development of DFU and in already ulcerated sites can delay wound healing and, therefore, need to be addressed. Podiatrists play a vital role in implementing offloading strategies to prevent such ulceration or eliminate pressures at the site of active ulceration, while keeping the patient mobile.

Boulton et al (2008) advise that this may be the single most important, albeit sometimes neglected, aspect, particularly in treating neuropathic ulceration.

Many offloading modalities exist with total contact casts (TCC) considered the 'gold standard' for healing DFUs — Boulton et al (2008) suggest TCCs

heal about 90% of foot ulcers without accompanying infection. However, TCC may not be appropriate in all instances, particularly in the presence of ischaemia and/or infection. Also patient agreement is often refused as TCCs afford an element of forced compliance and can be restrictive, heavy and cumbersome. In such instances, other modalities of offloading need to be considered (Ousey and McIntosh, 2008).

Removable cast walkers (RCW) and healing sandals are more readily acceptable to patients, although compliance is more difficult to monitor as patients can remove them. RCWs have produced comparable healing figures to TCC, according to Boulton et al (2008), and are relatively inexpensive with the benefit of easy removal for assessment and debridement of the ulcer. Patients are less restricted and can remove the RCW to bathe and sleep.

Several other removal devices are available, such as healing sandals, half-shoes, heel-wedged shoes, total contact insoles, simple insoles and felt padding, and all have their usefulness when appropriately prescribed. Additionally,

therapeutic footwear in conjunction with pressure-relieving insoles can be beneficial in the management of DFU. Whatever the offloading modality employed, it should be selected by taking a holistic patient approach and be tailored to meet individual needs.

### Education/empowerment — primary and secondary prevention

Patient involvement in the care plan and empowerment can encourage concordance and should be a consideration as it will increase the likelihood of successful resolution of the ulceration.

Figure 7 shows a new episode of ulceration that occurred when a male patient with a healed transmetatarsal amputation ignored footwear advice from his podiatrist. He was attending a wedding and insisted on wearing his new shoes, which led to a new episode of tissue breakdown.

Preventative measures that can be encouraged in the patient with diabetes include the patient checking their feet and footwear regularly and being observant for signs of redness on any areas of the foot. This could indicate areas of pressure from rubbing or foreign bodies within the shoes, which if left unaddressed could lead to tissue breakdown.

In addition, patient education on diet, exercise, smoking cessation and tight glycaemic control is imperative to lower the risk factors for long-

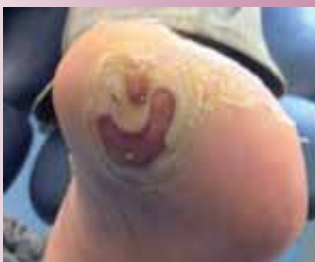

Figure 7: Diabetic foot ulceration, secondary to the wearing of new footwear.

term complications. This should be encouraged in patients with diabetes aiming to achieve self-management (McIntosh and Newton, 2006).

### Psychosocial elements

Diabetes mellitus is a chronic condition that can impact on almost every aspect of a person's life. Vileikyte (2001) reported a significant impact on quality of life associated with the loss of mobility linked to foot ulceration. Restriction on patients' ability to perform simple everyday tasks and participate in leisure activities, together with other consequences of foot ulceration, can lead to depression and poor quality of life. Vileikyte (2001) reports an increased incidence of depression in patients with foot ulcers and diabetes than in those with ulceration without diabetes.

### Conclusion

Treatment of patients with DFU needs to take a holistic approach, taking into account the patient's feelings associated with living with a chronic disease. Multidisciplinary management is of the utmost importance in managing foot ulcers, lowering the number of amputations and the financial cost, not to mention the detrimental effects on the patient with diabetic neuropathy and foot ulceration. **WE**

### References

- Best Practice Statement (2010) *The use of topical antiseptic/antimicrobial agents in wound management*. Wounds UK, Aberdeen.
- Boulton AJM, Cavanagh PR, Rayman G (2008) *The Foot in Diabetes* 4th Ed. John Wiley & Sons Ltd, West Sussex
- Diabetes UK (2012) Eating Well. Available at: [http://www.diabetes.org.uk/Guide-to-diabetes/Healthy\\_lifestyle/Eating\\_Well/](http://www.diabetes.org.uk/Guide-to-diabetes/Healthy_lifestyle/Eating_Well/) (Accessed on 11 June, 2012)
- Frykberg RG, Armstrong DG, Giurini J, Edwards A et al (2006) *Diabetic Foot Disorders: A Clinical Practice Guideline*. *J Foot Ankle Surg* 45(5): S1–60
- IDF Clinical Guidelines Task Force (2005) *Global Guidance for Type 2 diabetes*. International Diabetes Federation, Brussels
- Jeffcoate WJ, Price PE, Phillips CJ, Game FL et al (2009) Randomised controlled trial of the use of three dressing preparations in the management of chronic ulceration of the foot in diabetes. *Health Technol Assess* 13(54)
- Marshall C (2004) The ankle brachial pressure index. A critical appraisal. *Br J Podiatry* 7(4): 93–95
- McIntosh C, Newton V (2006) *Managing Diabetic Foot Ulcers: Best Practice*. *Wounds Essentials* 1:122–33
- NICE (2004) *Clinical guidelines for Type 2 diabetes: Prevention and management of foot problems, clinical guideline 10*, National Institute for Clinical Excellence
- O'Loughlin A, McIntosh C, Dinneen SF, O'Brien T (2010) Basic Concepts to Novel Therapies: A Review of the Diabetic Foot International. *J Lower Extremity Wounds* 9(2): 90–102
- Ousey K, McIntosh C (2008) *Lower Extremity Wounds A Problem-Based Learning Approach*. John Wiley & Sons Ltd, West Sussex 267–83
- Ribu L, Hanestad BR, Moum T, Birke-land K, Rustoen T (2007) Health-related quality of life among patients with diabetes and foot ulcers: association with demographic and clinical characteristics. *J Diabetes Complications* Jul-Aug;21(4): 227–36.
- Robbins JM, Strauss G, Aron D, Long J, Kuba J, Kaplan Y (2008) Mortality rates and diabetic foot ulcers: is it time to communicate mortality risk to patients with diabetic foot ulceration? *J Am Podiatr Med Assoc* 98: 489–93
- Vileikyte L (2001) Diabetic foot ulcers: a quality of life issue. *Diabetes/Metabolism Research and Reviews* 17(4): 246–49
- Winter GD (1962) Formation of the scab and rate of epithelisation of superficial wounds in the skin of the young domestic pig. *Nature* 193: 293–94