

# **CASE SERIES EVALUATION:**

Preserving skin integrity  
using the CliniMed range

**PUBLISHED BY:**

Wounds UK  
108 Cannon Street  
London EC4N 6EU, UK  
Tel: + 44 (0)20 3735 8244  
Email: info@omniamed.com  
www.wounds-uk.com

**Wounds** UK

© **Wounds UK 2020**

**Suggested citation:**

Callaghan R, Tickle J (2020)  
*Case series: Preserving skin integrity using the CliniMed range.* Wounds UK, London

Free download available from:  
www.wounds-uk.com

This document has been developed by Wounds UK and supported by an unrestricted educational grant from **CliniMed**.

**CliniMed**<sup>®</sup>

The views expressed are those of the authors and do not necessarily reflect those of **CliniMed**.

**FOREWORD**

The skin is a barrier to irritants and allergens, while also preventing water loss (Cowdell and Radley, 2012). Patients with compromised skin integrity are at increased risk of injuries such as pressure ulcers, moisture lesions, skin tears, and complications, such as infections, which can lead to pain, reduced mobility, poor quality of life, further health complications and increased healthcare costs (Moncrieff et al, 2013; Wounds UK, 2018).

Early recognition of people who are at risk of skin damage is an essential part of prevention. Determining those at risk also aids appropriate allocation of resources (LeBlanc et al, 2018).

The aim of this document is to inform practitioners of the potential benefits of using medical adhesive removal and barrier products for patients with compromised skin integrity. Evidence provided in this document suggests that certain products alongside a structured skin care regimen can preserve skin integrity and avoid injury.

**CONTRIBUTORS**

**Rosie Callaghan**, Tissue Viability Nurse, Worcestershire Health & Care NHS Trust, Worcestershire

**Joy Tickle**, Tissue Viability Specialist, Shropshire Community NHS Trust, Telford

All rights reserved ©2020. No reproduction, copy or transmission of this publication may be made without written permission.

No paragraph of this publication may be reproduced, copied or transmitted save with written permission or in accordance with the provisions of the Copyright, Designs and Patents Act 1988 or under the terms of any license permitting limited copying issued by the Copyright Licensing Agency, 90 Tottenham Court Road, London, W1P 0LP.

# Focus on medical adhesive-related skin injury (MARSI)

Medical adhesive-related skin injury (MARSI) occurs when superficial layers of skin are removed during the removal of medical adhesive products, such as dressings, ostomy pouches or tape, that have been used to affix catheters or electrodes. MARSI can occur within all care settings and by anyone using medical adhesive products.

The financial and nursing-time costs of MARSIs can be high; each MARSI requires an average of 7.8 treatments at a cost of £1.10–£7.90 per treatment (McNichol and Bianchi, 2016). The cost of MARSI to patients can also be considerable. Medical adhesive removal can be very painful and can impact on patient confidence with treatment. It can be so painful that patients are fearful of dressing change and require analgesia beforehand. Skin damage at dressing change also increases the risk of infection, delays wound healing and can increase wound size (McNichol and Bianchi, 2016).

## **Strategies for prevention**





Strategies to prevent MARSI and further skin damage include the use of low-adherent dressings, such as silicone foam dressings, and adhesive removal techniques. Adhesive products can be peeled back slowly at a low angle or the adhesive backing stretched to shear the adhesive from the skin; however, these techniques require some force for detachment (Taroc, 2017).

Medical adhesive removal products may also be beneficial. Silicone adhesive removal products, water and emollients can be used to aid adhesive removal and may reduce the need for pre-emptive analgesia at dressing change.

# Appeel® Sterile Medical Adhesive Remover

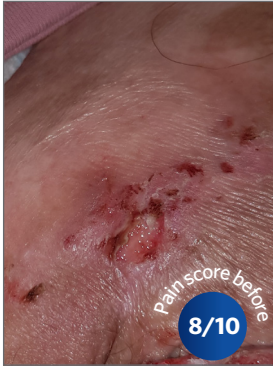**Appeel® Sterile Medical Adhesive Remover** is currently the only sterile silicone-based adhesive removal product that facilitates the removal of medical adhesives and is suitable for use on intact and broken skin. The alcohol free, no-sting formulation dries quickly on the skin. It has been shown to ease adhesive removal in a range of wounds, to reduce pain and trauma to the skin, and to reduce the frequency of dressing changes (Cooper, 2010; Reeve et al, 2016).

Appeel Sterile Medical Adhesive Remover is available as a single-use foam applicator, liquid sachet, wipe and a single-patient, multiple-use spray.

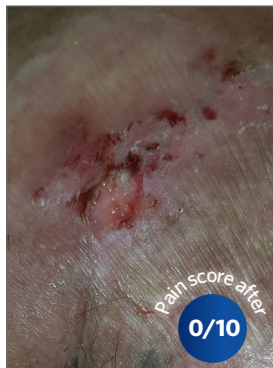<b>Sterile foam applicator</b> 	<b>Sterile liquid sachet</b> 	<b>Sterile wipe</b> 	<b>Sterile spray</b> 
<ul style="list-style-type: none"> <li>▶ Single-use application</li> <li>▶ Applicator allows for accurate application</li> <li>▶ Suitable for use on delicate skin.</li> </ul>	<ul style="list-style-type: none"> <li>▶ Patented, single-use delivery system</li> <li>▶ Suitable for large areas and dressings such as abdominal or spinal. Suitable for all care settings (Cooper et al, 2010).</li> </ul>	<ul style="list-style-type: none"> <li>▶ Individually packaged single-use application</li> <li>▶ Suitable for use on small adhesive tapes, dressings and around nasogastric tubes.</li> </ul>	<ul style="list-style-type: none"> <li>▶ Single-patient, multiple-use spray, which may be useful in the community</li> <li>▶ Bag-on-Valve technology means it can be sprayed at any angle with no cold sensation</li> <li>▶ Suitable for use at dressing change and urinary sheath removal.</li> </ul>

# Case 1: Female patient at high risk of pressure ulcer

Rosie Callaghan



**Figure 1** | Skin at the second dressing change using Appeel Sterile range



**Figure 2** | Skin after using Appeel Sterile range for 1 week

A 72-year-old nursing home resident sustained a moisture lesion to her right buttock. The patient is susceptible to moisture lesions, which often develop into pressure ulcers. Therefore, it was imperative to take care of the surrounding, fragile skin to avoid further deterioration.

The patient was often very worried at dressing removal as in the past she had experienced skin stripping and extreme pain (8/10 on the visual analogue scale [VAS]; 0=no pain; 10=unbearable pain). So Appeel Sterile Medical Adhesive Remover was selected to help remove the dressing and avoid further damage.

The Appeel Sterile Medical Adhesive Remove spray and liquid sachet were used to examine both products on separate occasions over the 2 weeks. Both were easy to use, and lifted the dressing with no resistance or pain to the patient. The wound was cleansed with saline and a conformable foam dressing was applied.

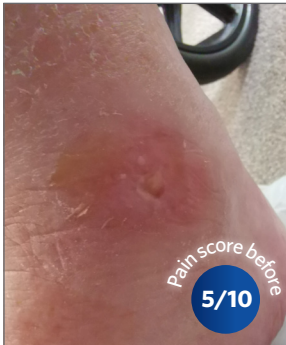## Outcomes after 2 weeks

The use of the Appeel Sterile Medical Adhesive Remover at each dressing change for 2 weeks helped to avoid skin stripping and distress at dressing change for this patient with very fragile skin who was at risk of pressure ulceration. Dressing change became less painful, reducing completely by 2 weeks (0/10 on the VAS), which improved the patient's treatment experience.

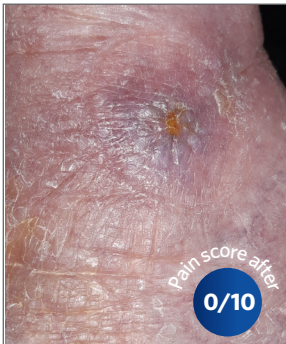This experience prompted a review and changes to the long-term management of this patient — it should be documented in the care plan when patients require an adhesive remover to facilitate pain-free, trauma-free dressing removal.

## Case 2: Sloughy and saturated wound

Rosie Callaghan



**Figure 1** | Start of treatment using Appeel Sterile Medical Adhesive Remover



**Figure 2** | End of treatment

An 84-year-old nursing home resident developed a wound on her left ankle, measuring 1cm (length) x 1cm (width). The patient had a history of diabetes and oedema, and her mobility was reduced. The surrounding skin was macerated, dry and flaky; therefore, it was crucial for the clinician to avoid further damage to the periwound skin.

The patient would often feel anxious before dressing change as a result of the distressing levels of pain experienced (5/10 on the [VAS]; 0=no pain; 10=unbearable pain).

Appeel Sterile Medical Adhesive Remover spray was used to ease dressing removal. The wound was cleansed with saline and an alginate dressing was applied to help debride, along with a secondary absorbent antimicrobial dressing to control exudate levels.

### Outcomes after 2 weeks

The Appeel Sterile Medical Adhesive Remover spray helped to minimise trauma to the skin during dressing removal; it was easy to use, and the patient no longer experienced any pain or felt anxious or apprehensive before each dressing change. During this experience, both clinician and patient were highly satisfied with the use of Appeel Sterile Medical Adhesive Remover and felt it had improved the patient's quality of life.

# Focus on moisture-associated skin damage

The term 'moisture-associated skin damage' (MASD) covers a range of skin problems that occur due to prolonged exposure to wound exudate, faeces and/or urine and perspiration (Dowsett and Allen, 2013). MASD is an umbrella term of four conditions (Gray et al, 2011; Beekman et al, 2017; Young, 2017):

- ▶ Incontinence-associated dermatitis (IAD) ➔ caused by urine and faeces
- ▶ Intertriginous dermatitis (ITD) ➔ caused by perspiration
- ▶ Peristomal moisture-associated dermatitis ➔ caused by effluent from the stoma
- ▶ Periwound moisture-associated dermatitis ➔ caused by wound exudate on the skin surrounding the wound.

The global prevalence of MASD is not accurately known, with figures varying greatly between clinical settings and geographical locations (Gray et al 2011; Beekman et al, 2017).

## Strategies for prevention





Adopting a structured skin care regimen that involves cleansing, protecting and restoring the barrier properties of the skin will assist in the prevention and management of all MASD (Young, 2017). It is important to review medications that may directly affect skin (e.g. topical and systemic steroids) and to implement an individualised skin care plan using a skin-friendly cleanser (not traditional soap) and warm, not hot, water (Dowsett and Allen, 2013). Barrier creams and films should be considered as part of the skin care plan.

<b>Ideal barrier cream (Beekman et al, 2015)</b>	<b>Ideal barrier film (NHS Business Services Authority, 2017)</b>
<ul style="list-style-type: none"><li>▶ Durable</li><li>▶ Easy to apply</li><li>▶ Non-sting</li><li>▶ Gentle to the skin</li><li>▶ Should not interfere with the absorption or function of incontinence management products</li><li>▶ Should have a rapid absorption and drying time so that it does not impact on the time required to administer the skin care regimen and additional treatments</li><li>▶ Should minimise the number of products, resources and time required to complete a comprehensive skin care regimen so that it is cost-effective.</li></ul>	<ul style="list-style-type: none"><li>▶ The product dries and is odourless 30 seconds after application</li><li>▶ Clear on the skin</li><li>▶ Does not leave a tacky residue on the skin when dry</li><li>▶ Can be applied to the skin at diverse angles from a pump action or aerosol container</li><li>▶ Should be suitable for application to paediatric skin</li><li>▶ Does not prevent successful application of adhesive dressings to the skin.</li></ul>

# LBF® Sterile Barrier Film Range and LBF® Barrier Cream

The **LBF® Sterile Barrier Film Range** is a sterile silicone-based product that forms a fast-drying, transparent protective film. It can be used on broken or infected skin, as well as intact skin around periwound sites to provide an effective, breathable barrier for intact skin from bodily fluids, for example faeces, urine, digestive enzymes and wound exudate. It may also be beneficial to protect this skin from adhesives and friction. LBF Sterile Barrier Film is available in three different formulations — spray, foam applicator and wipe.

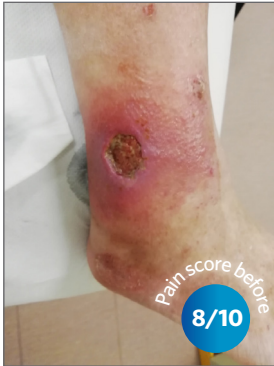The **LBF® Barrier Cream** is formulated to provide an effective breathable barrier for intact skin from bodily fluids. It moisturises the skin and helps to maintain skin integrity. It does not affect the absorbency of incontinence pads (Fleming et al, 2014) or the adhesion of dressings or adhesive appliances. It is indicated to protect skin that is at risk or likely to be compromised. It should not be used on broken or infected skin.

LBF® Sterile Barrier Film Range			LBF® Barrier Cream
Sterile Spray	Sterile Foam applicator	Sterile Wipe	
 <ul style="list-style-type: none"> <li>▶ 360° dispensing with uniform spray pattern</li> <li>▶ No sting or cold sensation when applied</li> <li>▶ Suitable for use on sore and delicate skin.</li> </ul>	 <ul style="list-style-type: none"> <li>▶ Single-use application</li> <li>▶ Applicator allows for accurate application</li> <li>▶ Suitable for suprapubic catheters, tracheostomy sites and for periwound protection.</li> </ul>	 <ul style="list-style-type: none"> <li>▶ Individually packaged single-use application</li> <li>▶ Suitable for use on small tapes, dressings and for periwound protection.</li> </ul>	 <ul style="list-style-type: none"> <li>▶ Highly concentrated</li> <li>▶ Latex and fragrance free</li> <li>▶ Suitable for use on fragile skin</li> <li>▶ Available in different sizes (2g, 30g, and 100g).</li> </ul>

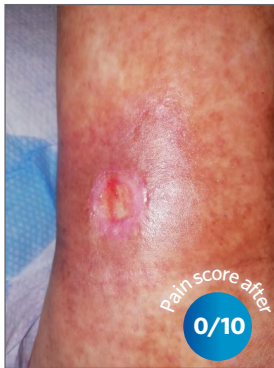

# Case 3: Heavily exuding infected spider's bite

Joy Tickle



**Figure 1** | Start of treatment



**Figure 2** | 4 weeks later

A 71-year-old man was bitten by a spider while travelling in Indonesia, which had been present for 9 months. The skin was very painful (8/10 on the visual analogue scale [VAS]; 0=no pain; 10=unbearable pain) and the surrounding skin was moderately itchy and inflamed. There were signs of wound infection, and presence of periwound erythema, skin damage and excoriation caused by exudate; the periwound skin required protection to prevent further skin damage and increasing wound size.

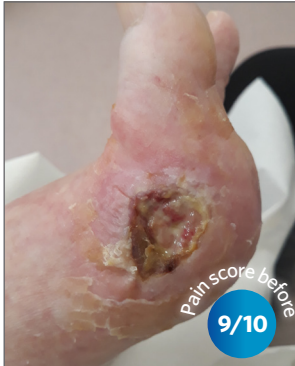The wound was cleansed with an irrigation solution (octenidine and ethylhexylglycerin) or saline. The LBF Sterile Barrier Film Range was used to apply a transparent film to the periwound skin. The LBF Sterile Barrier Film Foam applicator was used on the periwound skin first and as the wound progressed to healing, the LBF Sterile Barrier Film Spray was used. An absorbent cellulose gelling dressing was used to absorb and manage the exudate — the underlying cause of the skin damage. An adhesive silicone foam was used as a secondary dressing, and compression hosiery was applied.

## Outcomes after 2 weeks

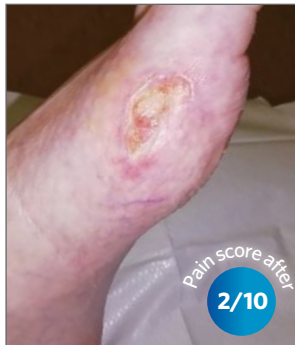The LBF Sterile Barrier Film Spray and Foam applicator were used to protect the fragile and painful periwound skin. As the barrier film is sterile, it was appropriate to use on this infected area. The patient found the LBF Sterile Barrier Film Range to be quick drying, not tacky on the skin, easy-to-use and painless when applied. It met the periwound skin management objectives for this patient and, over time, fewer absorbent dressings were required as the underlying infection resolved. Additionally, for patients with an infected wound it was found to be pertinent to use a sterile barrier film.

## Case 4: Macerated periwound skin

Joy Tickle



**Figure 1** | Before treatment



**Figure 2** | After 2 weeks

A 62-year-old female patient had a trauma wound to her foot that had been present for 8 months without progress. She had peripheral vascular disease and was on immunosuppressive medication, which was thought to be impacting on wound healing. The wound itself was very painful (9/10 on the visual analogue scale [VAS]; 0=no pain; 10=unbearable pain) and moderately exuding, as such the periwound skin was macerated and at risk of further breakdown.

A barrier cream had been used previously, but it had been ineffective at protecting the periwound skin as it had continued to deteriorate. Therefore, the LBF Sterile Barrier Film Foam applicator was selected to precisely apply a transparent, water-resistant barrier film to protect the periwound skin from the wound exudate and reduce further skin breakdown.

The wound was cleansed with saline and dried, before the LBF Sterile Barrier Film was applied. It was very easy-to-use and extremely quick-drying and non-tacky on the skin. An adhesive foam dressing was used to cover the wound.

### Outcomes after 2 weeks

After 1 week, the macerated skin had healed, and the patient's pain had reduced considerably (2/10 on the VAS). Using the LBF Sterile Barrier Film Foam applicator at each dressing change was accepted by the patient and after 2 weeks' use the periwound skin was healthy and intact.

# Summary

Preserving skin integrity is an important part of wound management. Using medical adhesive removers, such as **Appeel® Sterile Medical Adhesive Remover** and barrier films and barrier creams, such as **LBF® Sterile Barrier Film Range** and **LBF® Barrier Cream**, as part of a holistic treatment plan can be beneficial to reduce patient pain, distress and further wound deterioration as shown in the presented patient cases. For patients with an infected wound, a sterile barrier film, such as **Appeel® Sterile Medical Adhesive Remover**, would be pertinent to use. These sterile products are easy-to-use so can be used by patients to engage with self-care at home, thereby empowering the patient and freeing up clinical resources.

## References

- Beeckman D, Campbell J, Campbell K et al (2015) *Proceedings of the Global IAD Expert Panel. Incontinence-associated dermatitis: moving prevention forward*. Wounds International. Available from [www.woundsinternational.com](http://www.woundsinternational.com)
- Beeckman D (2017) A decade of research on Incontinence-Associated Dermatitis (IAD): Evidence, knowledge gaps and next steps. *J Tissue Viability* 26(1): 47–56
- Cooper P (2010) Appeel® Sterile sachet: helps remove pain from a dressing change. *Wounds UK* 6(2): 100–6
- Cowdell F, Radley K (2012) Maintaining skin health in older people. *Nursing Times* 108(49): 16–20
- Dowsett D, Allen L (2013) Moisture associated skin damage made easy. *Wounds UK* 9(4). Available from: [www.wounds-uk.com/made-easy](http://www.wounds-uk.com/made-easy)
- Fleming L, Zala K, Ousey K (2014) Investigating the absorbency effects of LBF barrier cream. *Wounds UK* 10(2): 24–30
- Gray M, Black JM, Baharestani MM et al (2011) Moisture-associated skin damage: overview and pathophysiology. *J Wound Ostomy Continence Nurs* 38(3): 233–41
- LeBlanc K, Campbell K, Beeckman D et al (2018) *Best practice recommendations for the prevention and management of skin tears in aged skin*. London: Wounds International. Available from [www.woundsinternational.com](http://www.woundsinternational.com)
- McNichol L, Bianchi J (2016) *Medical adhesive-related skin injuries (MARSI) Made Easy*. London: Wounds UK. Available from [www.wounds-uk.com](http://www.wounds-uk.com)
- Moncrieff G, Cork M, Lawton S et al (2013) Use of emollients in dry skin conditions: consensus statement. *Clin Experimental Dermatol* 38(3):231-8
- NHS Clinical Evaluations Team (2017) *Clinical review: skin barrier film*. NHS Business Services Authority, London. Available from <https://www.nhs.uk/sites/default/files/2017-11/Skin%20Barrier%20Films%20-%20Final%20%20Report%20%28V1.2%29%2011.2017.pdf> (accessed 19.12.19)
- Reevell G, Anders T, Morgan T (2016) Improving patients' experience of dressing removal in practice. *J Comm Nurs* 30(5): 44–9
- Taroc AM (2017) A guide for adhesive removal: principles, practice, and products. *American Nurse Today* 12(10)
- Wounds UK (2018) *Best Practice Statement Maintaining skin integrity*. London: Wounds UK. Available from [www.wounds-uk.com](http://www.wounds-uk.com)
- Young T (2017) Back to basics: understanding moisture-associated skin damage. *Wounds UK* 13(4): 56–65

PID 8364

