

The treatment of 3 category 4 pressure ulcers using a gelling-fibre dressing with silver nanoparticles and monofilament fibre debridement

Pippa Heath | Tissue Viability Specialist | East Suffolk and North Essex NHS Foundation Trust

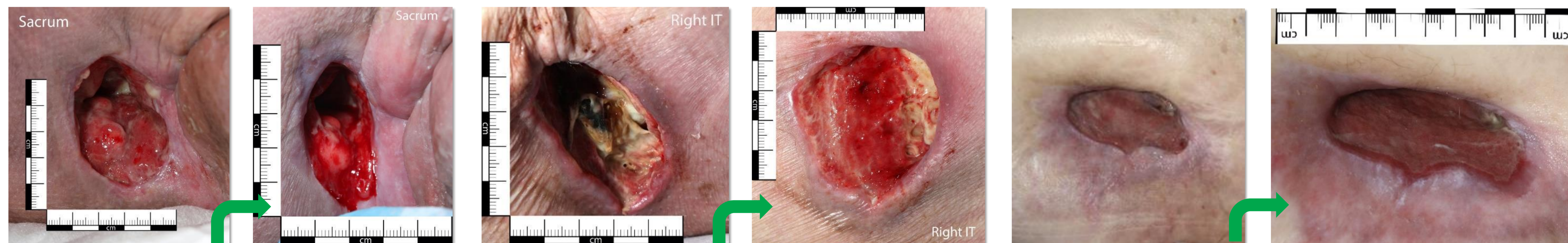
Introduction: Pressure ulcers rank among the "top ten harms" within the NHS in England. Research into the origins of pressure ulcers often reveals that deviations from established evidence-based practice play a significant role in their occurrence (Fletcher 2022). The NICE clinical guideline regarding pressure ulcers indicates that every patient may be at risk of developing a pressure ulcer. Consequently, all healthcare professionals interacting with patients should evaluate the risk of pressure ulcers during each encounter (NICE 2014). The risk of infection is also a critical concern in the management of pressure ulcers. When these ulcers develop, they can create open wounds that serve as entry points for pathogens, leading to local and systemic infection. This poster presents a case series involving three patients and investigates the efficacy of an innovative silver nanoparticle-infused gelling-fibre dressing, **Suprasorb Liquacel Ag**, in combination with mechanical debridement using monofilament fibre technology, **Debrisoft**, for the treatment of category 4 pressure ulcers. The objective of the poster is to highlight this evidence-based approach to wound healing, infection control and its contribution to overall patient care.

Method: This case series examines three medical scenarios involving multiple category 4 pressure ulcers in diverse anatomical locations, including the greater trochanter, sacrum, and perineum. The patients, aged 56, 62, and 65, presented with complex comorbidities such as multiple sclerosis and paraplegia. All three patients were admitted to secondary care following referrals from healthcare professionals. The primary concern was infection, with one patient exhibiting symptoms suggestive of sepsis. Upon admission, Wound swabs were collected from all patients and Magnetic Resonance Imaging (MRI) scans were scheduled. The diagnostic procedures revealed multiple bacterial cultures were present in the wounds of two patients and osteomyelitis was confirmed in all three cases. Upon physical examination, two patients' wounds were probed to bone, suggesting deep tissue involvement and potential bone exposure. All wounds exhibited complex presentations with varying tissue types being observed. A combination of slough and granulating tissue was present with low to moderate levels of exudate noted. Alongside treatment for osteomyelitis, the wound beds were first debrided using either a **Debrisoft** pad or Lolly. **Suprasorb Liquacel Ag**, a gelling fibre dressing infused with silver nanoparticles was applied as part of a comprehensive pressure ulcer treatment protocol. This advanced dressing was selected to efficiently regulate moisture levels within the wound environment, mitigate the risk of local infection through the antimicrobial properties of silver and promote optimal conditions for wound healing.

Discussion: Managing pressure ulcers presents significant challenges, primarily due to the complexity of patient needs and the multifactorial nature of ulcer development. Key factors contributing to pressure ulcer formation include impaired mobility, poor nutrition, moisture, and inadequate blood flow to the skin. Despite being largely preventable, pressure ulcers continue to occur frequently in healthcare settings, often exacerbated by the presence of comorbidities in patients and a lack of consistent training for caregivers on prevention strategies. Infected pressure ulcers can complicate treatment, prolong healing times, and increase healthcare costs significantly.

Case Study Example: A 56-year-old paraplegic male was admitted on July 26th 2024, with multiple medical issues including an infected pressure ulcer on the right ischial tuberosity/perineum area, acute osteomyelitis of the 5th metatarsal bilaterally, and a hydrocele. Upon initial assessment by the Tissue Viability Nurse (TVN), the right ischial tuberosity wound measured 5x5cm and 8cm deep with exposed bone. The wound bed presented with granulating wound bed with macerated edges and blood-stained exudate. Treatment was initiated with Aquacel Ag+ Extra and Mepilex border dressings. On August 1, 2024, the wound had increased slightly in size to 6x3.5cm and 6cm deep, with 9.5cm tracking. Bone remained palpable with moderate exudate. An MRI on August 6th confirmed osteomyelitis of the right ischial tuberosity and Intravenous antibiotics (Tazocin) were started on August 7th. A trial of **Suprasorb Liquacel Ag** was initiated on August 14th and concluded on September 3. Throughout the admission, wound swabs remained negative for infection.

The patient's hydrocele persisted, necessitating the use of incontinence pads instead of his usual convene catheter, which occasionally led to dressing contamination. The patient responded well to osteomyelitis treatment and wound care. The pressure ulcer showed significant improvement, with tracking depth reduced by almost half since admission. The combination of appropriate dressings, antibiotic therapy, and regular wound assessments contributed to the positive outcome.



Case Study 1

Case Study 2

Case Study 3

Results: The treatment of three patients with category 4 pressure ulcers using a combination of monofilament fibre debridement and a gelling-fibre dressing infused with silver nanoparticles resulted in positive outcomes. After two weeks of treatment, all three patients showed improvements in wound bed preparation, with a notable reduction in devitalised tissue. Signs of infection, including erythema, exudate, and malodour, decreased in all cases. The dressing demonstrated excellent moisture management capabilities, effectively absorbing excess exudate while maintaining an optimal moist environment for healing. Additionally, the periwound skin condition improved in all cases, with reduced maceration and irritation. These results suggest that the silver nanoparticle-infused gelling-fibre dressing is an effective option for managing complex category 4 pressure ulcers, promoting wound bed preparation, controlling infection, balancing moisture, and accelerating the healing process.

Conclusion: This evaluation of three patients with category 4 pressure ulcers showed promising results when using the innovative gelling-fibre dressing infused with silver nanoparticles (**Suprasorb Liquacel Ag**), in combination with effective debridement using monofilament fibre technology (**Debrisoft**) over a two-week period. The dressings demonstrated effective wound management by maintaining a moist healing environment while simultaneously providing antimicrobial protection. While larger studies are needed to confirm these findings, this initial evaluation suggests that this silver nanoparticle-infused gelling-fibre dressing may be a valuable addition to comprehensive pressure ulcer treatment protocols. This case series also highlights the complexity of managing patients with multiple comorbidities and the importance of thorough diagnostic procedures in identifying underlying complications such as osteomyelitis in pressure ulcer cases.

References: 1. Fletcher, J. National Wound Care Strategy update: Pressure ulcer prevention and the PSIRF exemplar. 2022, Vol. 18, 4.
2. National Institute of Clinical Excellence. Pressure ulcer prevention and management: Clinical Guideline. CG 179.