

Background: Chronic leg ulcers greatly impact patients' quality of life with a significant cost to healthcare. Fish skin is thought to have properties that aid in wound healing with low risk of disease transmission. Kerecis provides fish skin that is already sterilized.

Aims: To assess the effects of Kerecis FSG (fish skin graft) use on the rate of healing over three weeks as a percentage area reduction (PAR) in patients with chronic leg wounds which have remained unhealed over four weeks as a primary outcome.

Hypothesis: We hypothesized the properties of the fish skin to aid in faster wound closure and improved healing.

Methods: 18 Patients and 20 chronic leg wounds that remained unhealed for at least four weeks had Kerecis FSG (fish skin graft) applied to their wound and were assessed weekly for a period of three weeks or until complete healing of their wound. Wound sizes were assessed for four weeks before the trial, during the trial and for four weeks after the trial. The daily percentage area reduction (PAR) was calculated.

Results: 18 patients completed the trial and 20 wounds were assessed. All patients saw a reduction in wound size during trial with FSG (fish skin graft). The use of FSG (fish skin graft) resulted in a PAR reduction of 40.92% in the three-week trial period with 30% of patients with complete healing.

Conclusion: The use of FSG (fish skin graft) lead to significantly enhanced wound healing witnessed as a result of greater PAR (percentage area reduction) in wound size with the application of FSG (fish skin graft) and rates of complete healing in patients with chronic unhealed leg ulcers.

Keywords: Chronic leg ulcers, FSG (fish skin graft), PAR (percentage area reduction), Kerecis

Properties of fish skin

- Fish skin is abundant in collagen, omega-3 unsaturated fatty acids, EPA, DHA, elastin, laminin and glycoproteins¹
- In studies collagen has demonstrated low immunogenicity, ability to provide stability and strength as well as being biodegradable and biocompatible¹
- EPA, DHA and the omega-3 unsaturated fatty acids in fish skin help to reduce inflammation and promote wound healing by reducing inflammatory reactions and increasing pro-inflammatory cytokines¹
- Fish is skin is much easier to process with much lower risk of disease transmission in comparison to other sources such as bovine making it a much more economical process¹

Sterilization of fish skin

- Ibrahim et al. compared the sterilization of fish skin with 3 different sterilization agents namely chlorhexidine gluconate 4% (CHG), povidone iodine 10% (PVP-I), and silver nanoparticles (AgNPs) to compare microbial count as well as histological effect and effects on collagen property²
- Their study found silver nanoparticles had a 100% reduction in microbial growth in the treated times whilst simultaneously not impairing cellular function or collagen content like the other 2 agents²
- Another study sought to sterilize the fish by lyophilization (freeze drying) and then treating with gamma irradiation and various lengths concluded 10KGy to be the most appropriate in preserving the fish skin³

Fish species utilized

- Wild Atlantic (right) cod has been previously utilized and the species utilized by Kerecis
- Nile tilapia (left) has also been utilized, however, no commercial products utilizing Nile tilapia as a xenograft are currently available



Figure 1: Image taken from Nile Tilapia - Profile | Diet | Growth | Farming | Aquaculture - SeaFish (seafishpool.com). Image taken from Profiling the Atlantic Cod - The Fisherman

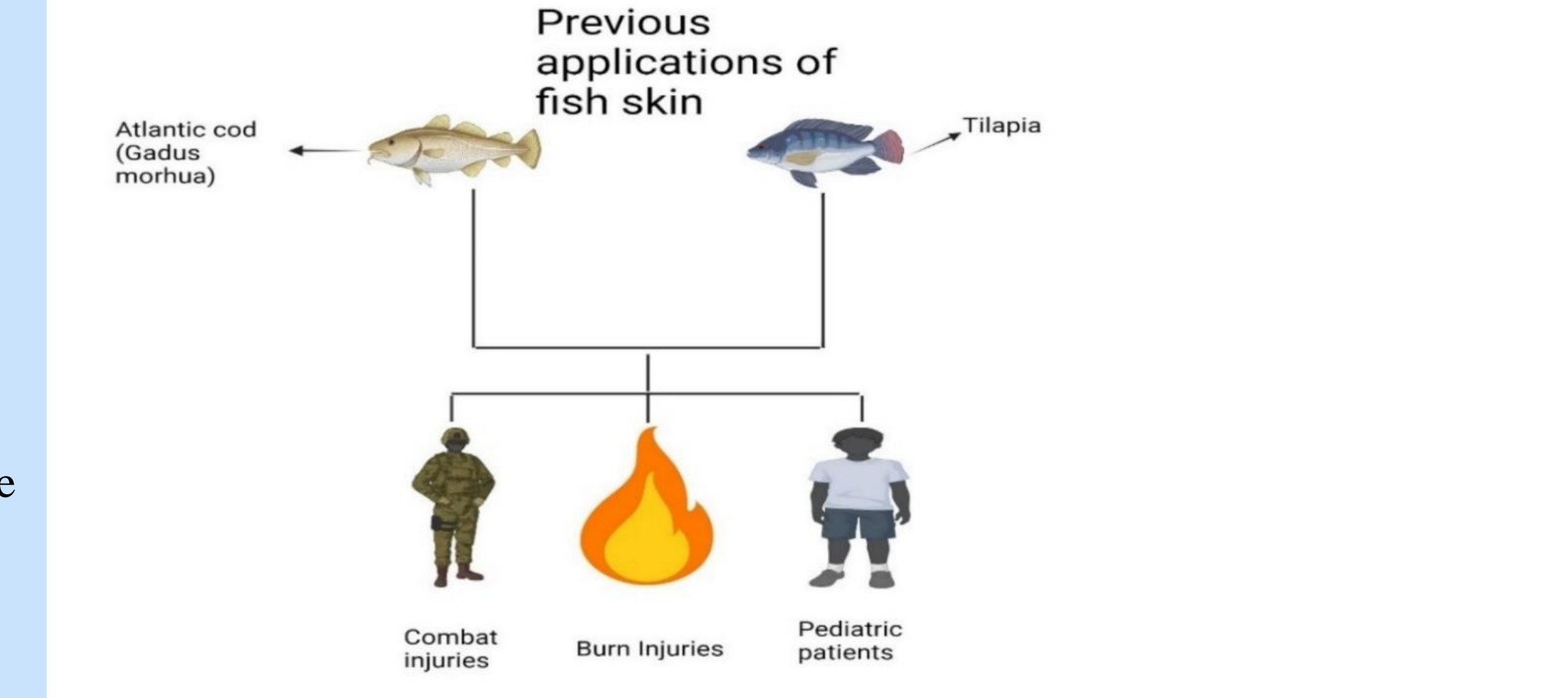


Figure 2: Previous applications of fish skin. Information sourced from reference (4-6). Image created with BioRender.com

Chronic unhealed leg ulcers

- Leg ulcers are those ulcers which remain unhealed after 12 weeks^{7,8}
- Mostly venous leg ulcers^{9,10}
- According to one study looking at records from 2007-2017 the cost of treating venous leg ulcers (VLUs) made up for 1.2% of the annual budget for the Welsh NHS¹¹
- Extrapolated to the UK population this represents a cost of over 2 billion pounds annually¹¹
- In the UK the cost of treatment and amputation of diabetic foot ulcers was estimated to be between £837 million and £962 million as far back as 2014-2015 taking up almost 1% of the annual NHS budget¹²

Impact of chronic leg ulcers

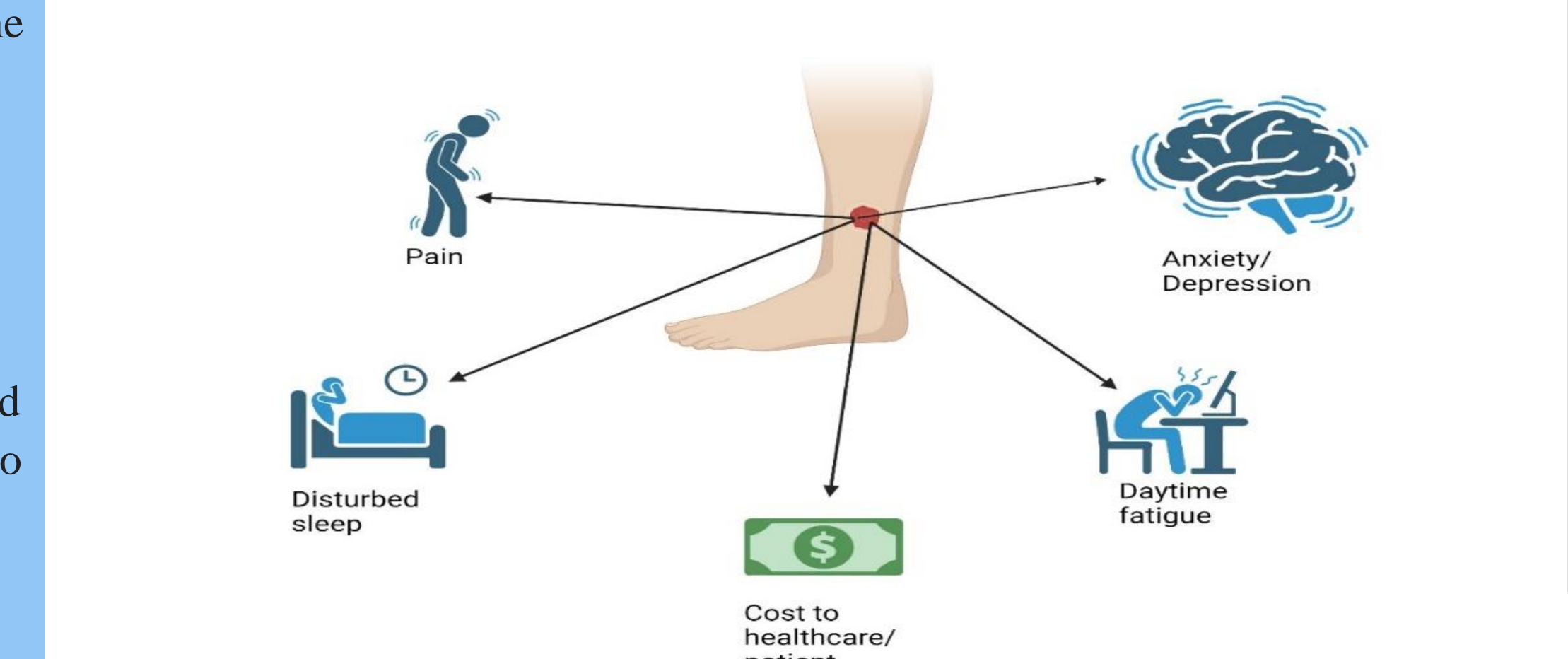


Figure 3: Impact of chronic unhealed leg wounds, (Information sourced from reference 12-15). Created with BioRender.com

Aims:

- Study the wound healing effects of FSG over 3 weeks in patients with unhealed leg ulcers
- The primary outcome I wanted to assess was percentage area reduction (PAR) during pre-trial to post-trial period which was to be calculated by taking weekly wound measurements
- Secondary outcomes were total percentage reduction of wound size, week to week reduction in wound size, number of patients that healed completely, patients who witnessed an increase in wound size or no decrease were also calculated and assessed as well as rates of complication and adverse reactions
- I hypothesized that the unique properties of fish skin to aid in more rapid wound healing

Methods

- 18 patients and 20 wounds that had remained unhealed after a minimum of four weeks were selected for this self-control evaluation for 3 weeks of treatment with Kerecis fish skin graft
- Patients who had no allergies to fish skin, were not undergoing another trial, had appropriate wound size and did not have excessively inflamed wounds formed part of the inclusion and exclusion criteria
- Wounds were measured weekly in order to calculate the percentage area reduction (PAR) during pre-trial, trial and post-trial period
- Use of fish skin graft resulted in a percentage area reduction (PAR) of 49.96% in the trial period. This was more than double the reduction seen in the pre-trial period.
- 30% of wounds healed completely whilst 30% saw an increase in wound size or no further reduction with 2 patients from this group having no reduction in size.
- No adverse reactions and complications were noted with the use of Kerecis fish skin

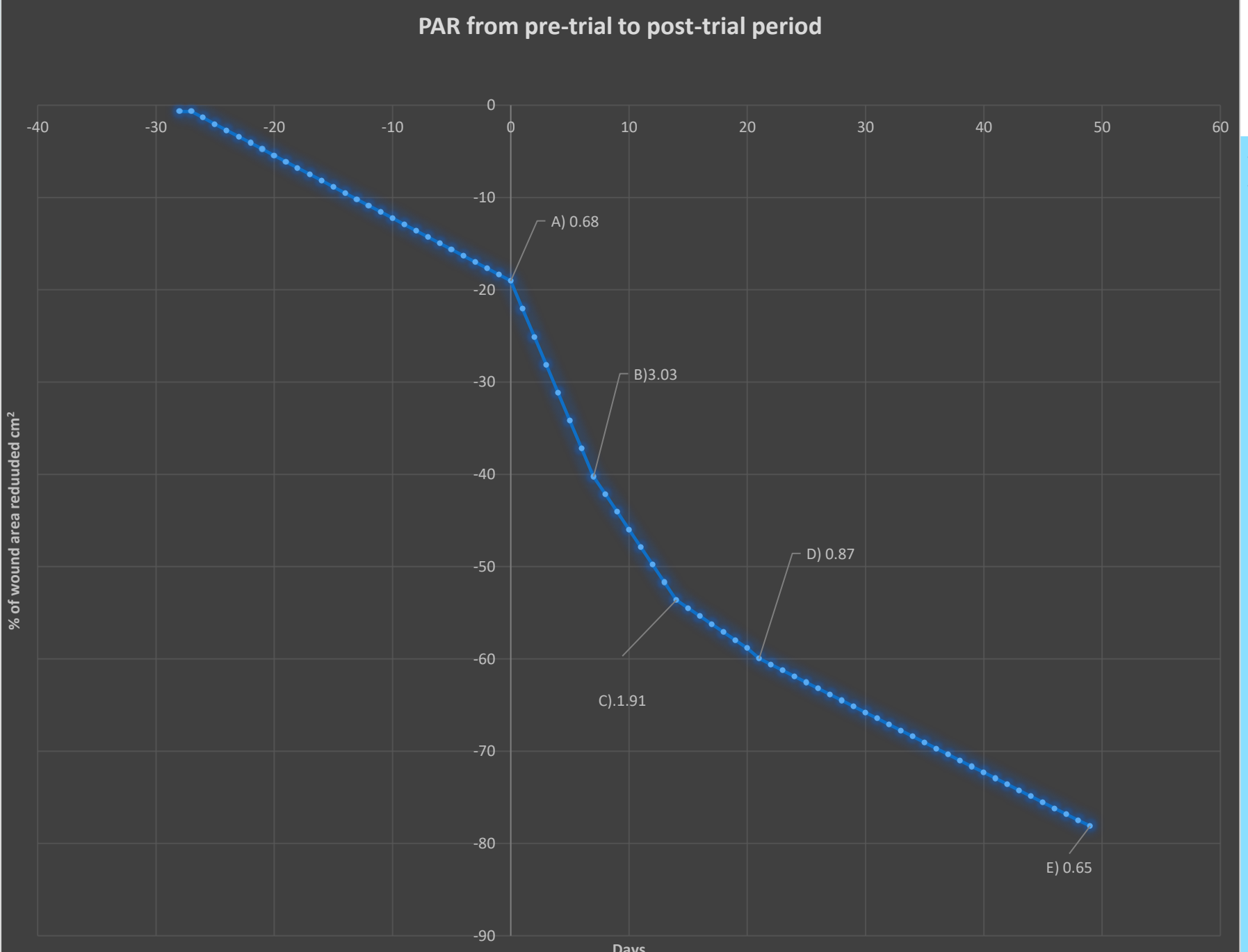


Figure 4: Daily PAR reduction from pre-trial to post-trial period. A: Daily PAR in the 4-week pre-trial period B: Daily PAR during first week of Kerecis fish skin graft C: Daily PAR during 2nd week of Kerecis fish skin graft application D: Daily PAR during 3rd week of Kerecis fish skin graft application E: Daily PAR in the 4 week post-trial period

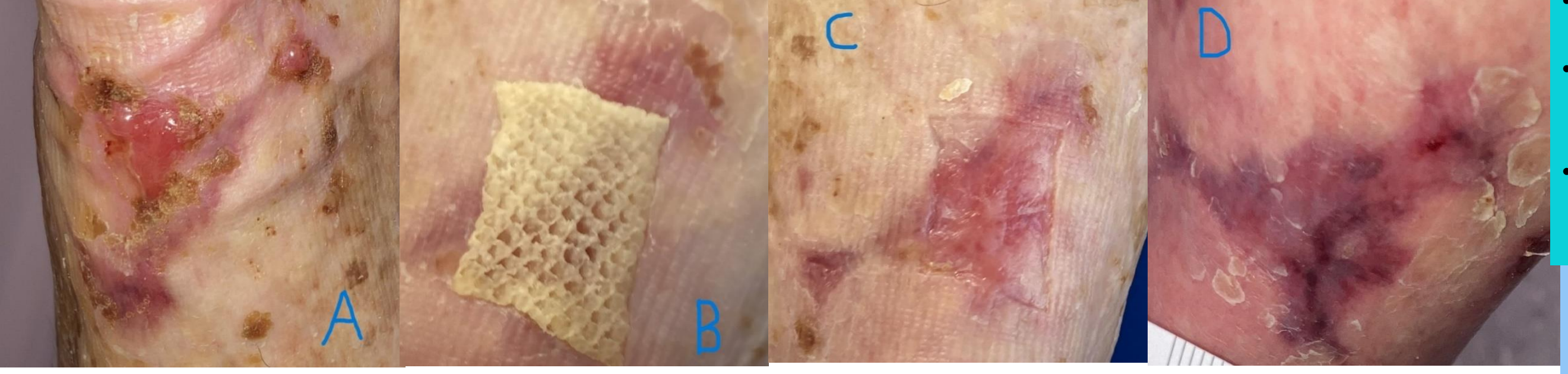


Figure 5: Patient treated due to trauma with underlying venous pathology A) Wound before initial application of Kerecis FSG B) 7 days after initial application of fish skin C) 14 days after initial application of fish skin (wound healed) D) 4 weeks post-trial (wound remained healed)

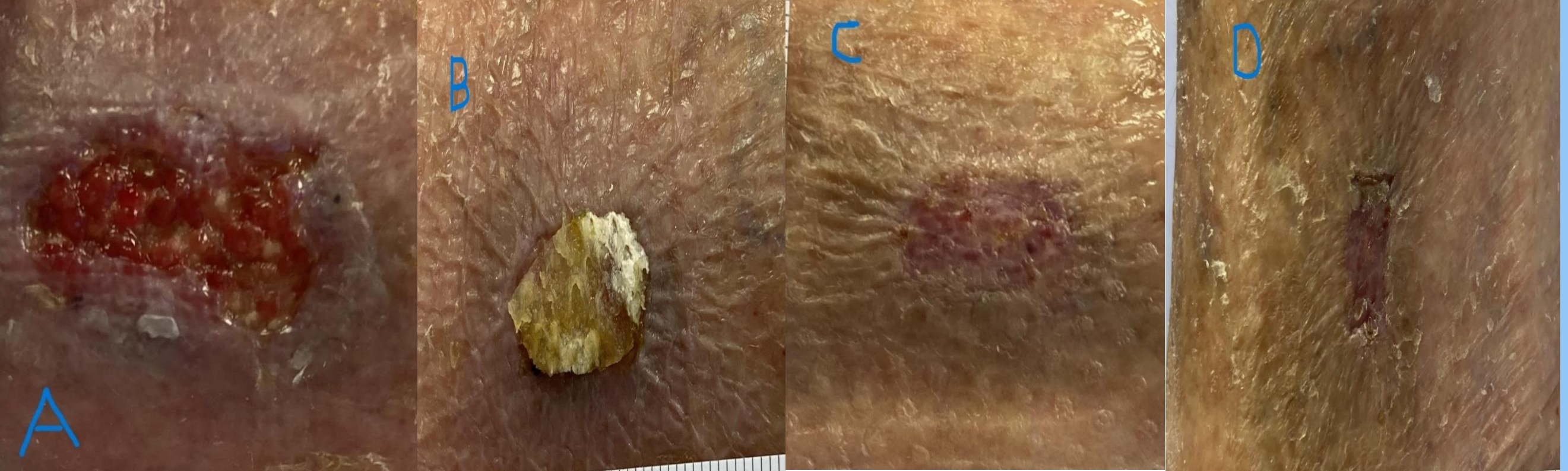


Figure 6: Patient with mixed venous and arterial leg ulcer A) Wound before initial application of Kerecis FSG B) 7 days after initial application of fish skin C) 14 days after initial application of fish skin (wound healed) D) 4 weeks post-trial (wound remained healed)

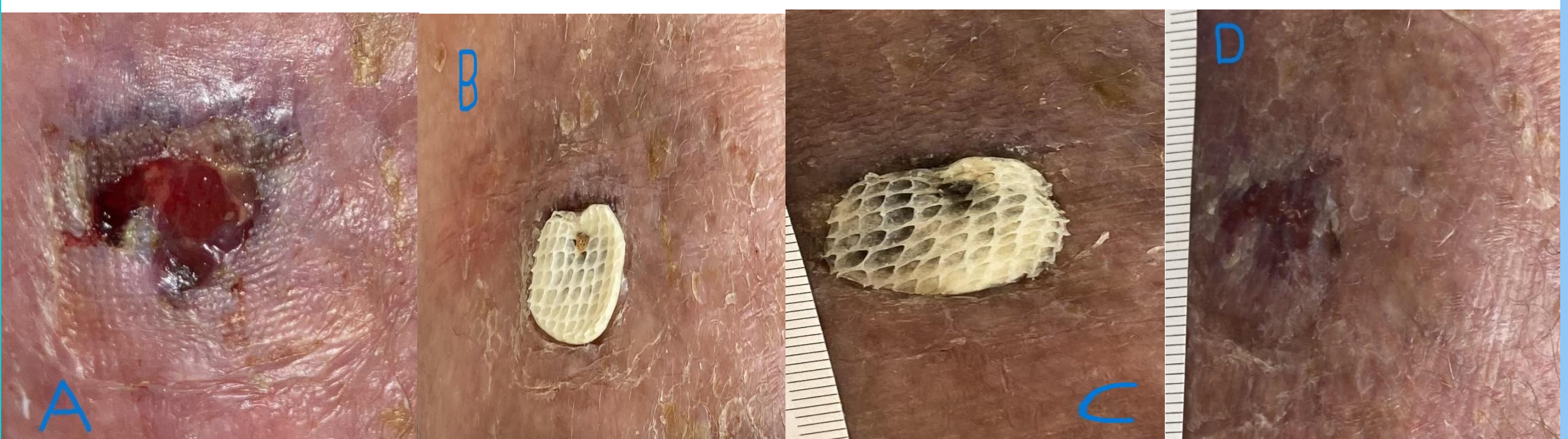

Figure 7: Patient with VLU at anterior gaiter A) Wound before initial application of Kerecis FSG B) 7 days after initial application of fish skin C) 14 days after initial application of fish skin (wound healed) D) 21 days after initial application of fish skin (wound healed)

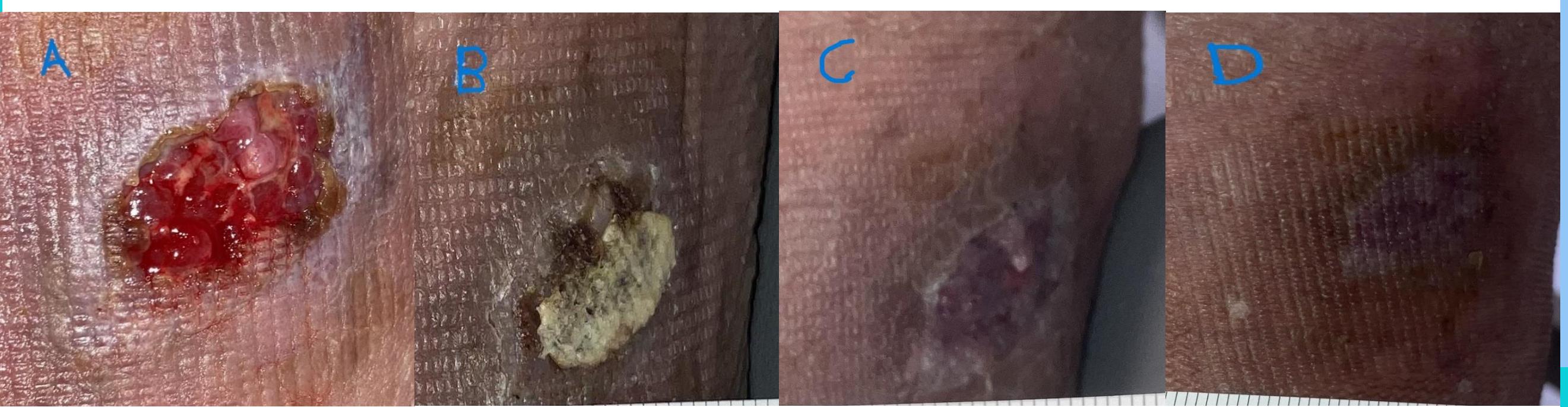


Figure 8: Patient with chronic wound below calf due to trauma A) Wound before initial application of Kerecis FSG B) 7 days after initial application of fish skin C) 14 days after initial application of fish skin (wound healed) D) 21 days after initial application of fish skin (wound remains healed)

Discussion

- In a study on the use of fish skin graft in patients with VLUs and diabetic foot ulcers demonstrated superior outcomes compared to standard of care¹⁶
- Similar to the results of my thesis Lee, Han and Shim saw the greatest reduction in the first week of treatment with fish skin graft¹⁷
- Utilizing fish skin resulted in a far greater PAR (percentage area reduction) of wound despite shorter duration of application
- Easy to apply
- Minimal storage requirements
- The fish skin we utilized was from an Icelandic company named Kerecis where renewable energy is almost exclusively used¹⁸

- Kerecis provides fish skin that may be stored at room temperature and requires minimal training on its use¹⁸
- The company uses fish skin from wild Atlantic cod in Iceland whereby the suppliers to the company are certified by Marine Stewardship Council (MSC) and Iceland Responsible Fisheries Management (IFRM) in order to ensure sustainable fishing practices¹⁸
- Kerecis have set up an environmental social and governance program (ESG) aligning their goals with the UN Sustainable Development Goals (SDGs) framework¹⁸

References

- Esmaili A, Biazar E, Ebrahimi M, Heidari Keshel S, Kheilnezhad B, Saeedi Landi F. Acellular fish skin for wound healing. *Int Wound J*. 2023; 20(7): 2924-2941. doi:10.1111/iwj.14158
- Ibrahim, A., Hassan, D., Kelany, N., Kotb, S., & Soliman, M. (2020). Validation of Three Different Sterilization Methods of Tilapia Skin Dressing: Impact on Microbiological Enumeration and Collagen Content. *Frontiers in veterinary science*, 7, 597751. <https://doi.org/10.3389/fvets.2020.597751>
- Ibrahim, A., Fahmy, H. M., Mahmoud, G. A., Soliman, M., & Elshahawy, A. M. (2024). New strategies for sterilization and preservation of fresh fish skin grafts. *Scientific reports*, 14(1), 1253. <https://doi.org/10.1038/s41598-024-51608-4>
- Phillips CJ, Humphreys I, Thayer D, Elmessary M, Collins H, Roberts C et al. Cost of managing patients with venous leg ulcers. *International wound journal*. 2020 Aug;17(4):1074-82. doi: 10.1111/iwj.13366. PMID: 32383324; PMCID: PMC7948848
- Guest JF, Ayoub N, McIlwraith T, Uchegbu I, Gerrish A, Weidlich D et al. Health economic burden that different wound types impose on the UK's National Health Service. *International wound journal*. 2017 Apr;14(2):322-30. doi: 10.1111/iwj.12603. PMID: 27229943; PMCID: PMC7950097
- Zhang P, Lu J, Jing Y, Tang S, Zhu D, Bi Y. Global epidemiology of diabetic foot ulceration: a systematic review and meta-analysis. *Annals of medicine*. 2017 Feb 17;49(2):106-16. doi: 10.1080/07853890.2016.1231932
- Agale SV. Chronic leg ulcers: epidemiology, aetiopathogenesis, and management. *Ulcers*. 2013;2013(1):413604. <https://doi.org/10.1155/2013/413604>
- Kahl B, Hermanns HJ, Gallenkerper G. Evidence-based treatment of chronic leg ulcers. *Deutsches Arzteblatt International*. 2011 Apr;108(14):231. <https://doi.org/10.3238/arztebl.2011.0231>
- Casey G. Causes and management of leg and foot ulcers. *Nursing Standard* (through 2013). 2004 Jul 21;18(45):57. DOI: 10.7748/ns2004.07.18.45.57.e3653
- Gotttrup F, Karlsmark T. Leg ulcers: uncommon presentations. *Clinics in dermatology*. 2005 Nov 1;23(6):601-11. <https://doi.org/10.1016/j.clindermatol.2005.01.018>
- Raffetto JD, Ligi D, Maniscalco R, Khalil RA, Mannello F. Why venous leg ulcers have difficult healing: overview on pathophysiology, clinical consequences, and treatment. *Journal of clinical medicine*. 2020 Dec 24;10(1):29. <https://doi.org/10.3390/jcm10010029>
- O'Donnell TF, Passman MA, Marston WA, Ennis WJ, Dalsing M, Kistner RL et al. Management of venous leg ulcers: clinical practice guidelines of the Society for Vascular Surgery® and the American Venous Forum. *Journal of vascular surgery*. 2014 Aug 1;60(2):3S-59S. <https://doi.org/10.1016/j.jvs.2014.04.049>
- Meissner MH, Moneta G, Burnand K, Gloviczki P, Lohr JM, Lurie F et al. The hemodynamics and diagnosis of venous disease. *Journal of Vascular Surgery*. 2007 Dec;46 Suppl S:4S-24S. doi: 10.1016/j.jvs.2007.09.043. PMID: 18068561
- Eberhardt RT, Raffetto JD. Chronic venous insufficiency. *Circulation*. 2014 Jul 22;130(4):333-46. <https://doi.org/10.1161/CIRCULATIONAHA.113.006898>
- Chi YW, Raffetto JD. Venous leg ulceration pathophysiology and evidence based treatment. *Vascular Medicine*. 2015 Apr;20(2):168-81. <https://doi.org/10.1177/1358863X14568677>
- Zehnder T, Blatti M. Faster than projected healing in chronic venous and diabetic foot ulcers when treated with intact fish skin grafts compared to expected healing times for standard of care: an outcome-based model from a Swiss hospital. *The International Journal of Lower Extremity Wounds*. 2022 May 12;15347346221096205. doi:10.1177/15347346221096205.
- Lee YJ, Han HJ, Shim HS. Treatment of hard-to-heal wounds in ischaemic lower extremities with a novel fish skin-derived matrix. *Journal of Wound Care*. 2024 May 2;33(5):348-56. <https://doi.org/10.12968/jowc.2024.33.5.348>
- Kerecis, 'Environmental, Social and Governance', Available at: www.kerecis.com/eg/,

Acknowledgments:

I would like to acknowledge the staff at Pioneer Wound Healing and Lymphoedema Centre for their help during this self-control evaluation. Additionally, I would like to thank Professor Steven Jeffery for his guidance and assistance during this self-control evaluation.

Dr. Rokhan Yousaf Zai
MBBS
MSc Burns, Plastic and Reconstructive Surgery (UCL)
Email:
rokhan.zai.20@ucl.ac.uk
rokhanyousafzai1@gmail.com

