Management of malignant fungating wounds with a bioactive microfibre gelling technology dressing: an evaluation

KEY WORDS

- Bioburden
- Case studies
- Malignant fungating wounds
- Odour reduction
- Oncology wounds
- Pathways

Aim: In this article, we aim to raise awareness of some of the clinical concerns surrounding the management of oncology wounds, particularly malignant fungating wounds. We will also provide practical wound management recommendations for healthcare professionals to consider when managing this wound type. We aim to assess the potential of a 100% chitosan with bioactive microfibre gelling (BMG™) dressing (MaxioCel®), to support wound management and work in partnership with industry to deliver clinical education on the management of oncology wounds, including malignant fungating wounds. **Method:** A case study series was undertaken over four weeks, using the chitosan BMG dressing. **Results:** We recruited 10 patients during the study. The chitosan BMG dressing facilitated a significant improvement in wound tissue type, exudate levels, and periwound skin, as well as reduced malodour. A reduction in patient-reported pain levels was also noted throughout the evaluation process. **Conclusion:** The introduction of BMG fibre technology demonstrated good outcomes in this patient group, in a short period of time. Importantly for this patient group, the BMG dressing was able to remain *in situ* during radiotherapy treatment, allowing uninterrupted management of the wounds.

SUSY PRAMOD
Lead Nurse Tissue Viability, The Christie NHS Foundation Trust, Manchester

SUE RICE
National Clinical Development Manager, CD Medical, Bolton, Lancashire

According to Cancer Research UK, there were 375,400 new cases of cancer during 2016–2018 (Cancer Research UK, 2023). Patients with cancer often suffer from acute or chronic wounds caused by either the disease itself or as a result of the cancer treatment. These wounds present many challenges for the patient, their family and the multidisciplinary team treating them.

Cancer can cause wounds in the form of multiple skin lesions or malignant fungating wounds (Naylor et al, 2001). Malignant fungating wounds are often non-healing wounds, which are caused by the aggressive proliferation of malignant cells and tumours that infiltrate the epidermis, blood vessels and underlying structures in advanced cancer patients (Grocott et al, 2013). Malignant fungating wounds can result from primary, secondary or recurring malignant disease (Alexander, 2009) and often become infected, although data on this is limited (Vardhan et al, 2019).

The wounds can be odorous, produce large amounts of exudate, bleed easily, cause psychosocial distress and are a constant reminder to the patient and family of progressive cancer (Schultz et al, 2002). The symptoms attributed explicitly to malignant fungating wounds are unique to this population (Tilley et al, 2016). Malignant fungating wounds are predominantly developed during the last months of life and indicate the impending end of life (Alexander, 2010).

An interdisciplinary approach with continuous consultation between various specialists can support patient management (Furka et al, 2022). Patients experiencing an oncology or malignant fungating wound require a comprehensive treatment solution to alleviate severe symptoms (Figure 1).

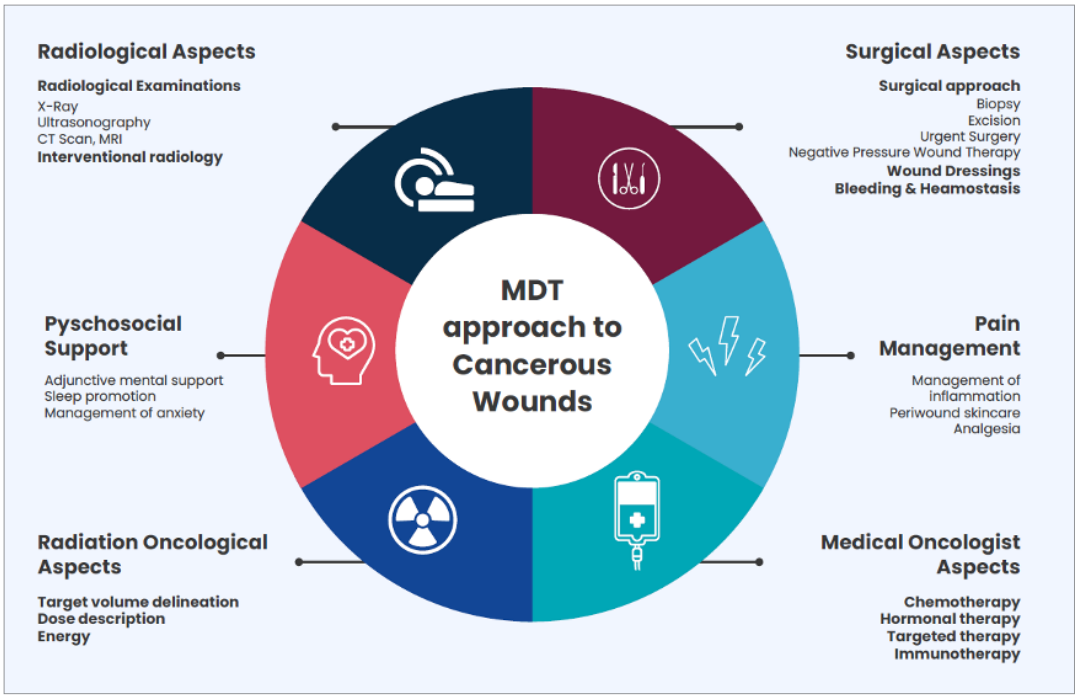

Figures 1.The multidisciplinary team approach to cancerous wounds. Adapted from from Andrea et al (2022).

The prevalence and challenges of malignant fungating wounds

Non-healing fungating wounds without effective therapy are a severe socio-economic burden for all involved, including patients, caregivers, and health services (Furka et al, 2022). Cancer patients with wounds may experience difficulties with symptom management, disturbances of body image, decreased feelings of self-worth and alterations in their quality of life (QoL). Such wounds often affect every aspect of an individual's life, including work, socialisation, and relationships. This can be due to prolonged healing times, the repeated need for medical attention in the form of dressing changes, pain, infection and odour (Olsson et al, 2019).

Chronic wounds affect up to 2.21 per 1000 individuals and significantly impact rates of morbidity (Martinengo et al, 2019; Sen, 2019). It is much more challenging to assess the prevalence of malignant fungating wounds, a subset of chronic wounds, as there is no incidence monitoring registry for this type of wound.

A survey of 269 nurses in Switzerland, which was conducted over a six month period, found the prevalence of malignant wounds in patients with metastasised cancer was 6.6% (Probst et al, 2009). However, this was a nurses' survey, not a prospective prevalence study, and the overall sample number was small, all of which means it may not represent the world population. Furthermore, the prevalence of malignant wounds is thought to be underreported due to feelings of shame, fear and embarrassment (Alexander, 2009).

A systematic review of literature published between 1995 and 2020 (Tilley et al, 2021) found that malignant fungating wounds can develop from any type of malignancy. The most prevalent are associated with breast cancer (66%), followed by head and neck tumours (24%). The groin, genitals, and back combined account for 3%, and all other sites account for 7%. According to Tilley et al (2016), malignant wounds are a global health problem and their incidence is expected to rise as the ageing population grows due to improvements in treatment.

Cancer wounds have a dynamic bacterial flora when compared with chronic wounds (Fromantin et al, 2013). Symptoms of malignant fungating wounds are already a result of an imbalance created by bacterial species, type, and total bacterial load (Vardhan et al, 2019). There is greater difficulty in diagnosing infection in malignant wounds since they often emit malodours, exudates, and necrosis, and their clinical signs are not indicative of bacterial imbalances (Fromantin et al, 2023).

A Cochrane review in 2014 found relatively little

Table1. Clinical benefits and mode of action of chitosan bioactive microfibre gelling (BMG) dressings

Clinical Benefit	Chitosan BMG mode of action
Haemostat	Positively charged chitosan fibres of the dressing attract negatively charged blood cell membranes, initiating the agglutination of red blood cells and platelets (Chen et al, 2017). Thrombin is activated and the clotting pathway begins to activate haemostasis
Antimicrobial/antibiofilm action	Oncology wounds can become infected and are at risk of increased and repeated infections. The positively charged chitosan fibres attract, disrupt and kill bacteria while reducing the bacterial load. Biofilms adhere to the gel matrix so when the dressing is changed the biofilm is removed
Odour management	The chitosan dressing can reduce odour by removing devitalised tissue and slough
Exudate management	BMG technology and the dressing's vertical wicking action allows for increased absorbency and strength. This results in effective exudate management and periwound skin protection
Pain reduction	Chitosan has been shown to have the ability to prevent the release of, and to help absorb, bradykinin that is released at the wound site and causes pain by directly stimulating primary sensory neurons (Okamoto et al, 2002)
Promotion of wound healing	The chitosan BMG dressing aids autolytic debridement, via the removal of slough and necrotic tissue. Chitosan BMG fibres have demonstrated cell migration similar to a positive control, demonstrating no toxicity (Edwards-Jones, 2023)
Reduction of inflammation	The inflammatory response is essential for wound healing. In many wounds, chronicity is associated with wounds remaining in this inflammatory phase with inflammatory proteins and other cytokines beginning to interfere with the healing process, this can lead to wound stasis and pain. The chitosan BMG dressing has a positive effect on reducing chronic inflammation and been shown to significantly reduce levels of matrix metalloproteinases (MMPs).

evidence for using topical agents and dressings to improve the QoL in people with malignant fungating wounds (Adderley and Holt, 2014).

In our Trust, there was an unexplainable increase of 94.4% of referrals for malignant fungating wounds in the year following the COVID-19 pandemic. This may be due to chance, or because there was a late cancer diagnosis or delayed referral during the COVID-19 pandemic. A potential gap in the education around the management of oncology wounds may also be a potential causative factor. As a tissue viability team, we wanted to raise awareness of some of the clinical issues surrounding the management of oncology wounds, as well as practical wound management recommendations for working as part of a multidisciplinary team (MDT), which could serve as a guide for healthcare professionals in future management of this wound type.

The challenge of dressing selection

According to the radiotherapy skin guidelines of the Trust, silver dressings (antimicrobial) are not appropriate to use while patients are undergoing radiotherapy. Even though there is limited evidence for the use of antimicrobials in malignant fungating wound management (Finlayson et al, 2017), antimicrobial dressings are widely used in clinical practice and are recognised to have a role in the reduction of odour (Gethin et al, 2023).

Additionally, we explored the options for dressings that do not require removal for radiotherapy treatment. In accordance with skin care guidelines, if the patient uses silver dressings for wound management, this must be removed before radiotherapy to prevent the beam from scattering. If the radiotherapy dose was calculated with the non-silver dressings on, there was no need to remove the dressings while treating the patient with radiotherapy. This indeed helps in unnecessary dressing changes.

A new chitosan bioactive microfibre gelling (BMG) dressing, MaxioCel, was recommended to our Trust for evaluation and to determine if it can overcome the challenges staff face with dressing changes during radiotherapy. We wanted to ensure

Table 2. Baseline demographics of the patients recruited for this evaluation

Patient	Wound type	Wound location	Wound duration	Presenting factors	Previous Dressing Used
1	Malignant fungating tumour	Left side of neck	12 months	High exudate levels, slight excoriation to periwound, 30% slough, 50% granulation, 20% over-granulation, pain visual analogue scale (VAS) 5	Silflex, Flaminal, Eclypse
2	Malignant fungating tumour	Left breast	7 months	Static wound, very high exudate levels, excoriated periwound, 50% necrosis and 50% slough, pain VAS 8	AquacelAG Extra, Flaminal, CliniSorb, Zetuvit Plus
3	Malignant fungating tumour	Sacrum	25 years	Static wound, moderate levels of exudate, eczematous periwound, 50% slough, 25% granulation, 25% epithelialisation, pain VAS 7	CarboFlex, Gamgee padding, Micropore
4	T-cell lymphoma	Left arm	7 months	Static, high levels of exudate, excoriated painful periwound, 80% necrosis, 10% slough, 10% granulation, pain VAS 8	Aquacel AG, Flaminal Forte
5	Fungating nodule disease, squamous cell carcinoma	Left side of neck	1 month	Deteriorating, high levels of exudate, macerated and excoriated periwound, 10% necrosis, 90% slough, pain VAS 2–4	Flaminal Forte, Silflex Contact, Aquacel Extra, PolyMem
6	Differential squamous cell carcinoma, malignant fungating wound	Lower mandibula	13 years	Static, very high levels of exudate, dry/eczematous periwound, 5% necrosis, 35% slough, 60% granulation, pain VAS 4–7	Kaltostat, Kliniderm, Aquacel Ag
7	Malignant fungating wound	Breast	18 months	Deteriorating, moderate levels of exudate, macerated periwound, 80% slough, 20% granulation, pain VAS 5	Mepilex Border, Flaminal Forte.
8	T-cell lymphoma	Left side of back	6 weeks	Static, low exudate levels, 5% granulation, 95% epithelialisation, pain VAS 4	Kliniderm, Aquacel Ag
9	Fungating ulcer	Groin	16 months	Deteriorating, high exudate levels, 5% necrosis, 60% slough, 35% granulation, healthy periwound, pain VAS 7	Aquacel Ag, Flaminal Forte
10	Lymphoma	Multiple sites: arm, leg	9 years	Deteriorating, moderate exudate levels, 100% slough, maceration to periwound, pain VAS 3	Flaminal, Aquacel Ag

that patients received the full benefit of a dressing's properties by not having to take them off every day, which is not necessary in most cases. The dressing's properties include haemostatic, antimicrobial and antibiofilm actions, as well as odour and exudate management, which in turn support a reduction in inflammation and wound pain, and promotes wound healing (Table 1).

Chitosan and bioactive microfibre gelling (BMG) technology

MaxioCel is a chitosan wound dressing with BMG technology. The gelling mechanism of BMG fibres enable the dressing to maintain a cohesive structure with increased fluid absorption capacity. The dressing, with vertical wicking, is intended for the management of moderate-to-heavy wound exudate with fluid-locking ability that prevents saturation, and consequently periwound skin maceration.

Due to the absorption of bradykinin and proton ions that are released within an inflammatory site, chitosan has also been found to have analgesic properties (Mo et al, 2015). Additionally, the reduction in exudate due to the dressing's absorption capability also improves periwound skin, which helps reduce pain levels and increases comfort levels for patients.

Grade A Chitosan is proven to have an antimicrobial effect against a range of common and uncommon wound pathogens (Dai et al, 2011). MaxioCel works in multiple ways against bacteria, including breaking down the cell wall and killing bacteria within the BMG fibres. MaxioCel's BMG fibres are positively electrostatically charged, naturally attracting negatively charged

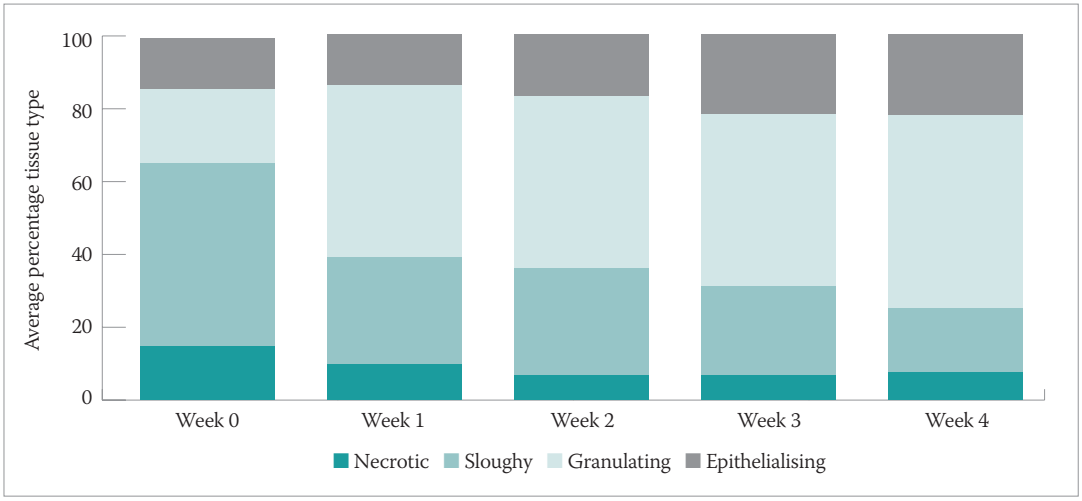

Figures 2. Average percentage of different tissue type

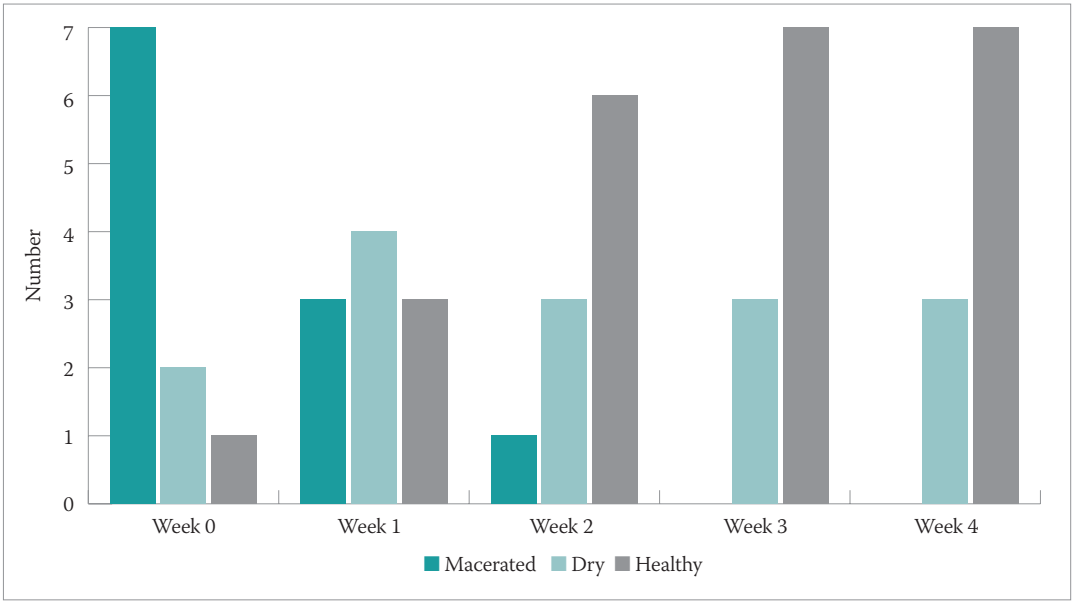

Figures 3. Changes to the periwound skin condition throughout four-week evaluation

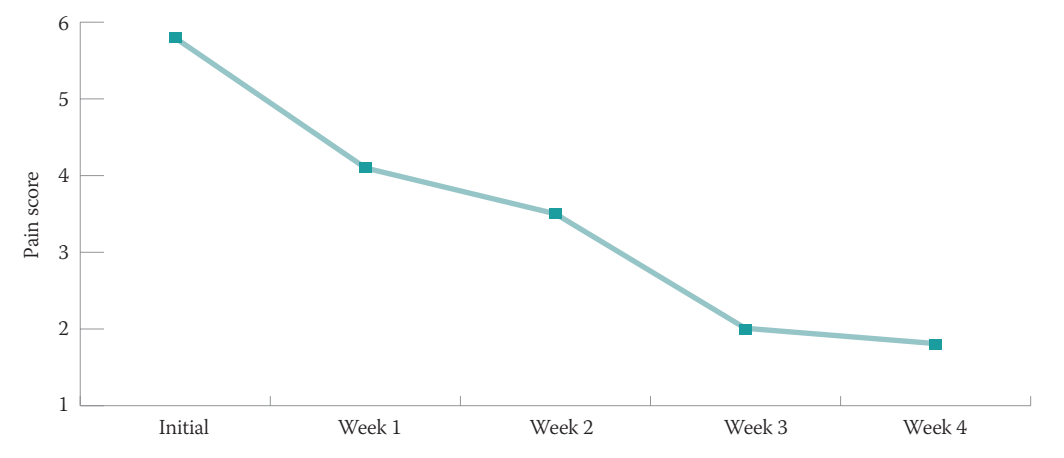

Figures 4. Change in the average patient's reported pain level (on visual analogue scale) over the four weeks

pathogens and trapping, disrupting, and killing them within the dressing fibers.

METHOD

A patient evaluation was undertaken to assess the impact of the chitosan BMG dressing over a four-week period at The Christie hospital, Manchester. All patients consented to take part in the study, signing the Trust's informed consent forms, as well as company consent forms. Consent was also given for the use of data and use of imagery for publication and teaching purposes. This was supported by the hospital's medical illustrations department. Patient recruitment initially took place across the hospital trust, and the evaluation continued across the wider community upon discharge.

RESULTS

Wound types included: fungating tumours to the neck (2) breast (2) sacral tumour (1) submandibular (1) groin (1) and three patients with lymphomas (3). Table 2 details the baseline demographics of the patients recruited, including wound types, location, duration, presenting factors and previous dressings used, to provide an overview of the clinical challenges faced.

By conclusion of the four-week evaluation period, the patient's wound status was assessed as: healing (7), almost healed (2) or non-healing (1). The average wound area reduced from 51cm^2 on initial assessment, to 44cm^2 at final assessment.

The wound tissue type improved throughout the evaluation period, with increased re-epithelialising and granulation tissue from 34.5% at presentation to 68.5% at final assessment. There was also a decrease in slough and necrotic tissue from 65.5% at presentation to 25.5% by final assessment (Figure 2).

By the conclusion of the evaluation period, an improvement in periwound skin condition was found with periwound maceration and excoriation reducing from 70% to 0% in the four-week period, and 'healthy' periwound skin increasing from 10% to 70% by the end of the evaluation (Figure 3).

Also, all patients in this study experienced a reduction in pain within the first few dressing changes, reducing in an average pain level of six on the visual analogue scale (VAS) at initial presentation, to two at final assessment (Figure 4). In the case of a 49-year-old female with T-cell lymphoma (Case study 2), the wound management objectives included the management of the patient's pain levels while promoting healing. The patient initially reported pain level as eight on VAS, causing significant distress and impacting QoL. By the end of the four-week evaluation, the patient's pain level had reduced to two.

Case study 1

- A 56-year-old female with a malignant fungating wound to the left side of her neck that had been present for 12 months
- **Initial assessment**: 24 April 2022. Wound dimensions: 8.5cm (length) x 3cm (width) x 0.5cm (depth). Wound bed condition: 40% slough, 50% granulation, 10% overgranulation, high exudate level, malodour, and moderate pain level 5 on VAS
- **Previous treatment:** Daily dressings with hydrofibre and superabsorbent. Antibiotic therapy for wound infection. Radiotherapy treatment, slight excoriation to periwound skin
- **Final assessment**: 24 May 2022. Wound dimensions: 5cm (length) x 0.5cm (width). Wound bed condition: 5% slough, 75% granulation, 20% epithelialisation, low exudate level, malodour no longer present and pain level 2 on VAS

Case study 2

- A 49-year-old female with T Cell Lymphoma to her left arm (5cm x 4.5cm) and satellite wound (3.5cm x 3.5cm)
- **Initial assessmen**: 21 April 2022. Wound dimensions: 5cm (length) x 4.5cm (width) x 0cm (depth). Wound bed condition: 80% necrotic, 10% slough, 10% granulation, moderate exudate level, malodour, significant pain level 8 on VAS
- **Previous treatment:** Foam dressing and enzymatic alginogel tried with no success. Patient's husband was changing the dressings at home 2-3 times per day.
- **Final assessmen**t: 26th May 2022. Wound dimensions: 4cms (length) x 3cm (width). Wound bed condition: 60% granulation, 40% epithelialisation, low exudate level, malodour no longer present and pain level 2 on VAS

21.04.2022

28.04.2022

30.06.2022

13.10.2022

Case study 1

A 56-year-old female with a malignant fungating wound to the left side of her neck that had been present for 12 months. The patient was undergoing radiotherapy. Wound management objectives were to encourage granulation, reduce exudate and the associated odour, and to reduce excoriation during patient's end-of-life care.

Full details can be found in Case study 1. In summary after the four-week treatment, the periwound skin was healthy. Community nurses were able to perform dressing changes on alternate days, which allowed the patient comfort during her end-of-life care. The patient found the dressing to be extremely comfortable and was very pleased with how it managed both exudate and in particular odour, and supported some reduction in wound pain.

Case study 2

A 49-year-old female with T-cell lymphoma on the left arm (5cm x 4.5cm) and satellite wound (3.5cm x 3.5cm). The patient expressed that the wound was impacting her QoL, as the offensive malodour of the wound was causing her embarrassment at work, where there was a shared office environment. Objectives were to manage the patient's pain levels, promote healing, protect granulation tissue, manage exudate and support autolytic debridement.

Full details can be found in Case study 2. In summary, within 4 days of beginning treatment using the chitosan BMG dressing, pain reduced, the necrotic area was debrided, slough softened, odour reduced, and dressing change reduced from 2–3 times per day to daily, allowing supported self-care. The periwound skin had improved. The patient requested to continue with the dressing beyond the evaluation. She was also receiving immunotherapy treatment.

DISCUSSION

In patients with malignant fungating wounds, an aggressive approach of debridement, cleansing and application of topical antimicrobial may not be possible due to patients' levels of pain and discomfort. The chitosan BMG dressing facilitated gentle debridement and minimisation of odour as a result of removing the bacterial load from the wound. Evidence of the dressing facilitating autolytic debridement can be seen in Case study 1, where the dressing supported the end-of-life care. Working in partnership with both radiotherapy and chemotherapy colleagues, and their associated treatment regime, also contributed to outstanding results in a relatively short period of time.

Malignant wounds have a myriad of unpleasant symptoms including odour, pain, bleeding and excessive exudate. The individual with a malignant

Table 3. Summary of the properties of chitosan bioactive microfibre gelling (BMG) dressing, and the clinical impact for patients in this evaluation

Clinical benefit	Chitosan BMG mode of action	Patient results
Haemostat	The positively charged chitosan fibres of this BMG dressing attract negatively charged blood cell membranes, initiating the agglutination of red blood cells and platelets (Chen et al, 2017). This promotes the activation of thrombin, which activates the clotting pathway, leading thrombus formation to activate haemostasis	There were two patients who experienced bleeding from their wounds. The BMG dressing aid haemostasis in both cases
Antimicrobial/ antibiofilm action	Oncology wounds can become infected and run the risk of increased and repeated infections which was seen during this evaluation. The positively charged chitosan fibres attract, disrupt and kill bacteria within the dressing, therefore reducing the bacterial load. Biofilms adhere to the gel matrix. When the dressing is changed, the biofilm is removed	There were four patients who had suspected or confirmed infection present in their wounds at initial presentation
Exudate management	BMG technology and the dressing's vertical wicking action allows for increased absorbency and strength, resulting in effective exudate management and periwound skin protection, together with longer dressing wear time which reduces dressing changes and clinic visits. The dressing can be removed in one piece	The BMG dressing effectively managed exudate in all 10 cases for a longer period of time, compared with previous dressings, and periwound skin was protected from further breakdown
Pain reduction	Chitosan has been shown to have the ability to prevent the release of, and to help absorb, bradykinin that is released at the wound site and causes pain by directly stimulating primary sensory neurons (Okamoto et al, 2002)	All 10 patients reported a reduction in pain (on the visual analogue scale) within the first few dressing changes
Promotion of wound healing	The BMG dressing aids autolytic debridement in helping to remove slough and necrotic tissue. BMG chitosan fibres have demonstrated cell migration similar to a positive control, demonstrating no toxicity and reflecting its contribution to supporting wound healing (Edwards-Jones, 2023)	A reduction in wound area was seen in 9 patients, which in turn increased patient concordance. There was one non-healing wound, however the objective was to manage wound symptoms during end-of-life care
Reduction of inflammation	The inflammatory response is essential for wound healing. However, in many wounds chronicity is associated with wounds remaining in this inflammatory phase with inflammatory proteins and other cytokines beginning to interfere with the healing process. This can lead to wound stasis and pain. The BMG dressing has been shown to significantly reduce levels of MMPs	In three patients, MaxioCel supported end-of-life care in which management of both inflammation, exudate, odour and periwound skin was extremely important

wound can suffer physical and social distress due to the unacceptable and offensive presence of the wound. Normality is turned on its head and they find themselves in a painful and undesirable situation (Young, 2017). By being able to manage the patient's wound pain, promote wound progression across the healing continuum, in the majority of cases, and together with end-of-life care, this evaluation demonstrated an enhanced experience for all involved and increased all the patient's QoL

This work has been presented at a national virtual oncology conference to support other clinicians managing oncology wounds alongside two virtual symposia. It is hoped that the introduction of a pathway (Figure 5) will support other clinicians in the management of their patients' oncology wounds and facilitate further discussion, education and training events around this topic in the future.

CONCLUSION

The case study series has been a thought-provoking experience for both patients and staff across all departments and specialities. The impact that the introduction of BMG Fibre technology has had alongside chemotherapy and radiotherapy, in such a short period of time, has been remarkable. WUK

Declaration of interest

This evaluation and publication of results was supported by CD Medical Ltd.

REFERENCES

Adderley UJ, Holt IGS (2014) Topical agents and dressings for fungating wounds. *Cochrane Database Syst Rev* 2014(5):CD003948. https://doi.org/10.1002/14651858.cd003948.pub3

Alexander S (2009) Malignant fungating wounds: epidemiology, aetiology, presentation and assessment. *J Wound Care* 18(7):273–76. https://doi.org/10.12968/jowc.2009.18.7.43110

Alexander SJ (2010) An intense and unforgettable experience: the lived experience of malignant wounds from the perspectives of patients , caregivers and nurses. *Int Wound J* 7(6):456–65. https://doi.org/10.1111/j.1742-481x.2010.00715.x

Cancer Research UK (2023) Health professional https://tinyurl.com/dwwvzf4k (accessed 17 October 2023)

Chen Z, Yao X, Liu L et al (2017) Blood coagulation evaluation of N-alkylated Chitosan. *Carbohydr Polym* 173:259–268. https://doi.org/10.1016/j.carbpol.2017.05.085

Dai T, Tanaka, M Huang, Y Y, Hamblin MR (2011) Chitosan preparations for

Oncology Wounds Pathway

BLEEDING

Light bleeding: [1]
✓ Apply local pressure for 10 – 15 minutes (with a moist, non-adherent dressing) to external bleeding. Proceed with caution as may cause pain.

✓ Apply an alginate or haemostatic dressing i.e. BMG fibre dressing.

Heavy bleeding:
✓ Apply pressure to wound

✓ Seek urgent medical advice

✓ Oral tranexamic acid or tranexamic acid (antifibrinolytic agent) made into a paste applied under dressings. Tranexamic acid 500mg in 5ml soaked into gauze and applied with pressure for 10 minutes.

✓ Topical sucralfate paste; can be made by crushing two 1-gram tablets in 5mL of water soluble gel and applied topically 1-2 times daily.

✓ Topical adrenaline (epinephrine) 1 in 1000 (1mg in 1ml) can be applied on gauze along with pressure to areas that are bleeding heavily to induce local vasoconstriction. Be aware may also cause 'rebound' bleeding once these effects wear off. Excessive use can cause ischaemic necrosis.

✓ Silver nitrate sticks can be used to cauterise small bleeding points

Severe, suspected end of life bleeding
✓ Ensure family / carers have emergency contact numbers

✓ Ensure supply of dark sheets or towels, gloves, aprons, plastic sheet, clinical waste bags

✓ Benzodiazepine (midazolam 10mg) can be given into a large muscle such as deltoid and gluteal

Only prescribed after specialist advice.
✓ Tranexamic acid topically at dressing changes 500mg / 5mls, 5-10 mls – as a preventative measure – off licence drug.
✓ Oral antifibrinolytics three times a day are prescribed if there is a tendency to bleed.

INFECTION

Local infection:
✓ Topical cleansing as per local guidelines

✓Autolytic debridement if required

✓Antimicrobial agents

✓ Apply an antimicrobial dressing as per local guidelines i.e. BMG fibre dressing

✓ Metronidazole Gel for short term use 5-7 days (BNF)

If clinical signs of infection (increased pain, exudate, fever, patient systemically unwell):

✓ Take wound swab

✓ Consider antibiotics

MALODOUR

Assess odour
✓ Use odour using odour intensity scale

Establish cause of odour [2]

Cause: Infection
Refer to section on Infection

Cause: Slough/necrotic tissue

Aid autolytic debridement with one of the following products, as per local guidelines:

✓ Hydrogel or Gelling Fibre Dressing. Some also contain antimicrobial properties.

✓ Alginate paste.

Note: Surgical sharp and mechnical debridement not recommended for fungating malignant wounds.

✓ Odour controlling dressings as an adjunct to the above (A cinnamon based dressing or activated charcoal dressing can be used as a secondary dressing over a non-adherent primary layer).

✓ Gentle irrigation where necessary with normal saline or appropriate antibacterial cleansing agents.

✓ Commence Metronidazole antibiotic wound gel if exudate levels are low.

✓ Consider essential oils as per your local complementary therapy team.

EXUDATE

Assess
✓ Volume and appearance, as change may indicate infection

Consider absorbency of secondary dressing as per local guidelines.

Alway apply non adherent primary contact layer below any absorbent dressing to reduce risk of trauma and bleeding upon removal

Protect periwound skin from maceration, excoriation, wound edge breakdown by applying a skin barrier film.

Consider referral to dietician if exudate is excessive.

PAIN

Assess pain levels
✓ Use numeric rating scale / visual analogue scale

Limit wound cleansing to only when necessary (removal of excess exudate and debris)

Select dressings that minimise trauma and pain during application and removal i.e. BMG fibre dressing, Polymeric dressing as per local guidelines

Give regular analgesia prior to dressing change dependant on need

Evaluate need for pharmacological and non pharmacological strategies to minimise pain

Swab wound and treat infection that may be the cause of pain

Refer to pain specialist nurse, GP or palliative care team as required., for further advice.

SKIN & TISSUE

Assess periwound skin

Maceration:
✓Protect surrounding skin with barrier film

✓Select appropriate secondary dressing (see exudate section)

Excoriation:
✓Consider cause – exudate, skin stripping, allergy to dressings.

✓ Protect surrounding skin with a barrier film.

✓ Select alternative dressing if allergy is suspected.

✓ Consider silicone primary dressing if skin stripping evident.

✓ Consider topical steroid treatment.

✓ Consider adhesive remover for dressing changes.

Itch:
✓Consider cause of itch – exudate, allergy to dressing, endogenous.

✓ Reverse cause of itch if possible i.e. exudate management, alternative dressing etc.

✓ Consider topical steroid treatment

✓ Consider emollient therapy (emollient spray for for fragile skin).

✓ Consider bed linen / garments that reduce itching.

✓ Seek further medical advice if necessary.

PYSCHO-SOCIAL

Assess psychological and social impact [3]

✓Continually assess psychological and social needs of the patient at each visit - thorough holistic assessment.

✓Consider psychological needs of family and caregivers, as well as those of the patient.

Considerations

✓Referral to counselling support services e.g. Macmillan, Marie Curie, and other services for social support for patient, family members and caregivers.

✓For further information see NICE guidance.

✓ Encourage supported self-care to facilitate patient empowerment, where appropriate.

References:
Adapted from MEMPHIS Pathway NHS Forth Valley and POSIES Pathway, Gardner S and Taylor K, Stockport NHS Foundation Trust. (1) Scottish Palliative Care Guidelines, Accessed June 2023. (2) European Oncology Nursing Society (2015) Recommendations for the Care of patients with Malignant Fungating Wounds (3) https://cks.nice.org.uk/topics/palliative-care-malignant-skin-ulcer/ Accessed June 2023

Clinicians should always refer to tissue viability specialist if:

- Treatment plan was established and shows no signs of progression within 2 weeks
- Increases in wound size, pain, exudate, or odour as can be an indication of a worsening wound condition
- There are underlying structures in the wound like exposed tendon or bone
- Deterioration of wound edges i.e., rolling or advancing, periwound maceration
- The cause aetiology of the wound is unknown
- Suspicion or signs of systemic infection — where detrimental biofilm or local infection is suspected and debridement is indicated but outside of the individual clinician's scope of practice
- Comorbidity factors e.g., uncontrolled diabetes, vascular status, elevated C-reactive proteins
- A decline in the patient's overall wellbeing and health.

Figure 5. The multidisciplinary team approach to cancerous wounds. Adapted from from Andrea et al (2022)

wounds and burns: antimicrobial and wound-healing effects. *Expert Rev Anti Infect Ther* 9(7):857–79. https://doi.org/10.1586/eri.11.59

Finlayson K, Teleni L, McCarthy AL (2017) Topical opioids and antimicrobials for the management of pain, infection, and infection-related odors in malignant wounds: a systematic review. *Oncol Nurs Forum* 44(5):626–32. https://doi.org/10.1188/17.ONF.626–32

Fromantin I, Seyer D, Watson S et al (2013) Bacterial floras and biofilms of malignant wounds associated with breast bacterial floras and biofilms of malignant wounds associated with breast cancers. *J Clin Microbiol* 51(10): 3368–73. https://doi.org/10.1128%2FJCM.01277-13

Furka A, Simkó C, Kostyál L et al (2022) Treatment algorithm for cancerous wounds: a systematic review. *Cancers (Basel)* 14(5):1203.https://doi.org/10.3390/cancers14051203

Gethin G, Vellinga A, McIntosh et al (2023) Systematic review of topical interventions for the management of odour in patients with chronic or malignant fungating wounds. Journal of Tissue Viability 32(1), pp. 151–157. Available at: https://doi.org/10.1016/j.jtv.2022.10.007

Grocott P, Gethin, G, Probst S (2013) Malignant wound management in advanced illness: new insights. *J Tissue Viability* 32(1):151-–7. https://doi.org/10.1016/j.jtv.2022.10.007

Leadbeater M (2016) Assessment and treatment of fungating, malodorous wounds. *Br J Community Nurs* 21 Suppl 3:S6–10. https://doi.org/10.12968/bjcn.2016.21.sup3.s6

Martinengo L, Olsson M, Bajpai R et al (2019) Prevalence of chronic wounds in the general population: systematic review and meta-analysis of observational studies. *Ann Epidemiol* 29:8–15. https://doi.

org/10.1016/j.annepidem.2018.10.005

Mo X, Cen J, Gibson E et al (2015) An open multicentre comparative randomized clinical study on chitosan. *Wound Repair Regen* 23(4):518–524. https://d SOTV - STP - GRAPHICS FOR JOURNALS3 oi.org/10.1111/wrr.12298

Naylor W, Laverty D, Mallett J (2001) The Royal Marsden Hospital Handbook of Wound Management in Cancer Care. Blackwell Science

Okamoto Y, Kawakami a K, Miyatake K et al (2002) Analgesic effects of chitin and chitosan. *Carbohydrate Polymers* 49(3):249–52. https://doi.org/10.1016/S0144-8617(01)00316-2

Olsson M, J¨arbrink K, Divakar U et al (2019) The humanistic and economic burden of chronic wounds: a systematic review. *Wound Repair Regen* 27(1):114–25. https://doi.org/10.1111/wrr.12683

Probst S, Arber A, Faithfull S (2009) Malignant fungating wounds: a survey of nurses' clinical practice in Switzerland. *Eur J Oncol Nurs* 13(4):295–8. https://doi.org/10.1016/j.ejon.2009.03.008

Sen CK (2019) Human wounds and its burden: an updated compendium of estimates. *Adv Wound Care (New Rochelle)* 8(2):39–48. https://doi.org/10.1089/wound.2019.0946

Schulz V, Triska OH, Tonkin K (2002) Malignant wounds: Caregiver-determined clinical problems. *J Pain Symptom Manage* 24(6):572–7. https://doi.org/10.1016/s0885-3924(02)00540-7

Tilley CP, Fu MR, Qiu JM et al (2021) The microbiome and metabolome of malignant fungating wounds: a systematic review of the literature from 1995 to 2020. *J Wound Ostomy Continence Nurs* 48(2):124–35. https://doi.org/10.1097/won.0000000000000749

Tilley CP, Lipson J, Ramos M (2016) Palliative wound care for malignant fungating wounds holistic considerations at end-of-life. *Nurs Clin North Am* 51(3):513–31. https://doi.org/10.1016/j.cnur.2016.05.006

Vardhan M, Zia Flaminio Z, Sapru S et al (2019) The microbiome, malignant fungating wounds, and palliative care. *Front Cell Infect Microbiol* 9: 373. https://doi.org/10.3389%2Ffcimb.2019.00373

Young T (2017) Caring for patients with malignant and end-of-life wounds. *Wounds UK EWMA Special* https://tinyurl.com/yr475u2p