

## Introduction

**Acute inflammation is the body's immediate response to injury. Signals released by damaged tissue increase local fluid, nutrient and immune system cell levels, resulting in swelling, heat, redness and pain. Adequate preparation of the wound bed can help to reduce inflammation and optimise conditions for healing. The TIME framework – which incorporates control of Inflammation and Infection – should be applied as part of a patient-centred treatment pathway (Dowsett and Newton, 2005). Local and systemic factors that contribute to inflammation need to be identified and managed. This Made Easy explains how prolonged inflammation can impact on healing, how to identify inflammation in practice, and which patients are at risk. It also describes how PROMOGRAN™ Protease Modulating Matrix and PROMOGRAN PRISMA™ Wound Balancing Matrix (KCI, an Acelity company) work to reduce inflammation and support progression to healing.**

## INFLAMMATION AND STALLED WOUNDS

The normal wound healing trajectory consists of four sequential phases that may overlap. These phases are haemostasis (0 to several hours after injury), inflammation (1–3 days), proliferation (4–21 days) and remodelling (21 days to 1 year) (Landén et al, 2016). Cellular and vascular changes that occur during acute inflammation remove foreign bodies and debris while providing the proteins and growth factors needed for tissue repair (Table 1). Under normal conditions, the symptoms associated with these processes decrease over time and disappear 4–6 days after injury (Table 2). A suboptimal wound environment, for example the presence of cellular debris, non-viable tissue or biofilm, and poor patient health status, can prolong the inflammatory process (Yastrub, 2009).

Inflammation results in:

- High levels of inflammatory cytokines and proteases (also known as proteinases), such as matrix metalloproteinases (MMPs) and elastases
- Low levels of growth factors and cell proliferation
- Increased bioburden and risk of associated complications.

If not addressed quickly, this can stall healing and cause further tissue breakdown becoming a self-perpetuating cycle (Figure 1). The issue of non-healing wounds is of key importance, both in terms of patient quality of life and cost. It has been highlighted that non-healing wounds cost on average 135% more than a wound that heals (Guest et al, 2017). Chronic wounds consume a disproportionate amount of resources (Frykberg and Banks, 2015) in an already stretched workforce (The Health Foundation, Kings Fund and The Nuffield Trust, 2018).

**Table 1. Cellular and vascular changes during inflammation (Collier, 2003; Cutting et al, 2015; Gefen, 2018)**

Cellular	Vascular
Damaged cells release chemokines, which: <ul style="list-style-type: none"> <li>■ Act as inflammatory signals</li> <li>■ Attract immune system cells (ISCs) to the site</li> <li>■ Increase vascular permeability</li> </ul> Immune system cells: <ul style="list-style-type: none"> <li>■ Release pro-inflammatory cytokines, which up-regulate inflammatory actions, causing local redness, swelling, increased temperature and pain</li> <li>■ Release histamine for inflammatory responses</li> <li>■ Surround and kill microorganisms</li> <li>■ Ingest foreign material</li> <li>■ Remove dead cells</li> <li>■ Attract additional ISCs to boost immune response</li> </ul>	Vasodilation of capillaries increases: <ul style="list-style-type: none"> <li>■ Local blood flow, increasing the volume of:                             <ul style="list-style-type: none"> <li>■ ISCs to tackle debris and foreign bodies</li> <li>■ Clotting factors to control bleeding</li> <li>■ Oxygen for tissue repair processes</li> <li>■ Protein-rich exudate for tissue repair</li> </ul> </li> <li>■ Osmotic pressure, drawing more fluid containing cells and nutrients to the injury site, resulting in swelling and pain</li> </ul> Increased vascular permeability enables: <ul style="list-style-type: none"> <li>■ ISCs, clotting factors and protein-rich exudate to leak into the area surrounding damaged cells</li> <li>■ ISCs to remove debris and foreign bodies</li> </ul>

# Identifying and managing inflammation

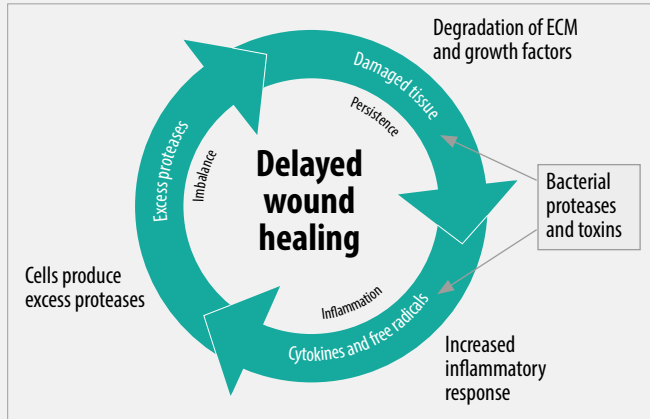


Figure 1. Cullen's delayed wound healing cycle (Gibson et al, 2009).  
ECM=extracellular matrix

Prevention and prompt management of prolonged inflammation is important to reduce the risk of further damage and infection. Visual indicators of continued inflammation include failure of a wound to significantly decrease in size (e.g. area reduction of 40% or more at 4 weeks; NICE, 2016) and little to no pink vascular tissue followed by a change in wound bed colour (to white, yellow or brown/black), increased exudate production, redness of the periwound area and possibly epibole/rolled edges to the wound (Yastrub, 2009). Greater exudate production may also increase in the presence of biofilm or infection (Schultz et al, 2011; WUWHS, 2019).

## INFLAMMATION VERSUS INFECTION

The signs and symptoms of inflammation can be very similar to that of infection (Table 2); therefore, anecdotal evidence suggests that infection can be over-diagnosed, when the key issue is inflammation. In diabetic foot ulceration, infection is based on the presence of two of the five signs of inflammation in the absence of another reason for the inflammation (e.g trauma). While infection creates inflammation, inflammation often exists in the absence of bacteria; therefore, local inflammation needs to be reduced in order to facilitate wound healing (Cutting and Harding, 1994; Dowsett and Newton, 2005; Wound Source, 2016; WUWHS, 2019).

Persistent wound inflammation is a recognised and damaging feature of the chronic wound environment and is frequently associated with wound ischaemia and infection, as bacterial proteases may contribute to the tissue damage in both the wound and periwound skin (Cutting et al, 2015). It has been hypothesised that a persistent inflammatory state may be due to underlying patient issues, or may be associated with the presence of biofilm (Wolcott et al, 2008).

It is important to differentiate between inflammation and infection (Table 2) in order to select the most appropriate treatment. An increase in the level of pain makes the presence of infection more likely (Reddy et al, 2012). Exudate characteristics can provide valuable indications about whether or not infection is present and, if so, the organism(s) responsible (WUWHS,

Table 2. Local signs of inflammation and infection (Cutting and Harding, 1994; Dowsett and Newton, 2005; Wound Source, 2016; WUWHS, 2019)

Inflammation	Infection
Local swelling that decreases over time	Persistent swelling
Redness that decreases over time	Redness around the wound that continues to expand or worsen
Pain worsens with stimuli (e.g. touching or dressing change) and decreases over time; may increase and become continual in stalled/hard-to-heal wounds	Increasing or continual wound pain
Increased skin temperature near the wound	Increased skin temperature near the wound and possibly spreading from the wound
Loss of function and movement in the wounded area	Loss of function and movement in the wounded area
Exudate more likely to be: <ul style="list-style-type: none"> <li>■ Thin, watery or slightly thicker than water</li> <li>■ Clear</li> <li>■ Amber, straw-coloured or pink</li> </ul>	Exudate more likely to be: <ul style="list-style-type: none"> <li>■ Thick</li> <li>■ Cloudy, milky or opaque</li> <li>■ Green, yellow, tan, brown or red</li> <li>■ Malodorous</li> </ul>
	Friable granulation tissue that bleeds easily
	Pocketing/bridging at the base of the wound
	Wound breakdown/enlargement
	Cellulitis/redness

**Authors:**

Jacqui Fletcher, Independent Nurse Consultant, UK  
Paul Chadwick, Visiting Professor in Tissue Viability, Birmingham City University, UK

2019). The presence of systemic symptoms, such as a high temperature, raised white cell count, C-reactive protein and/or erythrocyte sedimentation rate, lethargy, nausea/loss of appetite and confusion, indicate the presence of infection (Patten, 2010). If there are clinical signs of infection, a swab should be taken to identify the causative organism (Dowsett and Newton, 2005; Patten, 2010).

### THE IMPORTANCE OF ASSESSMENT

A holistic assessment should be performed to:

- Determine the underlying aetiology of the wound to identify treatment goals
- Aid in the selection and implementation of appropriate management, including interventions to treat the underlying causes of the wound
- Provide a baseline from which to assess healing progression and treatment efficacy (WUWHS, 2019; Lawton, 2009).

#### Patient assessment

Comorbidities and patient factors that increase the likelihood of prolonged inflammation are listed in Box 1. Encouraging healthy eating and smoking cessation as well as treating comorbidities, will improve the chances of a positive outcome (Dowsett and Newton, 2005). Risk assessments may be appropriate for individuals in whom further wound development may occur (WUWHS, 2019).

#### Wound assessment

The wound should be assessed for signs of inflammation and infection (Table 2). Prompt, appropriate wound bed preparation following the TIME framework reduces inflammation and optimises conditions for healing by removing damaged tissue and foreign materials and by reducing bacterial bioburden (Dowsett and Newton, 2005). Careful re-evaluation of the patient's health and wound status is required if healing has stalled to determine the cause.

### THE ROLE OF DRESSING SELECTION

While managing inflammation can involve many elements (e.g. wound cleansing, growth factor protection [Cullen et al,

**Box 1. Patient factors increasing the chances of prolonged inflammation and delayed healing (Guo and DiPietro, 2010).**

- Chronic conditions, such as diabetes or cancer
- Cardiovascular diseases
- Older age
- Immobilisation, e.g. following surgery
- Obesity
- Previous history of chronic wounds, e.g. leg ulcers
- Lifestyle, e.g. smoking, poor diet, stress
- Compromised immune system, e.g. due to corticosteroids or chemotherapy

2002]), dressing selection is an important part of care. The PROMOGRAN™ Matrix Family of wound matrix dressings provide an interactive wound therapy that transforms into a soft, conformable, biodegradable gel in the presence of exudate, maximising contact with the wound bed and optimising moisture levels (Table 3). Its efficacy is supported by a range of clinical evidence, including randomised controlled trials for PROMOGRAN™ Matrix (Veves et al, 2002) and PROMOGRAN PRISMA™ Matrix (Gottrup et al, 2013; Lázaro-Martínez, 2007).

Proteases are present at higher levels and persist for much longer in non-healing wounds than they would during the normal course of healing (Wounds International, 2011). Excess MMPs and human neutrophil elastase degrade and destroy collagen, gelatin, extracellular matrix proteins and growth factors (Cullen et al, 2002). Proteases and their actions are, therefore, key targets in the prevention of prolonged inflammation.

**Table 3. Components of PROMOGRAN™ Matrix and PROMOGRAN PRISMA™ Matrix**

Component	Role	Dressing
Oxidised regenerated cellulose	Increases cell growth; protects growth factors from degradation; inactivates proteases (specifically binding human neutrophil elastase); mops up free radicals; lowers pH (controlling bacteria); and is haemostatic (Cullen et al, 2002; Hart et al, 2002).	PROMOGRAN™ Matrix; PROMOGRAN PRISMA™ Matrix
Collagen	Supports cellular differentiation, angiogenesis and mitogenesis; involved in protein synthesis, extracellular matrix deposition, cellular migration, platelet aggregation, clotting and wound contraction; controls MMP activity by providing an alternate substrate; induces growth factors, cytokines, extracellular matrix molecules and proteins (Rangaraj et al, 2011).	PROMOGRAN™ Matrix; PROMOGRAN PRISMA™ Matrix
Silver-oxidised regenerated cellulose	Contains ionically bound silver that has proven antimicrobial properties, particularly when combined with lowered pH level (facilitated by ORC; Cullen et al 2002), providing bactericidal properties even when bacteria are in a biofilm (Graham, 2005).	PROMOGRAN™ Matrix; PROMOGRAN PRISMA™ Matrix

PROMOGRAN™ Matrix and PROMOGRAN PRISMA™ Matrix address the three components of Cullen's delayed healing cycle (Figure 1), and thus stimulate wound healing by:

- Binding to and inactivating excess proteases, retaining them within the gel
- Binding to growth factors, preventing their degradation, and releasing them back into the wound bed
- Binding elastase activity and lowers pH to help control bacteria (Cullen et al, 2002)
- Providing additional collagen, which acts as a sacrificial substrate for excessive MMPs and supports the creation of new tissue (Cullen et al, 2002).

### Indications and application

PROMOGRAN™ Matrix (55% Collagen: 45%ORC) and PROMOGRAN PRISMA™ Matrix (55% Collagen: 45% ORC: 1% Silver-ORC) are indicated for the management of all wounds healing by secondary intent which are clear of necrotic tissue, including diabetic ulcers, venous ulcers, pressure ulcers, ulcers caused by mixed vascular aetiologies and traumatic and surgical wounds. It should be applied directly to the wound following debridement of dry necrotic material and should cover the entire wound bed. Following application, a secondary dressing should be selected that is suitable for the level of exudate present. Compression therapy can be applied over the top of the secondary dressing.

Depending on the volume of exudate, PROMOGRAN™ Matrix and PROMOGRAN PRISMA™ Matrix can be reapplied every 24–72 hours. The dressing gels on contact with fluid and is biodegradable. It is naturally absorbed over time and any residual dressing does not need to be removed when the matrix is reapplied. When PROMOGRAN™ Matrix and PROMOGRAN PRISMA™ Matrix are used on wounds with no or little exudate, the dressing should be hydrated with saline to initiate the gel forming process. Systemic antimicrobial therapy should be considered in conjunction with the use of PROMOGRAN PRISMA™ Matrix if infection is

evident. If infection is suspected with PROMOGRAN™ Matrix an appropriate antimicrobial dressing or systemic therapy should be used. These products should be used under medical supervision. These products should not be used in patients with hypersensitivity to collagen, ORC or silver and should be discontinued if signs of sensitivity appear.

### Patient benefits

The dressing transforms into a soft and conformable biodegradable gel. PROMOGRAN™ Matrix and PROMOGRAN PRISMA™ Matrix modulate and re-balance the wound environment by the unique combination of binding and inactivation of proteases (i.e. matrix metallo proteases, elastase and plasmin) which have been shown to be detrimental and in excess in chronic wounds. They also bind and protect naturally occurring growth factors against degradation, by these excess proteases, and have been shown to proliferate human dermal fibroblasts *in vitro*. In addition, PROMOGRAN PRISMA™ Matrix contains silver which is a broad spectrum antimicrobial which has been shown to be effective against wound pathogens. By optimising the wound healing environment, PROMOGRAN™ Matrix and PROMOGRAN PRISMA™ Matrix help stimulate healing and reduce the risk of a wound becoming hard to heal.

### SUMMARY

Clinicians should consider the presence of inflammation when performing a holistic wound assessment and manage contributing factors by preparing the wound bed following the TIME framework and treating underlying comorbidities that may prolong the inflammatory process. Prolonged inflammation can result in additional tissue damage, sensitisation, pain and stalled healing. Wound treatments that help to reduce the effects of inflammation, such as PROMOGRAN™ Matrix and PROMOGRAN PRISMA™ Matrix, should therefore be considered in patients at risk of delayed healing and in wounds showing signs of prolonged inflammation to optimise conditions for healing. Doing so, has the potential to speed up healing, reduce number of dressing changes, release nurse capacity and resources and positively impact the patient.

### REFERENCES

- Collier M (2003) *Nurs Times* 99(25): 63–4
- Cullen B et al (2002) *Wound Repair Regen* 10(1): 16–25
- Cutting KF, Harding KG (1994) *J Wound Care* 3(4): 198–201
- Cutting KF et al (2015) *Wounds International* 6(2): 41–6
- Dowsett C, Newton H (2005) Wound bed preparation: TIME in practice. *Wounds UK* 1(3): 58–70
- Falanga V (2009) *Blood Cells Mol Dis* 32(1): 88–94
- Frykberg RG, Banks J (2015) *Adv Wound Care* 49(9): 560–82
- Gibson D et al (2009) *MMPs Made Easy*. Wounds International: London
- Gefen A (2018) Managing inflammation by means of polymeric membrane dressings in pressure ulcer prevention. *Wounds International* 2018;9(1)22–8
- Gottrup F et al (2013) *Wound Repair Regen* 21(2): 216–25
- Graham C (2005) *Br J Nurs* 14(19): S22–6
- Guest JF, Vowden K, Vowden P (2017) *J Wound Care* 26(6): http://bit.ly/2lBn6Bq (accessed 27.08.2019)
- Schultz GS, Davidson JM, Kirsner RS et al (2011) *Wound Rep Reg* 19(2): 134–48
- Veves A, Sheehan P, Pham HT (2002) *Arch Surg* 137(7): 822–7
- Wolcott RD, Rhoads DD, Dowd SE (2008) *J Wound Care* 17(8): 333–41
- Wound Source (2016) 8 signs of wound infection. Available at: [www.woundsource.com/blog/8-signs-wound-infection](http://www.woundsource.com/blog/8-signs-wound-infection) (accessed 16.08.2019)
- Wounds International (2011) *International consensus. The role of proteases in wound diagnostics. An expert working group review*. London: Wounds International
- World Union of Wound Healing Societies (2019) *Wound exudate: Effective assessment and management. A consensus document*. London: Wounds International
- Yastrub DJ (2009) Pearls for practice: getting the stalled wound back on the road to healing. *Wound Prev Management* 55(1): 8
- Guo, DiPietro LA (2010) *J Dent Res* 89(3): 219–229
- Hart J, Silcock D, Gunnigle et al (2002) *Int J Biochem Cell Biol* 34(12): 1557–70
- Landén NX, Li D, Ståhl M (2016) *Cell Mol Life Sci* 73(20): 3861–85
- Lawton S (2009) *World Wide Wounds*
- Lázaro-Martínez JL et al (2007) *Cir Esp* 82(1): 27–31
- NICE (2016) *Chronic wounds: advanced wound dressings and antimicrobial dressings*. NICE, London. Available online at: <https://www.nice.org.uk/advice/esmpb2/chapter/full-evidence-summary-medicines-and-prescribing-briefing> (accessed 30.09.2019)
- Patten H (2010) *Wound Essentials* 5: 63–6
- Rangaraj A, Harding K, Leaper D (2010) The role of collagen in wound management. *Wounds UK* 7(2): 54–63
- Reddy M, Gill SS, Wu W et al (2012) *JAMA* 307(6): 605–11
- The Health Foundation, Kings Fund and The Nuffield Trust (2018) *The Health Care Workforce in England: Make or Break*. Available at: