

# Understanding necrobiosis lipoidica diabetorum

## KEY WORDS

- » Diabetes Mellitus
- » Granuloma annulare
- » Necrobiosis lipoidica diabetorum
- » Wounds

Necrobiosis lipoidica diabetorum (NLD) is an uncommon inflammatory condition that usually affects people with diabetes mellitus (DM), in which shiny, red-brown or yellowish patches develop in the skin often on the lower limbs. The course of the disease is unpredictable with recurrence and flare-ups common occurrences. In her article, Trudie Young gives an overview of this condition, its aetiology, clinical presentation, complications and treatment options

Diabetes mellitus (DM) is a heterogeneous group of metabolic disorders characterised by elevated serum glucose levels resulting in defects in insulin production in the beta cells of the islets of Langerhans in the pancreas. In type 1 DM the destruction/inactivity of insulin-producing beta cells results in dependence on exogenous insulin. Whereas type 2 non-insulin dependent DM can be controlled by a combination of oral medication and diet. Type 2 DM is associated with older age, obesity, physical inactivity and family history of the disease (Chakrabarty et al, 2002).

The number of adults living with DM worldwide in 2017 was 425 million and this is expected to rise to 629 million by 2045 (International Diabetes Federation, 2018) (*Figure 1*). There is an increase in DM in the younger population due to sedentary lifestyles and diet (Karadag et al, 2018).

The complications of DM are as a result of metabolic, hormonal, environmental and genetic factors which can affect all organs of the body including the skin (Karadag et al, 2018). The complications include retinopathy, neuropathy and nephropathy. DM has been implicated as the single largest cause of end-stage renal disease, the main reason for non-traumatic amputation and an independent risk factor for cardiovascular disease (Chakrabarty et al, 2002). One-third of individuals with DM will have some form of disease-related dermatological problem (Stewart, 2006).

Necrobiosis lipoidica diabetorum (NLD) was

described by Urbach in 1932 and subsequently by Oppenheim in 1932 when he referred to NLD as '*dermatitis atrophicans diabetica*' (Drury et al, 1967; Hammer et al, 2016). A year after Oppenheim's presentation at the Vienna Dermatological Society, Klaber presented a patient with NLD to the Royal Society of Medicine, UK, (Klaber, 1933; McGuinness and Padhiar, 1997). Subsequently Gordon published the histology report of a patient with NLD in the Journal of the Royal Society of Medicine (Gordon, 1937).

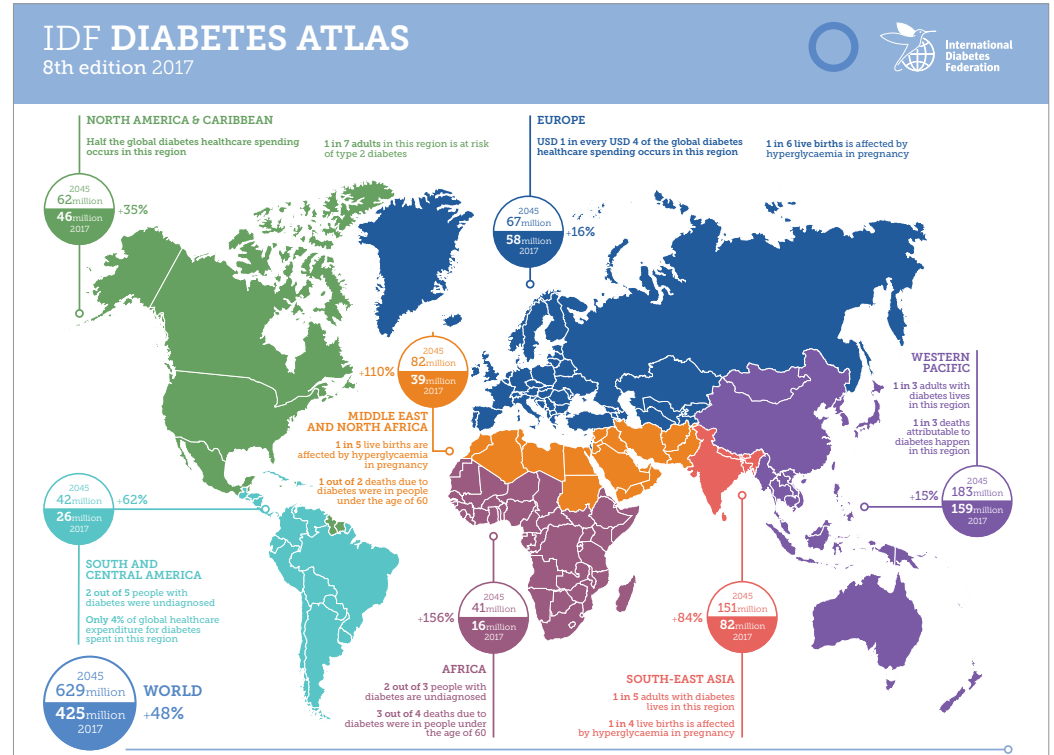
Necrobiosis literally means a state of life and death and is therefore self-cancelling, necro meaning degeneration and bio meaning regeneration. Lipoidica refers to the accumulation of fat which is not a primary event of the disease, diabetorum links it to DM (McGuinness and Padhiar, 1997).

NLD is a rare non-infectious granulomatous disorder of the skin which occurs in 0.3% of people with both type 1 and type 2 DM (Du Vivier, 2002; Mistry et al, 2017). It is more common in the female population with the average age of onset being 30-years old. It can be found in people without DM although this may be a precursor to the disease and the individual will require regular monitoring for the development of DM. Sanotos et al (2013) present one of many case studies in the literature of an individual with typical NLD on the pretibial area that did not have DM and it was thought to be preceding the onset of DM. The first incidence of NLD reported

## TRUDIE YOUNG

Director of Education and Training and Tissue Viability Nurse, Welsh Wound Innovation Centre, Llantrisant, Wales, UK

Figure 1. The International Diabetes Federation (IDF) Atlas (with kind permission from the IDF, 2017)



in the non-diabetic population was described by Goldsmith in 1935 (Kota et al, 2012). There is debate in the literature regarding the relationship of NLD to diabetes with Hammer et al (2016) establishing a link between type 1 DM and NLD in a retrospective review of 64,133 patients. In addition, there are multiple case reports highlighting NLD alongside poor glycaemic control (Yigit and Estrada, 2002; Bonura et al, 2014). However, following a review of the literature Mistry et al (2017) state that there is currently insufficient evidence to support or refute the claim of a link between glycaemic control and the manifestation of NLD. Consequently, the disease is sometimes referred to as necrobiosis lipoidica (NL) with the 'diabeticorum' being dropped from the title.

### AETIOLOGY

The aetiology of the disease is said to have three mechanisms; microangiopathic ischaemia, an immunological component and collagen abnormalities (Bonura et al, 2014).

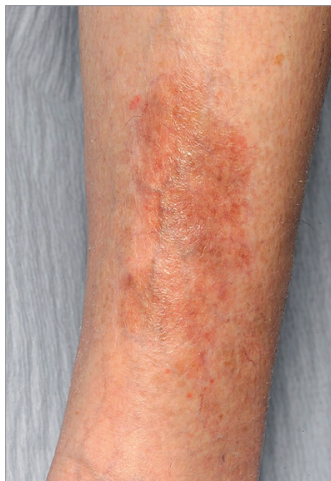Structural changes in diabetic microcirculation results in a thickening of the basement

membrane. This does not lead to a decrease in the diameter of the capillary lumen, however, the structural alterations adversely affect the vasodilation capacity, cellular adhesion, proliferation, differentiation and gene expression (Tecilizich et al, 2011).

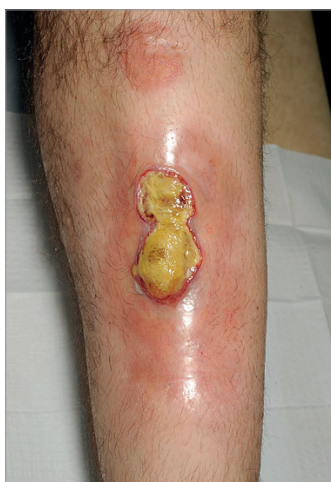Immunofluorescence studies have demonstrated the presence of immunoglobulin, fibrinogen and complement deposition on the vascular wall of the capillaries and occasionally along the dermal/epidermal junction which may indicate an immunological-mediated vascular disease mechanism in NLD (Scaramuzza et al, 2012).

The dermal collagen degenerates producing dermal inflammation at the site of the lesion. Microangiopathic vessel changes can contribute to the development of collagen degradation and subsequent dermal inflammation (Mazur et al, 2011).

There is debate regarding which component is the leading underlying mechanism, e.g. Doppler studies have demonstrated that an underlying inflammatory process, rather than microangiopathic ischaemia of the skin plays the



**Figure 2. NLD in pre-tibial area with early onset plaque present**



**Figure 3. Active NLD lesion**

most important role in the pathogenesis of NLD. Whereas glycoprotein deposition on the vascular wall of skin capillaries due to the underlying diabetes results in the lower oxygen tension within the lesion (Basoulis et al, 2015). There is a school of thought that views NLD as a primary disease of collagen with inflammation occurring as a secondary event (Mazur et al, 2011).

Histological examination of the lesions demonstrates the presence of interstitial and palisaded granulomas in a layered presentation that involve the subcutaneous tissue and the dermis (Korber and Dissemond, 2007; Kota et al, 2012). Dermal collagen degeneration is seen along with an atrophic epidermis and a thickening of blood vessel walls (Kota et al, 2012; Lima et al, 2017).

### CLINICAL PRESENTATION

The disease starts with red papules that slowly enlarge into erythematous non-scaling plaques (Figure 2) with waxy indurated yellow-brownish telangiectatic centres and raised edges (Phillips, 2003; Tecilazich et al, 2011; Motolese et al, 2015). The plaques can precede ulcerations by months or years (Dissemond et al, 2018). It is particularly prevalent on the lower limbs; however, it can present on the fingers, dorsum of hands, face, scalp, abdomen, interscapular region and penis (Drury et al, 1967; Kanchan et al, 2001; Du Vivier, 2002; Korber and Dissemond, 2007; Scaramuzza et al, 2012; Bonura et al, 2014; Mistry et al, 2017). The presentation on the lower limbs is often bilateral and symmetrical and may present with single or multiple lesions (Tecilazich et al, 2011).

The lesions are usually asymptomatic and are not associated with any serious complications (Stewart, 2006). However, pruritis and pain have been recorded at the site of the lesions in patients with NLD (Drury et al, 1967; Dissemond et al, 2012). The disease process has periods of activity when the lesions commence and enlarge (Figure 3) and periods of inactivity when the lesions become atrophied (Stewart, 2006). NLD is self-limiting and can resolve spontaneously, however, recurrence is a probability and flare ups are frequent (Wake and Fang, 2006; Mistry et al, 2017).

There are reports in the literature of NL and NLD occurring following tattooing and tattoo removal (Babin-Muise et al, 2012; Jibreal et al, 2017).

### COMPLICATIONS

The three main complications reported in NLD are the development of malignancy within the lesion, secondary infection in the wound bed and the unsightly scarring which produces a cosmetic disability (Guidi et al, 2000; McGuinness and Padhiar, 1997).

### DIFFERENTIAL DIAGNOSIS

Granuloma annulare is a chronic asymptomatic dermatosis found on dorsum of the hands, feet and elbow and it can be difficult to distinguish from NLD. It is characterised by collagen degeneration and reactive inflammation and fibrosis (Chakrabarty et al, 2002; Karadag et al, 2018). In addition, patients with sarcoidosis can have similarly presenting lesions to those in NLD (Mistry et al, 2017).

### TREATMENT

There are no recognized standard treatment plans for NLD. The evidence currently available is insufficient to give definitive recommendations as regards the systemic treatment of NLD (Dissemond et al, 2018).

An early theory regarding the aetiology of NLD based on experiences within the Mayo clinic in USA was that the causative factor was local lipid disturbance in the skin based on a general disturbance in fat metabolism. Therefore, the suggested treatment was to put the patient on a low-fat diet, however, with hindsight it is not surprising that this did not result in an increase in healing rates (Hildebrand et al, 1940).

Systemic, intralesional and topical application of corticosteroids appear to be the mainstay of treatment for NLD (Guidi et al, 2000). Success has been reported using triamcinolone (an intralesional steroid) applied to modulate the inflammation in the active borders of enlarging lesions (Lima et al, 2017). Non-steroidal anti-inflammatory agents have also been used to modify the inflammatory component of the disease.

The use of immune modulating agents such as Infliximab given intravenously or intralesional can lead to a reduction of pro-inflammatory cytokines levels. Infliximab is a monoclonal antibody antagonist to tumor necrosis factor  $\alpha$  (Kota et al,

2012). Basoulis et al (2015) presented a single case study in which the NLD healed after four monthly sessions of systemic Infliximab. Nevertheless, treatment with immune modulating agents has the potential for serious infections to develop e.g. reactivation of latent tuberculosis, invasive fungal infections and infections by opportunistic pathogens, they also have an association with malignancies (Basoulis et al, 2015). Tacrolimus, a calcineurin inhibitor, and Cyclosporin A have been used in NLD to inhibit interleukin-2 production by T-helper cells preventing T-cell proliferation and thereby suppressing the immune response (Korber and Dissemond, 2007; Kota et al, 2012). Tacrolimus has produced a positive response when used in the early inflammatory phase of the disease by influencing T-cell activation (Stewart, 2006).

A retrospective case series of patients with ulcerated non-healing NLD who were receiving standard wound care, plus weekly applications of bioengineered neonatal human dermal tissue was presented by Rader and Wilson (2013). The metabolically active cells in the human tissue provide collagen I and III, fibronectin, tenascins and glycosaminoglycans and growth factors, which may help to alleviate the collagen degradation at the dermal and subcutaneous tissues in NLD. Additionally, the living cells in the human dermal tissue promote cell proliferation and angiogenesis. During the case review no secondary infections or adverse events were noted. Previous treatment included moist wound healing and topical steroids. The duration to healing improved from 40 weeks to 7 weeks when treated with the human dermal tissue (Rader and Wilson, 2013).

Another treatment evaluated in a small group of patients (15) with recalcitrant NLD was homologous platelet-rich plasma (prp), which is a concentration of human platelets in a small volume of plasma, it is proposed that the treatment will degranulate the  $\alpha$ -granules in platelets and release the growth factors stored within the  $\alpha$ -granules. All patients showed a marked enhancement in wound healing with a mean reduction in lesion size of 79% and no adverse effects were noted (Motolese et al, 2015). Topical becaplermin is a gel containing human-derived growth factor that has been used to treat NLD, presumably by promoting chemotaxis and the proliferation of the cells

involved in wound healing (Kota et al, 2002; Keller, 2018).

Medication used to influence the blood flow in NLD include aspirin which is a cutaneous blood flow enhancer and pentoxifylline which inhibits platelet aggregation and decreases blood viscosity (Kota et al, 2012). Templeton and Caughman (1993) report success in using aspirin and pentoxifylline along with whirlpool therapy, topical corticosteroids and occlusive dressings. Conversely, these treatments were reported as being unsuccessful in a single individual who was subjected to recurrent infections along with NLD. They subsequently responded to a regimen including long term flucloxacillin, topical hydrogel, conservative sharp debridement and 3 layers of tubigrip to provide modified compression therapy. The individual had been non-healing for 18 months, however, after the introduction of the new regimen healed after 28 weeks (Nash et al, 1994). Conservative sharp debridement and compression was employed successfully in another case, this time with the addition of a protease modulating dressing (Stewart, 2006).

A variety of other treatments have been recommended for the treatment of NLD; laser therapy, surgery and grafting, psoralen and ultraviolet A radiation (PUVA), (Chakrabaty et al, 2002; Stewart, 2006; Mazur et al, 2011; Kota et al, 2012).

The proponents of collagen degeneration as the main aetiology of NLD recommend avoiding trauma to prevent the onset of the disease (Scaramuzza et al, 2012; Mitre and Wang, 2016). Whereas blood sugar control may help to reverse hyper-glycaemia-induced microangiopathy (Basoulis et al, 2015). Numerous case reports exist when tight glucose control was part of the treatment regimen, nevertheless this remains a contentious issue (Yigit and Estrada, 2002; Scaramuzza et al, 2012; Bonura et al, 2014; Mitre and Wang, 2016).

## CONCLUSION

Kota et al (2012) refers to NLD as the benign devil which accompanies diabetes. This disease is also found in non-diabetics and referred to as NL.

The disease is said to have three elements; vascular, immune-mediated and collagen



components with debate existing around the influence of each aspect.

The early changes are papules that develop into plaques which then may remain static or eventually develop into intractable non-healing asymptomatic lesions with a predilection for the female population and the pretibial area. The disease is diagnosed by histological findings from a biopsy of the lesion. The course of the disease is unpredictable with recurrence and flare-ups common eventualities.

Myriad treatments have been postulated with corticosteroids and immune modulators being the most commonly used. However, due to the rarity of the disease it has yet to be subjected to rigorous research surrounding the potential treatment regimens. This can lead to the individual with NLD to have an unpredictable chronic situation in which they are subjected to countless treatment regimens, unless they are fortunate enough to achieve spontaneous remission.

WUK

## REFERENCES

- Babin-Muise D, Miller R, Murray S, Walsh N (2012). Necrobiosis lipoidica diabetiformis in a tattoo site. *J Cutan Med Surg* 16(4):286–7
- Basoulis D, Fragiadiki K, Tentolouris N et al (2016) Anti-tnf  $\alpha$  treatment for recalcitrant ulcerative necrobiosis lipoidica diabetiformis: A case report and review of the literature. *Metabolism* 65(4):569–73
- Bonura C, Frontino G, Rigamonti A et al (2014). Necrobiosis lipoidica diabetiformis: A pediatric case report. *Dermato-Endocrinology* 6(1): e983683
- Chakrabarty A, Norman RA, Phillips T J (2002) Cutaneous manifestations of diabetes. *Wounds* 14(8):267–74
- Dissemond J (2012) Necrobiosis lipoidica diabetiformis. *The New England Journal of Medicine*, 366(26):2502
- Dissemond J, Erfurt Berge C et al (2018) Systemic therapies for leg ulcers. *J Dtsch Dermatol Ges* 16(7): 873–90
- Drury MI, Barnes J, Timoney FJ, Keelan DM (1967) Necrobiosis lipoidica diabetiformis. *Irish Journal of Medical Science* 6(500): 379–85
- Du Vivier A (2002) Necrobiosis lipoidica diabetiformis. In: Hodgson S. ed. *Atlas Of Clinical Dermatology* Vol 3 Churchill Livingstone, London: 6, 11, 532, 724
- Gordon H (1937) Necrobiosis lipoidica diabetiformis: Section of dermatology. *Proc R Soc Med* 30(5):527
- Gudi VS, Campbell S, Gould DJ, Marshall R (2000) Squamous cell carcinoma in an area of necrobiosis lipoidica diabetiformis: A case report. *Clinical and Experimental Dermatology* 25(8):597–9
- Hammer E, Lilienthal E, Hofer SE et al (2016) Risk factors for necrobiosis lipoidica in type 1 diabetes mellitus. *Diabet Med* 34(1): 86–92
- Hildebrand AG, Montgomery H, Rynearson EH (1940). Necrobiosis lipoidica diabetiformis. *JAMA Internal Medicine* 66(4): 851–78
- International Diabetes Federation (2017) *IDF Diabetes Atlas, 8th edn*. Brussels, Belgium. <http://www.diabetesatlas.org>
- Jibreal HA, Manoharan H, Weedon D (2017) Necrobiosis lipoidica following qswitched laser tattoo removal. *Australas J Dermatol* 58(4): 268–e27
- Kachan P, Janth D, Sheno S, Sandra A (2001) Necrobiosis lipoidica diabetiformis. *Indian Journal of Dermatology* 46(4): 231–33
- Karadag AS, Ozlu E, Lavery MJ (2018) Cutaneous manifestations of diabetes mellitus and the metabolic syndrome. *Clin Dermatol Rep* 36(1): 89–93
- Keller JJ (2018) Leg ulcers: Expanding the differential. *Curr Dermatol Rep* 7(3): 180–9
- Klaber R (1937) Necrobiosis Lipoidica Diabetiformis. *Journal of the Royal Society of Medicine* 27(713):976
- Körber A, Dissemond J (2007) Necrobiosis lipoidica diabetiformis. *Canadian Medical Association* 177(12):1498
- Kota SK, Jammula S, Kota SK, Meher LK, Modi KD (2012). Necrobiosis lipoidica diabetiformis: A case-based review of literature. *Indian J Endocrinol Metab* 16(4):614–20
- Lima AL, Illing T, Schliemann S, Elsner P (2017) Cutaneous manifestations of diabetes mellitus: A review. *Am J Clin Dermatol* 18(4):541–53
- Mazur MJ, Lowney AC, Prigoff J et al (2011) Resolution of long-standing necrobiosis lipoidica diabetiformis (nld) lesion after restoration of euglycemia following successful pancreas after kidney (pak) transplantation: A case report. *Transplantation Proceedings* 43(9): 3296–8
- McGuinness M, Padhiar N (1997) Necrobiosis lipoidica diabetiformis. *The Foot* 7(1):47–51
- Mistry BD, Alavi A, Ali S, Mistry N (2017) A systematic review of the relationship between glycemic control and necrobiosis lipoidica diabetiformis in patients with diabetes mellitus. *Int J Dermatol* 56(12): 1319–27
- Mitre V, Wang C, Hunt R (2016). Necrobiosis lipoidica. *J Ped* 179:272
- Motolese A, Vignati F, Antelmi A, Saturni V (2015) Effectiveness of platelet-rich plasma in healing necrobiosis lipoidica diabetiformis ulcers. *Clin Exp Dermatol* 40(1):39–41
- Nash JH, Miller LA G., Harding KG (1994) Management of a lesion in a patient with necrobiosis lipoidica diabetiformis. *J Wound Care* 3(8): 363–4
- Phillips T (2003) Diagnostic dilemmas: Necrobiosis lipoidica. *Wounds*, 15(2):59–63
- Rader AJ, Wilson M (2013) Bioengineered human dermal tissue grafting of necrobiosis lipoidica diabetiformis ulcerations: A case series. *Wounds* 25(11):310–2
- Santos S, Ceryno I, Sandes L et al (2013). Necrobiosis lipoidica. *JAAD* 68(4): AB55
- Scaramuzza A, Macedoni M, Tadini GL et al (2012). Necrobiosis lipoidica diabetiformis. *Case Rep Pediatr* 152602
- Stewart E (2006) Using a protease-modulating dressing to treat necrobiosis lipoidica diabetiformis. *J Wound Care* 15(2):74–7
- Teclazich F, Kafanas A, Veves A (2011) Cutaneous alterations in diabetes mellitus. *Wounds* 23(7):192–203
- Templeton SF, Caughman SW (1993) Necrobiosis lipoidica diabetiformis. *The New England Journal of Medicine*, 320. doi: 10.1056/NEJM199307293290505
- Wake N, James BA, Fang MD (2006) Necrobiosis lipoidica diabetiformis. *N Engl J Med* 355(18):e20
- Yigit S, Estrada E (2002) Recurrent necrobiosis lipoidica diabetiformis associated with venous insufficiency in an adolescent with poorly controlled type 2 diabetes mellitus. *J Pediatrics* 141(2), 280–282