

## Dealing with anthrax-induced tissue necrosis

Heather Hodgson is Tissue Viability Nurse Specialist; Mary Smith is Staff Nurse, both based at Gartnavel General Hospital, Glasgow

This paper presents the care given to treat the wounds of a male patient who required emergency surgery to debride devitalised tissue after injecting heroin intravenously contaminated with anthrax. It is thought by Dr Colin Ramsay that contaminated heroin or a contaminated cutting agent mixed with the drug may be responsible for anthrax infections (Ramsay, 2010).

Anthrax is caused by *Bacillus anthracis* (Figure 1), a Gram-positive spore-forming bacillus. It occurs when *Bacillus anthracis*' endospores enter the body either through breaks in the skin, ingestion or inhalation. Anthrax characterisation is based upon its original mode of transmission; cutaneous, gastrointestinal and inhalational (World Health Organization [WHO], 2008; Mayo et al, 2010).

Anthrax remains relatively rare, with between 20,000 and 100,000 cases occurring in the world annually (Friedlander, 2000). It is predominantly related to occupational exposure as seen in farmers, veterinarians and people handling wool (Bush et al, 2001). Only a handful of anthrax cases have been seen in Britain in the last ten years. In 2006, a fatal case of inhalation anthrax was reported in the Scottish borders (Cramb, 2009). Ringerz et al (2000) described the first case of systemic anthrax caused by injecting contaminated heroin.

### Case report

A 32-year-old male who was a known intravenous drug user, presented at the A&E department with a 12-hour history of increasing swelling in his left leg and groin. He had purulent discharge from a chronic sinus in his left groin.

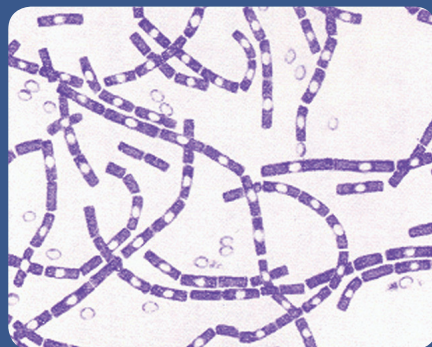


Figure 1. *Bacillus anthracis*.

Blood culture grew Gram-positive organisms suggestive of anthrax and he was referred from A&E to the receiving surgical team for consideration for surgery.

### Surgery

A computer tomography (CT) scan of the patient's abdomen, pelvis and thighs showed loculated fluid and inflammatory change anterior to the left psoas muscle extending down to the iliacus. In the pelvis, the left pectineus and adductor magnus were oedematous, possibly reflecting muscle necrosis. It was decided by the surgical team that the patient required surgical debridement of necrotic tissue in his groin.

Forty-eight hoMurs post surgical debridement, the nurses caring for the patient referred him to the tissue viability nurse specialist (TVN). The TVN assessed the patient and found:

- ▶▶ The limb grossly oedematous
- ▶▶ The wound bed was clean, measuring 300cm<sup>3</sup> (Figure 2).

The wound was still in the inflammatory stage where there is an expectation that exudate will be produced, also there was gross oedema around the wound. Therefore, the TVN decided to apply negative pressure wound therapy (NPWT), as using a conventional dressing would be challenging due to the size of the wound, anatomical location, and the amount of exudate being produced.

### Negative pressure wound therapy (NPWT)

Negative pressure wound therapy is suitable for acute, chronic and traumatic wounds as an adjunct to surgery (Sussman and Bates-Jensen, 2007). NPWT is a non-invasive technology, comprising a negative pressure pump connected by a tube to a dressing (gauze or foam) that fills the wound cavity. The dressing is sealed to the peri-wound skin with an adhesive film. This provides a closed system, so that negative (sub-atmospheric) pressure is generated at the wound/dressing interface.

There are several NPWT medical devices available with two different wound bed interfaces: foam or gauze. Borgquist et al (2009) suggested that less force is required to remove gauze and there is no tissue in-growth into the dressing. They concluded that patients may experience more pain on removal of foam dressings and that the morphology of the wound bed tissue differs under foam and under gauze, i.e. there is a greater degree of leukocyte infiltrate and tissue disorganisation under foam.

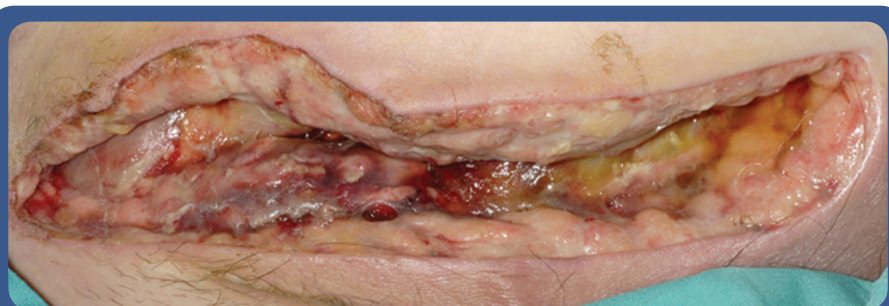

Figure 2. Wound post surgical debridement, 300cm<sup>3</sup>.

NPWT is reported to:

- ▶▶ Remove excess fluid and oedema
- ▶▶ Assist in wound contraction
- ▶▶ Stimulate granulation tissue
- ▶▶ Protect from outside contaminants
- ▶▶ Increase vascular perfusion
- ▶▶ Decrease wound bioburden
- ▶▶ Remodel connective matrix
- ▶▶ Encourage maturation of epithelial cells
- ▶▶ Maintain a moist wound healing environment (Keen and James, 2004)

For this particular patient, all of the above modes of action were relevant because he had a large, open wound which had previously been contaminated and there was copious exudate and surrounding oedema.

A gauze-based interface impregnated with polyhexamethylene biguanide (PHMB), a broad-spectrum antimicrobial, was selected for this patient because the wound was deep, irregular and extensive, and therefore it was felt that the gauze interface would be easier to apply.

NPWT was the only treatment that the patient received for the first 30 days. The dressing was changed three times per week and after week two the patient was discharged into the community to continue his NPWT. On day 30 he was reviewed by the TVN at an outpatient clinic, where the wound bed was found to be healthy with 100% granulation tissue and measured 68cm<sup>3</sup>, a reduction of 77% (Figure 3). Due to the improvement in the wound, it was decided to discontinue NPWT and change to a more conventional dressing, a hydrofiber protease modulator. The patient was discharged into the care of the community team, with no follow up being arranged.

### Conclusion

In this case, NPWT proved both beneficial and cost-effective for managing a large, challenging wound. This treatment was chosen following a thorough holistic

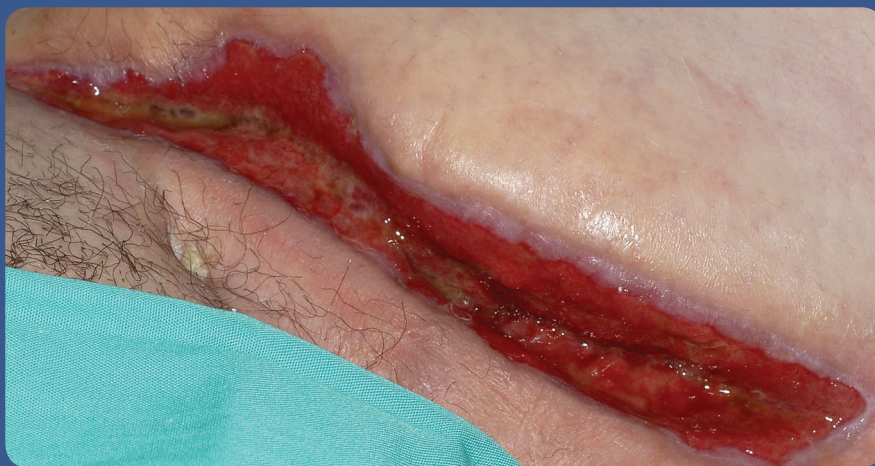

Figure 3. Wound 30 days after being treated with NPWT, 68cm<sup>3</sup>.

assessment of the patient. It is important that all treatment decisions are based on such an assessment, with dressing selection being underpinned by clinical expertise and in-depth knowledge of the treatment modality being used. Failure to do so, could compromise the patient and lead to ineffective, costly care (Keen and James, 2004; Baranoski, 2005; Buckley et al, 2005; Hodgson, 2010). **WUK**

### References

- Baranoski S (2005) Wound dressings: a myriad of challenging decisions. *Home Healthcare Nurse* 23(5): 307–17
- Buckley K, Tran B, Adelson L, Agazio J, Halstead L (2005) The use of Digital Images in Evaluating Homecare Nurses' Knowledge of Wound Assessment J WOCN Set/Oct
- Borgquist O, Gustafsson L, Ingemansson R, Malmsjo (2009) Tissue ingrowth into foam but not into gauze during negative pressure wound therapy. *Wounds* 21(11): 302–9
- Bush LM, Abrams BH, Beall A, Johnson CC (2001) Index case of fatal inhalation anthrax due to bioterrorism in the united states. *N Engl J Med* 345(22): 1607–10
- Chariker ME, Jeter KF, Tintle TE (1989) Effective management of incisional and cutaneous fistulae with closed suction wound drainage. *Contemp Surg* 34: 59–63
- Cramb, A (2009) First British anthrax death in 30 years due to 'freak circumstances'. [online]. Available online at: [www.telegraph.co.uk/health/healthnews/4527107/First-British-anthrax-death-in-30-years-due-to-freak-circumstances.html](http://www.telegraph.co.uk/health/healthnews/4527107/First-British-anthrax-death-in-30-years-due-to-freak-circumstances.html).
- Friedlander AM (2000) Anthrax: clinical features, pathogenesis, and potential biological warfare threat. In: Remington JS, Swartz MN, eds. *Current clinical topics in infectious diseases*. Vol 20. Blackwell Science Malden, Mass: 335–49
- Hodgson H (2010) *Working in Partnership to Improve Patient Outcomes*. Oral Presentation at EWMA, Geneva, May 2010
- Keen D, James J (2004) A tool to aid nurses decision making in relation to dressing changes. *Br J Nurs* 13(15): S6–14
- Mayo L, Dionne-Odom J, Talbot EA et al, (2010) Gastrointestinal anthrax after an animal-hide drumming event — New Hampshire and Massachusetts, 2009. *Morbidity Mortality Weekly Report* 59(28): 872–7
- Miller MS, Lowery CA (2005) Negative pressure wound therapy: 'a rose by any other name'. *Russian Ostomy Wound Management* 51(3): 44–9
- Ramsay C (2010) Heroin users warned as anthrax deaths rise. *The Herald*, 6 January. Available online at: [www.heraldscotland.com/news/health/heroin-users-warned-as-anthrax-deaths-rise-1.996586](http://www.heraldscotland.com/news/health/heroin-users-warned-as-anthrax-deaths-rise-1.996586)
- Ringertz SH, Hoiby EA, Jensenius M, et al (2000) Injectional anthrax in a heroin skin-popper. *Lancet* 356(9241): 1574–5
- Sussman C, Bates-Jensen B, eds (2007) *Wound Care: A Collaborative Practice Manual for Health Professionals*. 3rd edn. Wolters Kluwer/lippincott Williams & Wilkins, USA
- World Health Organisation (2008) *Anthrax in Humans and Animals*. 4th edn. WHO, Geneva