

New method for treating hard-to-heal wounds: clinical experience with charged polystyrene microspheres

A new device, charged polystyrene microspheres (CPM), that is applied topically to the wound bed appears to offer hope of wound closure for hard-to-heal wounds, particularly those with exposed bones and tendons. This article presents an evaluation of 54 wounds of different aetiologies that were treated with CPM for an average of 4.5 weeks. 65% achieved significant granulation tissue growth (>75% of the surface of the wound), and 39% achieved complete wound closure, either by natural healing or surgical closure. Charged polystyrene microspheres appear to be a safe and clinically effective treatment option for hard-to-heal wounds.

Jacky Govrin, Kogan Leonid, Elchanan Luger, Jeremy Tamir, Gabriel Zeilig, Raphael Shafir

KEY WORDS

Chronic wounds
Recalcitrant wounds
Exposed bones and ligaments
Granulation tissue
Wound healing

Wound healing is delayed when it fails to 'proceed through an orderly and timely reparative process to produce anatomical and functional integrity' (Lazarus et al, 1994). Some patients with chronic, recalcitrant wounds, including those with exposed bones/tendons, are too debilitated for surgical intervention, or it is otherwise inappropriate due to the wound characteristics, patient

condition or difficulties in rehabilitation, and so the focus shifts from attempting to heal the wound to simply managing it. Enoch (2004) proposes that it is important to acknowledge and appreciate that some wounds will be resistant to all efforts and treatments aimed at healing, either because of the underlying aetiology or because the

There is an unmet need for both clinical and cost-effective wound healing treatments that can improve patients' health and quality of life and reduce concomitant health and social care costs.

'demands of treatment are beyond the patient's physical health, tolerance or stamina'. Failure of a wound to heal is associated with the risk of infection, tissue necrosis, and progressive loss of the soft tissues and skin. In addition, the production of exudate may cause odour and staining, requiring constant local treatment (Boateng et al, 2008). Furthermore, patients with hard-to-heal wounds may experience severe emotional distress as a result of the reduction in their quality of life (QoL), which may have an impact on their family (Baranoski and Ayello, 2008). It has also been observed that such patients create a significant economic burden

on health and social care providers (Augustin and Maier, 2003).

There is an unmet need for both clinical and cost-effective wound healing treatments that can improve patients' health and quality of life and reduce concomitant health and social care costs (Baranoski and Ayello, 2008). As plastic surgeons with a specialist interest in wound healing, the authors are frequently asked to test new wound healing products that appear to promise the world but have little scientific basis, and have achieved regulatory marketing permission on the basis of pre-clinical safety studies and not clinical experience.

This paper presents the authors' clinical experience of the use of charged polystyrene microspheres (CPM) in the first 54 human wounds to be treated with the product.

Materials and methods

Technology

CPM (PolyHeal™, Polyheal Ltd, Yavne, Israel) is a water-based sterile, 0.025% suspension of charged polystyrene microspheres with a size of 5-microns. It is presented as a sterile, single-use bottle, for topical application by direct wetting and is approved for marketing in Europe and Israel. The postulated mechanism of action for this new therapy is based on pre-clinical *in vitro* assays and *in vivo* studies on experimental wounds that show:

Jacky Govrin is Plastic Surgeon, Head Bait Haroefem Medical Center, Haifa, Israel; Kogan Leonid is Head of Plastic Surgery and Burns Unit, Western Galilee Hospital, Nahariya, Israel; Elchanan Luger is Orthopaedic Surgeon, Director of Foot and Ankle Service, Department of Orthopedics, Ichilov Hospital, Tel Aviv Sourasky Medical Center, Tel Aviv, Israel; Jeremy Tamir is FAPWCA, Sheba Medical Center, Plastic Surgery Department, Israel and Susan B Allen Memorial Hospital, El Dorado, Kansas, USA; Gabriel Zeilig is Head of Neurology, Rehabilitation Department, Sheba Medical Center, Israel; Raphael Shafir is Professor of Surgery, Department of Plastic Surgery, Ichilov Hospital, Tel Aviv Sourasky Medical Center, Tel Aviv, Israel

- ▶ Increased cell proliferation rate
- ▶ Enhanced cell migration
- ▶ Activation of membrane-bound enzymatic proteolytic complexes (Ritter et al, 2004).

This suggests that CPM plays an important role in the activation of the 'stuck', chronic wound-healing process (Data on File, Polyheal Ltd, Yavne, Israel). There is evidence to suggest that it is the size and surface properties of the CPM that contribute to the provision of a supportive, healing microenvironment on the wound surface by serving as an additional surface for the attachment and migration of epithelial, endothelial and inflammatory cells (Wu, 1999; Sasaki et al, 2003). Negatively charged microspheres have been shown to increase the secretion of growth factors (GF), such as growth factor-beta 1 which stimulates bone repair in rabbits (Simmons et al, 1996). Additionally, CPM adsorbs to its surface excess proteolytic enzymes such as matrix metalloproteinases (MMPs) and human neutrophil elastase that appear to prevent normal healing.

Population and wound classification

Patients with wounds which had failed to proceed through an orderly and timely reparative process to produce anatomic and functional integrity, or that the authors considered were going to be hard to heal (the average wound had already been treated and was of a duration of 153 weeks) were included in this case series. The wounds had received a variety of other treatments such as: Granuflex™ (ConvaTec Ltd), Milton® (Milton Ltd), Silverol® (Teva), vacuum assisted closure (V.A.C.® Therapy, Kinetic Concepts Inc [KCI]) and a large variety of debriding agents and topical antibiotics, and yet had failed to heal despite appropriate treatment of underlying pathology. The mean wound age was 153 weeks (range 6–1008) and the mean wound size at baseline was 65cm² (range 2.5–250). A significant proportion of the wounds presented (40%) had exposed bone and/or tendon.

Chronic wounds have diverse aetiologies. Mustoe (2004) reports that 'over 90% of all chronic wounds fall into

three categories, venous ulcers, pressure sores and diabetic ulcers', and that their failure to heal reflects a combination of factors common to all wounds rather than a factor unique to each wound type. Given this, the authors felt justified in including hard-to-heal wounds of differing aetiologies in this case series.

The patients in this series were treated at three clinical sites in Israel: Sourasky Medical Center in Tel Aviv and the Western Galilee Regional Hospital in Nahariya as inpatients during the period 1996 to 1998. In 2003 to 2004, the Western Galilee Regional Hospital, Nahariya began to treat outpatients, as did one other centre, Sheba Health Center, Tel Hashomer, Israel. The total number of wounds treated was 54 and all patients were over 18 years of age. The presented data were collected with approval from the ethics committees of each centre and the Israeli Ministry of Health.

Clinical management

All patients received topical treatment with CPM once or twice-daily for up to 12 weeks, or until the wound had completely closed or was adequately prepared for surgical closure, whichever came sooner. In practice, some wounds were treated for as little as three weeks and others were lost to follow-up. The outpatients were taught to apply the treatment themselves. The wounds were first cleansed and observed for signs of infection, maceration and healing. Photographs and acetate tracings of the wound edge were taken at either weekly or bi-weekly intervals. The CPM was applied topically to the wound once-daily by direct wetting and then covered with a gauze pad dressing moistened with PolyHeal and a dry regular dressing (morning treatment). Each evening all dressings, except for the layer containing the PolyHeal preparation, were changed, while the pad contacting the wound was re-moistened with PolyHeal as needed. The patients in the earlier study were hospitalised while the patients in the second study were outpatients who performed the treatment by themselves. Compression was maintained in the case of venous ulcers and off-loading for the diabetic and pressure ulcers.

Adverse intervention experiences were recorded (see the section on 'Safety adverse events' later in this paper). Results of concurrent blood tests for haematology and chemistry parameters were recorded where available. Patients continued to take prescribed medication, and where antibiotics were prescribed during the treatment with CPM, it was recorded.

Patient population

This case series included 54 patients with open wounds of different aetiology, size and duration, that were considered by the authors to be hard to heal. In addition, a high proportion of the wounds (40%, n=22) had exposed bone and/or tendon. Table 1 shows the type and duration of the wounds.

Endpoints

Healing endpoints extracted from the clinical data were complete wound closure, preparation of the wound bed for surgical closure, and granulation tissue in ≥75% of the wound area.

The amount of granulation tissue was defined using a colour scheme described in a previous study (Cohen, 1998). This method is based on a simple and inexpensive eight-grade pocket-size scale, the Granulometer, to facilitate a more precise assessment and to standardise the documentation of wound healing.

Results

Effects of treatment with CPM

The mean treatment duration for all wounds was 4.5 weeks (range 0.5–12 weeks). In this short period, more than 75% granulation tissue coverage was achieved in 35 of the 54 wounds (65%), and overall, wound closure was achieved in 21 of the 54 wounds (39%). Of these, 11 wounds were adequately prepared for successful surgical closure.

Figure 1 shows the achievement of greater than 75% granulation tissue by wound aetiology.

Despite differences in aetiologies, the authors observed a reduction in wound size at the end of the treatment period, facilitated by an increase in the

Table 1

Baseline characteristics of the wounds treated

	Total	Number with exposed tendon	Age of patient (mean years)	Duration of wound (mean weeks)	Wound size pre-treatment with CPM (mean cm ²)
Venous ulcers	15	2	67.1	153.8 (6 to 1008)	65.6 (2.5 to 250)
Diabetic foot ulcers	14	7	67.1	128.8 (2 to 960)	44.0 (0.5 to 112)
Ischaemic ulcers	7	6	62.7	19.1 (3 to 78)	24.4 (1.0 to 100)
Other aetiologies (including post-surgical and traumatic wounds, decubitus ulcers and wounds in immunocompromised patients)	18	7	56.8	48 (2 to)	72.5 (1.4 to 640)
All	54	22	63.1	94.8 (2 to 1008)	57.2 (0.5 to 640)

percentage of granulation tissue. One encouraging observation was that about half of the wounds showed a 95–100% reduction in size. Just under a quarter (22%) showed a reduction in size of 25% or less. A small number of wounds (n=5) increased in size (range 31–98%). *Figure 2* shows the reduction in wound size by wound aetiology.

When considering the sub-population of wounds with exposed bone and tendon, similarly encouraging results were seen. The majority of wounds in this category had been present for at least 13 weeks, had slightly smaller surface area (mean 30cm²) and received slightly longer

mean treatment with CPM (5.0 weeks). Of these wounds, 68% achieved >75% granulation growth, almost half of them (10 out of 22 wounds) achieved complete closure, and only four of the 22 wounds failed to achieve greater than a 25% reduction in wound size. *Figure 3* shows the percentage of wounds achieving complete closure after application of CPM.

The following case reports illustrate these results.

Case 1: wound with exposed bone

A 72-year-old male with type 2 diabetes and peripheral vascular disease was referred to the authors by the vascular

surgery department of Sourasky Medical Center, Tel Aviv with an ulcer over the medial malleolus of his left ankle. The lesion had been present for nine weeks before starting treatment with CPM. Previous treatment had included Granuflex® dressings (ConvaTec) and surgical debridement as an inpatient. Photographs were taken of the wound at day 1 before the first application of CPM, and at days 5 and 30 of treatment. The wound progressively developed more granulation tissue and was sufficiently prepared for skin grafting at day 30, which was successful (*Figures 4–7*).

Case 2: chronic wound

A 51-year-old female who was a heavy smoker, with unstable insulin-dependent diabetes presented with two *necrobiosis lipoidica diabetorum* (NLD) ulcers on the calf of each leg (*Figure 8*). NLD is a degenerative disease of collagen in the dermis of patients with diabetes. One-third of these lesions may progress to ulcers and management of these wounds is often difficult (Remes and Ronnema, 1999; Moreno-Arias et al, 2001; Nguyen et al, 2002).

The ulcers had been present for 20 weeks and had been treated with topical antibiotics and corticosteroid agents before starting treatment with CPM as an outpatient. The CPM was applied by the patient herself at home twice-daily for seven weeks and resulted in complete closure of three out of four ulcers (*Figure 9*).

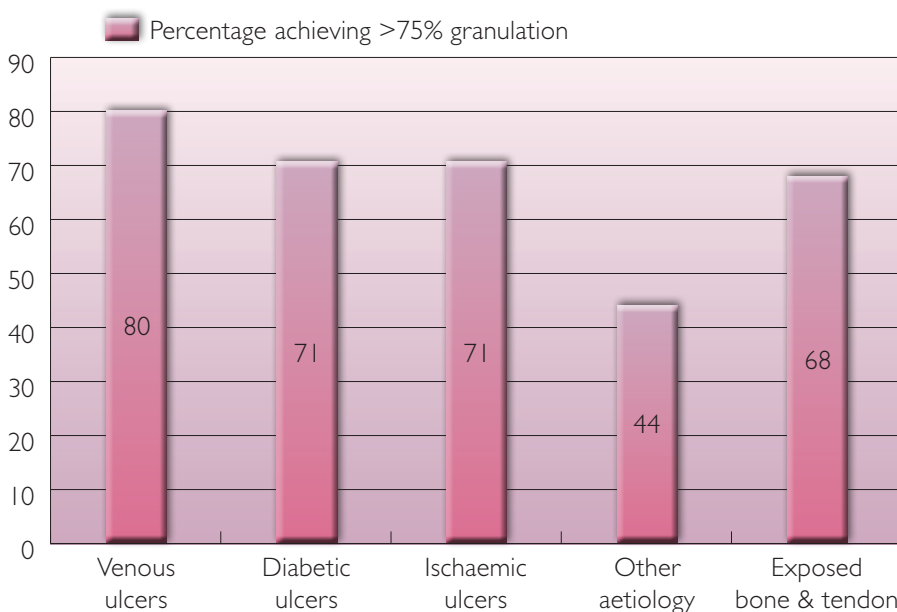


Figure 1. Achievement of >75% granulation tissue by wound type.

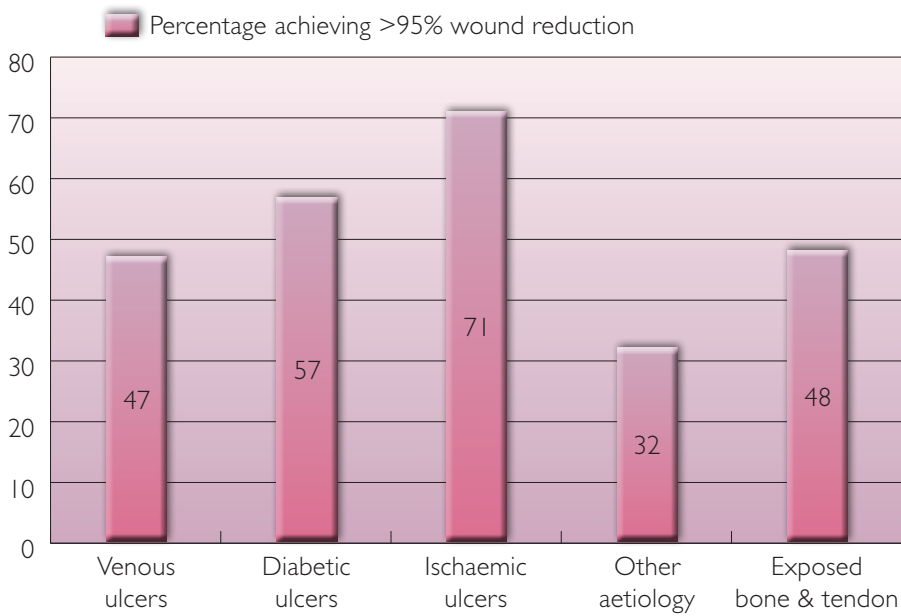


Figure 2. Achievement of >95% reduction in wound size by wound type.

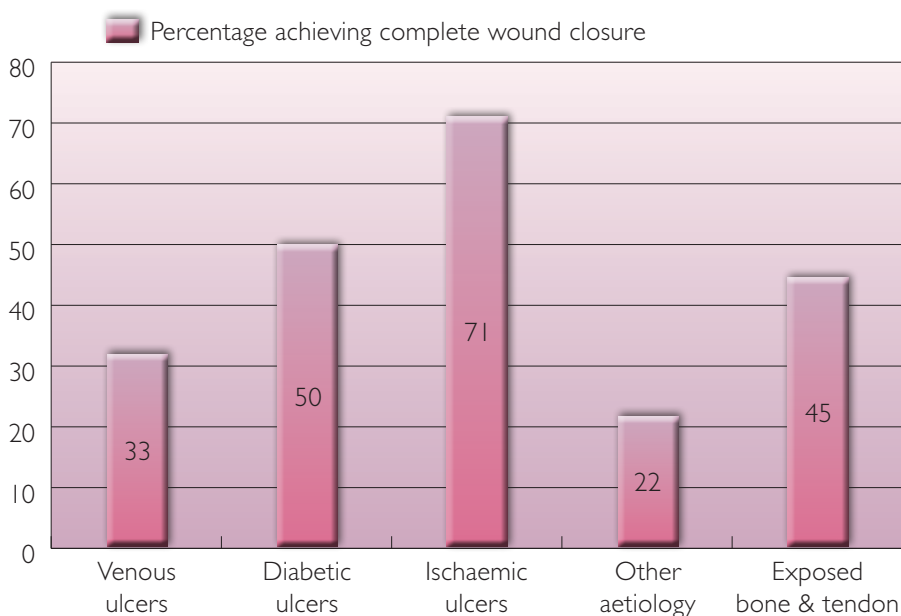


Figure 3. Complete closure by wound type.

Safety

As with any new product, safety is a major consideration. Any adverse experiences that were reported during treatment with CPM were recorded in the patient notes. Details of the duration and nature of the event and its likely relationship to the CPM were recorded. Pain was the most commonly reported symptom by six out of 54 patients. Early on in the authors' clinical use of CPM, treatment in two patients was interrupted because of the reported pain. As the authors' experience of the product grew, it became clear that the pain was associated with the wound

and not the dressing. Thus, when pain was reported by subsequent patients, application of CPM was continued. The reported pain was transient, sometimes 'burning' but disappeared spontaneously as healing progressed. In five patients, the wounds increased in size during the treatment period. Two of these wounds were venous ulcers, and there was one in each of the other categories. There are many reasons why a wound might deteriorate, but it is most commonly due to poor control of the underlying pathology or overt infection. As no wound infection was observed during the treatment

time with CPM, the assumption is that the increase in wound size was not a consequence of treatment. Overall, no serious adverse events were encountered.

Studies have shown that polystyrene microspheres have no adverse biological effects, and there are no known impurities or degradation products associated with the microspheres (Gesler and Garvin, 1973; Menei et al, 1994; Hesterberg et al, 1996).

Safety adverse events

Throughout the studies, safety was monitored by recording the type and

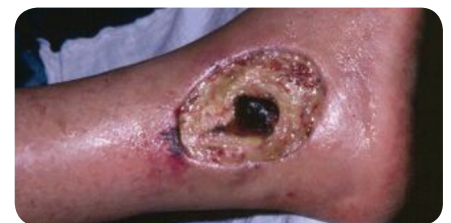

Figure 4. Case 1, day 0.

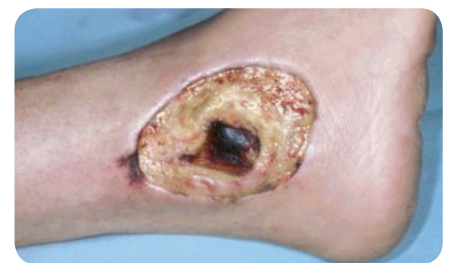

Figure 5. Case 1, day 5.

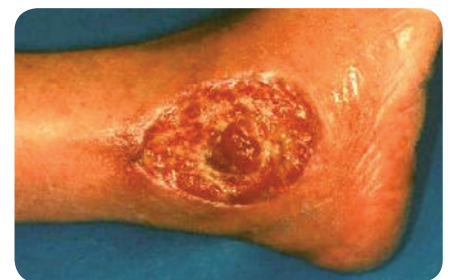

Figure 6. Case 1, day 18.

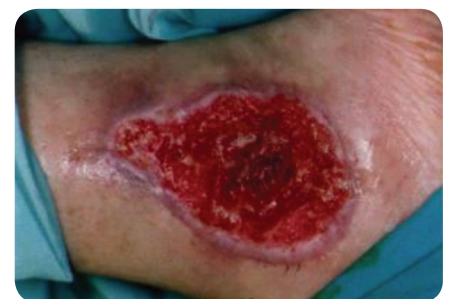

Figure 7. Case 1, day 30.

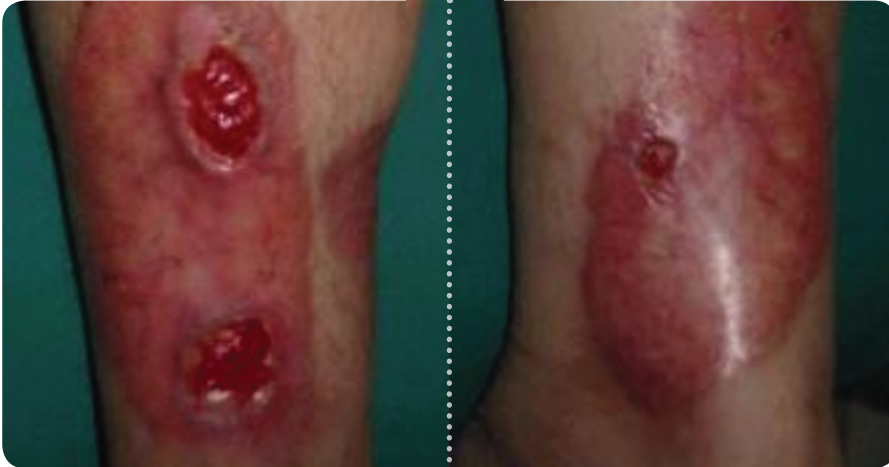

Figure 8. Case 2, Right and left legs, day 0.

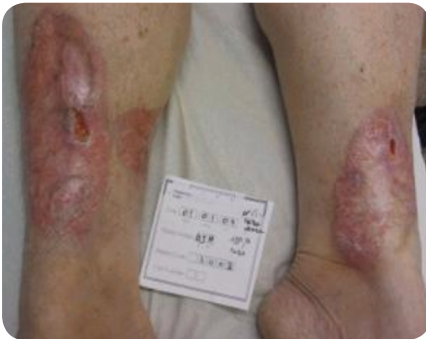

Figure 9. Case 2, day 49.

duration of adverse events and their chronological association to the treatment period.

The most common symptom reported was itching and pain. The authors felt that itching was probably related to the healing process and no cases required interruption of the treatment or specific therapy.

Pain is a common symptom in chronic wound patients, who often report pain as a dominant aspect of their lives (Krasner, 1998). Six out of ten venous leg ulcer patients experience pain with their ulcer, and similar trends are observed for other chronic wounds (Krasner, 1998).

Treatment with CPM was interrupted due to pain in 3% of the patients who were treated at the beginning of the clinical experience, but in patients treated later, it was clearly understood that pain was not related to treatment and CPM was continued, leading to successful healing of the lesions. Pain disappeared spontaneously as healing progressed.

Cellulitis occurred in 5% of the patients, all of which resolved with antibiotic medication. Hypergranulation at the wound bed was reported in 2% of patients and treatment was consequently stopped. The patients' wounds were debrided and follow-up was continued. Following this observation, it was recommended that clinicians and their patients should be cautioned to stop CPM treatment once granulation tissue reaches the wound surface.

These results demonstrate that treatment with CPM is safe, as no significant, systemic or unexpected reactions were seen in any of the patients in this evaluation.

Discussion

In the authors' experience, application of CPM appears to trigger a synchronised series of events that reverses the inflammatory process, shifting the wound from the inflammatory phase to the proliferative phase. As mentioned, the explanation for this beneficial effect is still putative and basic scientific research continues by Polyheal Ltd.

This theory is borne out by the clinical observations in this case series. Accelerating granulation tissue growth to more than 75% of the wound surface is a good indicator that the wound is in the proliferative phase. Granulation tissue is an essential pre-requisite for re-epithelialisation, and preparation of the wound bed in this way facilitates surgical closure (Enoch, 2004). A decrease in wound size is also a good predictor that

the wound is healing, as epithelialisation starts at the wound edges. In wounds with exposed bone and tendon, the effect of CPM was significant and surprising as such wounds rarely respond to treatment (Brandt et al, 2008; Chen et al, 2010), with half of the wounds achieving full closure during the period of observation.

Taken by itself, an increase in granulation tissue would not be seen as primary evidence of clinical efficacy *per se*, as it is only a measure of partial healing to demonstrate that relevant biological activity is occurring (FDA Clinical Focus Group, 2001). However, when considered alongside the time to achieve this endpoint (in this series an average of 4.2 weeks), a reduction in the overall size of the wound and the number of wounds achieving complete closure, it is supportive of the hypothesis that CPM has a beneficial clinical effect on hard-to-heal wounds.

Limitations of this case series

The results presented here are the pragmatic observations of the authors' clinical experience with the new CPM product and, as such, there is no control of confounders and bias. As with all case series, the authors are relying on their clinical experience and intuition to draw conclusions and not on controlled, comparative data. Inherent in this approach is a wide range of wound size and duration before treatment, and also of aetiologies of wounds that would not be seen in a prospective randomised controlled trial (RCT). This lack of homogeneity would appear to add to the strength of the observations, because despite differences in aetiology and other prognostic healing factors, approximately equivalent healing was seen. As there is no control for bias, there is also the possibility that the treatment effect observed might be overestimated (Guyatt et al, 1993; Levine et al, 1994), although other researchers have found that in comparison to prospective RCTs, the treatment effect size presented in observational studies does not differ significantly (Concato et al, 2000). The benefit of presenting this case series is that it forms the basis of the evidence hierarchy required for any therapeutic intervention, and the results have informed a series of prospective RCTs that will further evaluate the product.

Conclusions

Non-healing or slow healing wounds represent a major health burden and drain on resources, contributing to substantial disability, morbidity and cost. Therefore, availability of clinically and cost-effective tissue repair treatments is essential to improve patient health and quality of life, and reduce healthcare costs.

The diversity of wound types and the treatment outcomes in this evaluation provide clinical evidence that the topical application of CPM is an effective stimulator of the wound healing process in recalcitrant lesions, especially those with exposed bones and tendons. It appears to act as a temporary extracellular matrix scaffold, and stimulates the development and formation of healthy granulation tissue. Due to its perceived clinical benefit, the use of this product should be further investigated in order that its full potential to heal wounds and consequently improve the quality of life of patients with hard-to-heal wounds may be fully realised. **WUK**

References

- Augustin M, Maier K (2003) Psychosomatic aspects of chronic wounds. *Dermatol Psychosom* 4: 5–13
- Baranoski S, Ayello E (2008) *Wound Care Essentials. Practice Principles*. Lippincott Williams & Wilkins
- Boateng JS, Matthews M, Stevens H, Eccleston G (2008) Wound healing dressings and drug delivery systems: a review. *J Pharmaceutical Sci* 97(8): 2892–2923
- Brandi C, Grimaldi L, Nisi G, et al (2008) Treatment with vacuum-assisted closure and cryo-preserved homologous de-epidermalised dermis of complex traumas to the lower limbs with loss of substance, and bones and tendons exposure. *J Plast Reconstr Anesthet Surg* 61(12): 1507–11
- Chen X, Chen H, Zhang G (2010) Management of wounds with exposed bone structures using an artificial dermis and skin grafting technique. *J Plast Reconstr Anesthet Surg* 63(6): e512–8
- Cohen M (1998) The granulometer: a pocket scale for the assessment of wound healing. *Ann Plast Surg* 40(6): 641–5
- Concato J, Shah N, Horwitz RI (2000) Randomized, controlled trials, observational studies, and the hierarchy of research designs. *N Engl J Med* 342: 1887–94
- Cooper R (2004) The contribution of microbial virulence to wound infection. In White R, ed. *Trends in Wound Care*, vol III. Quay Books, Salisbury
- Enoch S (2004) Should alternative endpoints be considered to evaluate outcomes on chronic recalcitrant wounds? World Wide Wounds. Available online at: www.worldwidewounds.com/2004/october/Enoch-Part2/Alternative-Endpoints-To-Healing.html
- FDA Clinical Focus Group (2001) Guidance for industry: Chronic cutaneous ulcer and burn wounds — developing products for treatment. *Wound Rep Regen* 9(4): 258–68
- Gesler RM, Garvin PJ (1973) The biologic effects of polystyrene latex particles administered intravenously to rats — a collaborative study. *Bull Parenteral Drug Assoc* 27: 101–13
- Guyatt GH, Sackett DL, Cook DJ, for the Evidence-Based Medicine Working Group (1993) Users' guides to the medical literature, II: how to use an article about therapy or prevention, part A: are the results of the study valid? *JAMA* 270: 2598–601
- Hesterberg TW, McConnel EE, Cevalier J, et al (1996) Use of lung toxicity and lung particle clearance to estimate the maximum tolerated dose (MTD) for a fiber glass chronic inhalation study in the rat. *Fundam Appl Toxicol* 32: 31–41
- Krasner D (1998) Painful venous ulcers: themes and stories about living with the pain and suffering. *J Wound Ostomy Continence Nurs* 25(3): 158–68
- Lazarus GS, Cooper DM, Knighton DR, et al (1994) Definitions and guidelines for the assessment of wounds and evaluation of healing. *Arch Dermatol* 130: 489–93
- Levine M, Walter S, Lee H, et al, for the Evidence-Based Medicine Working Group (1994) Users' guides to the medical literature, IV: how to use an article about harm. *JAMA* 271: 1615–19
- Menei P, Croue A, Daniel V, et al (1994) Fate and biocompatibility of three types of microspheres implanted into the brain. *J Biomed Material Res* 28: 1079–85
- Moreno-Arias GA, Camps-Fresneda A (2001) Necrobiosis lipoidica diabetorum treated with the pulsed dye laser. *J Cosmet Laser Ther* 3(3): 143–6
- Mustoe T (2004) Understanding chronic wounds: a unifying hypothesis on their pathogenesis and implications for therapy. *Am J Surg* 187(5): S65–S70
- Nguyen K, Washenik K, Shupack J (2002) Necrobiosis lipoidica diabetorum treated with chloroquine. *J Am Acad Dermatol* 46(2): S34–S36
- Phillips TJ, Machado F, Trout R, et al (2000) Prognostic indicators in venous ulcers. *J Am Acad Derm* 43(4): 627–30
- Remes K, Ronnema TJ (1999) Healing of chronic leg ulcers in diabetic necrobiosis lipoidica with local granulocyte-macrophage colony stimulating factor treatment. *Diabetes Complications* 13(2): 115–8
- Ritter VM, Rosenblat G, Maretski SH, et al (2004) The role of PolyHeal microspheres in wound healing in patients with chronic ulcers. Available online at: www.polyheal.co.il/?categoryId=17680#1
- Sasaki A, Mueller RV, Xi G, et al (2003) Mast cells: an unexpected finding in the modulation of cutaneous wound repair by charged beads. *Plast Reconstr Surg* 111(4): 1446–53
- Simmons DJ, Phillips LG, Robson MC (1996) Negatively charged beads and transforming growth factor-1 stimulate bone repair in rabbits. *Wound Rep Regen* 4(3): 368–73
- Timmons J (2006) Skin function and wound healing physiology. *Wound Essentials* 1: 8–17
- Wu L, Mockros NE, Casperson ME, et al (1999) Effects of electrically charged particles in enhancement of rat wound healing. *J Surg Res* 85(1): 43–50

Key points

- ▶▶ There is an unmet need for both clinical and cost-effective wound healing treatments that can improve patients' health and quality of life and reduce concomitant health and social care costs.
- ▶▶ This case series included 54 patients with open wounds of different aetiology, size and duration, that were considered by the authors to be hard to heal.
- ▶▶ The results presented here are the pragmatic observations of the authors' clinical experience with the new CPM product and, as such, there is no control of confounders and bias.
- ▶▶ The diversity of wound types and the treatment outcomes in this evaluation provide clinical evidence that the topical application of CPM is an effective stimulator of the wound healing process in recalcitrant lesions.

colony stimulating factor treatment. *Diabetes Complications* 13(2): 115–8

Ritter VM, Rosenblat G, Maretski SH, et al (2004) The role of PolyHeal microspheres in wound healing in patients with chronic ulcers. Available online at: www.polyheal.co.il/?categoryId=17680#1

Sasaki A, Mueller RV, Xi G, et al (2003) Mast cells: an unexpected finding in the modulation of cutaneous wound repair by charged beads. *Plast Reconstr Surg* 111(4): 1446–53

Simmons DJ, Phillips LG, Robson MC (1996) Negatively charged beads and transforming growth factor-1 stimulate bone repair in rabbits. *Wound Rep Regen* 4(3): 368–73

Timmons J (2006) Skin function and wound healing physiology. *Wound Essentials* 1: 8–17

Wu L, Mockros NE, Casperson ME, et al (1999) Effects of electrically charged particles in enhancement of rat wound healing. *J Surg Res* 85(1): 43–50