

The life of a patient with two venous leg ulcers

Sharon Williams, Outpatient Sister, Newmarket Hospital, Suffolk Community Healthcare

Quality of life is a concept that has always been important in the wound care environment, and one which is gaining in prominence. However, due to the volume of caseloads, nurses do not always have the time to stay and talk with patients to gain a true understanding of their concerns. However, it is crucial to assess the impact that a wound can have on the person, as this can delay healing (Cole-King and Harding, 2001; Palfreyman et al, 2007). The following case report describes how a patient lived her life with two longstanding venous leg ulcers, and the impact that these had on her quality of life (QoL).

Case report

Thelma was a 67-year-old female who presented with bilateral leg ulcers. One had been present for two years, and the other for a total of seven years. Thelma was a patient with a complex underlying history, including hip and shoulder replacement surgery, neck surgery, osteoarthritis, warfarin treatment, high blood pressure and cholesterol. Thelma was also a full-time carer for her husband.

Impact of non-healing

Thelma had been treated with a variety of dressings and bandages without success. This had a significant social and psychological effect on Thelma, and her self-image had deteriorated. Pain was the first symptom she experienced — being chronic it disrupted all activities of daily life. Her wounds were heavily exuding and leaked badly. Thelma had to wash her bed linen every day and to bear the pain of daily dressing changes. Malodour was another issue which prevented Thelma from going out, as she felt it was too embarrassing. Although she had hoped to go on a holiday with a friend, she knew that while she had

these symptoms it would not happen. Although she loved wearing skirts, since her leg ulcers had appeared she had never felt able to wear one.

Thelma had previously been treated at a leg ulcer clinic, however, a combination of inconsistent bandaging techniques and exudate management resulted in repeated infection which depressed Thelma further. It is well known that non-healing can lead to anxiety and depression (Palfreyman et al, 2007; Cole-King and Harding, 2001), difficulty in performing daily tasks (Walshe, 1995; Franks et al, 2003), and have a negative effect on social life (Walshe, 1995; Franks, 2003; Palfreyman et al, 2007).

The challenges that Thelma faced, included:

- ▶▶ Rebuilding her self-confidence
- ▶▶ Social and psychological issues, she rarely went out and seemed depressed
- ▶▶ Improving her quality of life and pain management
- ▶▶ Wound healing.

They were not improving and affected my whole life. I was in constant pain...

A new treatment for Thelma

Following an appointment with the vascular surgeon, Thelma was referred to an outpatient leg ulcer clinic in February 2009. A silver dressing (UrgoCell® Silver) was used to clear the infection. When the infection was cleared, the nurse decided that it was time to try a new treatment. The wound was chronic (more than four to six weeks' duration) and stuck in the inflammatory phase, suggesting that there was probably a high level of protease enzymes (Tren Grove et al, 1999; White, 2008). This is when Thelma tried UrgoCell® Start (soft-adherent foam dressing with TLC-NOSF providing protease inhibiting properties and designed to rebalance the wound and promote faster healing in chronic wounds [Schmutz et al,

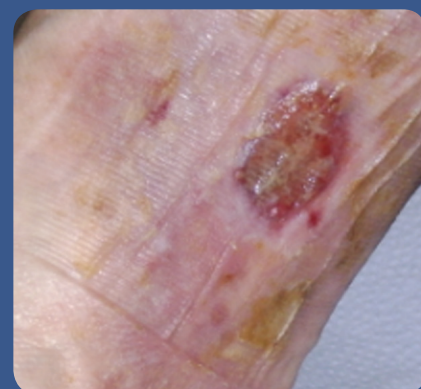

Figure 1. Right leg before treatment.

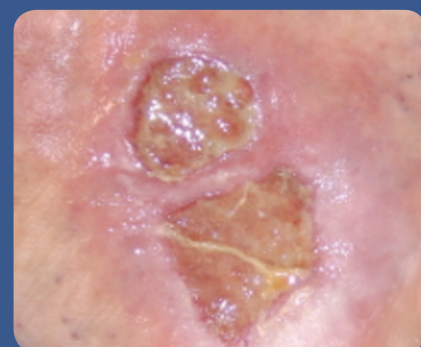

Figure 2. Left leg before treatment.

2008]). The nurse's decision to try this product was based upon clinical evidence available (RCT, observational study involving more than 2,000 patients etc;), supporting its clinical efficacy, pain management and long-term cost-effectiveness.

To treat the underlying venous disease, this treatment was done in combination with KTwo® (Urgo Medical), a two-layer bandage system for venous leg ulcers. Previously, Thelma had been treated with a four-layer compression system and she experienced difficulties in wearing shoes. The new two-layer bandage system enabled her to wear any shoes she wanted, improving her quality of life, as well as maintaining the gold standard pressure required.

Clinical studies have shown that graduated compression is the optimum regimen for venous leg ulcers. However,

when the wound becomes chronic (with a high level of protease enzymes), a combination of compression therapy and protease inhibiting properties are required to rebalance the wound and promote healing.

A life back on track...

Using the weekly treatment of KTwo and UrgoCell Start, Thelma's leg ulcers immediately improved. Dressing changes were initially reduced to twice a week, then once a week. This gave Thelma much more freedom to enjoy life. The exudate had reduced significantly and the periwound skin improved. Thelma found the dressing changes were completely pain-free. Hospital visits and existing medication needs decreased, which was better for Thelma and also cost-effective for the trust. Thelma could see improvement every week. Because the smell had disappeared, Thelma regained her confidence and enjoyed new shopping trips with her friends. After six weeks, her right leg had healed and after eight weeks, the left leg had also healed.

The nurse found the dressing easy to use and apply, easy to remove and exudate was managed well. She also witnessed the improvement in Thelma's quality of life. Thelma's legs are now healed and she is in compression hosiery.

I am so grateful as I can now get on with my life.

The impact

It was shown that venous ulcer improvement quickly and substantially improves all QoL dimensions. Changing the ulcer healing trajectory has an immediate impact on patients' health status, which was totally demonstrated by Thelma's case study.

Discussion

Several studies have been performed to analyse the impact of non-healing on quality of life, especially in venous leg ulcers. Although it includes only one

patient, this case report does reflect the impact in real life and the day-to-day effect of living with a wound.

Conclusion

The good communication between Thelma and her nurse, helped to heal her leg ulcers.

Cost is often an issue when choosing a treatment regimen. The cost of treating a venous leg ulcer without success has major cost implications, for example, in Thelma's case, she had bilateral leg ulcers for seven years. Another comparative case report showed the cost of a year of unsuccessful treatment in a two-year leg ulcer (£9907 or £174 per week of treatment), versus a 16-week treatment (KTwo and UrgoCell Start costing £1329 or £83 per week of treatment), leading to healing as well as a total saving of £7748 (Gardner, 2009). Moreover, as suggested in this article, the implications for the patient are considerable. Nurses need to assess patients and choose the most appropriate treatments. In this case report, correct management and dressing choice appeared to be a cost-effective treatment. **WUK**

References

- Cole-King A, Harding KG (2001) Psychological factors and delayed healing in chronic wounds. *Psychosom Med* 63(2): 216–20
- Franks PJ, McCullagh L, Moffatt CJ (2003) Assessing quality of life in patients with chronic leg ulceration using Medical Outcomes Short Short-36 questionnaire. *Ostomy Wound Management* 49(2): 26–37
- Gardner S (2009) The use of a new two-in-one treatment (K Two Start) in a venous leg ulcer. *Br J Community Nurs* 14(12): S22, S24–25
- Kerihuel JC (2008) Venous leg ulcers regarded as difficult and their impact on QoL: Results of the trajectoire survey. Oral communication, European Wound Management Association Conference, Lisbon
- Palfreyman SJ, Tod AM, King B, Tomlinson D, Brazier JE, Michaels JA (2007) Impact of intravenous drug use on quality of life for patients with venous leg ulcers. *J Adv Nurs* 58(5): 458–67
- Schmutz JL, Meaume S, Fays S, et al (2008) Evaluation of the nano oligosaccharide factor lipido-colloid matrix in the management of venous leg ulcers: results of a randomised controlled trial. *Int Wound J* 5(2): 172–82
- Trengove NJ, Stacey MC, MacAuley S, et al (1999) Analysis of the acute and chronic wound environments: the role of proteases and their inhibitors. *Wound Rep Regen* 7(6): 442–52
- Walshe C (1995) Living with a venous leg ulcer: a descriptive study of patient's experiences. *J Adv Nurs* 22(6): 1092–100
- Walshe C (1995) Living with a venous leg ulcer: a descriptive study of patient's experiences. *J Adv Nurs* 22(6): 1092–100
- White R (2008) Delayed wound healing: in whom, what, when and why? *Primary Health Care* 18(2): 40–6

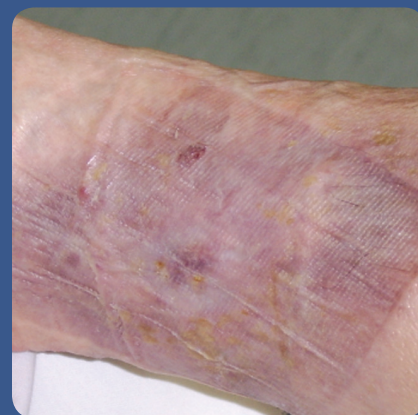


Figure 3. Right leg after six weeks of treatment.

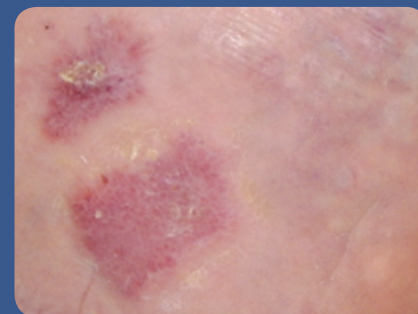


Figure 4. Left leg after eight weeks of treatment.