

NEUROPATHY: GAIT CHANGES IN THE DIABETIC FOOT

Motor neuropathy in patients with diabetes can lead to weakness in the muscles of the foot and lower leg, which in turn can lead to characteristic changes to the structure of the foot, such as an altered arch profile. Such structural changes often occur at sites of abnormally high pressure, which can result in tissue breakdown and ulceration particularly in individuals who also have sensory neuropathy.

Veronica Newton and Caroline McIntosh are Senior Lecturers in Podiatry, Centre for Health and Social Care Research, University of Huddersfield

Peripheral neuropathy is the dysfunction of the peripheral nerves (the nerves that are situated outside the brain and spinal cord), and it is a common problem for many people living with diabetes. Published data has suggested that up to 50% of people with diabetes who present at diabetic foot clinics may have the condition (Edmonds and Foster, 1999).

Peripheral neuropathy can affect many of the body's nerve pathways, including the sensory nerves, autonomic nerves and motor nerves. Loss of sensation, known as sensory neuropathy, is commonly observed in the diabetic foot (because raised levels of circulating glucose in the blood stream can over time permanently interfere with normal nerve function. The typical clinical features include a loss of sensitivity to touch, pain, temperature and vibration.

Common clinical tests that specifically assess sensory loss include monofilaments, for light touch, and tuning forks, for vibration perception. The

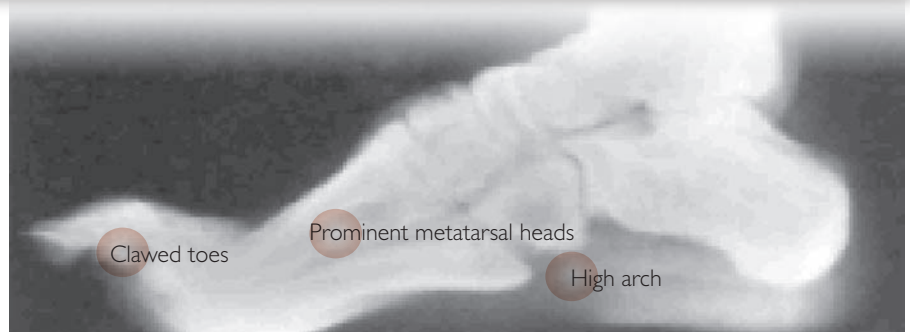


Figure 1. Classic structural change in the foot due to motor neuropathy as seen on X-ray.

10g monofilament (National Institute for Health and Clinical Excellence [NICE], 2004) is a nylon fibre mounted on a hand held wand/pen structure. The fibre compresses at a given force when applied to nominated areas informing the practitioner if the person has the ability to feel

Loss of sensation, known as sensory neuropathy, is commonly observed in the diabetic foot.

pressure/pain. The hand-held 128Hz tuning fork is pinched together at its farthest point and released to generate a vibration. The single end of the fork is then gently applied to the nominated area informing the practitioner if the person has the ability to feel vibration (Baker et al, 2005).

Peripheral neuropathy, which is secondary to diabetes, does not just affect the sensory nerves — it

can affect other nerve pathways, such as the motor pathways that innervate skeletal muscle, and autonomic pathways that innervate smooth muscle in the blood vessels, and is often referred to as a polyneuropathy.

Motor neuropathy

Motor neuropathy can cause wasting of the small muscles of the diabetic foot. This can subsequently lead to characteristic structural changes, including hammer toes, claw toes and prominent metatarsal heads (Figure 1) (van Schie et al, 2004).

When this is coupled with sensory loss, these areas become prime sites of tissue damage (Figure 2) (McIntosh and Newton, 2007). Foot deformities are common sites for abnormally high pressure because of the body weight exerting pressure down on the foot, which in turn is compressed against the hard surface of the sole of the

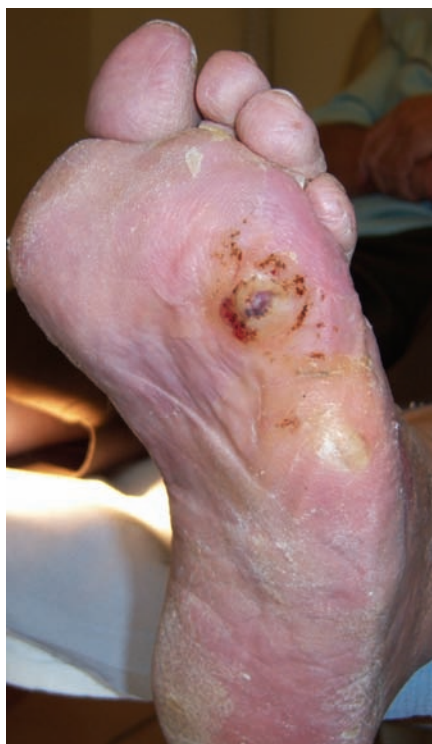

Figure 2. Structural changes with ulceration in a patient with diabetes.

shoe and external floor surfaces, resulting in tissue damage. Repetitive high pressure at sites of deformity can be particularly detrimental for individuals with diabetes as tissue breakdown can occur. Callosities can also develop at sites of high pressure — these can thicken, haemorrhage and eventually ulcerate (Figure 3) (van Schie et al, 2004).

Motor neuropathy and gait

Many of the gait abnormalities recognised in patients with diabetes are a direct consequence of motor neuropathy. Basically, motor neuropathy, or dysfunction of the motor nerves, can lead to wasting of the muscle belly (the fleshy part of the muscle), known as muscle atrophy (Figure 4).

Atrophy of the muscles in the feet can have a profound influence on activities such as walking (gait). Muscle atrophy, dependent on

which muscles are affected, can give rise to an altered arch profile, such as a high arched foot (pes cavus) or low arched foot (pes planus) (Figure 5).

Altered arch profiles can also give rise to areas of high pressure on the foot during walking, which can contribute to abnormally high pressure on the plantar surface (sole of the foot).

Gait changes due to motor neuropathy

Wastage in the muscles of the leg can also have a detrimental effect on a patient's gait. Figure 6 provides a guide to some of the key muscles of the lower limb and their role in the gait cycle.

Proprioception and altered gait

Proprioception is defined as a patient's perception of their body positioning. Impaired proprioception largely occurs due to sensory neuropathy and it can have a detrimental effect on gait.

Patients with impaired proprioception may present with an ataxic (uncoordinated) gait as they will be unaware of the position of their lower limbs and

feet when walking. This can also lead to postural instability, feelings of instability, balance deficits and an increased risk of fall-related injury (Van Deursen and Simoneau, 1999).

Assessment

When undertaking a neurological assessment on a patient with diabetes, it is important to assess the presence of motor neuropathy, particularly if sensory neuropathy is present. The combination of sensory and motor neuropathy can be particularly detrimental and can render the foot vulnerable to deformities and an increased risk of trauma and foot ulceration (van Schie et al, 2004).

A basic assessment of motor neuropathy should include the following measures:

- ▶▶ Observe the patient walking and note any coordination or balance problems. Listen for an audible foot slap, which may indicate atrophy of the tibialis anterior muscle (Figure 6)
- ▶▶ Ask the patient whether they feel unsteady, or have a history of falls/balance problems

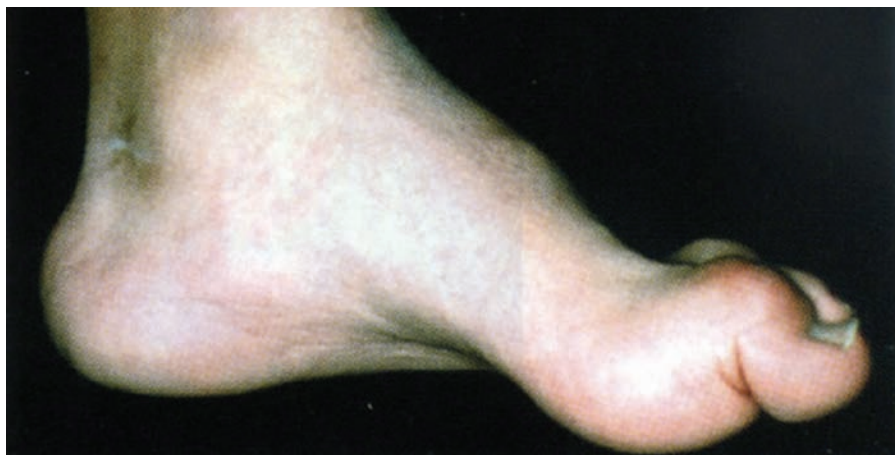

Figure 3. Structural changes to the foot without ulceration in a patient with diabetes. This is a classic image of a deformed high arch foot (pes cavus) affected by motor neuropathy where the muscle bulk in the arch region is much reduced.

- ▶▶ Look for any obvious foot deformities, such as hammer toes, claw toes or prominent metatarsal heads. Ask the patient about the history of the deformities — have they recently developed or have they always been present?
- ▶▶ Compare both of the patient's legs. Are they similar? Is there visible muscle wastage? A simple measurement of limb circumference can be used to compare the two legs
- ▶▶ If the healthcare worker is sufficiently trained in the relevant techniques, he or she should test for knee, ankle and plantar reflexes and conduct muscle power tests. If the healthcare worker is not trained in these techniques, the patient should be referred to a specialist nurse or podiatrist
- ▶▶ Knee reflex — on this test the knee (patellar) tendon is tapped with a reflex hammer with the knee flexed and leg hanging freely. Under normal circumstances once stimulated (tapped) the receptor within the tendon should initiate an involuntary muscle contraction and the practitioner would observe a brief rapid extension of the lower leg — known as the knee reflex
- ▶▶ Ankle reflex — this occurs when the Achilles tendon (at the back of the ankle) is tapped with a reflex hammer while the foot is flexed towards the body (dorsiflexed). A positive result would be the jerking of the foot towards its plantar surface (away from the body)
- ▶▶ Planter reflex — the lateral side (outside) of the sole of the foot is rubbed with a blunt implement (so as not to cause pain, discomfort or injury) from the heel

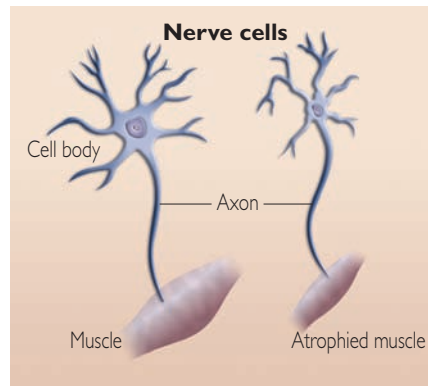


Figure 4. Atrophy (wastage) of the muscle due to motor neuropathy.

along a curve to the ball of the foot. A normal response should be observation of toes flexing inwards

- ▶▶ Muscle power test — muscle power can be defined as work done over a given period of time. The tissues being tested are skeletal tissues. Clinically this can be simply assessed by a person's ability to resist applied force to a given anatomical area.

Knowing when to refer

It is important for healthcare workers to recognise that the management of individuals with motor neuropathy requires a multidisciplinary approach.

Patients who present with a high or low arch profile, or any other foot deformities, should be referred to a podiatrist for assessment. A podiatrist will be able to undertake a biomechanical assessment, including a gait analysis, and prescribe treatment such as orthotic insoles to offload vulnerable pressure areas and minimise the risk of new or recurrent episodes of foot ulceration. Podiatrists may also work closely with orthotists to provide therapeutic footwear, often with extra depth to accommodate any foot deformities.

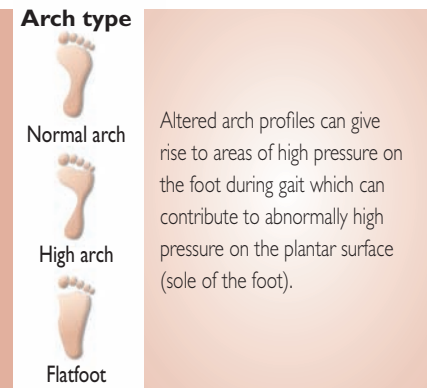


Figure 5. Commonly observed arch profiles of the foot.

It is important to establish glycaemic control when attempting to prevent sensory and motor neuropathy. Gaining glycaemic control means plasma glucose levels of 6–7 mmol/l or HbA_{1c} of 6–7% as recommended by National Service Framework for Diabetes (2001) and NICE guidelines (National Institute for Health and Clinical Excellence, 2004) to prevent the development or deterioration of peripheral neuropathy. Hence figures above or below this represent poor glycaemic control with increased likelihood of developing or accelerating peripheral neuropathy.

There are currently no pharmaceutical therapies that prevent or slow the progression of motor neuropathy (van Schie et al, 2004).

Conclusion

Motor neuropathy in patients with diabetes can lead to weakness in the muscles of the foot and lower leg, which in turn can lead to characteristic changes to the structure of the foot.

Deformities such as hammer toes, clawed toes, prominent metatarsal heads and an altered arch profile are common.


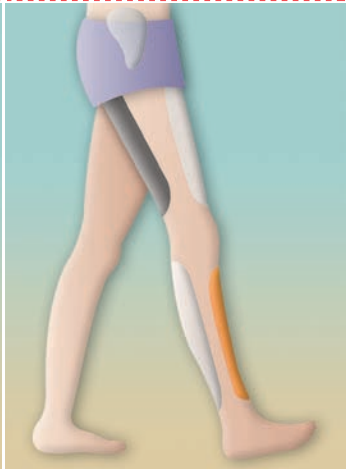
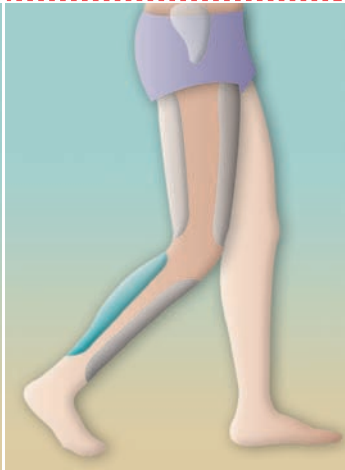
	The gait cycle	Tibialis anterior muscle	Gastrocnemius
			
Action:	The gait cycle consists of initial contact when the heel strikes the ground; this is followed by the forefoot contacting the ground and then toe off to propel the individual onto their next foot step. The muscle groups in the leg and foot are not represented on this figure but are active during different phases of the gait cycle	The tibialis anterior muscle (coloured in orange) on the front of the leg contracts to ease the foot down to the ground during the initial contact of the gait cycle	The gastrocnemius muscle (in blue) on the back of the leg is a very powerful muscle that has a role at the propulsive push off stage of the gait cycle. It assists with lifting the heel from the ground and controllably propelling the body forwards.
Effects of motor neuropathy:	Muscle wastage (atrophy) due to motor neuropathy can result in an altered gait pattern, which can make the foot vulnerable to trauma and ulceration.	If the tibialis anterior muscle is affected by motor neuropathy consequences would be of a rapid uncontrolled foot slap/foot drop during the initial contact period of gait after the heel makes contact with the ground. This would reduce the capacity of the foot to absorb shock.	The clinical consequences of this muscle wasting are reduced muscle strength. This can result in pulling the foot into a high arch position (pes cavus foot type), which would have a reduced ability to absorb shock.

Figure 6. A guide to some of the key muscles of the lower limb and their role in the gait cycle.

Such structural changes are often sites of abnormally high pressure, which can result in tissue breakdown and ulceration, particularly in patients who also have sensory neuropathy.

It is essential, therefore, that healthcare workers consider and assess patients for the presence of motor neuropathy when undertaking routine neurological assessments. If evidence is found, patients should be referred to specialist multidisciplinary teams for further assessment and management to minimise the risk

of new or recurrent episodes of foot ulceration. **WE**

Baker N, Murali-Krishnan S, Rayman G (2005) A user's guide to foot screening. Part 1: Peripheral neuropathy. *Diabetic Foot* 8(1): 28–37

Edmonds M, Foster A (1999) *Managing the Diabetic Foot*. Blackwell Science, Oxford

McIntosh C, Newton V (2007) Diabetic foot ulcers. In: Ousey K, McIntosh C (Eds). *Lower Extremity Wounds: A problem-based approach*. John Wiley and Sons, Chichester: 191–230

National Institute for Health and Clinical Excellence (2004) *Clinical Guidelines for Type 2 Diabetes: Prevention and management of foot problems*. NICE, London

Van Deursen RW, Simoneau GG (1999) Foot and ankle sensory neuropathy, proprioception and postural stability. *J Orthop Sports Phys Ther* 29(12): 718–26

van Schie CHM, Vermigli C, Carrington AL et al (2004) Muscle weakness and foot deformities in diabetes. *Diabetes Care* 27(7): 1668–73