

PILONIDAL SINUSES: AETIOLOGY, AND NURSING MANAGEMENT

A pilonidal sinus is a common surgical problem that occurs in the natal cleft, the area between the cheeks of the buttock. They can be very painful and often affect younger patients, many of whom will present as a surgical emergency. This article considers the aetiology and clinical presentation of pilonidal sinuses and examines the importance of assessment and appropriate wound management.

Jackie Stephen-Haynes is a Consultant Nurse and Senior Lecturer in Tissue Viability for Worcestershire Primary Care Trusts and the University of Worcester

A pilonidal sinus is a common surgical problem that occurs in the natal cleft, the area between the cheeks of the buttock that is frequently the site of hair growth (*Figure 1*). Pilonidal is Latin for nest (nidus) of hairs (pilus) (Miller and Harding, 2003). A pilonidal sinus can be very painful and often affects younger patients, many of whom will present as a surgical emergency. When it requires surgery, the condition can result in a painful wound that may take months to fully heal (Timmons, 2007).

Patients will usually present with either an asymptomatic hair-containing cyst or a large sacrococcygeal abscess with sinus formation (Timmons, 2007). The development of pilonidal sinus is usually acquired or congenital.

A congenital pilonidal sinus develops in patients who have a predisposition to the condition because of a 'dimpling' of the natal cleft. It is thought that these patients have a remnant of the caudal segment of the neural canal. Hair and dead skin cells

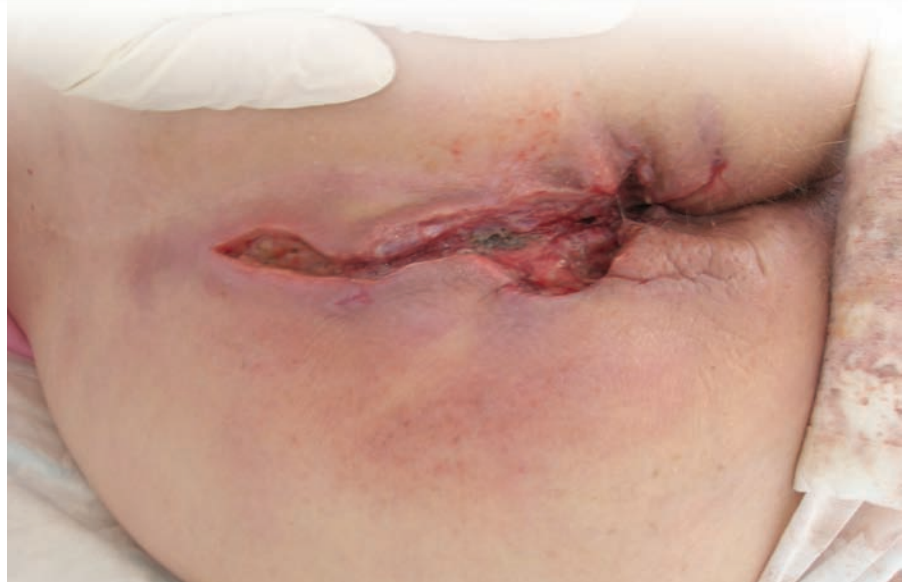

Figure 1. A pilonidal sinus, which has been incised, drained and laid open to allow drainage of exudate.

collect here and result in sinus formation (Timmons, 2007).

Acquired pilonidal sinus often results from an in-growing hair, which leads to the hair follicle

Patients will usually present with either an asymptomatic hair-containing cyst or a large sacrococcygeal abscess

becoming distended with keratin and infected due to the accumulation of hair, cellular debris and bacteria.

Acquired pilonidal sinus may present as a hair-containing cyst

or a sinus and is most commonly seen in males (the male/female ratio is 3:1), ranging in age from puberty to early thirties (Miller and Harding, 2003). It is particularly prevalent in those with thick (usually dark) hair, which can lead to distension of the hair follicle.

Acquired pilonidal sinus is also attributed to the onset of puberty, where the sex hormones act on the pilosebaceous glands in the natal cleft (Bale and Jones, 2000).

Incidence

The incidence of pilonidal sinus is thought to be 26/100,000 (Bradley, 2006), and there

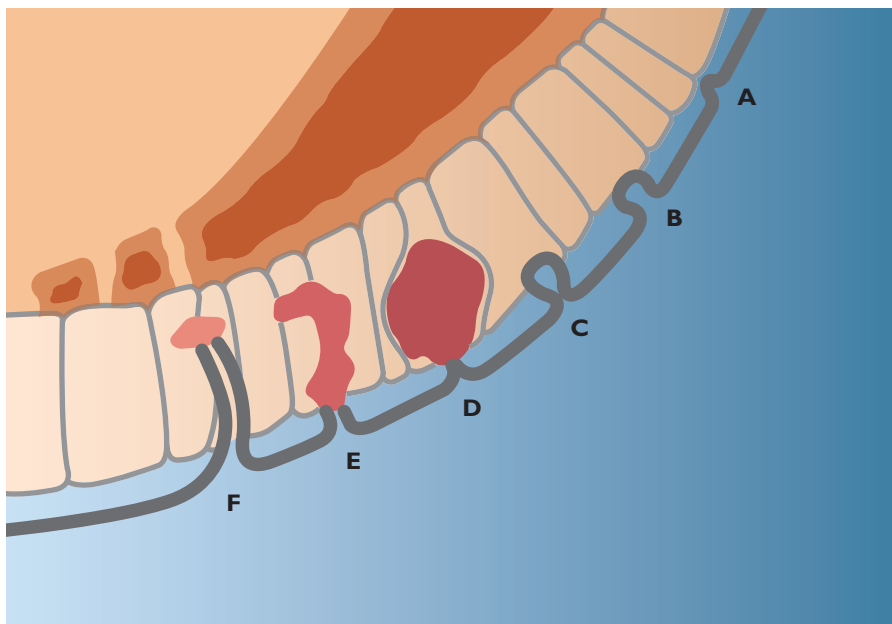


Figure 2. The sequence of events following hair insertion (hair as a secondary invader) and the infected hair follicle theory adapted from Bascom (1980). The stages of pilonidal sinus disease can be seen: a. Normal hair follicle; b. The follicle is distended with keratin, and fibrous strands suspend the follicle and skin from the sacrum; c. The distended follicle is infected and oedema closes the mouth of the follicle; d. The infected follicle ruptures into subcutaneous fat creating an acute pilonidal abscess; e. Chronic pilonidal abscess. The follicle is open at both ends and forms the mouth of the abscess. f. An epithelial tube is formed as epithelium from the end of the ruptured follicle grows down the wall. (Figure taken from Bradley, 2006)

were 12,000 admissions for the condition in the UK in 2001 (Miller and Harding, 2003). Admissions are very often acute and frequently require emergency surgical intervention. This requires expert nursing care as patients are often young and hospitalisation can be unexpected and stressful.

In one study, pilonidal sinus recurred in 22% of patients (n=205), with 71% of these relapsing within four years of the original surgery. However, in more positive cases, the effects of surgery can last for up to 20 years (Doll et al, 2007).

The level of recurrence can be reduced with an injection of non-toxic methylene blue dye into the sinus at the commencement of the operation as this makes it

clearer which tissue needs to be removed (Doll et al, 2008). The use of this dye has been shown to reduce infection rates and it is very likely that this will increasingly become common practice.

Pathophysiology

The sequence of events that leads to the formation of a pilonidal sinus is illustrated in Figure 2. Once a hair follicle starts to become blocked, an inflammatory reaction follows where localised oedema causes the pore to close. This can be assisted by natural movement of the skin (Timmons, 2007). The build up of purulent material eventually creates pressure, which leads to leakage into the surrounding tissues. The hair itself becomes a foreign body, which accentuates the inflammatory response.

The resultant micro-abscesses can become infected with bacteria, which release toxins that destroy tissue in the wound — simultaneously, the area becomes flooded with neutrophils and macrophages as the body's inflammatory response begins (Timmons, 2007). This can result in the area becoming oedematous and this will present as a cellulitis, which can be very painful. The build up of purulent material can result in it leaking onto the surface of the skin.

Eventually, the follicle and the inflamed tissues can become a chronic abscess, prone to recurrent infection due to the combination of moisture, bacteria, hair and friction (Timmons, 2007).

In rare cases, due to the constant damage and repair cycle, malignancy can result and, although uncommon, it should be considered a potential complication in this patient group.

Predisposing factors

A number of predisposing factors for pilonidal sinus have been identified, including (Sondenaa et al, 1995):

- ▶▶ Family history
- ▶▶ Sedentary lifestyle
- ▶▶ Obesity
- ▶▶ Local irritation before confirmation of the sinus.

Other risk factors include:

- ▶▶ 'Dimpling' of the natal cleft (Chamberlain and Vawter, 1974)
- ▶▶ Hirsutism and endocrine changes (Banerjee, 1999)
- ▶▶ Excess keratin in the hair follicle, increasing the potential for follicle blockage (Bradley, 2006)

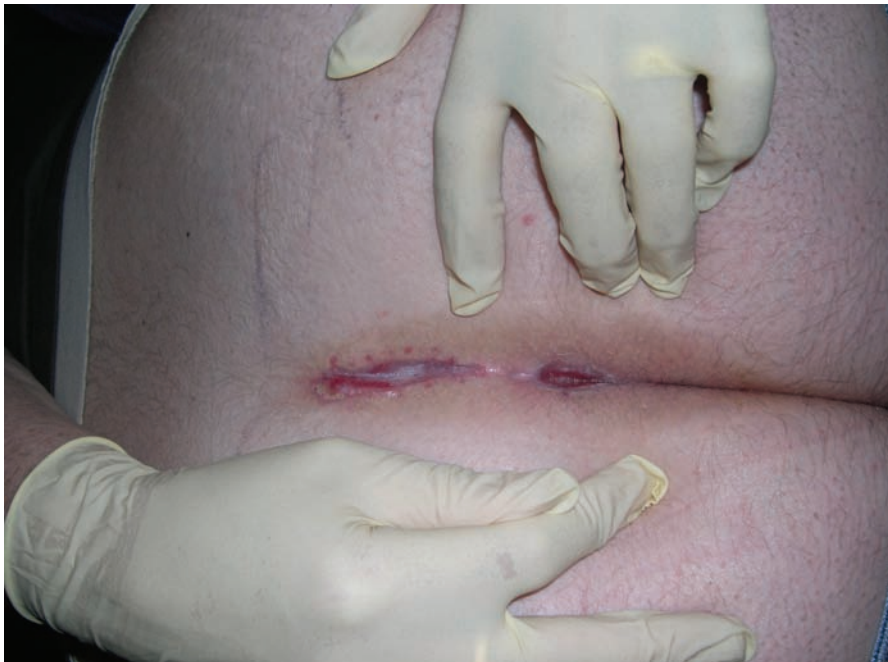

Figure 3. Wound healing 12 weeks post-wide excision.

- ▶ Poor diet and general lifestyle increase the risk of infection.

Clinical presentation

A pilonidal sinus may present in a number of ways, ranging from acute illness with high levels of pain to a painful area in the coccyx region, which like a sebaceous cyst is treated with antibiotics. Frequently, the patient presents with pain, which will vary in severity depending on the size of the abscess and the level of infection. Nurses should be especially aware of patients presenting with a unexplained recurring pain in the coccyx area.

Clinical presentations of pilonidal sinus have four disease 'stages':

- ▶ Asymptomatic — an initial stage pilonidal sinus may be discovered by the patient themselves or on routine medical examination
- ▶ Acute — this will present as a painful, swollen area with a sacrococcygeal abscess,

which may have purulent exudate. There may also be cellulitis over the natal cleft

- ▶ Chronic — this will manifest as recurrent infections in the sacrococcygeal area. The outward skin will be unbroken and oral antibiotics should be prescribed to try to prevent surgical intervention
- ▶ Infected post-operative wound.

Management

There are various management options for pilonidal sinus, depending on the presentation, including:

- ▶ Conservative management — this is considered for patients without severe symptoms. This includes the use of antibiotic therapy to treat infection, avoid sepsis and attempt to prevent the need for surgery
- ▶ Curettage — this can be used for small non-infected sinuses. It may be possible for a doctor or surgeon to remove the hair with a pair of forceps and to clean out the track. Analgesia would be required and it would

only be undertaken by a skilled medical professional

- ▶ Phenol injection — this would be administered into the non-infected pilonidal sinus to sclerose and close it. This procedure requires repeated injections, is uncomfortable and has historically not been linked with good results. More recently, however, Dogru et al (2004) found a recurrence rate as low as 5%
- ▶ Surgical intervention — this involves excision of the affected area, including any abscesses and inflamed tissue and primary closure. Before any surgical management, broad spectrum antibiotics should be administered for patients with cellulitis and purulent discharge (Timmons, 2007). Initially the sinus should be incised and drained of pus to reduce the inflammation. During surgery, the sinus is excised and the wound edges are brought together and sutured. It is important that the abscess is removed in its entirety
- ▶ Wide excision — this involves laying the sinus open and allowing the wound to heal by secondary intention (Figure 3). There is a 58% lower risk of recurrence after open wound healing compared with primary closure (McCallum et al, 2007). However, the wound can take at least 6–8 weeks to heal and the author's experience in clinical practice suggests that it can even take more than six months to heal due to the frequency of infection
- ▶ For those patients who experience recurrent admissions, flap surgery is another option. This involves the formation of a donor

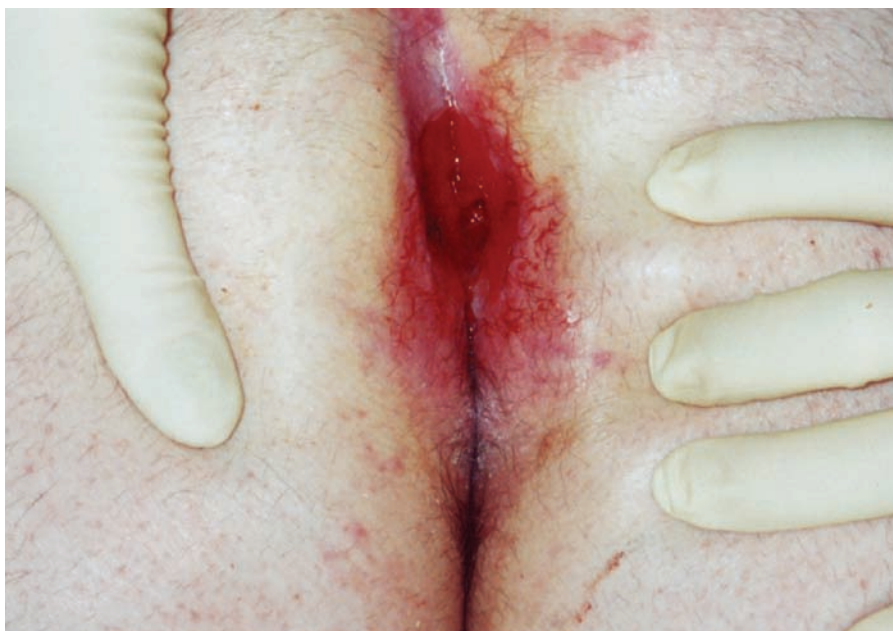

Figure 4. A pilonidal wound 15 months after initial surgery, showing unhealthy granulation and pocketing.

layer of skin and fascia that is applied to the wound site. Because the 'flap' retains its own blood supply it can 'take' readily and reduce the likelihood of recurrence (Timmons, 2007).

Nursing assessment and care

The care of a patient with a post-operative pilonidal sinus should involve a holistic nursing assessment of the wound and the psychological effects on the patient (Bradley, 2006; Timmons, 2007).

On admission, particularly in emergency cases, patients require full assessment including medical and nursing history, vital signs and temperature (this will give an indication of the level of infection) (Timmons, 2007). Pain management is important for patients who have been admitted as emergencies. The following points should be considered in a holistic nursing assessment:

- ▶▶ Any underlying illnesses
- ▶▶ Immune status, including anaemia

- ▶▶ Diabetes
- ▶▶ Nutrition
- ▶▶ Pressure reduction
- ▶▶ Steroid usage.

Psychological care includes a discussion of any treatments, and in the case of surgery the procedure should be properly explained as patients may not be adequately prepared for the depth and size of the wound (Timmons, 2007). Patients may also have fears about altered body image, self-esteem and anxiety in relation to pain. Recurrence and infection should also be discussed.

Pain assessment

Wound-related pain can be very distressing for patients and the strategies that can minimise this trauma have become increasingly recognised as an important element of holistic care. The European Wound Management Association (EWMA) (2002) and other documents (Hollinworth, 2005) propose strategies for assessing,

documenting and managing pain in relation to wound care, including:

- ▶▶ Preventive analgesia
- ▶▶ Explaining any procedures
- ▶▶ Positioning
- ▶▶ Avoiding exposure of the wound
- ▶▶ Time out
- ▶▶ Avoiding draughty, cold rooms
- ▶▶ Soaking the dressing
- ▶▶ Listening to the patient's views in relation to dressing changes.

Appropriate pain relief may range from regular paracetamol to opiates, depending on the severity of the pain, and should be provided on a regular basis to minimise discomfort, particularly post-operatively and at each dressing change.

Consideration should be given to appropriate application and removal of dressings and analgesia should be offered before dressing changes. Entonox may also be used in both the acute and primary care setting.

Treatment

While surgically excised pilonidal sinuses are essentially clean wounds, the location can, however, predispose them to infection (Figure 4) and thorough wound cleansing will be required at every dressing change. In the acute phase, warmed saline can be used or even tap water and a shower head, before the wound is redressed (Bale and Jones, 2000).

For patients recovering from pilonidal sinus surgery, the key aims of wound management are (Timmons, 2007):

- ▶▶ Prevention of infection
- ▶▶ Reducing the risk of recurrence of the sinus

- ▶▶ Promoting healing from the base of the wound
- ▶▶ Swift re-epithelialisation with the best cosmetic result.

Therefore, selecting and utilising the appropriate wound dressings is an important element of care. Initially, wounds which are being left to heal by secondary intention following incision and drainage should be packed with an alginate dressing.

Absorbent dressings, such as alginates or hydrofibres, can be loosely inserted into a wound and are easily removed with warm saline or showering/bathing. These dressings are usually removed daily and can prevent leakage.

Cavity dressings aim to keep the wound edges apart and prevent the development of superficial bridges and dead space in the depths of the wound.

In order to reduce the risk of cross-infection, an occlusive secondary dressing should also be used where possible.

Dressing choices for pilonidal sinus include:

- ▶▶ Foam dressings (such as Cavicare, Smith & Nephew, Hull), take the shape of the wound itself (Timmons, 2007). They can be applied over the cavity, maintaining a good seal and preventing leakage and infection. They can also be inserted into the wound cavity to offer absorption. Foam dressings allow the patient to manage their own wound care at home. They should
- be cleaned twice-daily to remove bacteria and a new dressing is needed every 1–2 weeks depending on the speed of healing
- ▶▶ Capillary action dressings can be applied into a cavity and the outer dressing changed regularly. The dressing lining the wound can stay in place for 2–3 days
- ▶▶ Alginate/hydrofibre dressings can be placed or packed into the wound and offer absorbance and ease of removal. Alginate dressings should be irrigated from the wound to ensure they are fully removed from the cavity and to avoid any residual fibres being left behind (Timmons, 2007). They can last for 3–4 days but may also be changed daily
- ▶▶ Anti-microbial dressings, such as honey, iodine or silver, may be used in those patients whose wounds are critically colonised or at significant risk of infection. These should only be used for a limited time and a conscious decision needs to be made to continue with their treatment rather than just using them indiscriminately
- ▶▶ Topical negative pressure (TNP) therapy can be used for wounds with very high levels of exudate as management with dressings alone can be difficult. TNP works by removing exudate and bacteria from the wound via an electrical pump, which is attached to a suction tube fixated under a hermetically sealed dressing covering the wound (Vowden et al, 2007).

Key Points

- ▶▶ A pilonidal sinus is one that forms in the natal cleft between the cheeks of the buttocks and is often caused by an in-growing hair.
- ▶▶ There were 12,000 admissions in the UK with pilonidal sinus in 2001.
- ▶▶ Predisposing factors are family history, sedentary lifestyle, obesity and local irritation, before confirmation of the sinus.
- ▶▶ Clinical presentation may be asymptomatic, acute or chronic.
- ▶▶ Management involves preventing infection, reducing the risk of recurrence, promoting healing from the base of the wound and encouraging epithelialisation.

Infection

Pilonidal sinus wounds are usually excised when they are infected and it is therefore possible that some organisms may still be present in the wound despite extensive surgery. Curettage offers the most effective method of removal of dead tissue, but as stated above, this can only be performed by an expert medical practitioner (Timmons, 2007).

Another cause of postoperative infection is the position of the wound and the presence of moisture and aerobic bacteria in the natal cleft area.

Nurses should assess the wound for signs of possible infection, including (Timmons, 2007):

- ▶▶ Purulent discharge
- ▶▶ Excess exudate
- ▶▶ Friable granulation tissue
- ▶▶ Bridging of epithelial tissue across the wound

- ▶▶ A malodourous wound
- ▶▶ Cellulitis
- ▶▶ Excessive pain
- ▶▶ Delayed healing.

It is important to remember, however, that some of these signs may be present in episodes of inflammation during the healing process and this must be taken into account when monitoring the wound for infection.

Scarring

Normal scarring should not be distinct from the surrounding skin and often occurs as a result of remodelling during wound healing. Scars continue to remodel for some time following wound closure and are not fully mature until about two years after the initial injury.

Abnormal scars are formed due to a defect in the wound healing process (Edwards, 2006) and can have both psychological and physical repercussions. Appropriate wound management and good peri-wound care can assist in the prevention of scarring.

Health promotion

The patient should be encouraged to eat a well-balanced healthy diet and drink 1.5 litres of fluid each day to try to prevent infection. Patients should be encouraged to reduce or stop smoking as this delays healing.

Cleansing the wound and peri-wound area should be encouraged and patients should be advised to take particular care with their personal hygiene as the area

can very easily be contaminated with faecal matter.

Conclusion

The care of a patient with pilonidal sinus can be complex and challenging, but a systematic approach can yield positive results in the assessment and management of these wounds.

The principles of providing care for surgical wounds are complicated by the significant risk of recurrence and infection, both of which can cause concern to the patient. Psychological as well as physical nursing care is important if the wound is to heal adequately. **WE**

Bale S, Jones V (2000) Wound Care Nursing. *A Patient Centred Approach*. Balliere Tindall, London

Banerjee D (1999) The aetiology and management of pilonidal sinus. *J Wound Care* **8(6)**: 309–10

Bascom J (1980) Pilonidal disease: origin from follicles of hairs and results of follicle removal as treatment. *Surgery* **May**: 567–72

Bradley L (2006) Pilonidal sinus disease: A misunderstood problem. *Wounds UK* **2(1)**: 45–53

Chamberlain J, Vawter G (1974) The congenital origin of pilonidal sinus. *J Paediatric Surg* **9(4)**: 441–4

Dogru MD, Carnei C, Aygen E, Girgin M, Topuz O (2004) Pilonidal sinus treated with crystallised phenol: an eight year

experience. *Dis Colon Rectum* **47(11)**: 19

Doll D, Novonty A, Rothe R et al (2008) Methylene Blue halves the long-term recurrence rate in acute pilonidal sinus disease. *Int J Colorectal Dis* **23(2)**: 181–7

Edwards J (2006) Scar management. *Nurs Stand* **25**: 11–15

European Wound Management Association (2002) Position Document. *Pain at Wound Dressing Changes*. MEP, London

Hollinworth H (2005) Pain at wound dressing-related procedures: a template for assessment. www.worldwidewounds.com Last accessed May 2008

McCallum I, King PM, Bruce J (2007) Healing by primary versus secondary intention after surgical treatment for pilonidal sinus. *Cochrane Database of Systematic Reviews* **4**: CD006213

Miller D, Harding K (2003) Pilonidal sinus disease. www.worldwidewounds.com Last accessed May 2008

Sondenaa K, Andersen E, Nesvik I, Soreide J (1995) Patient characteristics and symptoms in chronic pilonidal sinus disease. *Int J Colorectal Dis* **10**: 139–42

Timmons J (2007) Diagnosis, treatment and nursing management of patients with pilonidal sinus disease. *Nurs Stand* **21(52)**: 48–56

Vowden K, Teot L, Vowden P (2007) Selecting topical negative pressure therapy in practice. In: *EWMA Topical Negative Pressure in Wound Management*. EWMA Position Document. EWMA, Brussels