

The use of a new non-adherent silver hydroalginate dressing in the treatment of a patient with a complex leg ulcer

Fiona Russell is Clinical Nurse Specialist, Department of Tissue Viability, NHS Grampian, Aberdeen

Patients often present with complex wounds as a result of the nature of tissue in the wound bed, exudate level and irregular wound edges. With the increase in the number of patients with complex wounds, it is essential that dressings used have both the ability to support wound healing and to reduce pain and trauma at dressing changes (Hollinworth, 2005).

SILVERCEL® Non-Adherent (Systagenix, Gargrave) is a new dressing which has been developed using the antimicrobial silver hydroalginate with an ethylene methyl acrylate (EMA) non-adherent layer. This dressing is ideal for use on infected wounds which have moderate to heavy levels of exudate, and where there may be risk of damage to surrounding skin.

Case report

Past medical history

A 56-year-old male patient with atrial fibrillation was admitted to a Scottish hospital on 5 October 2009 with lower leg cellulitis in one limb. The department of tissue viability was asked to review this patient on 30 October 2009. Before their involvement, the dermatology team had ruled out *Pyoderma gangrenosum*. This had been requested as the patient's wounds had a blue edge, but this may have been due to his taking aspirin twice-daily for his cardiac condition.

First assessment, 30 October 2009

On examination the patient had two large wounds to his left lower limb measuring 15x6cm and a calf wound of 13x9cm (Figures 1 and 2). In the week before review by tissue viability, the dermatology team had started him on a short course of Bactroban® ointment (Glaxo Smith Kline) to cover all skin breaks.

A full Doppler assessment was performed at the initial assessment by the tissue viability team and the ankle brachial pressure index (ABPI) for his left leg was 1.1. As this was within the range for compression (≥ 0.8 – ≤ 1.2), compression options were discussed with the patient. A Silvercel Non-adherent dressing was applied to all moist wounds before application of a K-Four® bandage system

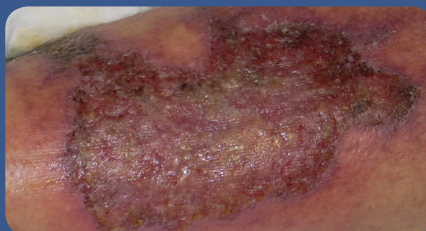


Figure 1. Ulceration to tibial area at first review.

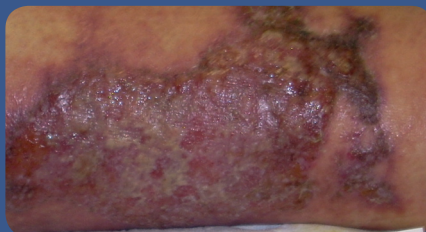


Figure 2. Ulcer on the calf first review.

(Urgo). This dressing was chosen because of its antimicrobial action which helps to reduce wound bioburden (Parsons et al, 2005) and because it is atraumatic on removal. In addition, its absorbent nature assists in protecting the surrounding skin from wound exudate. Under compression bandage systems dressings that retain exudate are needed. Thus, Silvercel Non-Adherent offered a number of benefits in this case.

The Scottish Intercollegiate Guidelines Network (SIGN) 26 leg ulcer protocol is adhered to in Scotland, which involves removing all bandaging within 24 hours and checking pressure areas and the wound bed (SIGN, 1998).

Second assessment, 31 October 2009

On bandage removal and showering of the patient's leg the dressings fell off causing no trauma or adherence to the wound. There was no staining to the leg. There was a significant volume reduction in both the leg and wound exudate (Figures 3 and 4). Silvercel Non-Adherent dressings were re-applied with K-Four bandaging.

Third assessment, 3 November 2009

At third assessment the bandaging system was removed and the skin breaks had almost completely healed (Figures 5 and 6). The wounds were no longer wet. At this stage, the Silvercel Non-Adherent dressings were stopped.

The patient found these dressings comfortable and pain-free on removal, while the clinicians

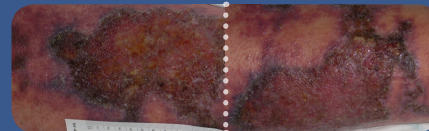


Figure 3. Ulcer on tibia after 24 hours of Silvercel Non-Adherent and compression.

Figure 4. Ulcer on calf after 24 hours of Silvercel Non-Adherent and compression.

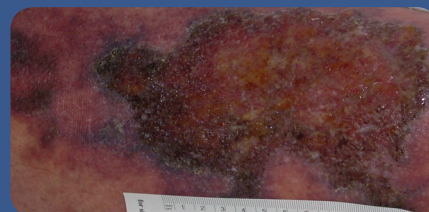


Figure 5. End of treatment with Silvercel Non-Adherent.

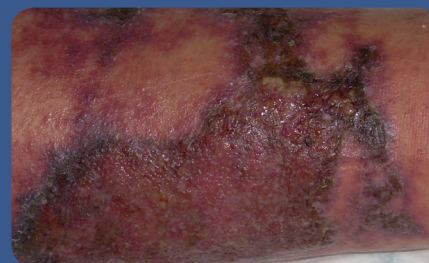

Figure 6. Wound no longer requires topical antimicrobial.

felt that they were easy to apply and remove without staining to the surrounding skin. In addition, no residue from the dressing was left in the wound bed. The dressing's absorbency together with the compression system helped the patient's venous circulation, thus reducing the oedema. The antimicrobial action of the dressing also helped to reduce the wound bioburden and its non-adherent quality proved beneficial both to the patient and to the clinician. **WUK**

References

Hollinworth H (2005) *Pain at wound dressing-related procedures: a template for assessment*. World Wide Wounds, Available online at: www.worldwidewounds.com/2005/august/Hollinworth/Framework-Assessing-Pain-Wound-Dressing-Related.html

Parsons, D Bowler PG, Myles V, Jones, (2005) Silver antimicrobial dressings in wound management: a comparison of antibacterial, physical, and chemical characteristics. *Wounds* 17(8): 222–32

Scottish Intercollegiate Guidelines Network (1998) *The Care of Patients with Chronic Leg Ulcers A National Clinical Guideline*. SIGN, Edinburgh. Available online at: www.sign.ac.uk/pdf/sign26.pdf