

# Fungal foot infection: the hidden enemy?

When discussing tissue viability in the lower limb, much attention is focused on the role of bacterial infection. However, fungal skin infection is a more frequent and more recurrent pathogen which often goes undetected by the practitioner and patient alike. Potentially, untreated fungal foot infection can facilitate secondary problems such as superficial bacterial infections, or, more seriously, lower limb cellulitis. Often simple measures can prevent fungal foot infection and therefore reduce the possibility of complications. This article will review the presentation of tinea pedis and onychomycosis, their effects and management.

Ivan Bristow, Manfred Mak

## KEY WORDS

Fungal  
Tinea pedis  
Onychomycosis  
Cellulitis

**T**inea pedis (athlete's foot) is an inflammatory condition and represents the most common of all the superficial fungal skin infections (Hay, 1993). Predominantly, it is caused by a group of fungi specifically adapted to living on the skin known as dermatophytes. Although there are a few other causative species (Table 1), by far the most common isolate from the foot is *Trichophyton rubrum*, a highly specialised dermatophyte which has adapted to residing within the human epidermis (Weitzman and Summerbell, 1995). The infection is propagated from person to person when fungal arthroconidia on shed skin squames adhere to the soles of others by way of adherent fibrils (Kaufman et al, 2007).

Under occlusive and humid conditions the fungal hyphae then develop and invade the deeper stratum corneum. Nutrition is afforded by the extra-cellular secretion of proteolytic and keratolytic enzymes breaking down the complex keratin into simple molecules which can be absorbed by the organism (Kaufman et al, 2007).

## Epidemiology of fungal foot infection

Fungal foot infection (FFI) is the most common infection found on the foot. Seldom seen before puberty, the prevalence rises with age, peaking in the 60-year plus age group with around 50% showing evidence of FFI (Pierard, 2001). The disease affects males three times more frequently than females (Gupta et al, 1998). The Achilles project (Roseeuw, 1999) reviewed over 96,000 patients for the presence of foot disease across 20 European countries and found 35% of subjects to have fungal foot infection (tinea pedis, onychomycosis or both). In addition it has been shown that countries with longer winters demonstrated higher infection rates, presumably because of the longer time more occlusive footwear was being worn (Djeridane et al, 2006).

Studies focusing on cancer patients, smokers and those with peripheral vascular disease (PVD) (Virgili et al, 1999; Gupta et al, 2000; Sigurgeirsson and Steingrimsen, 2004) have all reported an

increased risk of acquiring the infection. Patients with diabetes show an increased susceptibility (Yosipovitch et al, 1998). Boyko et al (2006) have identified the presence of tinea to be a predictor of foot ulceration in a diabetic population. The reason for an increased prevalence in patients with diabetes remains under-researched. It has been proposed that peripheral neuropathy renders the foot insensate reducing individual awareness to the presence of infection. Eckhard et al (2007) discovered a high prevalence in patients with type 2 diabetes who exhibited a lack of sweating when tested with the Neuropad® (Ark Therapeutics), which indicates sudomotor activity. They postulated that the absence of sweat production altered skin barrier function. *In vitro*, it has been demonstrated that sweat secretions contain acidified nitrite which has fungicidal activities (Weller et al, 2001).

Therefore, it could be suggested that a lack of production may render the individual more susceptible to invasion. The interaction between dermatophytes and the immune system has been studied and it has been demonstrated that *T rubrum* has the ability to inhibit the normal phagocytic process (Campos et al, 2006). Moreover, in patients with diabetes, hyperglycaemia itself has been shown to decrease phagocytic activity further; thus compounding the problem (Weekers et al, 2003).

Ivan Bristow is Lecturer, School of Health Sciences, University of Southampton; Manfred Mak is Podiatrist, Singapore General Hospital, Singapore

### Recognition and diagnosis

Classically, tinea pedis is reported as an acute, itchy infection accompanied by vesiculation and erythema or as interdigital fissuring and maceration. In practice, clinical recognition of the disease can be more difficult due to its subtle appearance. In particular, *T rubrum*, the most common cause of foot infection, may produce few symptoms other than dry plantar skin from which itching is frequently absent (Bristow, 2004; Maysen et al, 2004). Clinically, the infection may resemble dry skin, the only clue being a dry, chalky appearance exaggerated in the skin creases on the sole of the foot (Figure 1); a place typically overlooked when seeking an infection. As there are frequently no symptoms, patients and practitioners alike are unaware of the presence of the infection (Maruyama et al, 2003). The plantar surface is a frequently overlooked area and it has been suggested that this part of the foot, in particular, acts as a fungal reservoir from which the infection can spread (Szepietowski et al, 2006). Consequently, it is important to assess other areas of skin for a co-existing fungal infection. Concomitant dermatophyte infections are particularly common on the hands (tinea manuum), groin (tinea cruris) and fingernails (Szepietowski et al, 2006).

When the disease is established on the foot, the infection may also spread to the toenails causing onychomycosis. Typically, dermatophytes spread under the nail free edge (or hyponychium) onto the nail bed — this is termed 'distal sub-ungual invasion' (Figure 2a) and may gradually spread proximally towards the nail producing cells, the nail matrix. Other common variants are white superficial onychomycosis (Figure 2b), typically caused by *T interdigitale*, and total nail dystrophy (Figure 2c), which occurs when the infection advances to affect the whole of the nail. As approximately 50% of nail dystrophies are due to other causes, it is important to consider the typical nail changes which may raise suspicion of onychomycosis (Table 2). As nail infection is virtually always a secondary event to skin infection, any patient with toenail onychomycosis should have their feet examined for evidence of the primary source, usually the plantar surface (Daniel and Jelinek, 2006).

For most patients, fungal skin infection can be diagnosed on clinical grounds alone. However, if systemic antifungal therapy is being considered, to minimise the risks of potential, although rare, side-effects, microbiological confirmation is advised (Bell-Syer et al, 2002). Diagnosis can be confirmed by way of a nail clipping or skin scraping from the affected foot. Disappointing laboratory results often come back as negative despite overwhelming clinical evidence of infection. A successful sample requires the practitioner to collect viable fungus within the skin/nail sample. Strategies which may help to do this are listed below:

- ▶▶ When taking a nail clipping, if available include skin scrapings from the affected foot as well
- ▶▶ Include sufficient material for the laboratory to work with
- ▶▶ When taking a nail clipping, try and obtain material from the proximal edge of the infected nail as this is where most of the viable fungus is likely to be. Evidence from a study of 194 patients demonstrated that the more proximal the sample collection, the greater the chances of acquiring a positive culture (Shemer et al, 2007). Inclusion of sub-ungual nail debris from this area can also be helpful
- ▶▶ Vertically drilling a hole in the nail and collecting sub-ungual material from the proximal infected edge has been shown to be particularly effective at yielding more viable fungi for culture testing (Shemer et al, 2009)
- ▶▶ As an adjunct or alternative, skin and nail samples may be tested for the presence of dermatophytes using the periodic acid schiff (PAS) stain. A number of studies have confirmed the high sensitivity of this test over more traditional methods such as potassium hydroxide (KOH) preparations (Karimzadegan-Nia et al, 2007; Lawry et al, 2000; Weinberg et al, 2005). However, the PAS stain is a more costly technique (at roughly double the price of a standard KOH test). One study has evaluated the cost-effectiveness of the PAS stain and, despite its high sensitivity, it was not shown to be more cost-effective (Lilly et al, 2006). However, it has been suggested that this test may be useful when other methods have

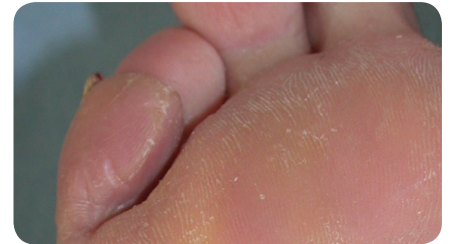

Figure 1. Tinea pedis — as a subtle plantar infection recognised as the dry, dusty appearance.

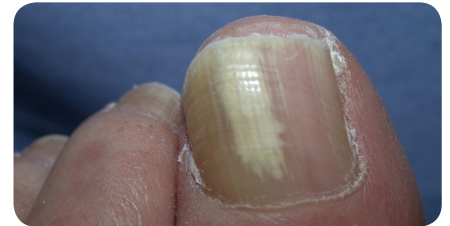


Figure 2a. Distal sub-ungual onychomycosis secondary to tinea pedis. Note the signs of skin infection surrounding the nail.

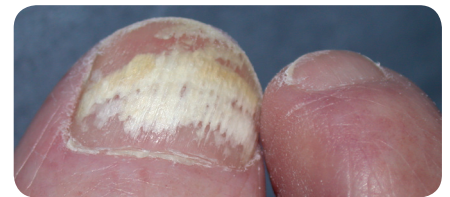

Figure 2b: White superficial onychomycosis.

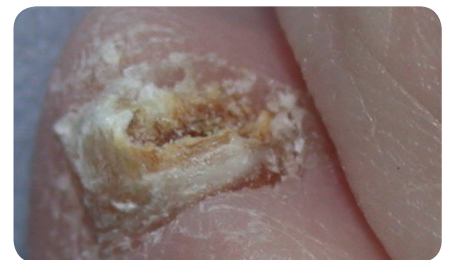

Figure 2c: Total nail dystrophy.

given negative results but clinical suspicion of fungal infection is still high (Weinberg et al, 2005).

### Complications of the untreated disease

For most patients recurrent or chronic FFI is more of an inconvenience than a problem. Rarely is treatment sought, particularly as there are few symptoms for the sufferer and hence this may explain the high prevalence of the disease. Onychomycosis occurs in a subset of patients and may lead to thickening and discolouration of the toe nails. Not only does this lead to embarrassment for the patient (Turner and Testa, 2000), but for older patients it may mean that basic

foot care is difficult. As a result, nails may become long and unmanageable causing injury to the adjacent digits.

Although seemingly innocuous, tinea pedis can potentially compromise tissue viability and render the skin susceptible to fissuring, thereby creating a portal of entry for bacterial agents such as Streptococci, Staphylococci and Pseudomonas. Localised interdigital infections are common and clinically should be suspected when a damp web space is encountered with fissuring, maceration and malodour.

Cellulitis is a more serious consequence of untreated fungal foot infection. Although treatable, it can be a limb-threatening disease for patients with comorbidities. Individuals with diabetes have an increased risk of developing this complication (Jegou et al, 2002). The frequent outcome for this group is hospitalisation and an increased length of stay when compared to their non-diabetic counterparts (Musette et al, 2004). Moreover, bacterial infection is a frequent precursor to lower limb amputation in this population (Lavery et al, 2006).

The link between cellulitis and fungal infection was suggested in 1937 by Traub and Tolmach (Traub and Tolmach, 1937), although only in the last decade has work been undertaken to establish the causality. In 1999, Dupuy et al published a study which identified possible risk factors for the development of lower limb cellulitis (Dupuy et al, 1999). In 167 cases they identified that the presence of a portal of entry carried the greatest risk (odds ratio 23.8), which is not unexpected. However, in this work they highlighted that the presence of a macerated toe web space (intertrigo) may account for as many as 60% of the cases of leg cellulitis. Roujeau et al (2004) undertook a further case-control study of 243 cases to more closely evaluate the role of fungal foot infection in patients with cellulitis. The subsequent results suggested that fungal foot infection was a significant risk factor for the development of cellulitis (odds ratio 2.4), with an increasing risk if more than one area of the foot was infected — toenails, interdigitally or on the sole of the foot. A subsequent review (Bristow and Spruce, 2009) presented evidence

**Table 1**  
Typical fungal isolates from toenails

Dermatophytes	
<i>Trichophyton rubrum</i>	Very common
<i>Trichophyton mentagrophytes var. interdigitale</i>	Very common
<i>Epidermophyton floccosum</i>	Less common
Yeasts	
<i>Candida sp.</i>	Uncommon
Non-dermatophyte molds	
<i>Scopulariosis brevicaulis</i>	Rare
<i>Fusarium sp.</i>	Rare

that fungal foot infection is a predictor for the development of lower limb cellulitis. From the available evidence, the authors note that it was not possible to establish if patients with diabetes were more at risk of this complication, as many diabetic subjects may have been excluded from these studies.

**Management**  
**Tinea pedis**

For most FFI, simple measures are the most effective at treating the disease. For established skin infection, there are a range of topical medicaments available based on effective pharmacological agents. For skin infection there are three main groups of topical agents available in the UK:

- » Allylamines — terbinafine
- » Imidazoles — clotrimazole, ketoconazole, sulconazole, miconazole
- » Morpholine derivatives — amorolfine.

Topical therapy using imidazoles (such as clotrimazole, miconazole) or allylamines (such as terbinafine) have been demonstrated to be more effective than placebo in a systematic review of therapy for fungal skin infection of the foot (Crawford and Hollis, 1999). All have been shown to be effective, but their speed of action may vary. Terbinafine and amorolfine based preparations have a fungicidal action and so tend to work more rapidly when compared to the imidazole based drugs such as clotrimazole and miconazole, which are fungistatic at their respective concentrations. However, when considering costs, the latter are a much

cheaper alternative but must be applied for a longer time raising the possibility of reduced compliance. Terbinafine is a well-established, effective drug available topically for tinea pedis in various forms (Patel et al, 1999; Hollmen et al, 2002), but recently a new single application formulation (film-forming solution) has been released. An early randomised, double blind, multicentre study of 271 patients has shown this to be effective with similar relapse rates to other formulations of the drug (Ortonne et al, 2006).

Patients using topical agents should be given basic advice on preventing

**Table 2**  
Typical considerations suggesting onychomycosis in the toe nails

<b>Number of nails affected:</b>
» Two or more nails affected on the same foot, particularly if only one foot affected
<b>Pattern of the affected nails:</b>
» 3rd and 5th involvement
» 1st and 5th affected simultaneously
<b>Other factors:</b>
» History or close family history of tinea pedis/onychomycosis
» Discolouration of the nails
» Thickening accompanied with friable, crumbly nails

the spread of the disease to family members and be instructed to use the preparation for the suggested length of time. Anecdotally, many patients stop treatment as soon as the itching and redness subside before the infection is fully eradicated. Subsequently, relapse is a common feature.

### Onychomycosis

Fungal infection of the nails presents a greater challenge. Topical agents alone are only indicated when the lunula (half moon) of the affected nail is disease free (Baran and Kaoukhov, 2005). Available medicaments include tioconazole paint and amorolfine lacquer. Patients on topical agents alone should be advised that complete resolution may take up to 12 months and there might be no immediate visible results (Crawford and Hollis, 1999).

When the nail matrix is infected a systemic agent is required. Clinically, this is the case if the fungal infection can be seen spreading proximally into the lunula. If treatment is considered appropriate, in the UK the main oral agents are terbinafine and itraconazole. These have been shown in a systematic review to have mycological cure rates of around 75% in the treatment of toenail mycosis (Gupta et al, 2004). Combining a topical nail lacquer concurrently with an oral antifungal agent has been shown to be more effective than using an oral agent alone in eradicating the disease (Bristow and Baran, 2006). Mycotic toenails which are thickened may harbour large numbers of dermatophytes and reduce the chances of success, therefore reduction of the nails before treatment can improve the likelihood of success and should be considered at the start of therapy (Malay et al, 2009). The safety of these drugs in at-risk populations, such as those with diabetes, has been called into question, however, a systematic review has concluded outcomes for these patients are similar for those without the condition (Cribier and Bakshi, 2004). Despite successful elimination of fungus from the nails, patients undertaking treatments for toenail onychomycosis should be advised that successful eradication of fungus from the nail may not necessarily restore a toenail to a normal appearance, as it may have been damaged and dystrophic before the infection occurred.

### Recurrence of fungal foot infection

Despite effective drug therapies, relapse rates have been shown to be as high as 87% (Sigurgeirsson et al, 2002). This may be due to incomplete eradication of existing fungal skin infection or reinfection following a successful cure. Patient education and involvement is paramount in preventing recurrence. Regular checking of the foot to examine for early signs of re-infection is key so that topical treatment can be instigated at an early stage. Avoidance of patient acquiring new infection can be undertaken following basic advice, for example, checking feet regularly, keeping nails short, keeping the feet dry, as well as avoiding walking barefoot in damp areas such as public sports facilities. Although formally untested, the prophylactic use of topical antifungal agents should be considered for those with recurrent fungal foot infection to maintain skin integrity, particularly in those with diabetes, poor peripheral circulation or a history of recurrent lower limb cellulitis.

Re-infection may also occur from fomites residing in footwear and hosiery. Where possible, patients should be advised to discard old socks, as even with frequent washing viable fungi may still be evident. Disinfection of footwear presents more of a challenge and so old pairs of shoes should be discarded when a cure has been achieved to reduce the chances of reinfection (Gupta et al, 2002). Finally, fungal skin infection on other parts of the body, particularly the hands and groin, should be treated simultaneously if a successful cure is to be achieved.

### Conclusion

Fungal foot infections, although seemingly innocuous, are a common problem particularly in the at-risk foot which can adversely affect tissue viability. A growing body of evidence appears to suggest fungal foot infection is a significant risk factor for the development of lower limb cellulitis. It is therefore suggested that patients and practitioners alike remain more vigilant in the recognition and management of the disease, particularly in those patients with compromised immune systems and poor tissue viability. Treatment with the appropriate therapy can be effective, along with advice to the patient to prevent recurrence. **WUK**

### References

- Baran R, Kaoukhov A (2005) Topical antifungal drugs for the treatment of onychomycosis: an overview of current strategies for monotherapy and combination therapy. *J Eur Acad Dermatol Venereol* 19(1): 21–9
- Bell-Syer S, Hart R, Crawford F, Torgerson D, Tyrrell W, Russell I, eds (2002) *Oral treatments for fungal infections of the skin of the foot*. Cochrane Database of Systematic Reviews 2002, Issue 2. Art. No: CD003584. DOI: 10.1002/14651858.CD003584
- Boyko E, Ahroni J, Cohen V, Nelson K and Heagerty P (2006) Prediction of diabetic foot ulcer occurrence using commonly available clinical information. *Diabetes Care* 29(6): 1202
- Bristow I (2004) Tinea pedis: diagnosis and management. *Podiatry Now* 7(8): S1–S8
- Bristow IR, Baran R (2006) Topical and oral combination therapy for toenail onychomycosis: an updated review. *J Am Podiatr Med Assoc* 96(2): 116–9
- Bristow IR, Spruce MC (2009) Fungal foot infection, cellulitis and diabetes: a review. *Diabet Med* 26(5): 548–51
- Campos MRM, Russo M, Gomes E, Almeida SR (2006) Stimulation, inhibition and death of macrophages infected with *Trichophyton rubrum*. *Microbes Infect* 8(2): 372–9
- Crawford F, Hollis S (1999) *Topical treatments for fungal infections of the skin and nails of the foot*. Cochrane Database of Systematic Reviews 2007, Issue 2. Art. No: CD001434. DOI: 10.1002/14651858.CD001434.pub2
- Cribier BJ, Bakshi R (2004) Terbinafine in the treatment of onychomycosis: a review of its efficacy in high-risk populations and in patients with nondermatophyte infections. *Br J Dermatol* 150(3): 414–20
- Daniel C, Jelinek J (2006) The pedal fungus reservoir. *Arch Dermatol* 142: 1344–6
- Djeridane A, Djeridane Y, Ammar-Khodja A (2006) Epidemiological and aetiological study on tinea pedis and onychomycosis in Algeria. *Mycoses* 49(3): 190–6
- Dupuy A, Benchikhi H, Roujeau J-C, et al (1999) Risk factors for erysipelas of the leg (cellulitis): case-control study. *Br Med J* 318(7198): 1591–4
- Eckhard M, Lengler A, Liersch J, Bretzel RG and Maysr P (2007) Fungal foot infections in patients with diabetes mellitus — results of two independent investigations. *Mycoses* 50(s2): 14–19
- Gupta A, Konnikov N, MacDonald P, et al (1998) Prevalence and epidemiology of toenail onychomycosis in diabetic subjects: a multicentre survey. *Br J Dermatol* 139: 665–71
- Gupta AK, Baran R, Summerbell RC (2002) Onychomycosis: strategies to improve efficacy

and reduce recurrence. *J Eur Acad Dermatol Venereol* 16: 579–86

Gupta AK, Gupta MA, Summerbell RC (2000) The epidemiology of onychomycosis: possible role of smoking and peripheral arterial disease. *J Eur Acad Dermatol Venereol* 14: 466–9

Gupta AK, Ryder J, Johnson AM (2004) Cumulative meta-analysis of systemic antifungal agents for the treatment of onychomycosis. *Br J Dermatol* 150: 537–44

Hay RJ (1993) *Fungi and Skin Disease*. Gower, London

Hollmen KA, Kinnunen T, Kiistala U, et al (2002) Efficacy and tolerability of terbinafine 1% emulsion gel in patients with tinea pedis. *J Eur Acad Dermatol Venereol* 16(1): 87–8

Jegou J, Hansmann Y, Chalot F, et al (2002) [Hospitalization criteria for erysipelas: prospective study in 145 cases]. *Ann Dermatol Venereol* 129(4 Pt 1): 375–9

Karimzadegan-Nia M, Mir-Amin-Mohammadi A, Bouzari N, Firooz A (2007) Comparison of direct smear, culture and histology for the diagnosis of onychomycosis. *Australas J Dermatol* 48(1): 18–21

Kaufman G, Horwitz BA, Duek L, Ullman Y, Berdicevsky I (2007) Infection stages of the dermatophyte pathogen *Trichophyton*: microscopic characterization and proteolytic enzymes. *Med Mycol* 45(2): 149–55

Lavery LA, Armstrong DG, Wunderlich RP, Mohler MJ, Wendel CS, Lipsky BA (2006) Risk factors for foot infections in individuals with diabetes. *Diabetes Care* 29(6): 1288–93

Lawry M, Haneke E, Strobeck K, Martin S, Zimmer B, Romano P (2000) Methods of diagnosing onychomycosis. A comparative study and review of the literature. *Arch Dermatol* 136: 1112–6

Lilly KK, Koshnick RL, Grill JP, Khalil ZM, Nelson DB, Warshaw EM (2006) Cost-effectiveness of diagnostic tests for toenail onychomycosis: a repeated-measure, single-blinded, cross-sectional evaluation of 7 diagnostic tests. *J Am Acad Dermatol* 55(4): 620–6

Malay DS, Yi S, Borowsky P, Downey MS and Mlodzienski AJ (2009) Efficacy of debridement alone versus debridement combined with topical antifungal nail lacquer for the treatment of pedal onychomycosis: a randomized, controlled trial. *J Foot Ankle Surg* 48(3): 294–308

Maruyama R, Hiruma M, Yamauchi K, Teraguchi S, Yamaguchi H (2003) An epidemiological and clinical study of untreated patients with tinea pedis within a company in Japan. *Mycoses* 46: 208–12

Mayser P, Hensel J, Thoma W, et al (2004) Prevalence of fungal foot infections in patients with diabetes mellitus type

1 — underestimation of moccasin-type tinea. *Exp Clin Endocrinol Diabetes* 112(5): 264–8

Musette P, Benichou J, Noblesse I, et al (2004) Determinants of severity for superficial cellulitis (erysipelas) of the leg: a retrospective study. *Eur J Intern Med* 15(7): 446–50

Ortonne JP, Korting HC, Viguie-Vallanet C, Larnier C, Savalunny E (2006) Efficacy and safety of a new single-dose terbinafine 1% formulation in patients with tinea pedis (athlete's foot): a randomized, double-blind, placebo-controlled study. *J Eur Acad Dermatol Venereol* 20(10): 1307–13

Patel A, Brookman S, Bullen M, et al (1999) Topical treatment of interdigital tinea pedis: Terbinafine compared with clotrimazole. *Australas J Dermatol* 40: 197–200

Pierard G (2001) Onychomycosis and other superficial fungal infections of the foot in the elderly: a pan European survey. *Dermatology* 202(3): 220–4

Roseeuw D (1999) Achilles foot screening project: preliminary results of patients screened by dermatologists. *J Eur Acad Dermatol Venereol* 12 (supp 1): S6–S9

Roujeau JC, Sigurgeirsson B, Korting HC, Kerl H, Paul C (2004) Chronic dermatomycoses of the foot as risk factors for acute bacterial cellulitis of the leg: a case-control study. *Dermatology* 209(4): 301–7

Shemer A, Davidovici B, Grunwald MH, Trau H, Amichai B (2009) Comparative study of nail sampling techniques in onychomycosis. *J Dermatol* 36(7): 410–4

Shemer A, Trau H, Davidovici B, Grunwald MH, Amichai B (2007) Collection of fungi samples from nails: comparative study of curettage and drilling techniques. *J Eur Acad Dermatol Venereol* 22(2): 182–5

Sigurgeirsson B, Olafsson JH, Steinsson JB, Paul C, Evans EGV (2002) Long term effectiveness of treatment with terbinafine versus itraconazole in onychomycosis. *Arch Dermatol* 138: 353–7

Sigurgeirsson B, Steingrimsson O (2004) Risk factors associated with onychomycosis. *J Eur Acad Dermatol Venereol* 18: 48–51

Szepietowski JC, Reich A, Garlowska E, Kulig M, Baran E (2006) Factors influencing coexistence of toenail onychomycosis with tinea pedis and other dermatomycoses: a survey of 2761 patients. *Arch Dermatol* 142(10): 1279–84

Traub E, Tolmach J (1937) An erysipelas-like eruption complicating dermatophytosis. *JAMA* 108: 2187–9

Turner R, Testa M (2000) Measuring the impact of onychomycosis on patient quality of life. *Qual Life Res* 9: 39–53

Virgili A, Zampino M, La Malfa V, Strumia R, Bedani P (1999) Prevalence of superficial

## Key points

- ▶▶ Fungal foot infection is the commonest of all fungal skin infections.
- ▶▶ Around 35% of the adult population and 50% of patients over 60 years of age show evidence of the disease.
- ▶▶ Many cases of the condition go unrecognised as clinical signs may be subtle, with a similar appearance to dry skin.
- ▶▶ Fungal foot infection has been identified as a risk factor for the development of lower limb cellulitis.
- ▶▶ Although therapy is usually effective, recurrence is common and so preventative measures along with patient education are an important part of treatment.

dermatomycoses in 73 renal transplant recipients. *Dermatology* (Basel, Switzerland) 199(1): 31–4

Weekers F, Giulietti A-P, Michalaki M, et al (2003) Metabolic, endocrine, and immune effects of stress hyperglycemia in a rabbit model of prolonged critical illness. *Endocrinology* 144(12): 5329–38

Weinberg JM, Koestenblatt EK, Jennings MB (2005) Utility of histopathologic analysis in the evaluation of onychomycosis. *J Am Podiatr Med Assoc* 95(3): 258–63

Weitzman I, Summerbell RC (1995) The dermatophytes. *Clin Microbiol Rev* 8(2): 240–59

Weller R, Price RJ, Ormerod AD, Benjamin N, Leifert C (2001) Antimicrobial effect of acidified nitrite on dermatophyte fungi, *Candida* and bacterial skin pathogens. *J Appl Microbiol* 90(4): 648–52

Yosipovitch G, Hodak E, Vardi P, et al (1998) The prevalence of cutaneous manifestations in IDDM patients and their association with diabetes risk factors and microvascular complications. *Diabetes Care* 21(4): 506–9