

Management of military wounds in the modern era

Improvements in the immediate medical and surgical care of battle casualties, and in body armour, have meant that soldiers are surviving injuries which would have killed them if sustained in previous conflicts. This has resulted in an increase in the complexity of the wounds that require reconstruction and new challenges for the orthoplastic team. Management of wound exudate, pain and nutrition are vitally important, as is control of the wound microbiology. These patients are best looked after in a single facility which has on-site trauma specialties, so that corporate knowledge of how to look after these unique injury patterns can be developed.

Chris Taylor, Steven Jeffery

KEY WORDS

Multiple simultaneous injury
Debridement
Photographing wounds
Microorganisms

Military wounds typically occur through ballistic trauma and high-energy transfer, although not invariably so, as even on operations soldiers may become injured in accidents. However, when discussing military wounds, we usually refer to those sustained through gunshots, multiple fragmentation injury secondary to grenades, improvised explosive devices (IEDs), landmines and suicide bombings. Isolated wounds are unusual and more commonly soldiers are sustaining multiple simultaneous injury. This has been reflected in increasing injury

severity scores (ISS) over recent years (personal communication: Colonel TJ Hodgetts, Defence Professor of Emergency Medicine, Royal Centre for Defence Medicine [RCDM]).

Multiple fragmentation injuries are associated with significant trauma. Soldiers are often in close proximity to detonation and are therefore subject to blast. Blast injury is multifaceted and involves an initial shockwave and

Military wounds are often heavily contaminated as a result of the environment in which they are sustained, the improvised nature of the explosive devices, and the fact that soldiers are often only able to maintain basic hygiene.

subsequent blast winds. Primary blast injury is sustained through pressure of the surrounding environment and can cause rupture of air-filled organs and tissues at air-fluid interfaces. This can result in ruptured tympanic membranes, blast lung, pneumothorax, haemopneumothorax, as well as gastrointestinal disruption and neurological sequelae. Secondary blast injury is a result of projectiles from the explosive device impacting with

the casualty and effecting multiple wounding. Tertiary blast injury occurs when either the casualty collides with surrounding objects, or surrounding objects fall on to the casualty as the result of blast winds. Quaternary blast injuries are sustained through other effects of the explosive device such as burns and toxic chemical contamination (Horrocks, 2001). It is not difficult to appreciate the magnitude, complexity and multiplicity of injury, as well as the potential for severe systemic compromise in these patients.

Furthermore, each individual injury sustained may be very different in nature, requiring many varied medical specialties. Military wounds are often heavily contaminated as a result of the environment in which they are sustained, the improvised nature of the explosive devices, and the fact that soldiers are often only able to maintain basic hygiene. They are, therefore, exceedingly challenging.

Patterns of military wounding

The majority of wounds sustained in military operations are extremity injuries to the head and neck and upper and lower limbs (Owens et al, 2007; Ramasamy et al, 2009). This is increasingly the case as a result of protection derived from improved body armour. Military casualties will often have more than one injury

Chris Taylor is Specialist Training Registrar, Department of Plastic Surgery, Sandwell General Hospital, West Bromwich; Steven Jeffery is Consultant Burns and Plastic Surgeon, Department of Burns and Plastic Surgery, Selly Oak Hospital, Birmingham

and injuries involving more than one anatomical region (Dougherty et al, 2009; Ramasamy, 2009) (Figure 1).

Injuries sustained in current theatres of operation are becoming ever increasingly survivable. This is due to improved immediate first aid through the use of combat tourniquets and novel haemostatic agents, as well as shorter timelines to definitive care as a result of helicopter-borne and consultant-led medical evacuation response teams (MERT). It is the authors' impression that many injuries sustained in current military operations would previously not have been survivable.

Historical approach

Since man first sustained injuries through accidents and animal attacks, and later through combat, people have attempted to treat wounds. Hippocrates in the 5th century BC believed that wounds should be kept dry and only irrigated with water or wine. He believed that a suppurating wound was a healing one and that pus was necessary. The belief in 'laudable pus' persisted for some time but in the early 13th century some turned against this view, believing that pus was not necessary. Wound healing without pus was considered healing by first intention. However, because the physician held a higher status than the surgeon during the middle ages, little was published.

In the early 14th century, the innovative surgeon, Guy De Chauliac, proposed five wound management principles:

- ▶▶ Removal of foreign bodies
- ▶▶ Rejoining of severed tissues
- ▶▶ Maintenance of tissue continuity
- ▶▶ Preservation of organ substance
- ▶▶ Prevention of complications.

Gunshot wounds resulted in gross tissue destruction and became heavily contaminated. Nothing was known of bacteria, and infection was thought to be the result of poisonous gunpowder. To counter this, burning oil was poured into the wound. Cautery became a widely practiced treatment

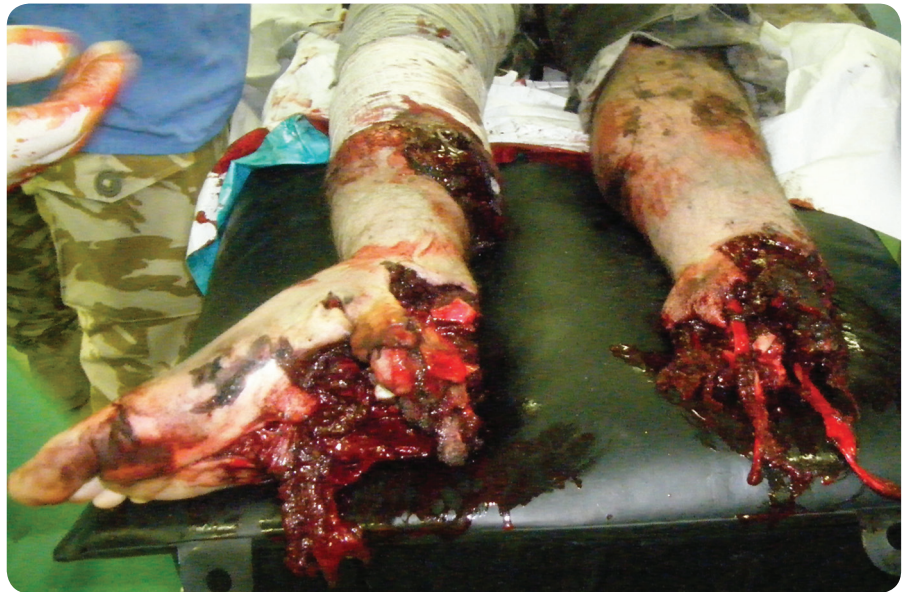

Figure 1. Typical wounding pattern and degree of soft and hard tissue destruction seen in modern military wounds.

for this type of wound (Manring, 2009). This was revised by the French surgeon Ambrose Paré after he ran out of burning oil during the siege of Turin in 1536. He instead used egg yolk, rose oil and turpentine to good effect, reducing inflammation and pain.

Insufficient analgesia will only serve to provide a patient who is petulant, non-compliant and, above all, exhausted. In a sense, they become primed to expect agony at every intervention...

During the American Revolutionary War, a conservative approach was encouraged and the British Surgeon General, John Hunter, suggested to physicians that they resist aggressive debridement of smaller wounds. Bullets were removed only if in easy reach of the surgeon, and if a wound had to be closed, it was done so initially over an onion, and after 1–2 days reopened and closed. This principle of delayed primary closure was re-learned in World War I and noted to aid recovery and reduce infection. The advent of cultures in World War II helped in decisions as to when definitive closure could

be undertaken. In the Vietnam War wound management involved infusion of the patient with Ringer's lactate and antibiotics, with debridement of the wound and open packing with occlusive dressings. Secondary closure was usually achieved within seven days (Manring et al, 2009).

Current management of military wounds

The approach to managing all wounds should be holistic and military wounds, although often more complex, are no different. It is useful to consider management of the patient rather than the wound in isolation. The following areas of patient management are key to achieving a successful outcome with military wounds, from the point of wounding back through increasing levels of care to definitive care facilities, such as military field hospitals and UK hospitals.

Management of pain

The effects of pain on the subsequent efficient management of the military casualty are not to be underestimated. Pain is not conducive to wound healing. Insufficient analgesia will only serve to provide a patient who is petulant, non-compliant and, above all, exhausted. In a sense, they become primed to expect agony at every intervention and this can have significant bearing on dressing

changes, line changes, suture removal and subsequent rehabilitation. Effective analgesia is particularly important during the transportation of casualties and should be planned well in advance. The authors have found that continuous infusion nerve blocks have proven very effective and can be maintained for prolonged periods without consequences such as infection. It is essential, however, that proper neurological assessment be made of involved limbs before these blocks are started, including detailed documentation regarding sensory and motor function. This will avoid the need for excessive surgical exposure and interruption of analgesia. Increasing requirements for analgesia may be due to dislodgement of the catheter or the development of compartment syndrome and this should always be considered.

Early attention to nutrition

Military casualties will have frequently been involved in high intensity exertion before injury and may not have had access to high calorie food, fresh fruit or vegetables for some time. Moreover, once they enter the care pathway, the many trips to the operating theatre are associated with inevitable controlled starvation. It may be the case that due to contamination these cases find themselves at the end of emergency lists and unfortunately will have a higher incidence of cancellation. The authors feel that patients should be weighed on arrival and a nutritional assessment obtained. In all but minor wounds, feeding should be started as soon as is possible. More significant injuries will need enteral feeding and the authors are currently investigating how injury severity scores can be used to predict the need for such intervention.

Optimum nutritional status is key to efficient wound healing and will help prevent enteric complications, such as bacterial translocation and associated sepsis (Stankorb, 2009). Nasojejunal as opposed to nasogastric feeding seems most appropriate, as this will reduce the need to stop feeding before subsequent surgery.

Microbiology

Microbiology swabs play an important role in managing wounds. Approximately 65% of patients with open fractures have wounds contaminated with microorganisms and the authors' impression is that the incidence is higher in military wounds. However, whether or not wound swabs should be taken at first presentation or at first debridement is not clear. Patakis et al (1974) suggested that those taken at this early stage were of little use as they often failed to identify the organisms that subsequently caused infection (Patakis et al, 1974; Patakis, 1989). Certainly, once at the definitive care facility, wound swabs should be taken and plated the same day. Debrided tissue should also be sent for analysis including fungal analysis. The authors have seen a high level of fungal contamination within wounds which has had significant effect on wound healing and subsequent soft tissue reconstruction. In contrast, multi-resistant *Staphylococcal aureus* and *Acinetobacter* infection have played little role in the spoiling of wound healing per se. Broad-spectrum antibiotics should be started as soon after wounding as possible, and the authors currently administer intravenous high dose Augmentin® (Glaxo Smith-Kline) on presentation at the field hospital, which is later changed according to sensitivities.

Photographing wounds

The documentation of wounds is best served by digital photography with appropriate consent if obtainable. It is far superior to written description or pictorial representation in illustrating the pattern of injury, complexity of wounds and degree of contamination. More importantly, it avoids unnecessarily disturbing dressings by subsequent receiving medical teams and can be sent ahead of the patient to help in forward planning of resources required for appropriate management. Furthermore, it will ultimately aid classification of wounds and retrospective analysis of injuries, which plays a vital part in being able to assess management and facilitate

ongoing development of best practice.

Debridement

Larrey, Napoleon's surgeon, stated that, 'debridement is one of the most important and significant discoveries in all of surgery' (Reichert, 1928). It is, of course, the fundamental stage in wound management and can significantly influence the final result. This is often achieved in the heavily contaminated wounds of military injuries in several stages. Initial debridement may well be performed within the limitations of 'damage control surgery.' Hence, it should be thorough but not excessive. It is useful to reflect on the debridement classification described by Granick and Chehade (2007). This is based on a view that tissue injury is similar in nature to that described by Jackson when discussing his burn wound model (Jackson, 1953). That is, within the centre of the wound most exposed to insult is an area of necrosed tissue, surrounded by an area of injured and marginal, but alive tissue. Surrounding this is healthy tissue. Based on these zones, Granick and Chehade classified wounds according to the level of debridement into:

- ▶▶ Non-debrided wound (0)
- ▶▶ Incomplete (1)
- ▶▶ Marginal (2)
- ▶▶ Complete (3)
- ▶▶ Radical (4).

Incomplete debridement describes a wound in which not all of the necrotic material has been removed. This level of debridement is to be avoided if possible, as retained necrotic material will serve only as a focus for infection. Marginal debridement implies that all necrotic tissue has been removed, but injured and potentially viable tissue is retained. This is the most appropriate level of debridement at the initial procedure, as removal of potentially viable tissue at this stage may unnecessarily create a larger wound and requirement to employ more complex reconstruction. Complete debridement removes both necrosed and marginal tissue, and radical debridement includes

normal tissue within the field of excision. Debridement should always be performed with the use of a tourniquet if possible.

Larger, complex wounds are often uneven and contain numerous pockets, and in high-energy explosive wounds foreign contaminated material may be forced deep between tissue planes. Without tourniquet control, these areas are quickly obscured with blood so that effective excision of necrotic and contaminated tissue can never be reliably achieved (Godina, 1986). Furthermore, blood loss can be significant in an already compromised patient. In proximal limb wounds, the surgeon can apply a sterile, disposable tourniquet once the skin has been prepared for surgery by the application of disinfectant.

Once soldiers reach definitive care within the UK reassessment is made of all wounds. It is the authors'

practice that this is done under general anaesthetic unless injuries are minor. This can usually wait to daylight hours unless the viability of a limb is in question, there is gross un-debrided contamination, or there is suspected sepsis. This assessment should be carried out by senior orthopaedic and plastic surgeons, so that a definitive plan for reconstruction of injuries is made from the outset. Debridement of wounds at this stage should be complete. The authors have found that sharp dissection under tourniquet control is best for removing all necrotic tissue and that the Versajet™ (Smith and Nephew) hydrosurgery dissection device is an extremely useful adjunct in ensuring ingrained mud, dirt and sand are thoroughly removed from the wound surface.

Fasciotomies

There must be a low threshold for performing fasciotomies in military injuries to the limbs, particularly

when associated with blast injury, fragmentation perforating the investing fascia or underlying fracture. If prolonged transfer times are likely from one facility to another, fasciotomy should be thought about early. In the military setting, trauma significant enough to warrant the insertion of nerve block catheters to control pain usually warrants a fasciotomy.

There is no place in military trauma for incomplete, 'limited', or 'single incision' fasciotomies. In an injured leg, the anatomical landmarks can be difficult to ascertain, so a marker pen should be used to mark out the proposed incision: 'draw twice, cut once'. Fasciotomy incisions should not be performed directly over the tibia, as they can convert a closed fracture into an open one. Closed fractures should not need flap cover. There should be no concern about damaging perforating blood vessels that a plastic surgeon may use, as he should not

Wounds UK, stand 4, Harrogate International Centre





1994 KCI introduces V.A.C.® Therapy to Europe



1996 Dolly the sheep becomes the first mammal cloned from an adult cell (died in 2003)



2002 KCI has V.A.C. ATS® System, & BariAir™ Mattress Replacement System



2003 New blood test can tell normal from cancerous DNA



2004 V.A.C.® Freedom System launched

In 1994 KCI promised you innovations in wound care.

Contact KCI today for more information on V.A.C.® Therapy, TSS Therapeutic Support Systems (TSS) or LifeCell Products by contacting KCI on **0800 980 8880** or visiting our new website www.kci-medical.com

© 2009 KCI Licensing, Inc. All Rights Reserved. All trademarks designated herein are property of KCI Licensing, Inc, its affiliates and licensors. Those KCI trademarks designated with the "®" or "TM" symbol are registered or pending registration in at least one country where this product/work is commercialized, but not necessarily in all such countries. These materials are intended for healthcare professionals only. DSL#09-10-575.UK(10/09)

need them. Never, ever primarily close fasciotomy incisions.

Dressings

Current doctrine is to apply dry, fluffed gauze to the wound following initial debridement at the field hospital. On arrival in the UK these dressings often show heavy soiling and strikethrough (Figure 2).


The possibility of using topical negative pressure (TNP) dressings following the initial debridement at the field hospital is currently being investigated. This would serve to effectively manage exudate and maintain a sealed and clean dressing during repatriation. Following initial debridement at the definitive treatment institution, wounds that are not closed surgically are all managed with TNP at the authors' institution. This is in the form of gauze dressings connected to vacuum suction devices. TNP allows for clean and closed

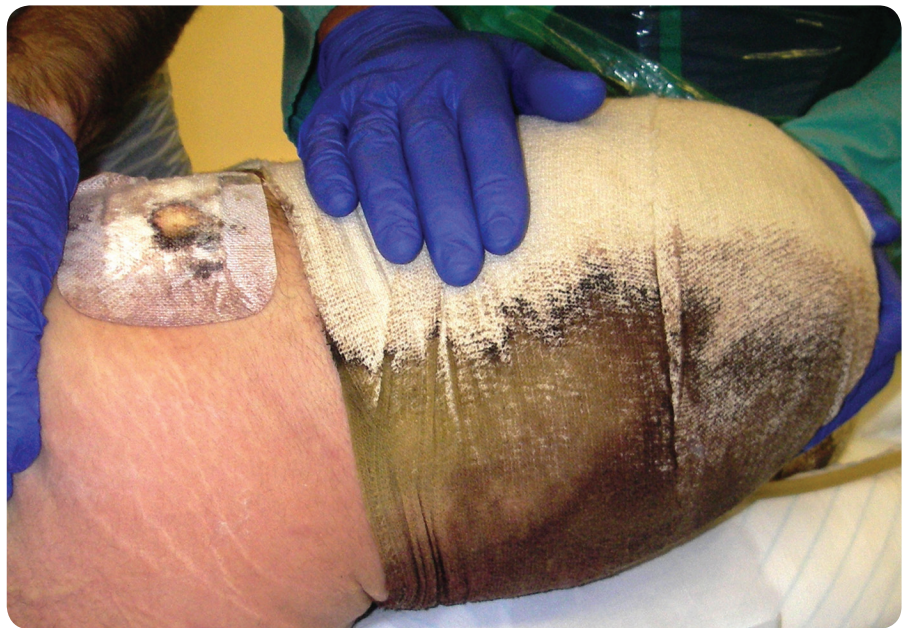


Figure 2. Heavy soiling and strikethrough due to the excessive exudate generated by military wounds.

wound management, continuous collection of excessive exudate and inflammatory mediators, and provides a more physiological wound


environment (Webb, 2006). Using gauze vacuum dressings also allows for functional splinting in a quick and easily manageable way, particularly when



Wounds UK, stand 4, Harrogate International Centre



2007 Scientists discover how to create embryonic skin cells



2008 KCI enters the tissue regeneration market with the purchase of LifeCell



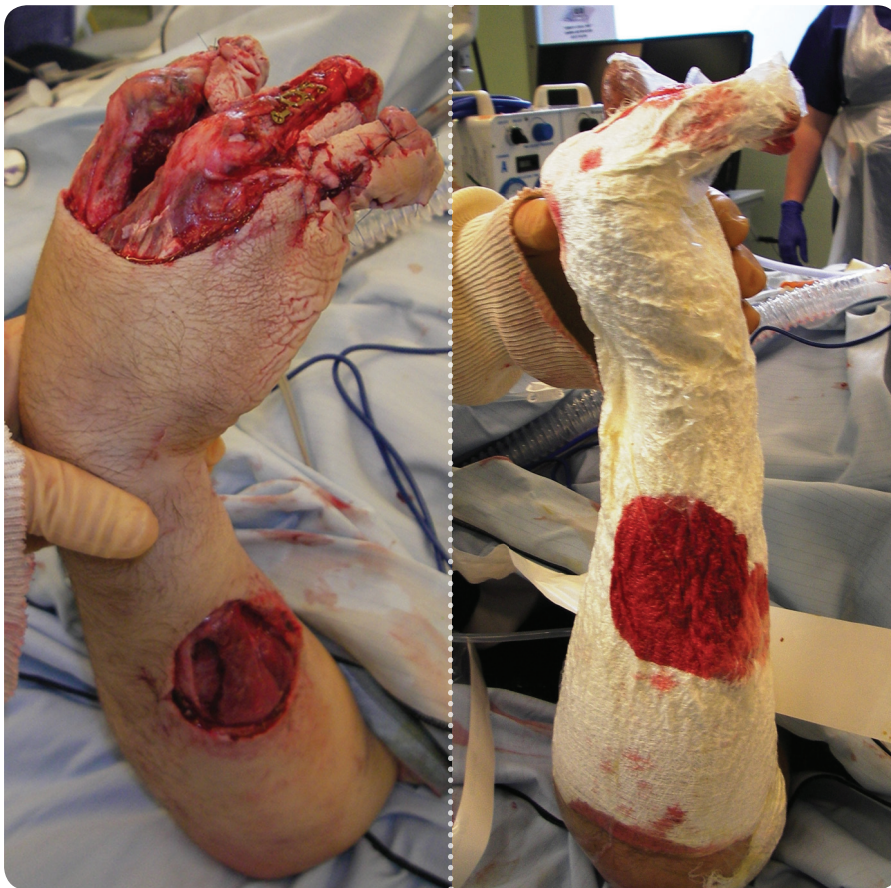
2009 KCI launches innovative new dressings

15 years later we are moving into our next stage of innovation...

Contact KCI today for more information on V.A.C.® Therapy, TSS Therapeutic Support Systems (TSS) or LifeCell Products by contacting KCI on **0800 980 8880** or visiting our new website **www.kci-medical.com**

© 2009 KCI Licensing, Inc. All Rights Reserved. All trademarks designated herein are property of KCI Licensing, Inc, its affiliates and licensors. Those KCI trademarks designated with the "®" or "TM" symbol are registered or pending registration in at least one country where this product/work is commercialized, but not necessarily in all such countries. These materials are intended for healthcare professionals only. DSL#09-10-575.UK(10/09)





Figures 3 and 4: Difficult to dress upper extremity wounds can be managed well with safe and functional splinting using gauze-based topical negative pressure (TNP) dressings.

managing upper extremity injuries (Figures 3 and 4).

The amount of exudate that can be removed from these wounds may well be in the order of 4–5 litres per day and, therefore, careful fluid balance management must take account of this and replace losses appropriately.

Soft tissue reconstruction

Before embarking on soft tissue reconstruction it is essential to ensure that both the patient and wound are in an optimal physiological state. This means that the patient must be physiologically stable, afebrile, in a corrected and optimal nutritional state and off all inotropic support. Wounds should have been thoroughly debrided with no remaining necrotic tissue or potential sources of infection and have minimal exudate. Furthermore, the microbiological profile of the patient must be known. If there is any suggestion of fungal infection, reconstructive efforts must not be

undertaken. Fungal infection is not uncommon in soldiers injured in the Middle East or Asia, who are often lying in contaminated ditch water following injury. They are also immunocompromised following massive blood transfusion. These patients often show prolonged pyrexia before having positive fungal histology and microbiology. Certain fungi can extend up the intima of blood vessels, thrombosing side branches and perforators, producing mycotic emboli. This may well lead to flap failure and wastage of donor sites. Following tissue biopsy in the UK, patients at high risk of fungal infection receive antifungal prophylaxis in the form of amphotericin (a powerful antibiotic for the treatment of fungal infections) until sensitivities are available.

Reconstruction relying on local perforator flaps should be used with caution as the zone of trauma is all too readily underestimated in the military injury. Primary blast

wave is likely, although not yet demonstrated in a research setting, to cause intimal damage to surrounding local blood vessels well beyond the obvious margins of wounding. This is particularly likely at sites where perforating vessels are relatively tethered, i.e. where they penetrate the fascia. Angiography does not appear to be helpful in determining this. In the authors' opinion, civilian guidelines as to the most appropriate timing of soft tissue reconstruction, particularly of open fractures, such as those produced by the British Association of Orthopaedic Surgeons and the British Association of Plastic, Reconstructive and Aesthetic Surgeons (Court-Brown et al, 1997), are to be ignored when treating military injuries. Such constant ambition to achieve soft tissue closure within five days is inappropriate for the complex multi-limb and heavily contaminated blast injuries seen in current military patients. The above pre-requisites to soft tissue reconstruction must be achieved and this often takes time, particularly with the extending necrosis seen in fungal infections.

Recently, publication of early outcomes in microvascular soft tissue reconstruction in US military casualties has demonstrated success comparable with early flap reconstruction, despite prolonged post-injury reconstruction taking a considerable length of time to achieve (Kumar, 2009).

Conclusions

Military wounds are by their very nature devastating and complex. With improvements in body armour, pre-hospital emergency care and timely evacuation to consultant-led field hospital management, soldiers are surviving injuries that previously they would have succumbed to before reaching definitive care. These soldiers are often physiologically compromised, will have received massive blood transfusions and, therefore, are immunocompromised and have large surface area wounds involving multiple limbs as well as body cavity trauma. This demands extensive and continuous wound

management from the time of injury through to definitive healing that is only achieved by managing the whole patient and addressing issues such as pain, nutrition, infection, physiological function and wound care before thoughts about reconstruction.

Debridement must be performed early, but not so extensively as to be lengthy and compromise physiology of an injured soldier. It needs to be tailored to the patient and be ongoing until such time as the wound is clean and healthy. This is proving especially difficult to achieve, particularly within the first week post-injury. Fungal infestation is commonly seen in extensively contaminated wounds and is to be expected. It will compromise reconstructive efforts if adequate debridement is not achieved through multiple visits to theatre and appropriate antifungal treatment. The large zone of injury involved, along with heavy contamination which is often thrust deep between tissue planes by the force of explosion and the likely vessel damage caused through the primary blast wave, makes reconstruction with local flaps (which are perforator based), or free flap surgery (which relies on a local as recipient vessel) precarious. That said, success has been reported in the wider literature following staged debridement within the sub-acute period (Geiger, 2008; Kumar, 2008; Kumar, 2009). **UK**

References

- Court-Brown C, Cross, Hahn D, et al (1997) A Report by the British Orthopaedic Association/British Association of Plastic Surgeons Working Party on the Management of Open Tibial Fractures. *Br J Plastic Surg* 50(8): 570–83
- Dougherty AL, Mohrie CR, Galarneau MR, Woodruff SI, Dye JL, Kimberly HQ (2009) Battlefield extremity injuries in Operation Iraqi Freedom. *Injury* 40(7): 772–7
- Geiger S, McCormick F, Chou R, Wandel A (2008) War wounds: lessons learned from Operation Iraqi Freedom. *Plast Reconstr Surg* 122(1): 146–53
- Godina M (1986) Early microsurgical reconstruction of complex trauma of the extremities. *Plast Reconstr Surg* 78(3): 285–92
- Granick MS, Gamelli RL, (2007) *Surgical Wound Healing and Management*. Informa Healthcare, New York
- Horrocks C (2001) Blast injuries: biophysics, pathophysiology and management principles. *J Royal Army Medical Corps* 147(1): 28–40
- Jackson D (1953) The diagnosis of the depth of burning. *Br J Surg* 40: 588–96
- Kumar AR (2006) Standard wound coverage techniques for extremity war injury. *J Am Acad Orthopaed Surgeons* 14(10): S62–5
- Kumar AR, Grewal NS, Chung TL, Bradley JP (2008) Lessons from the modern battlefield: successful upper extremity injury reconstruction in the subacute period. *J Trauma Injury, Infection Crit Care* 23:1–6
- Kumar AR, Grewal NS, Chung TL, Bradley JP (2009) Lessons from Operation Iraqi Freedom: Successful subacute reconstruction of complex lower extremity battle injuries. *Plast Reconstr Surg* 123(1): 218–29
- Manring MM, Hawk A, Calhoun JH, Andersen RC (2009) Treatment of war wounds: a historical review. *Clin Orthop Relat Res* 467(8): 2168–91
- Owens BD, Kragh JF Jr, Macaitis J, Svoboda SJ, Wenke JC (2007) Characterisation of extremity wounds in Operation Iraqi Freedom and Operation Enduring Freedom. *J Orthop Trauma* 21(4): 254–7
- Patakis MJ (1989) Factors influencing infection rate in open fracture wounds. *Clin Orthop Relat Res* 243: 36–40
- Patakis MJ, Harvey PH Jr, Ivler D (1974) The role of antibiotics in the management of open fractures. *J Bone Joint Surg Am* 56(3): 532–41
- Ramasamy A, Harrison S, Lasrado I, Stewart MP (2009) A review of casualties during the Iraqi insurgency 2006 — a British field hospital experience. *Injury* 40(5): 493–7
- Reichert FL (1928). The historical development of the procedure termed debridement. *Bull Johns Hopkins Hosp* 42: 93–104
- Stankorb SM, Salgueiro M, Grediagin A (2009) Enteral feeding practices for U.S. service members in a deployed combat support. *Military Med* 174(7): 685–8
- Webb LX, Dedmond B, Schlatterer D, Laverty D (2006) The contaminated high energy open fracture: a protocol to prevent and treat inflammatory mediator storm-induced soft-tissue compartment syndrome (IMSICS). *J Am Acad Orthop Surg* 14(10): S82–6

Key points

- ▶▶ Military wounds usually refer to those sustained through gunshots, multiple fragmentation injury secondary to grenades, improvised explosive devices (IEDs), landmines and suicide bombings.
- ▶▶ The approach to managing all wounds should be holistic and military wounds, although often more complex, are no different.
- ▶▶ Effective analgesia is particularly important during the transportation of casualties and should be planned well in advance.
- ▶▶ Optimum nutritional status is key to efficient wound healing and will help prevent enteric complications, such as bacterial translocation and associated sepsis (Stankorb, 2009).
- ▶▶ Microbiology swabs play an important role in managing wounds.
- ▶▶ Debridement is, of course, the fundamental stage in wound management and can significantly influence the final result. This is often achieved in the heavily contaminated wounds of military injuries in several stages.
- ▶▶ Military wounds are by their very nature devastating and complex.