

# Charcoal combined with silver for the treatment of chronic wounds

Actisorb™ dressing with silver consists principally of activated carbon impregnated with metallic silver. Activated charcoal can adsorb and neutralise the bacterial toxins locally released and reduce the inappropriate high level of cytokines in wound exudate of chronic wounds. Incorporating silver actively participates in decreasing bacterial bioburden and biofilm growth, a major factor of chronicity. Actisorb silver dressing is a therapeutic alternative when treating chronic wounds stuck in an inflammatory stage. It seems to be particularly useful for the management of strongly colonised wounds and even of heavily exuding ulcers if combined with a high-absorbing secondary dressing, such as a foam dressing.

Jean Charles Kerihuel

## KEY WORDS

Actisorb™ dressing with silver  
Bacteria  
Chronic wounds  
Activated charcoal

Actisorb™ dressing with silver (Systagenix Wound Management) consists principally of activated carbon impregnated with metallic silver. The carbonised fabric is enclosed in a sleeve of spun-bonded non-woven nylon, sealed along all four edges, to facilitate handling and reduce particle and fibre loss. When applied to a wound the dressing adsorbs locally released toxins and the products of wound degradation. Bacteria present in wound exudate are also attracted to the surface of the dressing where they are killed by the antimicrobial activity of the silver, which is active against a wide range of pathogenic organisms. This dressing has been used clinically for many years and, in the author's opinion, was one of the first dressings to efficiently and favourably

modulate the microenvironment of chronic wounds. The Actisorb™ dressing is marketed as ACTISORB™ Silver 220 in the United Kingdom and ACTISORB™ Ag+ in France.

Recent accumulation of fundamental data has largely clarified our understanding of the basic mechanisms that impair wound healing (Zamboni et al, 2008; Panuncialman and Falanga, 2009; Martin et al, 2009). Based on these new findings, wound management has substantially evolved. However, when reviewing these changes, it appears that the mode of action of Actisorb dressing with silver is still of clinical interest and these fundamental advances may open new ways to understand the mode of action of this dressing.

## Wound microbial flora, cytokines, inflammation and delayed healing

Chronic wounds are contaminated by microorganisms and their bacterial ecosystem is complex (Bowler et al, 2001; Hill et al, 2003; Davies et al, 2004). For venous leg ulcers (VLU), a polymicrobial ecosystem is the rule rather than the exception (Tomljanovic-Veselski et al, 2005; Gjødsbøl et al, 2006; Lim et al, 2006), and anaerobes may represent more than 30% of isolates from such wounds (Bowler and Davies, 1999; Halbert et al, 1992). The higher the extent of necrotic tissues in a wound, the higher the number of bacteria, whereas the wound is almost

sterile when abundant granulation tissue is present (Sapico et al, 1986). While chronic wounds may tolerate large amounts of bacteria without apparent clinical signs of infection, this proliferation is not without consequences on the healing process through complex interactions with the local wound environment (Sibbald et al, 2003; Edwards and Harding, 2004; Jones et al, 2004; Ebright, 2005; Penhallow, 2005). For instance, in appropriately debrided (clear of necrotic tissue) neuropathic diabetic foot ulcers, Xu et al (2007) have shown with repeated biopsies that the wound closure rate was linearly and negatively correlated to bacterial burden. This has been confirmed by Davies et al (2007) in a prospective study conducted in 66 patients treated for VLUs that were not clinically infected. The bacterial density of wound surface area measured at baseline either by swab or biopsy was a strong and independent prognostic factor of wound closure at six months. These results, among others, suggest that decreasing high bacterial burden in chronic wounds might be a favourable intervention to promote closure.

Along with metalloproteinases production enhancement, bacteria, even at low levels, have a direct effect on tissue viability via toxin secretion either directly from viable cells (exotoxins), or as a result of cell lysis (endotoxins) (Ovington, 2003). Endotoxins are known to have strong immune stimulatory and

proinflammatory properties, even in small amounts (Fleck, 2006). At wound level, these toxins tend to cause local necrosis and will disrupt the time-regulated series of events supporting the normal healing process.

More importantly, numerous points of experimental and clinical evidence have confirmed the negative impact of bacterial biofilms (Bjarnsholt et al, 2008; Rhoads et al, 2008; Singh and Barbul, 2008; Wolcott et al, 2008). This particular bacterial mode of growth is frequent in various microorganism species and is well known for *Pseudomonas aeruginosa*. In wounds characterised by delayed healing and maintenance of an inappropriate inflammatory reaction, investigations have suggested that bacteria present within these wounds tend to be aggregated in microcolonies embedded in a self-produced matrix, characteristic of the biofilm mode of growth (Kirketerp-Møller et al, 2008). Additionally, there is no good correlation between bacteria detected by standard culturing methods and those detected by direct detection methods such as PNA FISH. PNA FISH uses fluorescently-labelled peptide nucleic acid (PNA) probes in a highly sensitive and specific fluorescence in situ hybridisation (FISH) assay targeting the species-specific ribosomal RNA (rRNA). This technique provides a reliable tool to study bacterial biofilm formation (Malic et al, 2009).

Therefore, toxin control is a potentially valuable adjunct to any infection control modality. A long-standing method of controlling toxins of many types is the use of high surface area adsorbents, such as activated charcoal. Data strongly suggest that activated charcoal may offer specific advantages in topical wound management through its effects on bacterial toxins, especially when combined with silver; in order to decrease bacterial burden and the risk of biofilm development (Thomas and McCubbin, 2003; Castellano et al, 2007).

**Activated charcoal and silver: main properties**

**Activated charcoal and adsorption properties**

Activated charcoal (also named as

activated carbon, active carbon, or black bone) is a charcoal (most frequently of vegetable origin) that has been activated for adsorption by steaming or by heating in a vacuum. Charcoal becomes activated by heating it with steam to approximately 1000°C in the absence of oxygen (Marsh and Rodriguez-Reinoso, 2006).

Activated carbon (Figure 1) has an extraordinarily large surface area and pore volume that gives it a unique adsorption capacity (Baker et al, 1992). Some have surface areas as high as 5,000m<sup>2</sup>/g. The specific mode of action is extremely complex and has been the subject of numerous studies and debates (Bansal and Goyal, 2005; Marsh and Rodríguez-Reinoso, 2006). Activated

carbon has both chemical and physical effects on substances where it is used as a treatment agent. Activity can be usually separated into adsorption, its main property, mechanical filtration, ion exchange and surface oxidation. Activated charcoal is widely used to de-colourise liquids, recover solvents, and remove toxins from water and air.

The adsorption properties of activated charcoal have been used for a long time to clear fluids from bacterial endo- and exotoxins (Du et al, 1987), and these properties have an important impact in the management of chronic wounds. For instance, in experimental conditions it has been shown that activated charcoal, when bathed in a milieu enriched with *Escherichia coli*

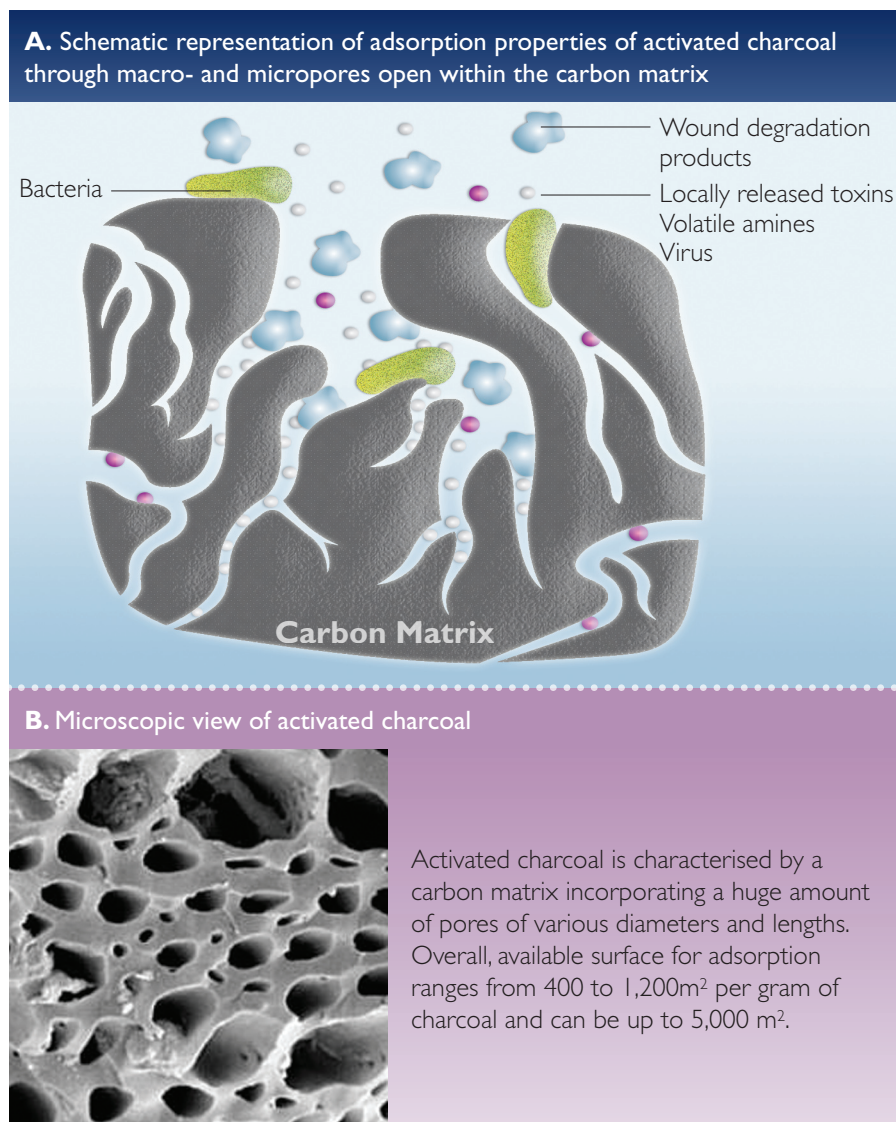


Figure 1. Schematic presentation of activated charcoal.

endotoxin, will remove 90–95% of this toxin (Nolan et al, 1975; Maitra et al, 1981). In *in vitro* and *in vivo* experiments using a murine model of gut-derived endotoxaemia, charcoal particles were one of the most effective materials in the prevention of endotoxaemia. Good correlation was shown between the ability of activated charcoal to bind endotoxin *in vitro* as compared with *in vivo* action (Ditter et al, 1983). Furthermore, it has been shown that activated charcoal can also adsorb bacteria, viruses, and various other biochemicals, both *in vitro* and *in vivo* (Drucker et al, 1977; Naka et al, 2001).

Additionally, *ex vivo* and *in vitro*, activated charcoal efficiently filters clear blood from inflammatory chemokines and cytokines such as interleukin-8 (IL-8) or tumour necrosis factor-alpha (TNF $\alpha$ ) (Cole et al, 2002; Howell et al, 2006; Sandeman et al, 2008). In an *ex vivo* experiment evaluating a haemofiltration device combined with an active carbon cartridge, the cartridge adsorbed 90% of IL-1 beta, 72% of IL-6, 100% of IL-8, and 7% of TNF $\alpha$  during each pass (Cole et al, 2002).

Malodour is a common problem when managing wounds, especially malignant wounds or pressure ulcers (Lee et al, 2006; McDonald and Lesage, 2006; Seaman, 2006). This problem may have a detrimental impact on patients' body image (Young, 2005). The blood supply to parts of the tumour or of the wound is often impaired, resulting in areas of hypoxic or necrotic tissue. These areas become infected with anaerobic bacteria, which release malodorous volatile fatty acids as a metabolic by-product. Activated charcoal heavily adsorbs and neutralises these volatile molecules, thus decreasing odour, as shown in a double-blind experiment (Chakravarthi et al, 2008). This will help both patients and healthcare professionals to more easily comply with wound care.

#### Advantages of adding silver

Silver has a broad antibacterial spectrum including all microorganisms involved in wound colonisation and wound infection (Lansdown, 2002). Due to

its mechanisms of action, resistance to silver is hard to develop (Percival et al, 2005). In addition, silver possesses other properties of clinical interest in wound management. It is a strong anti-inflammatory agent and is able to inhibit matrix metalloproteinase activity (Kerihuel, 2008).

Silver incorporated in the activated charcoal matrix is primarily bound to the structure of the charcoal and not released. However, in conjunction with bacterial adsorption onto charcoal surface, silver ions in the material kill these bacteria and efficiently participate to reduce bacterial burden and biofilm growth (Muller et al, 2003).

#### Actisorb in the management of chronic wounds: clinical evidence

##### Randomised controlled trials of Actisorb without silver

Two randomised control studies were conducted with Actisorb in the treatment of chronic wounds.

Mulligan et al (1986) randomised a total of 101 subjects with ulcers to either Actisorb or to any other dressing regarded as most appropriate by investigators (control group). These various ulcers were treated for six weeks, or until healing. Main evaluation parameters included ulcer size and wound aspect (granulation tissue, exudate level, oedema, odour, pain). There were no statistically significant differences in baseline demographic data. However, the Actisorb group included ulcers of longer mean duration (117 versus 52 months), and larger mean area (30.3 cm<sup>2</sup> versus 19.7cm<sup>2</sup>). In the Actisorb group, a statistically significant 28.7% ( $\pm$ 3.9%) mean percentage reduction in wound area was noted compared to 11.7% ( $\pm$ 6.8%) reduction in the control group. In addition, Actisorb was statistically superior for reduced exudate, odour and oedema levels ( $p=0.005$ ).

Another randomised controlled trial was conducted in pressure ulcers (Kerihuel et al, 2003). The wounds included in the study were moderately exudative but not clinically infected. The control group was treated with a hydrocolloid dressing. Patients were followed up to healing or up to eight

weeks. In the study group, Actisorb was used initially and then switched to an interface dressing (Adaptic [Johnson & Johnson]) as soon as complete debridement was achieved. Wounds were medically assessed weekly and all local care was recorded. Sixty-two patients were included in the study. Wound area decreased similarly with both dressing strategies (centralised and blind measurement of wound tracings). Time to reach debridement was, however, shorter with Actisorb (26 [ $\pm$ 9 days] versus 31 [ $\pm$ 5 days] days). Effective debridement was defined as a wound with no or very weak exudation, less than 25% of its surface still covered by slough and no more black necrotic tissue. Achievement of debridement was to be documented by a picture. Local tolerance of applied dressings was good in both groups.

##### Randomised controlled trials with Actisorb with silver

Millward (1991) compared Actisorb dressing with silver with two control dressings (a chlorhexidine paraffin gauze and a charcoal dressing) on 60 patients with leg ulcers. All wounds were swabbed at weekly intervals for two weeks before the study start and for four weeks with the test dressings in use. Wounds were assessed subjectively at each dressing change according to a standard scale. The overall assessments of dressing performance supported a higher efficiency of Actisorb dressing with silver wound management in wound cleansing, malodour control and exudate reduction. All Actisorb treated wounds showed healing improvement.

Wunderlich and Orfanos (1991) treated 40 patients with chronic VLU. They were randomised to either conventional (zinc paste bandages) or test (Actisorb dressing with silver) therapy. During the six-week treatment period, wound parameters were measured (ulcer size, odour, necrotic tissue, epithelialisation, erythema, oedema). Nineteen patients completed the treatment period in each group. Actisorb dressing with silver was statistically superior to the control ( $p<0.05$ ) in terms of wound area reduction with six ulcers (32%) healed, compared with two (10%) in the control group.



In another randomised trial conducted in venous leg ulcers (VLU) (Kerihuel and Dujardin-Detrez, 2003), controlled groups were treated with a hydrocolloid dressing. Patients were followed up to healing or up to eight weeks. In the study group, Actisorb dressing with silver was used initially and then switched to an interface dressing (Adaptic) as soon as complete debridement was achieved. Wounds were medically assessed weekly and all local care was recorded. Sixty patients were enrolled and all received compression bandaging. At one week visit, median regression of wound area was 15% in the Actisorb dressing with silver group and 3% in the control group ( $p=0.07$ ). A 50% or more area reduction was observed in 53.3% of the patients treated with Actisorb, as compared with 46.7% in the hydrocolloid group.

Finally, Verdu Soriano et al (2004) confirmed that Actisorb dressing with silver reduced bacterial burden. In this trial, the effect of Actisorb dressing with silver in reducing the level of bacteria in chronic wounds with no clinical signs of local infection was compared with cleansing and debridement (control group). Patients were randomly assigned to the intervention or control group and followed over two weeks. Surface smear (spatula) and percutaneous aspiration were performed at baseline and after 15 days. Sixty-seven lesions were included in the intervention group and 58 in the control group. At baseline in the intervention group, 71.6% of the wounds were contaminated ( $\leq 10^3$  colony forming unit [CFU]), 7.5% had a high level of bacteria ( $\leq 10^4$  CFU) and 20.9% were bacteriologically considered infected ( $\geq 10^5$  CFU). At baseline in the control group, 65.5% of the wounds were contaminated, 13.8% colonised or had a high level of bacteria, and 20.7% were infected. After two weeks, 85.1% (57/67) of the contaminated/colonised wounds in the intervention group had a reduction in the number of bacteria compared with 62.1% (36/58) in the control group ( $p=0.003$ ). For infected wounds at baseline, the bacterial level was still  $\geq 10^5$  CFU at two weeks in 7.1% (1/14) and 75.0% (9/12) in the Actisorb dressing with silver and control groups respectively ( $p=0.001$ ).

#### Other clinical evidence

Other data from non-controlled studies and large population surveys or case reports support the clinical benefit of using Actisorb dressing with silver in various clinical situations (White, 2001; Kerihuel and Dujardin-Detrez, 2003).

Furthermore, some evidence may support extension of the use of Actisorb dressing with silver to other types of wounds. As documented by Leak et al (2002), any breach in the integrity of the skin (e.g. incisions, intravascular catheters) can act as a portal for the ingress of microorganisms and thereby predispose the patient to infection. The infection, if unchecked, can put the patient at risk of bacteraemia. In cases of percutaneous enterostomal gastrostomy (PEG) sites, implementation of a protocol for skin care around PEG sites, including the use of Actisorb dressing with silver, indicates that patient comfort can be improved, hypergranulation reduced, and methicillin-resistant *Staphylococcus aureus* colonisation and infection eradicated (Leak et al, 2002).

#### Conclusion

Actisorb dressing with silver consists principally of activated carbon impregnated with metallic silver. This dressing combines the adsorption capacity of activated charcoal to the large-spectrum antibacterial properties of silver. In the author's practical experience, Actisorb actively modulates the impaired wound healing process of chronic wounds. Its main property is its potential to adsorb and neutralise the bacterial toxins locally released and to reduce the inappropriate high level of cytokines in the wound exudate of chronic wounds. In addition, incorporating silver actively participates in decreasing bacterial bioburden and biofilm growth, a major factor of chronicity.

Overall, the various studies discussed above support that Actisorb dressing with silver is a therapeutic alternative when treating chronic wounds that are stuck in an inflammatory stage. It may be used in the treatment of most types of chronic wounds but seems particularly useful for the management of strongly colonised wounds, and even of heavily

exuding ulcers if combined with a high-absorbing secondary dressing such as a foam dressing. **WUK**

#### References

- Baker FS, et al (1992) Activated carbon. *Kirk-Othmer Encyclopedia of Chemical Technology*, 4. John Wiley and Sons, Chichester: 1015–37
- Bjarnsholt T, Kirketerp-Møller K, Jensen PØ, et al (2008) Why chronic wounds will not heal: a novel hypothesis. *Wound Repair Regen* 16(1): 2–10
- Bowler PG, Davies BJ (1999) The microbiology of infected and noninfected leg ulcers. *Int J Dermatol* 38(8): 573–8
- Bowler PG, Duerden BI, Armstrong DG (2001) Wound microbiology and associated approaches to wound management. *Clin Microbiol Rev* 14(2): 244–69
- Castellano JJ, Shafii SM, Ko F, et al (2007) Comparative evaluation of silver-containing antimicrobial dressings and drugs. *Int Wound J* 4(2): 114–22
- Chakravarthi A, Srinivas CR, Mathew AC (2008) Activated charcoal and baking soda to reduce odor associated with extensive blistering disorders. *Indian J Dermatol Venereol Leprol* 74(2): 122–4
- Cole L, Bellomo R, Davenport P et al (2002) The effect of coupled haemofiltration and adsorption on inflammatory cytokines in an ex vivo model. *Nephrol Dial Transplant* 17(11): 1950–6
- Davies CE, Hill KE, Wilson MJ et al (2004) Use of 16S ribosomal DNA PCR and denaturing gradient gel electrophoresis for analysis of the microfloras of healing and nonhealing chronic venous leg ulcers. *J Clin Microbiol* 42(8): 3549–57
- Davies CE, Hill KE, Newcombe RG et al (2007) A prospective study of the microbiology of chronic venous leg ulcers to reevaluate the clinical predictive value of tissue biopsies and swabs. *Wound Repair Regen* 15(1): 17–22
- Ditter B, Urbaschek R, Urbaschek B (1983) Ability of various adsorbents to bind endotoxins *in vitro* and to prevent orally induced endotoxemia in mice. *Gastroenterology* 84(6): 1547–52
- Drucker MM, Goldhar J, Ogra PL, Neter E (1977) The effect of attapulgit and charcoal on enterotoxicity of *Vibrio cholerae* and *Escherichia coli* enterotoxins in rabbits. *Infection* 5(4): 211–3
- Du XN, Niu Z, Zhou GZ, Li ZM (1987) Effect of activated charcoal on endotoxin adsorption. Part I. An *in vitro* study. *Biomater Artif Cells Artif Organs* 15(1): 229–35

- Ebright JR (2005) Microbiology of chronic leg and pressure ulcers: clinical significance and implications for treatment. *Nurs Clin North Am* 40(2): 207–16
- Edwards R, Harding KG (2004) Bacteria and wound healing. *Curr Opin Infect Dis* 17(2): 91–6
- Fleck CA (2006) Differentiating MMPs, biofilm, endotoxins, exotoxins, and cytokines. *Adv Skin Wound Care* 19(2): 77–81
- Gjødssbøl K, Christensen JJ, Karlsmark T, Jørgensen B, Klein BM, Krogfelt KA (2006) Multiple bacterial species reside in chronic wounds: a longitudinal study. *Int Wound J* 3(3): 225–31
- Halbert AR, Stacey MC, Rohr JB, Jopp-McKay A (1992) The effect of bacterial colonization on venous ulcer healing. *Australas J Dermatol* 33(2): 75–80
- Hill KE, Davies CE, Wilson MJ et al (2003) Molecular analysis of the microflora in chronic venous leg ulceration. *J Med Microbiol* 52(Pt 4): 365–9
- Howell CA, Sandeman SR, Phillips GJ et al (2006) The in vitro adsorption of cytokines by polymer-pyrolised carbon. *Biomaterials* 27(30): 5286–91
- Jones SG, Edwards R, Thomas DW (2004) Inflammation and wound healing: the role of bacteria in the immuno-regulation of wound healing. *Int J Low Extrem Wounds* 3(4): 201–8
- Kerihuel JC (2008) The economic impact of using silver releasing dressings in the management of chronic wounds: have we the required evidence to conduct such evaluations? The example of VLU. *J Wound Technology* 1(2): 70–3
- Kerihuel JC, Dujardin-Detrez S (2003) Actisorb®Plus 25, a review of its clinical experience based on more than 12 000 various wounds. *JPC* 8(39): 3–7
- Kirketerp-Møller K, Jensen PØ, Fazli M et al (2008) Distribution, organization, and ecology of bacteria in chronic wounds. *J Clin Microbiol* 46(8): 2717–22
- Lansdown AB (2002) Silver. I: Its antibacterial properties and mechanism of action. *J Wound Care* 11(4): 125–30
- Leak K (2002) PEG site infections: a novel use for Actisorb® Silver 220. *Br J Community Nurs* 7(6): 321–5
- Lee G, Anand SC, Rajendran S, Walker I (2006) Overview of current practice and future trends in the evaluation of dressings for malodorous wounds. *J Wound Care* 15(8): 344–6
- Lim T, Mwipatayi B, Murray R, Sieunarine K, Abbas M, Angel D (2006) Microbiological profile of chronic ulcers of the lower limb: a prospective observational cohort study. *ANZ J Surg* 76(8): 688–92
- Maitra SK, Yoshikawa TT, Guze LB, Schotz MC (1981) Properties of binding of *Escherichia coli* endotoxin to various matrices. *J Clin Microbiol* 13(1): 49–53
- Malic S, Hill KE, Hayes A, Percival SL, Thomas DW, Williams DW (2009) Detection and identification of specific bacteria in wound biofilms using peptide nucleic acid fluorescent in situ hybridization (PNA FISH). *Microbiology* 155(Pt 8): 2603–11
- Marsh H, Rodriguez-Reinoso F (2006) *Activated carbon*. Elsevier, Oxford: 536
- Martin JM, Zenilman JM, Lazarus GS (2009) Molecular microbiology: new dimensions for cutaneous biology and wound healing. *J Invest Dermatol* July 23 [Epub ahead of print]
- McDonald A, Lesage P (2006) Palliative management of pressure ulcers and malignant wounds in patients with advanced illness. *J Palliat Med* 9(2): 285–95
- Millward P (1991) Comparing treatments for leg ulcers. *Nurs Times* 87(13): 70–2
- Muller G, Winkler Y, Kramer A (2003) Antibacterial activity and endotoxin-binding capacity of Actisorb Silver 220. *J Hosp Infect*, 53(3): 211–4
- Mulligan CM, Bragg AJ, O'Toole OB (1986) A controlled comparative trial of Actisorb activated charcoal cloth dressings in the community. *Br J Clin Pract* 40(4): 145–8
- Naka K, Watarai S, Tana, et al (2001) Adsorption effect of activated charcoal on enterohemorrhagic *Escherichia coli*. *J Vet Med Sci* 63(3): 281–5
- Nolan JP, McDevitt JJ, Goldmann GS, Bishop C (1975) Endotoxin binding by charged and uncharged resins. *Proc Soc Exp Biol Med* 149(3): 766–70
- Ovington L (2003) Bacterial toxins and wound healing. *Ostomy Wound Manage* 49(7A Suppl): 8–12
- Panuncialman J, Falanga V (2009) The science of wound bed preparation. *Surg Clin North Am* 89(3): 611–26
- Penhallow K (2005) A review of studies that examine the impact of infection on the normal wound-healing process. *J Wound Care* 14(3): 123–6
- Percival SL, Bowler PG, Russell D (2005) Bacterial resistance to silver in wound care. *J Hosp Infect* 60(1): 1–7
- Rhoads DD, Wolcott RD, Percival SL (2008) Biofilms in wounds: management strategies. *J Wound Care* 17(11): 502–8
- Sandeman SR, Howell CA, Mikhalovsky SV, et al (2008) Inflammatory cytokine removal by an activated carbon device in a flowing system. *Biomaterials* 29(11): 1638–44
- Sapico FL, Ginunas VJ, Thornhill-Joynes M, et al (1986) Quantitative microbiology of pressure sores in different stages of healing. *Diagn Microbiol Infect Dis* 5(1): 31–8
- Seaman S (2006) Management of malignant fungating wounds in advanced cancer. *Semin Oncol Nurs* 22(3): 185–93
- Sibbald RG, Orsted H, Schultz GS, Coutts P, Keast D (2003) Preparing the wound bed 2003: focus on infection and inflammation. *Ostomy Wound Manage* 49(11): 23–51
- Singh VA, Barbul A (2008) Bacterial biofilms in wounds. *Wound Repair Regen* 16(1): 1.
- Tomljanovic-Veselski M, Zilih-Ostojic C, Topolovac Z, Desic-Brkic A, Dokuzovic (2005) Colonization of venous leg ulcers by microorganisms. *Acta Dermatovenerol Croat* 13(2): 104–7
- Thomas S, McCubbin P (2003) A comparison of the antimicrobial effects of four silver-containing dressings on three organisms. *J Wound Care* 12(3): 101–7
- Verdú Soriano J, Rueda López J, Martínez Cuervo F, Soldevilla Agreda J (2004) Effects of an activated charcoal silver dressing on chronic wounds with no clinical signs of infection. *J Wound Care* 13(10): 419, 421–3
- White RJ (2001) A charcoal dressing with silver in wound infection: clinical evidence. *Br J Community Nurs* 6(12): Silver Supp 2
- Wolcott RD, Rhoads DD, Dowd SE (2008) Biofilms and chronic wound inflammation. *J Wound Care* 17(8): 333–41
- Wunderlich U, Orfanos CE (1991) Treatment of venous leg ulcers with silver-impregnated xerodressings. *Hautartz* 42: 446–50
- Xu L, McLennan SV, Lo L, Natfaji A et al (2007) Bacterial load predicts healing rate in neuropathic diabetic foot ulcers. *Diabetes Care* 30(2): 378–80
- Young CV (2005) The effects of malodorous fungating malignant wounds on body image and quality of life. *J Wound Care* 14(8): 359–62
- Zamboni P, Lanzara S, Mascoli F, Caggiati A, Liboni A (2008) Inflammation in venous disease. *Int Angiol* 27(5): 361–9

## Key points

- ▶▶ Activated charcoal has huge adsorption capacities for wound debris, bacterial species and bacterial toxins as well as for volatile amines.
- ▶▶ By combining silver to charcoal, this dressing will decrease local bacterial burden.
- ▶▶ Actisorb Silver is an efficient tool to help manage debridement of chronic wounds.