

# Using negative pressure wound therapy to manage severe military trauma wounds

The injuries sustained by British soldiers in Afghanistan and Iraq are frequently associated with extensive soft tissue stripping contamination and high levels of exudate. They are particularly prone to infection by both bacteria and fungi. Wound management in such scenarios is therefore challenging. Negative pressure wound therapy (NPWT) has been found to be extremely effective in the treatment of such wounds. This article looks at three cases of traumatic wounds (two military wounds and one traumatic crush wound) and how the use of NPWT, particularly using a gauze-based system, has helped to optimise care.

Jean-Pierre St Mart, Steven Jeffery, John Clark

## KEY WORDS

Exudate

Open cell polyurethane

Military wounds

Negative pressure wound therapy (NPWT)

British forces have been engaged in conflicts in Iraq and Afghanistan for several years. Those soldiers who sustain injuries caused by improvised explosive devices (IEDs), landmine explosions and gunshot wounds are all transferred for treatment to the University Hospital Birmingham Foundation Trust and the Royal Centre for Defence Medicine in Birmingham. The injuries sustained are frequently associated with extensive soft tissue stripping and contamination, and often produce high levels of exudate. These wounds are particularly prone to infection by both bacteria and fungi. Wound management for these patients is therefore challenging.

Jean-Pierre St Mart is Core Surgical Trainee Year 1; Steven Jeffery, Lt Col Royal Army Medical Corps is Consultant Plastic and Reconstructive Surgeon; Major John Clark is Senior Burns and Plastic Surgery Military Nurse Specialist, Burns and Plastics, all at The Royal Centre for Defence Medicine, Selly Oak Hospital, Birmingham

Fungal wound infection is a major problem during the initial stages of management. Buildings in Iraq and Afghanistan often have foundations that are composed of animal dung slurry. The initial blast when a soldier steps on an IED can blow some of this contaminated material in between the soft tissue planes (i.e. muscle). This is then followed by a suction effect which can 'lock' these dung particles into the remaining tissue stump. This provides an optimal environment for bacterial and fungal species to grow which is exacerbated by the surrounding humidity in the war zones. Thus, after the soldier is transferred to Birmingham for definitive treatment, bacterial or fungal wound infection can already be well established. Initial management therefore involves stabilising the patient (sometimes after a traumatic double amputation), and salvaging as much of the remaining limbs as possible without exposing the patient to an unnecessary high risk of infection. The authors have found that using negative pressure wound therapy (NPWT) optimises wound bed preparation, exudate management and infection control, and contributes to eventual wound closure and improvement of the patient's overall condition.

NPWT has become an accepted option for managing and treating

trauma cases (Kanakaris et al, 2007). More recently, NPWT has been incorporated into the management of extensive compound fractures of the lower limbs due to its ability to handle high volumes of exudate and provide a closed wound environment (Steiert et al, 2009).

NPWT applies sub-atmospheric pressure to the wound bed through a wound-filler material which is subsequently covered with an adhesive dressing providing an air-tight seal. Suction apparatus is then connected to the dressing, thus drawing off exudate into a collection device. Until recently, the only wound-filler material available was an open cell polyurethane (PU) foam, supplied as part of the VAC<sup>®</sup> system (KCI). However, new alternative wound fillers including non-adherent gauzes are now commercially available in several alternative NPWT devices, including WoundASSIST TNP<sup>™</sup> by Huntleigh<sup>®</sup>. This method is based on the Chariker-Jeter system (1989). It incorporates a single layer of saline-moistened antimicrobial gauze which is impregnated with polyhexamethylene biguanide (PHMB) and laid directly onto the wound bed. A silicone drain is sandwiched between the gauze and a further layer of similar gauze material is placed on top to fill in the wound deficit. This is covered with a clear

semi-permeable film which is cut so that the remaining border is at least 2–3cm around the wound. The use of NPWT at the wound centre has seen a change from using foam only, to a combination of sponge and gauze depending on the wound.

The following three cases illustrate how the WoundASSIST TNP system has been used in wound bed preparation to eventually achieve wound closure. The objectives were to stabilise soft tissue, salvage compromised tissue, prevent infection, reduce oedema, wound size, the number and frequency of dressing changes, and, finally, the complexity of the wound itself in order to facilitate further reconstruction of lost tissue.

#### Case one: traumatic injury to both legs and left hand

A 24-year-old soldier was injured when he stood on an IED in Afghanistan. The patient initially sustained both left and right below-knee traumatic amputations (Figure 1). He also had a traumatic amputation of the tip of his left index finger and had sustained significant damage to the urethra, as well as multiple penile and genital fragment wounds.

Microbiological investigation revealed *Bacillus* and *Fusarium* species within the patient's right leg wound. In such cases thorough wound debridement is essential before attempting wound closure to promote wound healing and minimise the risk of infection.

Initially the patient underwent several theatre sessions for debridement of all wounds. Equipment used in debridement included the Versajet hydrosurgery system (Smith & Nephew). The patient underwent urethral reconstruction with an interposition graft of buccal mucosa from his right cheek and debridement of scrotum and penile wounds.

After several sessions of debridement the patient ended up with an above-knee amputation on his left leg due to initial inadequate tissue coverage. However, there was adequate skin coverage and no grafting was required.

The right below-knee amputation did not initially have sufficient skin coverage. Topical NPWT was therefore applied using the WoundASSIST TNP system after initial debridement to prepare the wound for skin grafting.

Before applying NPWT, chlorhexidine gluconate 0.5% with isopropyl alcohol 70% was used to degrease the surrounding skin. The wounds and surrounding skin were carefully dried, which allowed a good seal to be maintained once vacuum pressure was applied. The authors have found through experience that application of an adhesive solution to the surrounding skin, especially in junctional areas such as the groin in a high amputation, provides a more secure seal. Whitehead's varnish has been most effective, as has been tincture of benzoin (Friar's Balsam).

Once the adhesive was applied to the surrounding skin, the antimicrobial gauze (Kerlix™, Covidien) was laid into the wound. Heavily exuding wounds do not require the gauze to be pre-wet. It is important to ensure that the gauze is lightly packed into all crevices so as to be in contact with all parts of the wound.

A drain was then placed onto the gauze, with further gauze packed on top. The transparent adhesive moisture vapour permeable film was laid over the area to complete the seal.

For heavily exuding wounds the drain is connected and suction is applied on 'maximum' setting before attempting to seal the film. This removes any exudate that may potentially leak out and ruin the seal, as well as identifying any possible leaks. It is important that every part of the skin in contact with the film is dry as obtaining and maintaining a good seal is critical to the success of NPWT.

The manufacturer's instructions have an optimal flow rate of -75mmHg, but rates should be adjusted to take account of individual requirements. The authors have used two WoundASSIST TNP systems in situations where there has been an exceptionally large amount

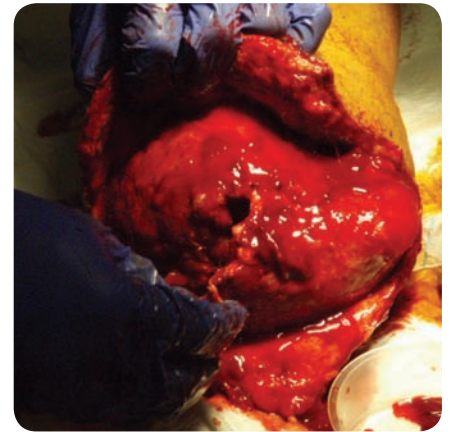


Figure 1. IED injury showing patient's right leg stump.

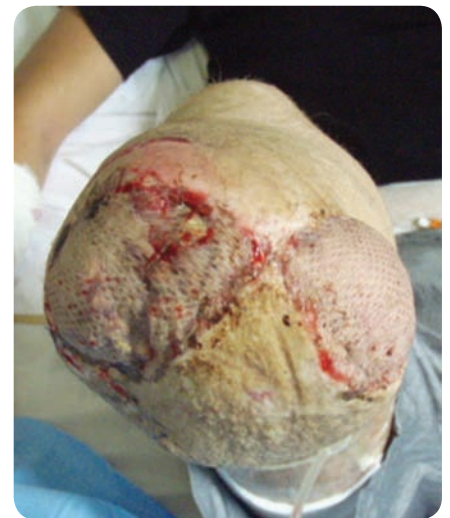

Figure 2. Right leg stump 10 days post graft and five days post NPWT therapy.

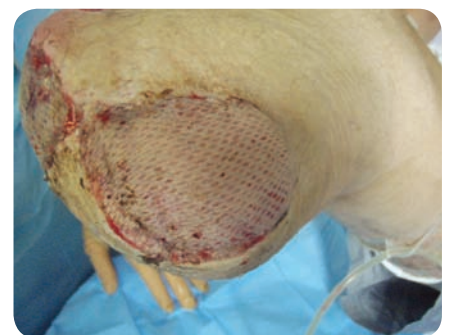

Figure 3. The graft over the right stump was salvaged by NPWT therapy.

of exudate to clear. However, more recently the authors have been using the larger Ezcure pump (Smith & Nephew) with its higher flow rate for excessively exuding wounds. It is not unusual for large wounds, such as this one, to drain up to 4.5 litres per 24 hours and such fluid losses need to be accounted for when calculating fluid requirements.

Further episodes of wound debridement were required due to the fungal infection. After three weeks of intermittent NPWT the right stump wounds were ready for skin grafting. Once grafted the right stump wounds were dressed with a conventional bandage dressing without reapplication of NPWT therapy. The authors regretted this decision when the wound was inspected four days later and the graft over the lateral aspect of the right stump was tented, slightly dusky looking and had not taken well. The NPWT was reapplied as a dressing for protection against infection and shearing forces: the theory being that the direct compression effect would reduce the risk of haematoma or seroma formation and thus reduce the risk of graft failure and potentially salvage the tented graft. This time a layer of Telfa™ (Covidien) was applied between the skin graft and the gauze to prevent accidental removal of the graft at dressing changes.

WoundASSIST TNP was applied to grafted areas for a further five days. All grafts, including that over the lateral part of the right stump, took well and were photographed 10 days post graft (Figures 2 and 3). The soldier's condition continues to improve.

**Case two: traumatic injury to all four limbs**

A 19-year-old soldier was injured after he stepped on an IED in Afghanistan. He required an emergency high, above-knee amputation of his left leg, an above-elbow amputation of his right arm and an external fixator to a compound tibia-fibula fracture in his right leg. His remaining left forearm also had compound radial and ulna fractures with extensive soft tissue damage. Initial surgical treatment involved radical debridement of all traumatic wounds leaving healthy tissue beds. A radial forearm flap was rotated to cover the wrist's soft tissue defect. The left ulna and radial fractures underwent open reduction and internal fixation followed by a free Latissimus dorsi flap for soft tissue coverage. Once the muscle flap had taken well, the soft tissues were covered with a split-skin graft. Given the previous colonisation of the

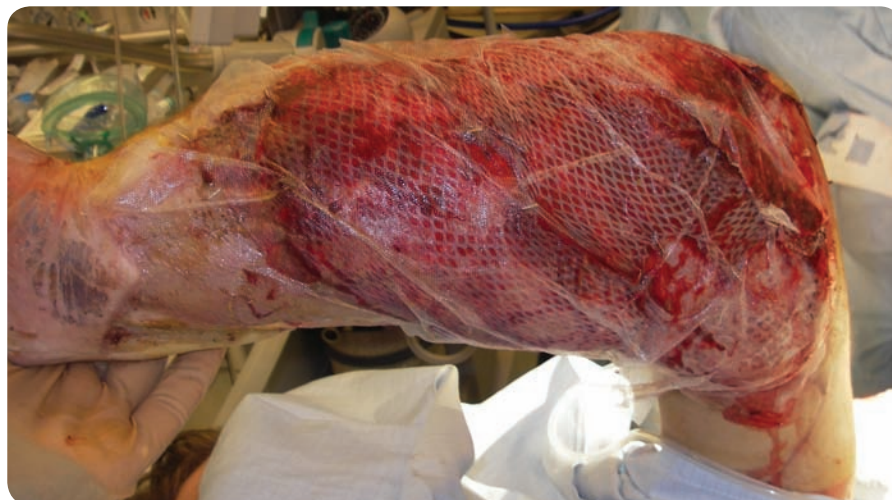

Figure 4. An anti-shear layer of Telfa placed on top of split-skin graft.




Figure 5. A layer of antimicrobial gauze placed over the Telfa dressing.

soldier's wounds with *Pseudomonas* species, it was essential to minimise the risk of infection in order to provide the maximal chance of graft survival. Due to the tissue swelling and heavy exudate, it was felt that conventional dressings would be unsuitable. Therefore, a gauze-based NPWT system (WoundASSIST TNP) was the treatment of choice to provide optimal wound healing, exudate management and a secure dressing (Figures 4–6). There was 100% take of the split-skin graft (Figure 7) and the patient was discharged to a rehabilitation centre two months later.

**Case three: traumatic injury to the right foot**

This case demonstrates how the WoundASSIST TNP system has been useful when treating non-military traumatic injuries. A 43-year-old woman sustained a traumatic crush injury after

a car knocked a concrete bollard onto her left foot. Initially she had several sessions in theatre for debridement of the wound. She ended up with an amputation of her right great, second and third toes and the metatarsal heads were covered with soft tissue. It was noted three weeks after the initial injury that, although there were no signs of cellulitis or formation of a collection, the wound over the amputations had not healed. She therefore underwent split-skin grafting to heal the defect. NPWT using antimicrobial gauze provided optimal dressings, exudate management and graft protection (Figures 8–12). Telfa was used as an anti-shear layer in the dressing. NPWT was removed after seven days. There was excellent take of the graft and the patient was discharged to self-manage the wound with regular dressing changes using Urgotul® Silver (Urgo). Follow-up at clinic five weeks later showed that the wound had fully healed (Figure 13).

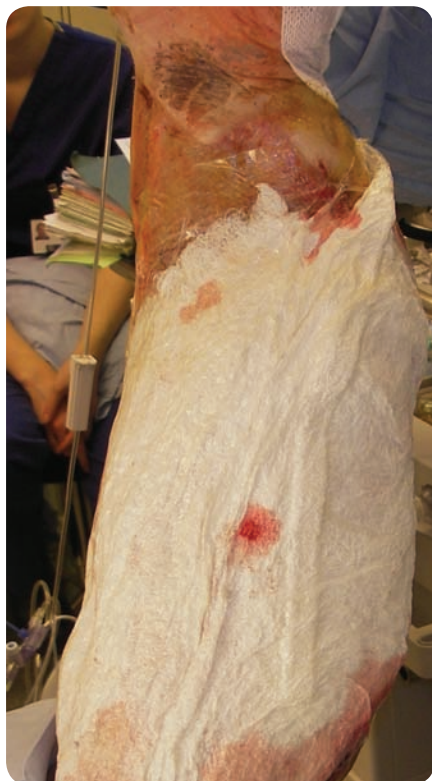

Figure 6. Drain and permeable film placed over wound and NPWT system connected.

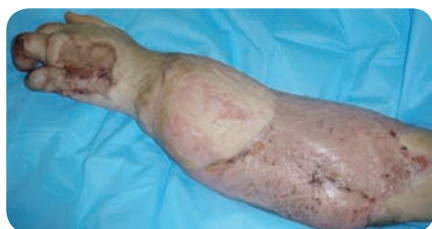

Figure 7. Healed graft over left arm.

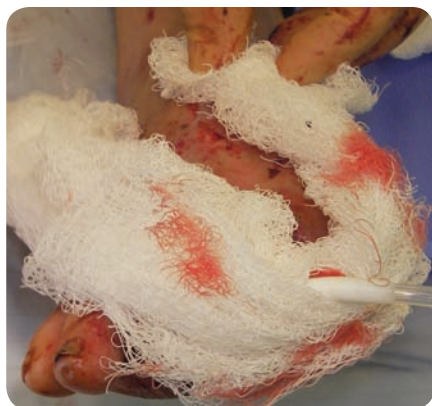

Figure 8. Split skin graft to wound.

### Discussion

Recently, antimicrobial gauze has been reintroduced as a filler material for NPWT, rather than foam-based substances (Timmons, 2006; Hunter et al, 2007; Miller et al, 2007).

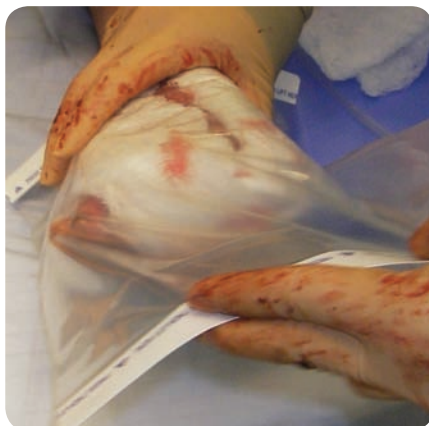

Figure 9. Telfa layer over graft.

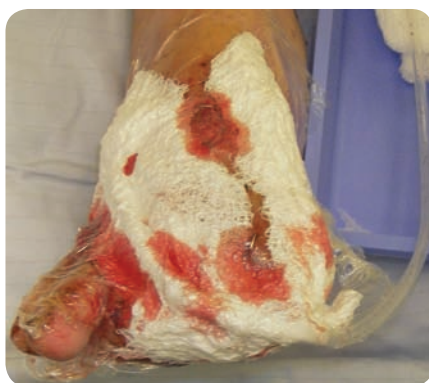

Figure 10. Gauze applied.

Malmsjö et al (2009) using animal-based experiments via a porcine wound model demonstrated that gauze and polyurethane (PU) foam were equally effective at delivering negative pressure, wound contraction and stimulation of blood flow at the wound edge (Malmsjö et al, 2009). Campbell et al (2008) have also shown that wound size reduction progresses at a similar rate (about 15% per week) in both gauze and PU foam wound fillers.

Despite the more frequent use of foam with NPWT systems, the authors have found that it can present a number of problems. It can be difficult to cut the foam to fit the wound exactly. This is particularly apparent with wounds sustained from traumatic blast injuries which are highly irregular in shape and extend over awkward, curved surface areas of the body (Figure 14). Also, the foam block has sides that are perpendicular to the base which are difficult to alter to fit into wounds which commonly have

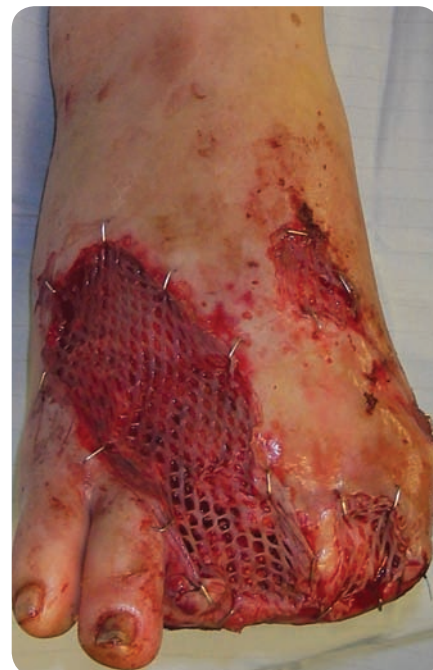

Figure 11. Permeable film applied.

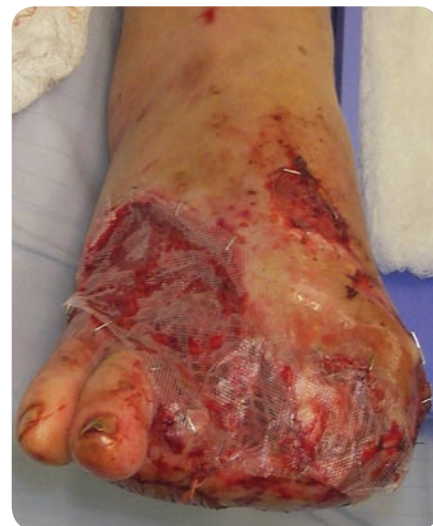

Figure 12. WoundASSIST system connected.

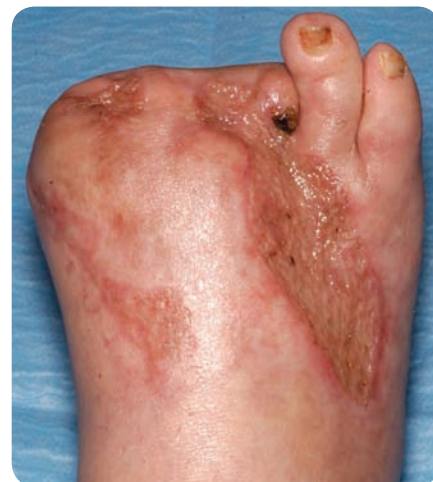

Figure 13. Wound five weeks post grafting

irregular sides that are graduated in depth. While the foam pad is flat, the wound bed is irregularly contoured, and so it only comes into contact with part of the wound base (Figure 15). However, the foam material needs to be in contact with all the wound surface for suction to be effective (Malmjö et al, 2009). Foam is noted to have 'shape memory' which causes it to lift out of curved surfaces when it returns to its original shape. Thus, it does not treat the whole wound base and pulls the skin grafts off the edges of the wound. Several theatre staff are required to hold the foam in place when applying the covering permeable film to achieve a complete seal.

As the foam has to be cut several times to shape, there is increased risk of excess foam fragments being accidentally dropped onto the floor or into the wound. These multiple fragments are sometimes needed to be 'tiled' into irregular wounds and secured to each other using staples which can be an arduous task.

The authors have found that using gauze is a simpler procedure as the material naturally fills the contours of the wound bed. As it can be packed into wound crevices it only requires a rough tailoring of size and is easier to cut to shape (Figure 16).

PU foam filler shrinks when a vacuum is applied to it. Although this is a benefit when encouraging wound healing by primary intention, it is not desirable before reconstruction of acute defects, as the reduction in the area of the defect can cause functional impairments such as reduced range of movement. Wound shrinkage is also a disadvantage in terms of joint contractures and the authors have found that due to the shrinking of the PU foam, there is an even greater risk of pulling the graft away from the wound edges, increasing the risk of sub-optimal skin coverage or even graft failure. In the authors' opinion, this risk does not appear to be present when using gauze-based NPWT systems, as they do not appear to cause as much shrinkage.

Several studies have documented in-growth of granulation tissue into the cells of the PU foam resulting in severe pain at dressing changes and a disturbance in the re-epithelisation process (Kaufman and Pahl, 2003; Bickels et al, 2005; Shirakawa and Isseroff, 2005; Venturi et al, 2005; Campbell, 2006; Pikaitis and Molnar, 2006; Woodfield et al, 2006). The authors' have found that foam-based NPWT systems are associated with an excess of granulation tissue through the skin graft resulting in poorer cosmesis.

The Chariker-Jeter system has the potential to reduce pain and cause less disturbance to granulation tissue at dressing changes than foam-based systems (Miller and McDaniel, 2006). The authors have noted that some patients have required Ketamine

sedation at dressing changes with the foam-based VAC system, while patients with gauze-based NPWT therapy and comparable wounds have tolerated dressing changes without sedation.

Kerlix gauze (Covidien) is impregnated with PHMB which has antimicrobial properties. Thus, if the vacuum is lost the antimicrobial layer acts as a reasonable barrier against infection and the patient does not necessarily require the NPWT system replaced immediately. With foam-based systems that traditionally do not have antimicrobial properties, the manufacturers advise the TNP system be replaced within a couple of hours of loss of suction to minimise the risk of infection. Given that many patients require sedation or even a general anaesthetic for foam-based dressing changes, this is sometimes impractical.

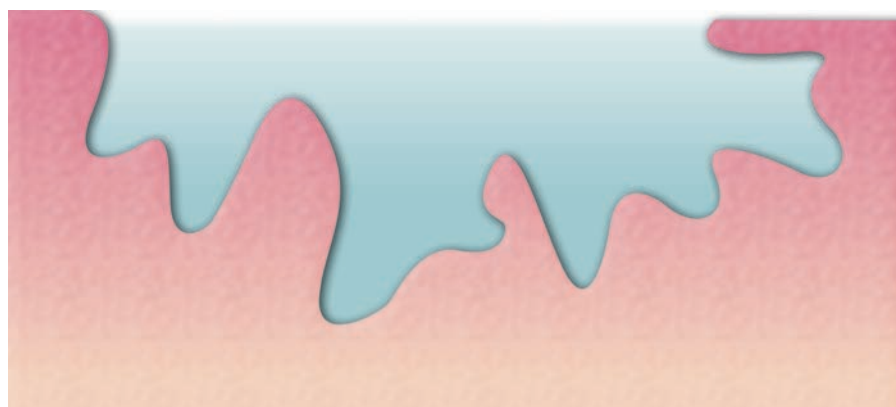


Figure 14. Typical wound shape resulting from IED device.

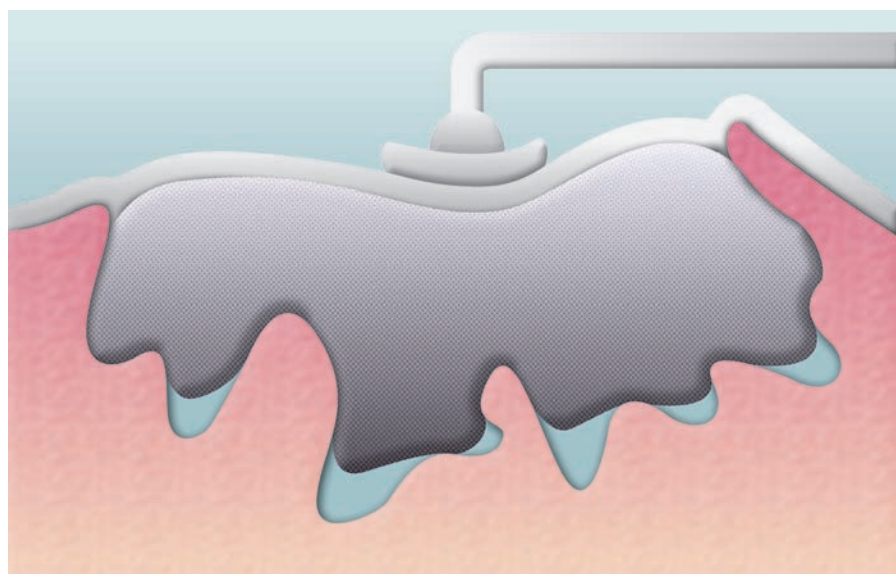


Figure 15. Foam packed with only partial contact to the wound bed despite NPWT.

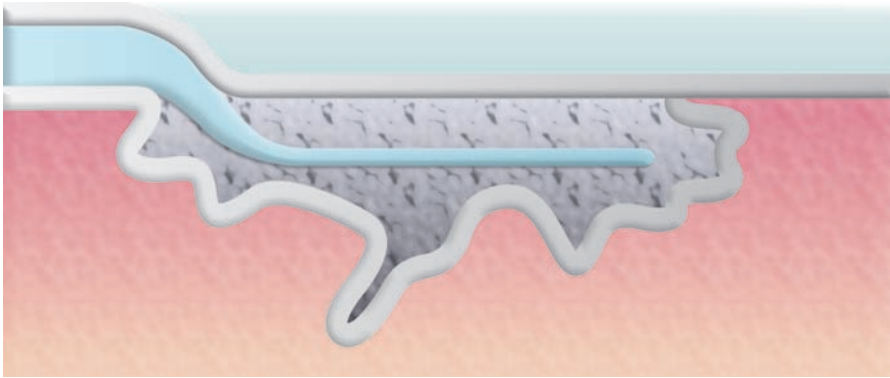


Figure 16. Gauze packed within a typical wound with contact to entire wound bed.

Recent advances have resulted in foam materials that have been modified to contain micro-bonded metallic silver. However, these are more expensive and are not widely used at present.

It should be remembered that it is unwise to rely completely on topical antimicrobials to prevent infection. The primary treatment of at-risk wounds should be thorough debridement and antibiotics. The decision to use antimicrobials should be based on an assessment of the most likely pathogens present in the wound.

### Conclusion

NPWT systems are frequently used to treat complex traumatic wounds as they provide great advantages for wound bed preparation and infection control (Jeffery, 2009). Due to their location, extent and level of exudate, such wounds would be difficult to treat with conventional dressings. Conventional NPWT systems have previously used a foam-based filler. The authors have found that the antimicrobial gauze-based WoundASSIST TNP system is more versatile and capable of treating a larger variety of traumatic wounds. The gauze wound filler used in the WoundASSIST TNP system also has advantages for the surgical team in its conformability and ease of application to irregular wounds. **WUK**

### References

Bickels J, Kollender Y, Wittig JC, Cohen N, Meller I, Malawer MM (2005) Vacuum-assisted wound closure after resection of musculoskeletal tumors. *Clin Orthop Relat Res* 441: 346–50

Campbell P (2006) Surgical wound case studies with the Versatile 1 wound vacuum

system for negative pressure wound therapy. *J Wound Ostomy Cont Nurs* 33: 2–10

Campbell PE, Smith GS, Smith JM (2008) Retrospective clinical evaluation of gauze-based negative pressure wound therapy. *Int Wound J* 5: 280–6

Chariker ME, Jeter KF, Tintle TE (1989) Effective management of incisional and cutaneous fistulae with closed suction wound drainage. *Contemp Surg* 34: 59–63

Hunter JE, Teot L, Horch R, Banwell PE (2007) Evidence-based medicine: vacuum-assisted closure in wound care management. *Int Wound J* 4(3): 256–69

Jeffery SLA (2009) Advanced wound therapies in the management of severe military lower limb trauma: a new perspective. *Eplasty* 9: e28

Kanakaris NK, Thanasis C, Keramaris N, Kontakis G, Granick MS, Giannoudis PV (2007) The efficacy of negative pressure wound therapy in the management of lower extremity trauma: review of clinical evidence. *Injury* 38(S5): S9–18

Kaufman M, Pahl D (2003) Vacuum-assisted closure therapy: wound care and nursing implications. *Derm Nurs* 4: 317–25

Malmsjö M, Ingemansson R, Martin R, Huddleston E (2009) Negative pressure wound therapy using gauze or polyurethane open cell foam: similar early effects on pressure transduction and tissue contraction in an experimental porcine wound model. *Wound Rep Regen* 17(2): 200–5

Miller M, McDaniel C (2006) Treating wound dehiscence with an alternative system of delivering topical negative pressure. *J Wound Care* 15(7): 321–4

Miller MS, Ortegon M, McDaniel C (2007) Negative pressure wound therapy: treating a venomous insect bite. *Int Wound J* 4: 88–92

Pikaitis C, Molnar J (2006) Subatmospheric pressure wound therapy and the vacuum assisted closure device: basic science and current clinical successes. *Exp Rev Med Dev* 3(2): 175–84

### Key points

- ▶▶ The injuries sustained by British soldiers in Afghanistan and Iraq are frequently associated with extensive soft tissue stripping contamination, and high levels of exudate.
- ▶▶ After the soldier is transferred to Birmingham for definitive treatment, bacterial or fungal wound infection can already be well established.
- ▶▶ Negative pressure wound therapy (NPWT) optimises wound bed preparation, exudate management and infection control, and contributes to eventual wound closure and improvement of the patient's overall condition.
- ▶▶ Recently, antimicrobial gauze has been reintroduced as a filler material for NPWT, rather than foam-based substances (Timmons, 2006; Hunter et al, 2007; Miller et al, 2007).

Shirakawa M, Isseroff R (2005) Topical negative pressure devices. *Arch Dermatol* 141(11): 1449–53

Steiert AE, Gohritz A, Schreiber TC, Krettek C, Vogt PM (2009) Delayed flap coverage of open extremity fractures after previous vacuum-assisted closure (VAC) therapy. *J Plast Reconstr Surg* 62: 675–83

Timmons J (2006) The use of the versatile-1 wound vacuum system to treat a patient with a challenging grade 3 pressure ulcer in continuing care. *Wounds* 2: 125

Venturi ML, Attinger CE, Mesbahi AN, Hess CL, Graw KS (2005) Mechanisms and clinical applications of the vacuum assisted closure (VAC) device: a review. *Am J Derm* 6(3): 185–94

Woodfield JC, Parry BR, Bissett IP, McKee M (2006) Experience with the use of vacuum dressings in the management of acute enterocutaneous fistulas. *ANZ J Surg* 76(12): 1085–7