

# Treating pilonidal sinus wounds with an antibacterial wound gel after incision and drainage

Tanya Grant is Wound Therapist Nurse, Wound Clinic, Medway Primary Care Trust, Healthy Living Centre, Rochester

Pilonidal sinus disease is a sinus or epithelial tract which is found in the skin of the natal cleft close to the anus and often contains hair. The cause of pilonidal disease is not clearly understood but the present consensus is that cysts form by overstretching and enlargement of the hair follicles in the natal cleft which then becomes blocked with keratin and can lead to rupture of the follicle and infection with the formation of an abscess. Hair within the follicle can become trapped in the skin and cause further irritation and infection (Bascom, 2008). Sondenaar et al (1995) report evidence of certain risk factors associated with the disease, including obesity, sedentary occupation, hirsuteness and local irritation or trauma.

## Treatment

Berry and Harding (1992) state that antibiotic therapy given orally may reduce bacterial levels within the sinus and reduce the risk of sepsis. Al-Hassan et al (1990) discuss primary closure of the wound which entails excision of the sinus followed by suturing along the mid-line. Flap surgery is another option, often reserved for patients that have recurring pilonidal sinus. This involves donor skin and fascia formation (Torkington, 2004). Abscess formation demands urgent treatment and the pilonidal sinus should be incised and drained thereby reducing inflammation and removing pus. The patient undergoing surgery is usually given oral antibiotic therapy.

## Wound management

Following incision and drainage the wound is healed by secondary intention allowing it to granulate from the base (Miller and Harding, 2003). Traditionally the wound requires daily packing with an absorbent dressing. Alginate or hydrofibre dressings are often used with a secondary dressing that absorbs exudate and helps to prevent cross-infection.

## Case reports

At the author's workplace — a specialist

wound clinic — patients with pilonidal sinus post incision and drainage are common and their wounds often take up to three months or more to heal. Delayed healing is thought to be attributed to infection and is possibly due to the surgical creation of a wound which does not facilitate ease of drainage (Marks et al, 2005). This can cause loss of work time, altered body image, low self-esteem and have a potential effect on relationships, and be a source of embarrassment. (Bradley, 2006).

At this wound clinic a short evaluation was carried out using an antibacterial honey as a primary dressing instead of packing with Aquacel (ConvaTec, Ickenham) and covering the wound with a foam to manage exudate such as Mepilex Border (Mölnlycke, Göteborg) or Allevyn Adhesive (Smith & Nephew, Hull). The clinic wanted to assess whether using an antibacterial product would bring faster healing times and better outcomes for the patients. Medihoney Antibacterial Wound Gel (Comvita, New Zealand) was used, which comes in the form of a wound gel which is packed into the wound. An antibacterial honey may be considered in nearly all instances of pilonidal sinus after incision and drainage surgery. This is because it can eradicate infection, it is anti-inflammatory, it removes malodour, debrides and maintains a moist wound healing environment (Bradley, 2006). The antibacterial honey should be the initial dressing with a secondary dressing in place that can absorb exudate and will be atraumatic at dressing changes.

Three patients were asked on their initial visit to the clinic if they would participate in this 12-week trial and all three consented. All three wounds were dressed daily with Medihoney as a primary dressing and with the same adhesive foam as a secondary dressing (Mepilex Border or Allevyn Adhesive). No other patients presented with pilonidal sinus disease during the 12-week trial.

### Patient 1

The patient was fit and healthy and had presented with an abscess which was incised and left open for secondary healing and drainage. The wound measured 2.5cm in

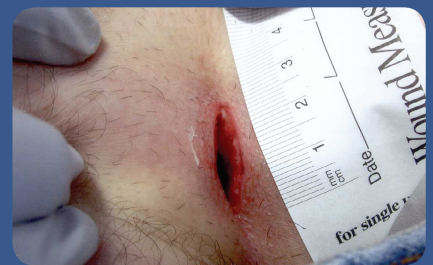

Figure 1. Patient 1 at initial assessment.

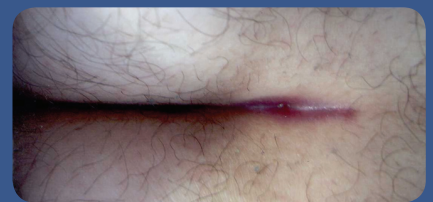

Figure 2. Patient 1 towards the end of their treatment. The wound has less exudate and is progressing to healing.

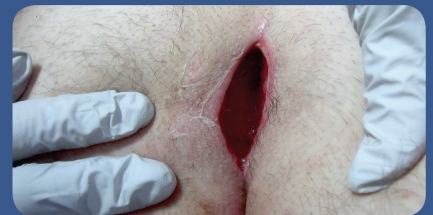


Figure 3. Patient 2 at initial assessment. The wound is 80% granulation and 20% slough.

length, 1 cm in width, 2 cm in depth (Figure 1). There was minimal friable/bleeding tissue with 100% granulation of the wound bed. The exudate was of a medium amount. The peri-wound was intact and healthy looking and there was no malodour. The patient was treated with Medihoney antibacterial wound gel as a primary dressing with an adhesive foam dressing as a secondary dressing for absorption. The patient was treated with Medihoney for four weeks by which time the wound had healed. Throughout the four-week treatment, the wound bed remained constant with 100% granulation tissue. There was only one dressing change that had a mild malodour; otherwise no odour was detected. The patient's pain level remained mild and was only experienced during dressing changes. The exudate level during the first two weeks varied from medium to high and during the last two weeks of treatment reduced to a low

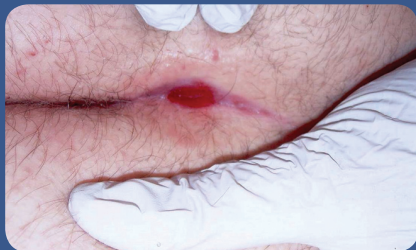

Figure 4. Patient 2 near the end of treatment.

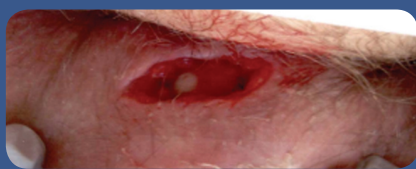


Figure 5. Patient 3 at initial assessment.

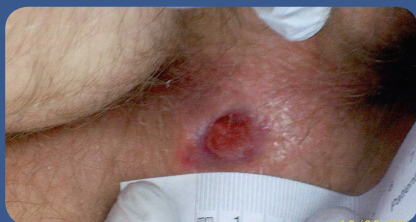

Figure 6. Patient 3 near the end of treatment, exhibiting no depth to the sinus.

level indicating the wound had progressed through the inflammatory stage to granulation (Figure 2). The patient found both the Medihoney gel and the secondary absorbent dressing comfortable. The patient was not discharged from the clinic for a further three weeks as on the final visit, the patient had split the scar area due to excessive physical exertion. No Medihoney was necessary at this time as the wound was relatively minor.

### Patient 2

Patient 2 was fit and healthy and presented with an abscess which was incised and left open for secondary healing and drainage. The wound measured 4.4cm in length, 1.6cm in width and 2.7cm in depth (Figure 3). The wound bed was 80% granulation with 20% slough. There were medium levels of exudate. The peri-wound was healthy and intact with slight irritation in the morning. The primary dressing was Medihoney gel, with an adhesive foam for the secondary dressing. The patient was treated with the Medihoney for a period of

5.5 weeks, until the wound had healed. During the treatment, the wound changed from 10% slough and 90% granulation for one week and 90–100% granulation with 10% epithelisation for the remaining 4.5 weeks (Figure 4). There was only one dressing change that had a mild malodour. All other dressing changes were odourless. Exudate levels ranged from medium to low throughout. The patient complained only of mild pain mid-way through treatment which appeared to resolve of its own accord. The patient found that both the Medihoney and the foam dressing were comfortable.

### Patient 3

Patient 3 presented with an abscess which was incised and left open for secondary healing and drainage. The wound measured 2cm in length, 1cm in width and 0.5cm in depth (Figure 5). The wound bed was 100% granulation. There were medium levels of exudate. The peri-wound was healthy and intact with some irritation. Patient 3 was treated with Medihoney gel as the primary dressing and an adhesive foam as a secondary dressing. The patient was treated with Medihoney gel for two weeks and was discharged from the wound clinic as the wound did not require further dressings. Throughout the treatment the wound bed was 100% granulation tissue (Figure 6) and there was no malodour. Exudate levels were mainly medium but decreased to low near the end of treatment. The only complaints of pain were during the first few days of treatment. This was only mild and subsided quite quickly. The patient found both the Medihoney and the foam dressing comfortable.

### Conclusion

The treatment of pilonidal sinus disease involves incision and drainage. The wound then needs to heal by secondary intention allowing it to granulate from the base. The three evaluations in this study support the use of Medihoney antibacterial wound gel as all three wounds healed within weeks. None of the wounds became infected during the treatment and there was minimal pain for the patients. Dressings were found to be comfortable and easy to apply. The dressings also managed the exudate levels adequately in all three cases so this was not an issue for either the patients or

the nursing staff. Additionally, odour appeared to be well controlled in each case.

Although the clinical evaluation was limited, the use of Medihoney as a primary dressing in the treatment for post-surgical pilonidal sinus wounds demonstrated potential improvement in clinical outcomes compared with previous dressing regimens used with this patient group. The regimen enabled patients to have a quicker return to their previous quality of life compared with cases previously seen in the wound clinic.

As a result of this study, the author's wound clinic has introduced Medihoney as a viable alternative to other treatments previously used. One of the benefits that was particularly appreciated was the reduced treatment time. There has been no research into why these wounds take a long time to heal apart from the previously mentioned infection risk and drainage problems (Marks et al, 2005). It appears to be the cavity and the situation of the wound in a 'sweaty' area. Antibacterial honey may work better than previous treatment due to the antibacterial and anti-inflammatory properties, however, as with most wound dressings further research is required. **WUK**

### References

- Al-Hassan HK, Francis IM, Neglen P (1990) Primary closure or secondary granulation after excision of pilonidal sinus. *Acta Chirurgica Scandinavica* 156(10): 695–9
- Bascom J (2008) Surgical treatment of pilonidal disease. *Br Med J* 336: 842–3
- Berry DP, Harding KG (1992) Treatment of natal cleft sinus. *BMJ* 305(6848): 311
- Bradley L (2006) Pilonidal sinus disease: a misunderstood problem. *Wounds UK* 2(1): 43–53
- Marks J, Harding KG, Hughes LE, Ribeiro CD (2005) Pilonidal sinus excision – healing by open granulation. *Br J Surgery* 72(8): 637–40
- Sondenaa K, Anderson E, Nesvik I, Soreide JA (1995) Pt. Characteristics and symptoms in chronic pilonidal sinus disease. *Int J Colorect Dis* 10(1): 39–42
- Timmons J (2007) Diagnosis, treatment and nursing management of patients with pilonidal sinus disease. *Nurs Stand* 21(52): 48–56