

Celebrating 25 years of Sorbsan and its contribution to advanced wound management

There can be few wound dressings that are still as popular, if not more so, 25 years after its launch. One such range of dressings is Sorbsan alginates from Unomedical (Redditch). Launched in 1983, the range has grown and developed to meet the challenges faced in the management of all types of acute and chronic wounds such as leg ulcers, pressure ulcers, partial thickness burns and surgical wounds. This product review catalogues the evidence that has been produced over the past 25 years and examines Sorbsan's relevance to today's wound care challenges.

Clare Morris

KEY WORDS

Wound care
Alginate dressings
Chronic wounds
Acute wounds
Exudate

Over the past 30 years clinicians have been exposed to a plethora of new advanced wound dressings. Historically, wound dressings were designed to absorb and remove exudate to dry the wound and allow a hard, dehydrated eschar to form in the belief that drier wounds would be less likely to become infected (Benbow, 2008). The moist wound care revolution began in the 1970s with the introduction of films and hydrocolloid dressings, and today these are the traditional types of dressings of the advanced dressing category (Queen et al, 2004).

Alginates have been used in various forms for more than 60 years and yet they remain poorly understood and probably underused (Heenan, 1998). Despite early successes, the use of alginates in wound management

declined until the mid-1980s (Thomas, 1992). Alginate wound dressings are made from seaweed harvested off the coasts of Scotland, Ireland, Norway and many other waters around the world. Seaweed was often called 'The Mariner's Cure' because in the early 1800s, it was discovered to be very effective in treating the wounds of sailors who had been injured in sea battles (Williams, 1998). However, there were no further developments for nearly 150 years when George Blaine, an army major, reported very good results when treating wounds with alginate dressings (Blaine, 1947).

Sorbsan (Unomedical, Redditch) is made from a naturally occurring polysaccharide found in brown seaweed. The species used in Sorbsan is *Laminaria* and *Ascophyllum* which occur in abundance off the coast of Scotland (Williams, 1994). Sorbsan interacts with the exudate from the wound to form a hydrophilic gel. Essentially, calcium ions in the calcium alginate extracted from the seaweed are replaced by Sodium ions found in serum or wound exudate. This exchange of ions allows the alginate fibres to absorb fluid and swell, progressively transforming into a gel at the wound surface (Thomas and Loveless, 1992). It is now commonly used in the management of cavity wounds, surgical wounds, abscesses and sinuses in place of traditional ribbon gauze.

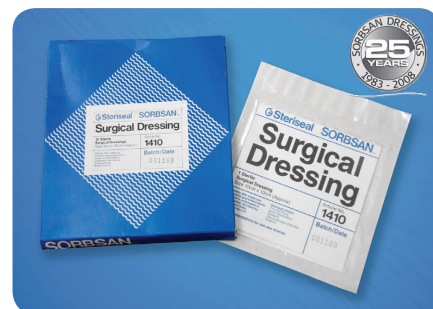

Figure 1. 1980s packaging of the original Sorbsan.

Alginate dressings vary in their chemical structure and it is mainly this variation that is responsible for the differences in the performance and method of use of each alginate. (Thomas and Loveless, 1992). Sorbsan is rich in mannuronic acid which helps to produce a soft amorphous gel that disperses on irrigation. Kaltostat (ConvaTec, Gwent) is an alginate which has a high guluronic acid content which is why the gel produced retains its structure (Williams, 1994).

The concept of wound bed preparation has gained international recognition as a framework that can provide a structured approach to wound management (Dowsett and Newton, 2005). To assist in implementing the concept of wound bed preparation, the TIME acronym was developed in 2002 by a group of wound care experts as a practical guide for use when managing patients with wounds (Schultz et al, 2003). The four

Table 1**Sorbsan range of dressings****Sorbsan**

Flat: 5 x 5cm, 10 x 10cm, 10 x 20cm

Packing: 2g/30cm with plastic probe

Ribbon: 1g/40cm with plastic probe

Sorbsan Plus Non-Adhesive

7.5 x 10cm, 10 x 15cm, 10 x 20cm, 15 x 20cm

Sorbsan Plus Self-Adhesive with adhesive border

11.5 x 14cm, 14 x 19cm, 14 x 24cm, 19 x 24cm

Sorbsan Plus Carbon

7.5 x 10cm, 10 x 15cm, 10 x 20cm, 15 x 20cm

Sorbsan Silver

Flat: 5 x 5cm, 10 x 10cm, 10 x 20cm

Packing: 2g/30cm with plastic probe

Ribbon: 1g/40cm with plastic probe

Sorbsan Silver Plus Non-Adhesive

7.5 x 10cm, 10 x 15cm, 10 x 20cm, 15 x 20cm

Sorbsan Silver Plus Self-Adhesive with adhesive border

11.5 x 14cm, 14 x 19cm, 14 x 24cm, 19 x 24cm

main components are:

- ▶▶ T Tissue management
- ▶▶ I Control of infection and inflammation
- ▶▶ M Moisture imbalance
- ▶▶ E Advancement of the epithelial edge of the wound.

Alginate dressings such as Sorbsan would fit into the moisture imbalance component as they absorb exudate in the moderate to high exuding wounds. The range now includes Sorbsan Silver which would also assist with the 'I' component: control of infection and inflammation.

Sorbsan range

Sorbsan wound dressings have been available now for 25 years (Figure 1) and won the Queen's Award for Technological Achievement six years after its launch. Since then the range has grown over the years to address the changes and challenges faced in the management of all types of wounds.

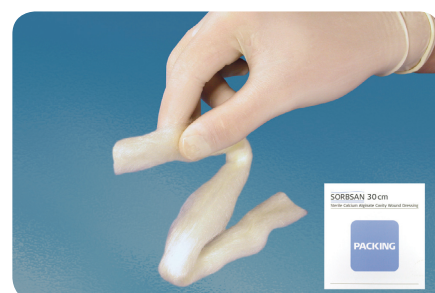
The current product range is listed in Table 1. The dressings are non-adherent and are therefore atraumatic on removal (Williams, 1996). They maintain a moist wound healing environment and manage exudate. Sorbsan also has haemostatic properties as do all alginate dressings (Jones, 1999) which means they can be used to stop bleeding or for wounds where bleeding is a problem or a potential problem, such as fungating wounds. These haemostatic properties were described following the use of alginates during dental, aural and neurosurgical procedures (Thomas, 1992).

Sorbsan Flat, Ribbon and Packing

These are the original Sorbsan dressings and are suitable for flat, shallow cavity or sinus wounds with moderate to high exudate levels (Figure 2). Sorbsan's non-woven structure and high mannuronic acid content aids maximum absorption of exudate (Qin, 2007). One of the main advantages in the clinical environment is the way the dressings form a soft amorphous gel which helps the dressing conform to have maximum contact with the wound bed which is particularly important for cavity wounds. The gelled Sorbsan is easily and painlessly removed by irrigation with saline. The ribbon and packing (Figures 3 and 4) comes with a sterile plastic measuring probe to measure the wound and to assist in the application into a cavity or sinus. The dressing must not be used if the opening to the wound is smaller than the tip of the probe.

Sorbsan Plus

Sorbsan Plus range is even more absorbent and is available in a non-adhesive or self-adhesive version. It has a two-stage absorbing action to help keep exudate away from the peri-wound skin so reducing maceration. The self-adhesive range is shower-proof and the non-adhesive range is effective underneath compression. Collier (1996) undertook a clinical evaluation of Sorbsan Plus dressing. The study involved four patients and the author acknowledged that this was a small number of patients, but highlighted the following benefits:

**Figure 2. Sorbsan Flat****Figure 3. Sorbsan Ribbon****Figure 4. Sorbsan Packing****Figure 5. Sorbsan Silver range**

- ▶▶ That it is used as an all-in-one dressing saving on secondary dressing costs and being simpler to apply
- ▶▶ It is a highly-absorbent alginate and viscose pad which has much greater absorbency
- ▶▶ It provides a moist wound healing environment
- ▶▶ It involves a simple dressing change, which is painless and leaves no residue on the wound bed.

Sorbsan Silver

Sorbsan Silver (Figure 5) was launched in 2007 and has 1.5% silver content. Manufacturer's tests have shown it to be effective against methicillin-resistant *Staphylococcus Aureus* and vancomycin-resistant enterococci. The management or prevention of wound infection is a key element of successful wound management. An antimicrobial wound dressing can be used in patients with an infection, or who are at high-risk of developing infection as part of a structured plan of care. Timmons and Gray (2007) report on nine case reports using Sorbsan Silver and conclude that the results suggested that the clinical outcomes were positive when used appropriately for short periods. Callaghan (2007) reports on the management of a woman with colonised circumferential bilateral venous leg ulcers that were managed with Sorbsan Silver. Callaghan concluded that the dressing tackled the infection, achieving quick and effective control of exudate. It was not noted if improved healing had taken place.

Further evidence of the Sorbsan range's effectiveness

Odugbesan and Barnett (1987) report the use of Sorbsan on a 68-year-old woman with diabetes with venous ulcers on both legs. She had been taking oral therapy for her diabetes for eight years and had good peripheral pulses and no diabetic neuropathy or retinopathy. Although the bandage system that was in use was not mentioned in the report, healing coincided with the use of Sorbsan. It is not reported if this patient was resting more and elevating her limbs more while in hospital as this could have been a factor in the improved healing. The authors conclude that they have used Sorbsan in other venous ulcers and neuropathic and ischaemic ulcers with good success. They conclude that the handling characteristics of Sorbsan were superior to the commonly used wound dressing, but the comparative dressing was not identified.

Thomas and Tucker (1989) report on a community-based trial of Sorbsan compared with paraffin gauze dressing in the treatment of 64 patients with

mixed aetiology leg ulcers. Overall 73% of ulcers treated with Sorbsan healed or reduced in area, but only 43% dressed with paraffin gauze showed any evidence of improvement. Normal leg ulcer management and any bandage systems were continued. The authors acknowledge the difficulties in controlling a study of this size with the large number of medical and nursing staff involved. They also stated that the improvements in wound healing which could result from the use of Sorbsan appear to be achievable without an increase in overall costs of dressings. Patients also reported a reduction in pain and an improved quality of life. Madden (2000) describes the importance of making clinically effective and cost-effective progress in the management of wound dressings. She emphasises that by choosing wisely and taking into consideration the overall treatment costs and not just the unit costs, it is possible to select a modern wound dressing that is not only effective but cost-effective too.

Smith (1992) compared Sorbsan with a polynoxylin powder and low-adherent dressing after toenail removal. A total of 62 patients were involved in the study with 34 patients treated with Sorbsan and 28 with polynoxylin powder and a low-adherent dressing. The results indicated that Sorbsan reduced the median healing time and reduced the patients' complaints of pain when compared with the control treatment. Sorbsan was also found to be easy to apply and remove.

Gupta et al (1991) undertook a study of 29 patients with acute surgical wounds and abscesses. Seventeen were allocated to conventional gauze-soaked proflavine packs and 12 were allocated to the Sorbsan group. The wounds ranged from pilonidal sinus to perineal wounds and a variety of abscesses. The authors concluded that Sorbsan was superior to traditional gauze dressings in terms of patient comfort and bacterial clearance. They also stated that although the unit cost of Sorbsan is more expensive the whole treatment is cost-effective as there is also less analgesia required and patients undoubtedly suffer less.

Key Points

- ▶▶ The original award-winning Sorbsan alginate wound dressing has been in clinical use for 25 years.
- ▶▶ The range of dressings maintain a moist wound healing environment and are designed to handle moderate to high levels of exudate.
- ▶▶ Sorbsan is rich in mannuronic acid which produces a soft amorphous gel.
- ▶▶ Sorbsan is best known for its ease of application and pain-free removal.
- ▶▶ Sorbsan remains an essential wound dressing and a cost-effective option for many wound types.

Miller et al (1993) report the use of Sorbsan packing in the management of deep sinuses. They describe the management of three patients that otherwise would have been managed with gauze soaked in saline or antiseptic. Sorbsan could continue to be nursed in the community. Sorbsan could be left in situ longer than traditional dressings, reducing nursing time, and ensured that the dressing was comfortable and pain free to remove. The authors conclude that the cases described may have been better managed by surgical intervention but all three were physically unsuited to anaesthetic and were unwilling to undergo further surgery.

Chaloner (1991) described the management of a woman with a cavity wound following a mastectomy. It was at a time when cavity wound dressings were not available to community nurses on Drug Tariff. The author achieved rapid pain-free healing of the wound by using Sorbsan enabling the patient to make a full recovery physically,

psychologically and socially. Cavity wound dressings are now available in abundance on Drug Tariff.

Williams (1999) described the use of alginates such as Sorbsan in cavity wounds for the diabetic foot. She outlines that there are three types of cavity in the diabetic foot;

- ▶▶ A straightforward cavity wound with a regular shape
- ▶▶ A cavity that extends or tunnels under the skin edges
- ▶▶ A sinus which is a blind-ended track, usually ending with an abscess.

She also explains how practitioners are normally split between those who favour a firm alginate and those who prefer a soft alginate. The author concludes that for patients with diabetes and a cavity wound, an alginate dressing such as Sorbsan can be an effective and comfortable wound dressing.

Jones (1999) also describes using alginates to manage diabetic foot lesions. Jones states that the major advantage with alginates in the treatment of diabetic foot lesions is their ability to provide a non-adherent packing material for small tortuous sinuses. The author concludes that caution should be observed with wounds that are infected or have only a low level of exudate production as inappropriate dressing management may result in further unwanted complications.

The management of pain is a very important concern in wound care. Thomas (1989) stated that sometimes the pain caused by the application or removal of a wound dressing is frequently accepted by medical and nursing staff as inevitable. Although this attitude has become less acceptable, more recently it has been said that the assessment and management of trauma and pain in relation to wound care is not yet integrated into routine practice (European Wound Management Association, 2002).

Williams (1996) undertook a small study to try and initiate a change in practice and to encourage general surgeons to change from packing surgical cavity wounds with ribbon gauze soaked

in proflavine to using an alginate dressing. Sorbsan was used because it is particularly easy to remove. The author explains that Sorbsan dissolves when irrigated with saline, which makes the dressing change less time-consuming and more cost-effective. The study included 24 patients with a variety of surgical cavity wounds; 10 were treated with ribbon gauze and 14 with calcium alginate. The results demonstrated that patients in the alginate group reported little or no pain and required no analgesia during dressing changes. Patients in the ribbon gauze group reported severe pain during the dressing procedure and immediately afterwards and all reported pain two hours later. Most of the ribbon gauze group required analgesia. Dressing changes took, on average, three times longer in the ribbon gauze group than in the alginate group.

Conclusions

Sorbsan remains a high quality and cost-effective wound care product — 25 years after its launch. It also costs less today than it did when it was launched in 1983. The range has been extended to meet the changing needs of modern wound care and has, along with other alginate dressings, become synonymous with pain-free wound dressing changes. This is an aspect of wound management that is currently high on the wound management agenda and a focus of much research and debate. **WUK**

References

- Benbow M (2008) Exploring the concept of moist wound healing and its application in practice. *Br J Nursing* 17(15): S4–S16
- Blaine G (1947) Experimental observations on absorbable alginate products in surgery. *Annals Surgery* 125: 102–14.
- Callaghan R (2007) A case study of a nursing home resident with infected venous ulcers. Poster presentation at Wounds UK, Harrogate
- Chaloner D (1991) Treating a cavity wound. *Nurs Times* 87(13): 67–9
- Collier M (1996) A Clinical Evaluation of Sorbsan Plus Dressing. Poster presentation at EWMA conference, Amsterdam
- Dowsett C, Newton H (2005) Wound bed preparation: TIME in practice. *Wounds UK* 1(30): 58–70
- European Wound Management Association (EWMA) (2002) *Position Document: Pain at Wound Dressing Changes*. MEP Ltd, London www.ewma.org
- Gupta R, Foster ME, Miller E (1991) Calcium alginate in the management of acute surgical wounds and abscesses. *J Tissue Viability* 1(4): 115–6
- Heenan A (1998) Alginate dressings. *World Wide Wounds* <http://www.worldwidewounds.com/1998/june/Alginates-FAQ/alginates-questions.html>
- Jones V (1999) Alginate dressings and diabetic foot lesions. *Diabetic Foot* 2(1): 8–14
- Madden V (2000) Maersk Medical: cost-effective wound care. *Br J Health Care Manage* 6(8): 2–4
- Miller L, Jones V, Bale S (1993) The use of alginate packing in the management of deep sinuses. *J Wound Care* 2(5): 262–3
- Odugbesan O, Barnett AH (1987) Use of a Seaweed-based dressing in management of leg ulcers in diabetics: a case report. *Pract Diabetes* 4(1): 46–7
- Qin Y (2007) The gel swelling properties of alginate fibers and their applications in wound management. *Polymer Adv Technol* 19(1): 6–14
- Queen D, Orsted H, Sanada H, Sussman G (2004) A dressing history. *Int Wound J* 1(1): 59–77
- Schultz G, Sibbald G, Falanga V et al (2003) Wound bed preparation: a systematic approach to wound management. *Wound Rep Regen* 11: 1–28
- Smith J (1992) Comparing Sorbsan and polynoxylin/Melolin dressings after toenail removal. *J Wound Care* 1(3): 17–9
- Thomas S (1989) Pain in Wound Management. *Comm Outlook July*: 11–5
- Thomas S (1992) Alginates. *J Wound Care* 1(1): 29–32
- Thomas S, Loveless P (1992) Observations on the fluid handling properties of alginate dressings. *Pharm J* 248: 850–1
- Thomas S, Tucker CA (1989) Sorbsan in the Management of Leg Ulcers. *Pharm J* 243: 706–9
- Timmons J, Gray D (2007) Sorbsan Silver Case Study Booklet: Clinical audit. Unomedical, Redditch:1
- Williams C (1994) Sorbsan. *Br J Nursing* 3(13): 677–80
- Williams C (1996) Painful Dressings. *J Tissue Viability* 6(3): 69–70
- Williams C (1998) Using alginate dressings: a cost-effective option. *Nurse Prescriber/Comm Nurse February*: 43–4
- Williams C (1999) Alginate cavity dressings for the diabetic foot. *Diabetic Foot* 2(4): 139–40