

Aquaform[®] hydrogel — a new formulation for an improved wound care performance

Hydrogels have played a significant role in wound care for over 20 years. They have been used safely on a variety of wound types and have successfully treated patients with skin damage related to incontinence. Primarily, hydrogels are used to assist in the debridement of necrotic tissue and with its unique formulation, Aquaform[®] hydrogel has been excellent at providing moisture to wounds. However, the new formulation of Aquaform hydrogel has a number of advantages over its predecessor and has the potential to greatly improve patient care.

John Timmons, Melvyn Bertram, Gail Pirie and Kristine Duguid

KEY WORDS

Hydrogels
Incontinence-associated skin damage
Debridement

Hydrogel is a blanket term for materials that are able to absorb water and swell in aqueous conditions without dissolving. Most are manufactured from a polymer backbone that provides structure — this is repeated throughout the gel and hydrogen bonds act to retain water within that structure (Thomas, 1998). Hydrogels of this type occur naturally, for example, in the cornea of the eye or in cartilage. Synthetic hydrogels are normally produced from polyacrylamide or polyethylene oxide.

The type of bonding that occurs within the gel will have an impact on how it performs clinically, with increased cross-linking leading to a more viscous gel. As the cross-linking increases, a sheet of gel will eventually be produced.

John Timmons is Editor of Wounds UK and Clinical Nurse Specialist, Department of Tissue Viability, Aberdeen Royal Infirmary; Melvyn Bertram, Gail Pirie and Kristine Duguid are all Tissue Viability Nurses, Department of Tissue Viability, Aberdeen Royal Infirmary

Hydrogels have excellent biocompatibility and are used in many medical devices, including electrocardiograph (ECG) contact pads, adhesives, contact lenses and drug delivery devices. As wound dressings, hydrogels are available as amorphous gels, sheet hydrogels and gel-impregnated gauze (Thomas, 1998).

Hydrogels and wound care

Shultz et al (2003) suggested that hydrogels are the best choice for the treatment of dry wounds with necrotic eschar *in situ*. Trudgian (2000) and Mulder (1995) found hydrogels reached a 50% debridement level more quickly than wet-to-dry dressings as well as being more cost-effective. Most hydrogels have the ability to provide moisture to a dry environment and some can absorb limited amounts of exudate from a wound — this can cause the gel to expand and fill a wound (Thomas, 1998).

Wound debridement

Debridement is considered an essential step in the management of chronic wounds as a failure to remove necrotic tissue can inhibit healing by providing an environment for bacterial growth and chronic inflammation as well as impeding re-epithelialisation (Schultz et al, 2003). A number of techniques can be used for debridement:

- ▶▶ Surgical/conservative sharp debridement

- ▶▶ Larval debridement
- ▶▶ Enzymatic debridement
- ▶▶ Autolytic debridement.

Surgical debridement is often viewed as the 'gold standard' method of debridement in terms of speed and efficiency, however, not all patients are able to tolerate this or indeed have access to a specialist who can perform the procedure (Timmons, 2003).

Larval therapy is also viewed as a quick and efficient method of debridement, however, it is not suitable for all wound types and may not be acceptable to every patient.

In the case of enzymatic debridement, preparations of proteolytic enzymes such as collagenase or varidase (a mixture of streptokinase and streptodornase) are applied topically to digest eschar — these can also be cross-hatched to aid penetration of the eschar.

Autolytic debridement is one of the most commonly used methods of debridement in the UK. It utilises proteolytic enzymes produced by cells in the wound tissue, such as macrophages. Its advantage is that the physiological mechanisms involved also allow the macrophages to phagocytose digested debris and remove it from the wound environment. However, autolytic debridement will not succeed if the eschar is dry. Rehydration with moisture-donating dressings

Table 1
The differences between old and new Aquaform hydrogel components

Old Aquaform	New Aquaform
Water	Purified water
Glycerol	Glycerol (glycerin)
Modified starch copolymer	Modified starch copolymer
Preservative — propylene glycol	Preservative — methylparaben (food grade)
	Preservative — Imidazolidinyl urea

such as hydrogels induces and accelerates autolysis.

Enzymatic debriding ointments are expensive and autolytic debridement with a hydrogel dressing has been shown to be as efficacious and more cost-effective (Martin et al, 1996). While the use of enzymes is common in other parts of Europe, they are not widely used in the UK.

Hydrogels are also effective in the debridement of diabetic foot ulcers. Indeed a meta-analysis of data pooled from three studies suggests that hydrogels increase the healing rate of diabetic foot ulcers and are significantly more effective than gauze or standard care (Smith, 2002). Sheet hydrogels have also been shown to be efficacious in the debridement of slough and necrotic tissue when combined with low trauma dressing changes (Armitage and Roberts, 2004).

Treatment of incontinence-related dermatitis

Although this is not yet viewed as a clinical indication for the use of hydrogels, some evidence exists which supports the use of hydrogels in treating skin damage as a result of faecal and or urinary incontinence (Pudner, 2001). Faeces and urine contain enzymes and chemicals that destroy the acid mantle and 'burn' the skin. Such damage often occurs over a large surface area that is not suited to traditional dressings. By using a hydrogel and good quality incontinence pads over

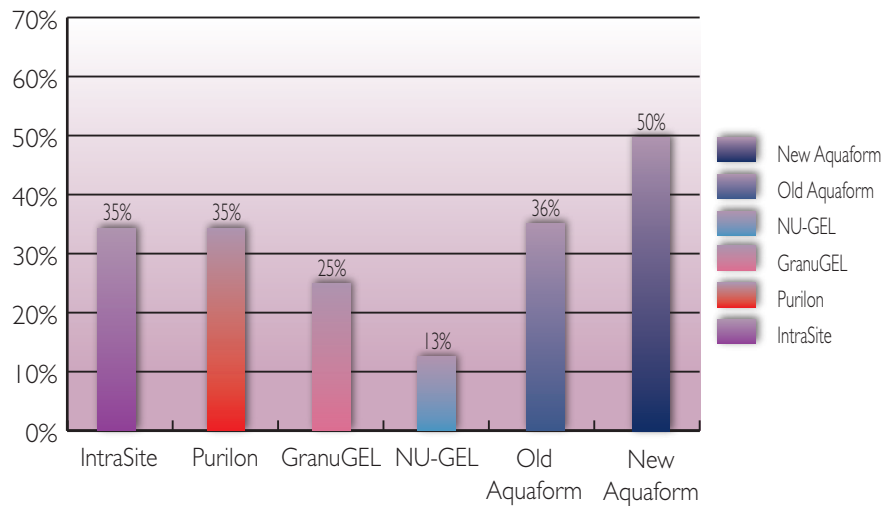


Figure 1. The results of *in vitro* moisture-donation testing show new Aquaform donated a greater amount of moisture than some of the other leading hydrogel brands.

the area, the gel can be reapplied 3–4 times per day with excellent results (see case study).

Hydrogel dressings have also been used in the treatment of neonatal extravasation injuries (Young, 1995), as well as other conditions such as nappy rash, radiotherapy-damaged skin and dermatological skin conditions (Williams, 1995).

New Aquaform® hydrogel

The new improved Aquaform hydrogel is still indicated for the same clinical use — flat or cavity wounds where there is no exudate or low exudate levels — and comes in the same 8g and 15g tubes. The nozzle has been improved for easier use and more precise application. There is also a new tamper-proof mechanism on the nozzle of the 8g tube and the 15g tube comes individually wrapped.

The gel itself has been reformulated to improve performance (Table 1). The new formulation Aquaform hydrogel is clear not cloudy which allows the clinician to be able to more easily monitor the wound bed and, as can be seen in Table 1, does not contain propylene glycol, which has been shown to be toxic to larvae meaning that it can now be used in conjunction with larval therapy.

The new Aquaform hydrogel also contains more water, which allows

a greater provision of moisture to the wound. However, Table 2 also shows that the gel is now more viscous, which makes it easier to apply and minimises gel run-off from the wound bed (data on file). The starch content is the same and this will allow for some absorption of water by the product. There is also a higher glycerol content, which helps with skin moistening and conditioning.

In vitro testing has demonstrated the improved performance of Aquaform hydrogel over the old Aquaform product. Figure 1 shows the results of *in vitro* moisture-donation testing and as the graph demonstrates, the gel provided a greater amount of moisture than some of the other leading hydrogel brands.

Separate *in vitro* testing for gel stability monitored the length of time that Aquaform remains on the site

Table 2
The increase in viscosity of the new formulation of Aquaform hydrogel

Gel name	Viscosity (centipoise)
New Aquaform	554,000
Old Aquaform	260,000
Purilon	600,000
GranuGEL	597,000
NU-GEL	600,000
IntraSite	524,000

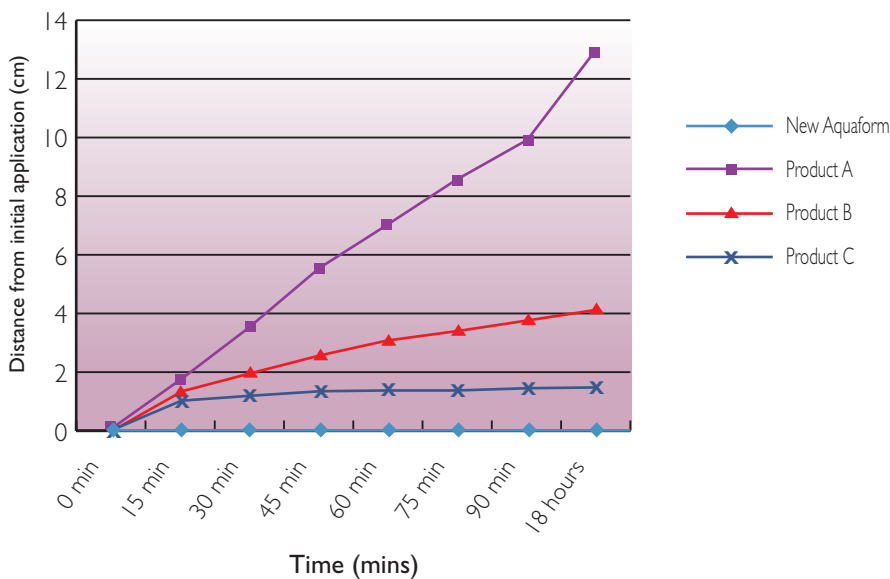


Figure 2. *In vitro* testing for gel stability monitored the time which Aquaform remains in the site of application.

of application (Figure 2). This can be important when treating leg wounds as gravity can affect a gel's ability to remain at the site of application, or in treating areas of skin damage where the gel is required to act on a small area. New formulation Aquaform hydrogel remained in place for the duration of the study and performed better than three other hydrogels.

Case study

The patient was a 64-year-old woman who had a past medical history of renal cancer, hypertension and colposuspension of the bladder neck. She also smoked 20 cigarettes a day up until her admission for a right partial laparoscopic nephrectomy.

The patient developed pneumonia post-operatively and was subsequently admitted to

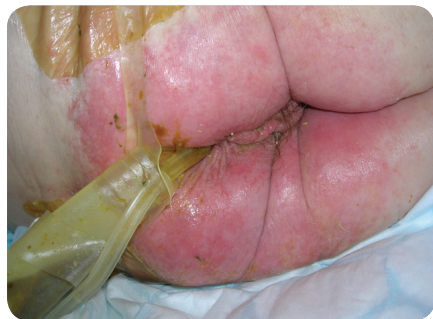

Figure 3. A faecal management system was inserted in an attempt to deal with the patient's faecal incontinence.

intensive care for the insertion of an emergency tracheotomy. Due to the administration of intravenous antibiotics the patient became infected with *Clostridium difficile*, which was resistant to vancomycin — she was subsequently commenced on metronidazole.

For 10 days, she experienced severe bouts of faecal incontinence and during this time a urinary catheter and a faecal management system were inserted (Figure 3). However, faecal matter continually bypassed the faecal management system and as a result the patient developed incontinence dermatitis.

First review

At her first review, she exhibited moderate excoriation of the peri-anal area and multiple small superficial breaks around the anal and vulval regions. The wounds were red/pink in colour with no sign of infection and low volume/viscosity exudates. They were also very painful.

Ongoing management

The patient still had an in-dwelling urinary catheter and a faecal management system in place. Aquaform hydrogel was applied to all of her wounds and the surrounding skin four times a day. After each episode

of incontinence, the area was also cleansed with a foam cleanser and the hydrogel reapplied.

Second review

Seven days later, all of the patient's wounds were completely healed and the skin remained red and irritated but intact. There was no evidence of infection and no exudate. The patient stated that the pain had completely subsided.

Although she still continued to have reduced episodes of faecal incontinence the faecal management system and urinary catheter were removed due to continued bypassing (Figure 4).

The patient was washed with a foam cleanser twice daily and again after any episodes of incontinence. A 50/50 emollient was also applied.

At the initiation of Aquaform hydrogel therapy she experienced reduced pain and by the seventh day of treatment the therapy had also helped to reduce inflammation and help to prevent cutaneous infection. Aquaform hydrogel therapy also achieved complete healing of all her wounds and promoted rehydration of the surrounding skin.

Conclusion

Optimal wound healing requires a moist environment and the accumulation of dry necrotic tissue impedes this process. Because of their ability to provide moisture, hydrogel-based dressings have been recommended as the best choice

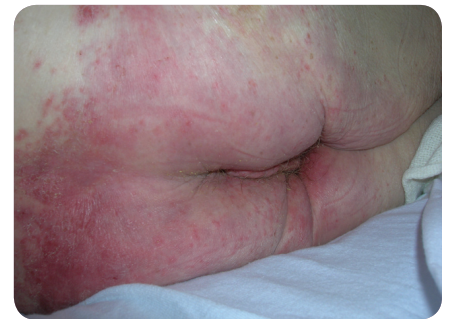

Figure 4. Eventually, the patient's wounds were healed and the skin remained red and irritated but intact.

for management of dry sloughy wounds. The product has also been used to excoriated skin as a result of incontinence. They also generate a cooling effect, providing pain relief when freshly applied to the wound.

New improved formulation Aquaform hydrogel has the potential to improve patient care by providing large amounts of water to otherwise dry wounds, thus assisting in debridement. It also remains in place on the wound for long periods of time. Also, the new Aquaform hydrogel gel does not contain propylene glycol, which means that it can be used in conjunction with larval therapy when treating hard eschar. **WUK**

References

- Armitage M, Roberts J (2004) Caring for patients with leg ulcers and an underlying vasculitic condition. *Br J Community Nurs* 9(12): 16–22
- Mulder GD (1995) Cost-effective managed care: gel versus wet-to-dry for debridement. *Ostomy Wound Manage* 41: 68–74

Martin SJ, Corrado OJ, Kay EA (1996) Enzymatic debridement for necrotic wounds. *J Wound Care* 5: 310–11

Pudner R (2001) Amorphous hydrogel dressings in wound management. *J Community Nurs* 15(6): 43–6

Schultz GS, Sibbald RG, Falanga V, et al (2003) Wound bed preparation: a systematic approach to wound management. *Wound Repair Regen* 11(Suppl 1): S1–S28

Smith J (2002) Debridement of diabetic foot ulcers. *Cochrane Database of Systematic Reviews* 4: CD003556

Thomas DR, Goode PS, LaMaster K, et al (1998) Acemannan hydrogel dressing versus saline dressing for pressure ulcers. A randomized, controlled trial. *Adv Wound Care* 11: 273–6

Timmons JP (2003) Methods of wound debridement. *J Nurs Res Care Homes* 5(11): 513–16

Trudgian J (2000) Investigating the use of Aquaform hydrogel in wound management. *Br J Nurs* 9: 943–8

Young T (1995) Wound healing in neonates. *J Wound Care* 4(6): 285–8

Williams C (1995) *Intrasite Gel: the extended role. Poster presentation. Proceedings of the 5th European Conference on Advances in Wound Management, 21–24 November, Harrogate.* Macmillan Magazines, London

Key Points

- ▶ Hydrogels are useful products for debridement and may be used to treat excoriation caused by incontinence.
- ▶ Hydrogels are relatively inert and are a safe product to use on a variety of wound types.
- ▶ New formulation Aquaform gel is designed to donate and absorb fluid when necessary.
- ▶ Aquaform now has an increase in water content but with increased viscosity which results in improved retention on the wound on application.

Leg Club update

Second Leg Club opens in Powys

January 2008 was an exciting month in Powys as we opened our doors to the second Leg Club in the county.

Our first Leg Club opened in September 2006 in Llandrindod Wells under the direction of Jessie Bergstrom and the Llandrindod Wells district nurses. This time it's the turn of Jane Banwell and her team of district nurses based with the Llanfyllin group practice.

We still only have a skeleton committee but are generating interest locally. At our first meeting we had six new members but after the local newspaper announced the launch of the Club our numbers swelled to 20 just one week later. Now four months on we have nearly 50 members.

Local infrastructure makes transport an issue here in rural mid-Wales and unfortunately we are not yet in the position of being able to help out with local transport so we feel that some people who would benefit from the Leg Club are not able to attend. Buses here are very few and far between and many people rely upon the post bus to get around. We are thinking of holding a second meeting in another village but in the meantime the members are helping each other out.

As the Tissue Viability Nurse covering North Powys I am very pleased to be involved with this initiative. I have given a commitment to support the Club as often as my limited time allows. I hope to be able to use the Leg Club as a centre of excellence where we will be able to work towards local competencies in bandaging and

undertaking ankle brachial pressure recording.

Industry is helping and we thank them for their support in this project. We are hoping to develop the social side of the Club as we grow. Currently we have booked armchair exercises on the last Thursday of the month and we have several companies booked to display stands about compression hosiery and the importance of nutrition. Where possible we are linking these to study sessions after the Leg Club and opening them to neighbouring district nursing teams as well.

I now look forward to the Thursday Leg Club as it always brings both new challenges and new members.

Jackie Griffin, Tissue Viability Clinical Nurse Specialist, North Powys Local Health Board