

Managing chronic wounds with Acticoat Moisture Control™

Nanocrystalline silver dressings are increasingly popular for managing the increased bacterial burden in different types of wounds. Evidence for their use is limited, but does suggest favourable results. This article looks at the effect of Acticoat Moisture Control™ in the treatment of various chronic wound types. Twelve patients with a history of recurring infection were assessed using standardised criteria. Marked improvements were seen in 10 of the patients. Four of these case studies are presented, highlighting the effectiveness of the nanocrystalline silver dressing at preventing recurrence of persistent infection.

Sarah Bradbury, Anna Turner, Nicola Ivins, Keith Harding

KEY WORDS

Infection
Chronic wounds
Nanocrystalline silver
Acticoat Moisture Control™

Chronic wounds are recognised to have a large impact on healthcare provision and resources, as well as adverse effects for people who have them. A large proportion of the direct costs associated with chronic wound management are attributed to treatment with various types of dressing materials (Harding et al, 2002).

Chronic wounds fail to progress through the main phases associated with normal wound healing. One of the main suggestions for this is they become trapped in a chronic inflammatory state (Ennis and Meneses, 2000). Dysfunction at a cellular level has been associated with this, including problems

Sarah Bradbury and Anna Turner are Research Nurses; Nicola Ivins is Clinical Trials Facilitator and Keith Harding is Professor of Rehabilitation Medicine (Wound Healing), all at the Department of Wound Healing, Cardiff University

in the modulation of matrix metalloproteinases (MMPs) and the availability of growth factors (Trengrove et al, 1999; Krishnamoorthy et al, 2001).

A variety of factors can also impede wound healing and lead to the development of chronic wounds, such as systemic diseases like diabetes mellitus and rheumatoid arthritis or the presence of ischaemia and infection (Harding et al, 2002). Leaper (2006) suggests that infection is probably the main cause of delayed healing in chronic skin ulcers. While all chronic wounds by their very nature will be colonised with bacteria, it is the maintenance of a balance between host resistance and the quantity and virulence of bacteria that will reduce the development of clinical infection and facilitate healing (Warriner and Burrell, 2005).

The role of silver

The development and use of various silver dressings has been one way in which prevention and management of infection has recently been addressed. Silver is widely recognised to be effective against many different organisms, including those that have developed antibiotic resistance (Wright et al, 1998; Lansdown, 2002). It exerts its effect on multiple areas of bacterial metabolism, which decreases the likelihood of bacteria developing resistance as multiple mutations

would be required to overcome the antimicrobial effect (Vermeulen et al, 2005; Warriner and Burrell, 2005). There is, however, some work that suggests that the likelihood of these mutations occurring is increased if the concentration of silver initially applied is below the minimum inhibitory concentration (MIC) required to inhibit growth through the most sensitive mechanism of action. Both Li et al (1997) and Warriner and Burrell (2005) found that, during in-vitro testing of silver against *Escherichia Coli* and *Pseudomonas Aeruginosa*, if the concentration of silver applied is lower than the MIC initially, the MIC for these bacteria increased at subsequent applications despite increases in silver concentration. They suggest that at low concentrations of silver the bacteria are able to develop resistance, as fewer simultaneous mutations are required to overcome the antimicrobial action of the silver.

This has only been demonstrated in an in-vitro setting, but does suggest that development of resistance is possible and should be guarded against. Dressings used in clinical practice should contain a sufficient amount of silver to be bactericidal as widespread and repeated use could otherwise encourage the development of silver resistance. Some research suggests that 20–40 parts per million (ppm) is the amount required to kill bacteria (Dowsett, 2003; Warriner and Burrell,

2005), although Yin et al (1999) found levels of 5–50 ppm is toxic to most bacteria.

This could suggest that dressings used in practice should contain a sufficient amount of silver to be bactericidal, as widespread and repeated use could otherwise encourage the development of silver resistance.

Dowsett (2004) suggests that another way to discourage resistance is to only use silver dressings for short periods of time. Leaper (2006) states that antibacterial dressings should not be used on non-infected wounds, wounds without signs of heavy bacterial burden or where non-healing is not considered to be due to the presence of micro-organisms, especially when considering that some in vitro studies have found silver to be toxic at a cellular level (Lam, 2004; Poon and Burd, 2004; Cochrane et al, 2006). These issues highlight the importance for clinicians to continually assess the clinical need for silver dressings if complications from its use are to be avoided.

Nanocrystalline silver

Nanocrystalline silver is one form of silver that has been used in modern dressings and consists of small water-soluble crystals that rapidly release and replenish effective concentrations of silver ions into the wound environment. The small size of the crystals also ensures a large surface area is available for antimicrobial activity (Dowsett, 2003). Nanocrystalline silver dressings deliver a sustained release of ions at a concentration of 70–100 ppm (Wright et al, 1998), well above the 5–50 ppm that research indicates is required to kill bacteria (Warriner and Burrell, 1995; Yin et al, 1999; Dowsett, 2003). This should ensure that they are an effective antimicrobial and also release silver above the suggested level at which bacterial resistance may be induced.

This form of silver has also been shown to have effective anti-

inflammatory properties as a result of its antibacterial activity. In vivo and clinical research indicates that nanocrystalline silver modulates the expression of tumour necrosis factor (TNF- α) induces apoptosis and inhibits MMP concentrations, thus improving wound healing (Paddock et al, 2002; Wright et al, 2002). Abnormalities in these processes are known to exacerbate the inflammatory cycle considered to be a cause of non-healing in chronic wounds, indicating a use for nanocrystalline silver not only for reducing bacterial burden but also for the control of inflammation and promotion of healing in wounds of this type.

Several studies using animal models have indicated favourable results for the use of nanocrystalline silver in reducing bacterial load. Burrell et al (1999) compared the efficacy of nanocrystalline silver dressings, silver nitrate and various controls against burn wounds infected with *P. aeruginosa* using a standardised, validated rat burn model. Results indicated a significant decrease in mortality rate for the rats receiving the silver dressing compared with the other groups, indicating the benefits of a rapid onset of bactericidal action from nanocrystalline silver. Wright et al (2002) used a porcine model to observe healing rates with wounds treated with nanocrystalline silver dressings being compared with a control group, who received an identical dressing but without the nanocrystalline silver. They also found that a more rapid healing response was seen in the wounds treated with nanocrystalline silver.

In vitro studies have also yielded promising findings for the antimicrobial activity of nanocrystalline silver. Yin et al (1999) compared the antimicrobial activity of the nanocrystalline silver dressing Acticoat (Smith and Nephew, Hull), silver nitrate, silver sulphadiazine and a control against five different bacteria. They found that viable bacteria were undetectable after 30 minutes post-inoculation with Acticoat, compared with 2–4 hours for the

silver nitrate and silver sulphadiazine. Acticoat also had a lower MIC and minimum bactericidal concentration (MBC) than the other two silver products. As MIC gives an indication of the susceptibility of the organisms to silver and MBC assesses killing activity (Warriner and Burrell, 2005), these results suggest that the nanocrystalline silver dressing was the most effective antimicrobial. In their 2003 study Thomas and McCubbin found that Acticoat had a more effective and sustained antimicrobial activity and rapid onset of action when they compared the antimicrobial efficacy of four different silver dressings on *Staphylococcus aureus*, *E. coli* and *Candida albicans*.

In addition studies comparing the efficacy of various silver dressings against methicillin-resistant *S. aureus* and other antibiotic-resistant organisms have found that nanocrystalline silver dressings had a more effective bactericidal and antimicrobial barrier action than other silver releasing dressings (Wright et al, 1998; Edwards-Jones, 2006).

It must be acknowledged that these studies have been performed either on animals or under controlled laboratory conditions, so the results cannot be applied with certainty to humans, especially when considering the dynamic and individual state of most wounds. Systematic reviews including the use of silver in wound care have indicated a lack of evidence on its effectiveness, mainly due to the paucity of rigorous randomised clinical trials (O'Meara et al, 2001; Bergin and Wraight, 2006). A small number of clinical studies using Acticoat on burn wounds have indicated positive results (Tredget et al, 1998; Yin et al, 1999; Demling and DeSanti, 2002), but more research is required with human subjects, using larger samples and other types of chronic wounds before more rigorous conclusions can be drawn and results applied to a wider population of patients. Leaper (2006) also suggests that using consistent methodologies may be less confusing and would aid the interpretation of

the efficacy of certain dressings when compared with others.

Acticoat Moisture Control™

In addition to reducing bacterial load, the development of modern wound dressings has also focused on the provision of an optimum wound healing environment, through promotion of moist wound healing, exudate management and wound bed preparation (Falanga, 2000; Schultz et al, 2004). Addressing these factors may help to better manage the variety of chronic wounds seen today and assist in progression towards healing.

Acticoat Moisture Control™ (Smith and Nephew, Hull) is a new dressing which combines a nanocrystalline silver wound contact layer backed with polyurethane foam and a waterproof film layer. The combination of these layers allows the dressing to provide an effective bacterial barrier while maintaining a moist wound environment, thereby contributing to effective wound bed preparation.

Case studies were used in a clinical setting to assess the effect of Acticoat Moisture Control on chronic wound healing. Twelve patients who presented with a history of recurring wound infection and previous multiple courses of systemic antibiotics were assessed using standardised assessment criteria. Photographs and area measurements were performed to monitor changes in wound size. The presence of clinical signs of infection, such as erythema, inflammation, increased pain and malodour, and levels of exudate were also observed. Patients were followed up for variable periods of time depending on their ability to tolerate the dressing or until clinically indicated.

During the course of treatment one patient achieved complete healing, five patients achieved between 30–94% reduction in wound surface area and three showed evidence of epithelialisation. One ulcer increased in size by 10% although the wound

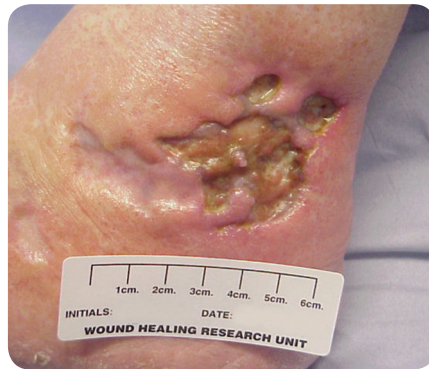

Figure 1. Case study 1: initial presentation of the lower lateral malleolus.

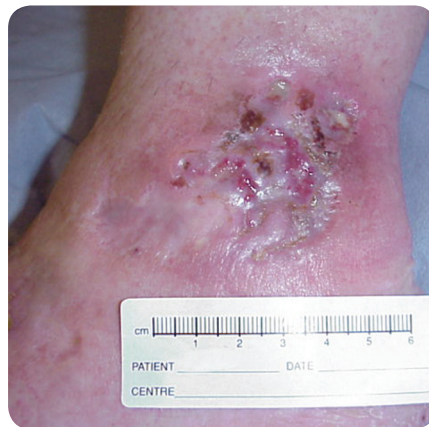

Figure 3. Case study 1: the lower lateral malleolus after five weeks of treatment with Acticoat Moisture Control.

bed was healthy and granulating. Although two were unable to tolerate the dressing due to discomfort on application, this was not a particular concern as this had previously been documented in other published literature with patients using silver-containing dressings (Sibbald et al, 2001; Dowsett, 2003; Lansdown, 2004). This report discusses four of the cases where Acticoat Moisture Control was used to successfully manage four different types of chronic wound.

**Case study 1
Clinical scenario**

The patient was a 64-year old retired woman who lived with her husband and had a past medical history that included breast cancer for which she had surgery and subsequent radiotherapy. She also had a laminectomy and suffered from hypertension which was being treated with felodipine and

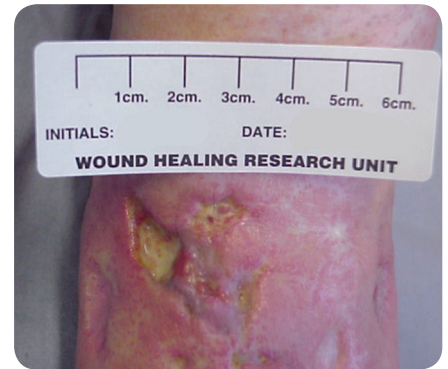

Figure 2. Case study 1: initial presentation of the upper lateral malleolus.

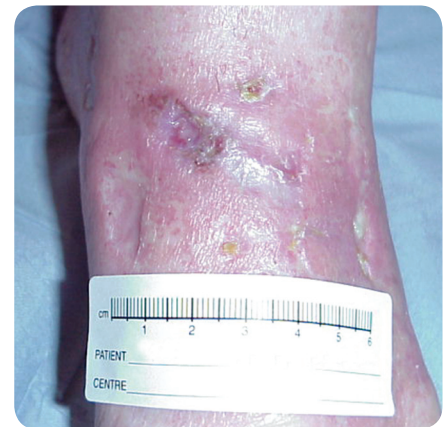

Figure 4. Case study 1: the upper lateral malleolus after five weeks of treatment with Acticoat Moisture Control.

bendroflumethazide. Other prescribed medication included co-codamol, tramadol and amitriptylline as analgesia for ulcer-related pain.

The patient had a long history of cutaneous vasculitis which led to previous ulcerations to both feet. She previously received a variety of treatments, including Dermovate NN (GlaxoSmithKline, London), topical glyceryl trinitrate (GTN) and oral steroids, and had multiple courses of systemic antibiotics for recurrent wound infections and cellulitis.

Clinical presentation

Initial assessment showed there were multiple areas of ulceration on the dorsum and lateral aspect of the foot and two further areas on the upper and lower lateral malleolus (Figures 1 and 2). The ulcers measured 0.2–0.3cm in depth and were mainly sloughy with small areas of granulation tissue and

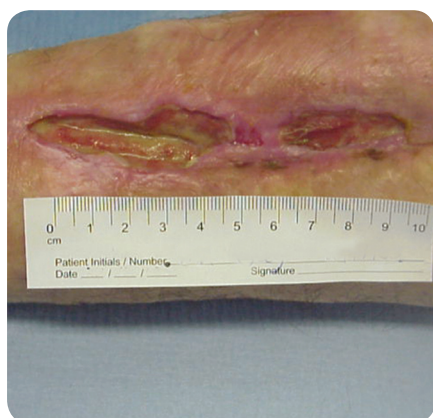

Figure 5. Case study 2: initial presentation of the patient's left leg.

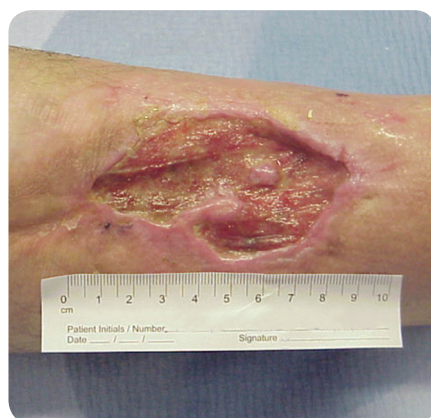

Figure 6. Case study 2: initial presentation of the patient's right leg.

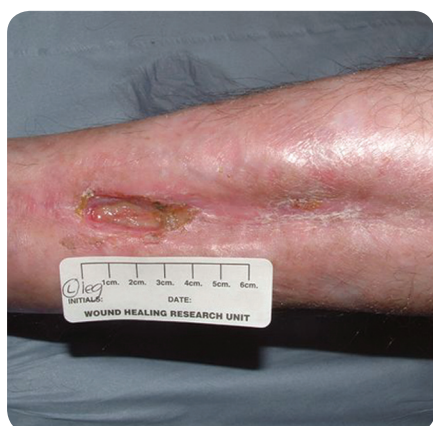

Figure 7. Case study 2: the patient's left leg after 12 weeks of treatment with Acticoat Moisture Control.

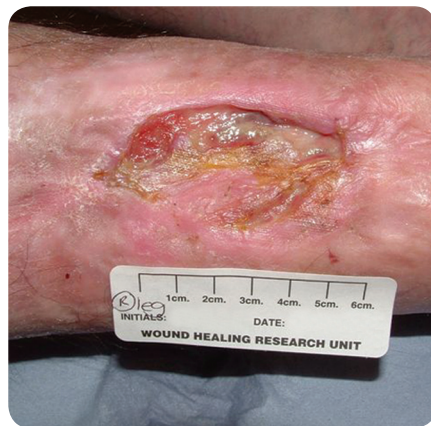

Figure 8. Case study 2: the patient's right leg after 12 weeks of treatment with Acticoat Moisture Control.

static wound edges. Evidence of clinical infection was also seen with visible erythema, inflammation and malodour. The surrounding skin was dry and flaky with extensive atrophie blanche.

A 6mm punch biopsy had been performed three months before which ruled out a primary vasculitis as the aetiology and diagnosed venous stasis. The ankle brachial pressure index (ABPI) measurement was 0.73 suggesting possible arterial involvement so a duplex scan had also been performed. Blood tests eliminated the possibility of a connective tissue disorder.

The patient was experiencing severe pain from the ulcers, possibly due to nerve damage secondary to the vasculitic process. She was getting some relief from oral analgesia, but was unable to tolerate any form of compression.

Treatment description

To treat the infection topically and promote a moist wound healing environment, the patient was treated with Acticoat Moisture Control dressings and no further systemic antibiotics were prescribed. Gauze and retention bandages were used to secure the dressing.

Reassessment was performed weekly by research nurses and the patient performed daily dressing changes herself at home.

Outcome

After one week, the ulcers to the malleolus were shallower compared with the baseline measurement, with less erythema and inflammation to the surrounding skin. Five weeks after commencing the treatment, the areas to the foot had completely healed. The ulcers to the malleolus had reduced to

very small areas of granulation tissue (Figures 3 and 4).

After eight weeks of treatment with Acticoat Moisture Control, complete healing had occurred to all areas. The patient was experiencing significantly less pain, which contributed to improvements in the patient's mobility and general well-being.

The use of Acticoat Moisture Control was very successful in the management of this patient's chronic ulceration, achieving its goals of exudate control, management of infection and promotion of wound healing, with the eventual outcome of complete wound closure.

Case study 2

Clinical scenario

The patient was a 52-year old man who had a four-year history of bilateral leg ulceration. He had experienced burn injuries to both lower legs during a gas explosion while at work. Skin grafts applied to both sites post-injury were unsuccessful and complete healing had never been achieved. He had suffered with recurrent infections, with MRSA previously being isolated from the left leg. Various dressings and four-layer bandaging had previously been applied without success.

The patient previously had a deep vein thrombosis to the right leg following a fracture. He had no other significant medical history and was not taking any prescription medication. The patient was a heavy smoker.

Clinical presentation

On initial assessment, the patient was found to have two ulcers to the left calf measuring 3.5 × 1.1cm and 6.5 × 2.1cm, with depths of 0.5cm, and one ulcer to the right calf measuring 8.2 × 4.7cm with a depth of 0.4cm (Figures 5 and 6). All the ulcers were sloughy with minimal granulation tissue. Exudate was heavy and malodorous with clinical signs of infection and the surrounding skin was erythematous and dry with extensive scarring. The patient was experiencing intermittent

pain from the ulcers which was being controlled with analgesia.

A Doppler ultrasound assessment was performed at this time, indicating an ABPI of 1.07 for the right leg and 0.79 for the left leg. The accuracy of this result was questioned due to the presence of oedema and muffled sounds from the Doppler. Due to the history of thrombosis and the clinical appearance of both ulcers and legs, it was decided that compression therapy would be suitable for this patient in order to increase venous return and minimise oedema.

Treatment description

Acticoat Moisture Control was applied to the bilateral ulcers with the goal of decreasing the bacterial burden and managing the production of heavy exudate, while promoting a moist wound healing environment. It was used in conjunction with a four-layer compression system with emollients applied to the surrounding skin.

Regular assessments were performed by research nurses to monitor progress, with weekly dressing changes being performed by a practice nurse.

Outcome

Following one week of treatment with Acticoat Moisture Control the wounds were no longer malodorous and exudate levels had decreased. The wound edge was epithelialising, there was healthy granulation tissue evident in the wound bed and the depth of the ulcer on the right leg had reduced to 0.3cm.

By week four, the wounds continued to improve and had decreased in size. The wound beds were less sloughy and despite the presence of heavy exudate, the surrounding skin was intact and the patient was able to continue with weekly dressing changes.

At week 12 the wounds had significantly improved (*Figures 7 and 8*). The right ulcer measured 4.3cm x 1.6cm with a depth of

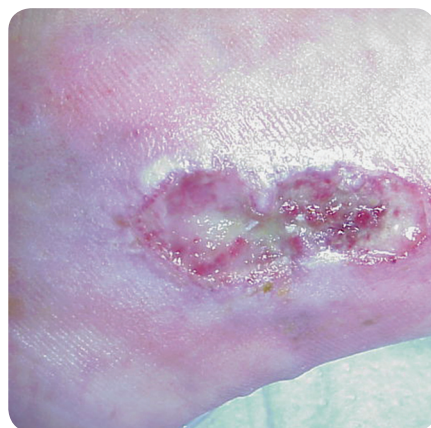


Figure 9. Case study 3: initial presentation of the right medial malleolus.

0.1cm and exudate levels were now minimal. Acticoat Moisture Control was therefore discontinued and the ulcer was redressed with Acticoat to maintain a barrier for bacterial penetration and prevent recurrence of localised infection. There was slight eczema to the surrounding skin which was treated with a steroid ointment. The top ulcer on the left leg had completely epithelialised, and the bottom wound measured 2.4cm x 1.3cm. The depth had reduced to 0.3cm. The wound bed remained sloughy but the wound edge was epithelialising and exudate was reduced.

The decision was made to continue with the Acticoat Moisture Control for the other wound on the left leg. The patient currently remains on this treatment and continues to progress towards healing.

Case study 3

Clinical scenario

The patient was a 71-year-old woman who lived on a farm with her family. She had a 13-year history of chronic venous leg ulceration to her right gaiter and medial malleolus regions. She previously achieved complete healing, but the current ulceration had been present for four years. Her main complications had been recurrent infections and episodes of osteomyelitis which were confirmed by a bone scan. She had been treated with a variety of different

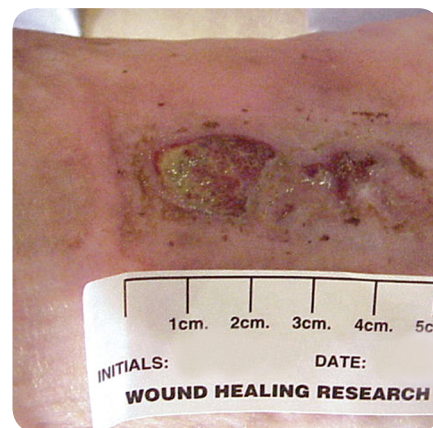

Figure 10. Case study 3: the right medial malleolus after 15 weeks of treatment with Acticoat Moisture Control.

dressings, and had received modified compression. She had previously refused high compression therapy. She had also received multiple courses of systemic antibiotics due to the recurrent wound infections.

Clinical presentation

The patient presented with a static, sloughy ulcer to her right medial malleolus that had small areas of visible granulation tissue (*Figure 9*). The ulcer measured 6cm² in area, with a depth of 0.2cm. Surrounding skin was erythematous, oedematous and macerated. The patient complained of intermittent pain that was controlled with analgesia.

Treatment description

The ulcer was dressed with Acticoat Moisture Control to absorb exudate, prevent further maceration and to provide an antimicrobial component to prevent recurrence of infection. A modified form of compression was used and the surrounding skin was treated with a potent steroid ointment and white soft paraffin. Dressing changes were performed three times each week by the patient's daughter-in-law, who is a practice nurse.

Outcome

Nine weeks after commencing treatment the ulcer had reduced in size and was visibly healthier with reduced slough. After 15 weeks, the majority of the ulcer was granulation tissue, with only a small amount of

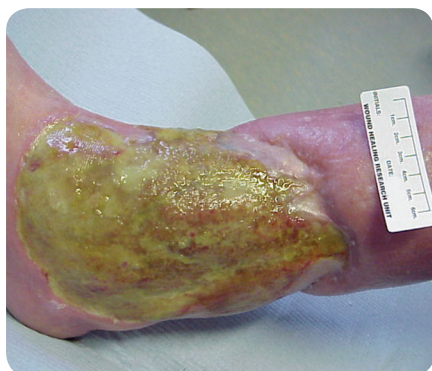

Figure 11. Case study 4: initial presentation of the patient's leg.

fibrin (Figure 10). The wound surface area had decreased to 2cm² in total, a reduction of 67% since commencing treatment. The surrounding skin was no longer macerated although erythema and oedema persisted. Acticoat Moisture Control was discontinued at this point as it was no longer indicated as exudate production was minimal and there was no evidence of further infection.

The wound progressed towards healing with Acticoat Moisture Control used in conjunction with a modified compression system. The patient complained of burning and stinging when the dressing was initially applied, but this subsided and she found the dressing comfortable to wear.

Case study 4 Clinical scenario

The patient was a 62-year-old woman with a three-year history of bilateral leg ulceration due to rheumatoid arthritis. She had a blood disorder which affected her platelet count and clotting times, for which she was taking warfarin, but experienced a deep vein thrombosis to the left leg about five years ago. Her other prescription medication included prednisolone for rheumatoid arthritis, alendronic acid and calcium supplements for osteoporosis, and furosemide. She was taking four different types of analgesia for mainly ulcer-related pain.

The patient had previous ulceration to her toes, which had since healed. She had suffered with recurrent wound

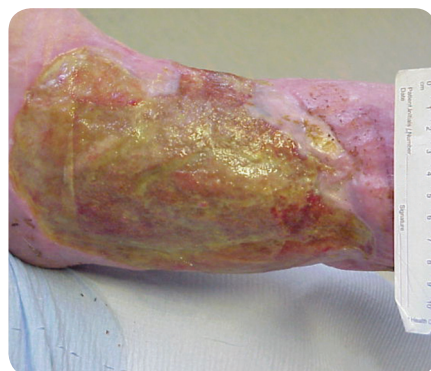

Figure 12. Case study 4: the leg after one week of treatment with Acticoat Moisture Control.

infections and cellulitis from the current ulceration to her legs, requiring multiple courses of systemic antibiotics. The patient had previously been treated with silver hydrofibre dressings for about four to six weeks, along with reduced compression therapy.

Clinical presentation

The patient presented with ulcerations to the gaiter area of both legs. The wound beds were covered with a thick layer of slough with a shiny appearance, suggestive of the presence of a biofilm. There were small areas of granulation tissue and islands of epithelium, but the wound edges seemed static (Figure 11). Surrounding skin was erythematous, oedematous and dry. Exudate production was very heavy, requiring twice-daily dressing changes by district nurses. The patient was experiencing intermittent pain and was unable to tolerate full compression therapy because of this.

Treatment description

Acticoat Moisture Control was initially applied to the ulcer on the right leg to manage exudate and maintain an optimum bacterial balance. Minimal compression was applied due to pain and emollients were applied to the surrounding skin.

Outcome

One week after commencing treatment with Acticoat Moisture Control, exudate levels had decreased and dressing changes were reduced to once every day. There was less slough evident on the ulcer bed, and the shiny

appearance had resolved (Figure 12). Sharp debridement was performed to the wound bed to further remove slough and biofilm, which was able to be lifted off easily. At this point, it was decided to change from using Acticoat Moisture Control to Acticoat as exudate levels had significantly reduced. The patient was experiencing less pain, allowing an increase to modified compression therapy.

Conclusion

Acticoat Moisture Control proved very effective in the management of these four chronic wounds that had varying causes. All four patients had chronic non-healing wounds that had persisted for several years but after commencing Acticoat Moisture Control, in conjunction with various forms of compression in three of the cases, they made significant progress towards healing or completely healed within months. Compression therapy is considered to improve healing in patients with venous disease (Fletcher et al. 1997), and is effective at minimising oedema, which also may be a goal of treatment in patients with other causes of ulceration. The ability of Acticoat Moisture Control to be used underneath multi-layer bandaging allowed management of the immediate wound environment while addressing the underlying disease, ensuring the patients received the optimum treatment for their ulceration.

The outcome of these case studies highlights the effectiveness of using nanocrystalline silver in clinical practice, as recurrence of persistent infections and the need for treatment with systemic antibiotics was prevented. Overall, the dressing maintained an optimal bacterial balance and managed exudate production efficiently and effectively, creating an ideal environment for progression of healing in wounds in the chronic cycle of inflammation and infection.

A number of studies, particularly focusing on patients with burns, have found that nanocrystalline silver can significantly impact on healing and rates of infection with challenging,

Key Points

- ▶ Infection is an important contributing factor in the development of chronic wounds.
- ▶ In-vitro and in-vivo research suggests silver dressings are effective antimicrobials.
- ▶ Nanocrystalline silver dressings rapidly release and replenish effective concentrations of silver into the wound environment.
- ▶ Acticoat Moisture Control dressings combine nanocrystalline silver and polyurethane foam to promote moist wound healing, manage exudate and optimise bacterial burden.
- ▶ In 10 out of 12 case studies, the use of Acticoat Moisture Control prevented the recurrence of persistent infection and need for systemic antibiotics.
- ▶ Challenging chronic non-healing wounds made significant progress towards healing within months of commencing Acticoat Moisture Control.

chronic wounds (Tredget et al, 1998; Sibbald et al, 2001; Demling and Desanti, 2002; Fong et al, 2005). Although the outcomes of these case studies only reflect clinical observations of a small number of cases, the results are consistent with other published evidence and support the use of this silver dressing in clinical practice. **WUK**

References

Bergin SM, Wraight P (2006) Silver based wound dressings and topical agents for

treating diabetic foot ulcers. *Cochrane Database Syst Rev* 1: CD005082

Burrell RE, Heggers JP, Davis GJ, Wright JB (1999) Efficacy of silver-coated dressings as bacterial barriers in a rodent burn sepsis model. *Wounds* 11(4): 64–71

Cochrane CA, Walker M, Bowler P, Parsons D, Knottenbelt DC (2006) The effect of silver-containing wound dressings on fibroblast function in vitro using the collagen lattice contraction model. *Wounds* 18: 29–34

Demling RH, DeSanti L (2002) The rate of re-epithelialisation across meshed skin grafts is increased with exposure to silver. *Burns* 28: 264–6

Dowsett C (2003) An overview of Acticoat dressing in wound management. *Br J Nurs* 12(19): S44–9

Dowsett C (2004) The use of silver-based dressings in wound care. *Nurs Stand* 19(7): 56–60

Edwards-Jones V (2006) Antimicrobial and barrier effects of silver against methicillin-resistant *Staphylococcus aureus*. *J Wound Care* 15(7): 285–90

Ennis W, Meneses P (2000) Wound healing at the local level: the stunned wound. *Ostomy Wound Manage* 46(1A Suppl): 365–485

Falanga V (2000) Classifications for wound bed preparation and stimulation of chronic wounds. *Wound Repair Regen* 8: 347–52

Fletcher A, Cullum N, Sheldon TA (1997) A systematic review of compression treatment for venous leg ulcer. *Br Med J* 315: 576–80

Fong J, Wood F, Fowler B (2005) A silver coated dressing reduces the incidence of early burn wound cellulitis and associated costs of in patient treatment: comparative patient care audits. *Burns* 31: 562–7

Harding KG, Morris HL, Patel GK (2002) Science, medicine and the future: healing chronic wounds. *Br Med J* 324: 160–3

Krishnamoorthy L, Morris HL, Harding KG (2001) Specific growth factors and the healing of chronic wounds. *J Wound Care* 10(5): 173–8

Lam PK, Chan ES, Ho WS, Liew, CT (2004) In vitro cytotoxicity of a nanocrystalline silver dressing (Acticoat) on cultured keratinocytes. *Br J Biomed Sci* 61: 125–6

Lansdown ABG (2002) Silver I: its antibacterial properties and mechanism of action. *J Wound Care* 11(4): 125–30, 173–7

Lansdown ABG (2004) A review of the use of silver in wound care: facts and fallacies. *Br J Nurs* 13(6): S6–S19

Leeper D (2006) Silver dressings: their role in wound management. *Int Wound J* 3(4): 282–94

Li XZ, Nikaido H, Williams KE (1997) Silver-resistant mutants of *Escherichia Coli* display active efflux of Ag⁺ and are deficient in porins. *J Bacteriology* 179(19): 6127–32

O'Meara SM, Cullum NA, Majid M, Sheldon TA (2001) Systematic review of antimicrobial agents used for chronic wounds. *Br J Surgery* 88: 4–21

Paddock HN, Schultz GS, Perrin KJ et al. (2002) Clinical assessment of silver-coated antimicrobial dressings on MMPs and cytokine levels in non-healing wounds. *Wound Repair Regen* 10: A45

Poon VK, Burd A (2004) In vitro cytotoxicity of silver – implication for clinical wound care. *Burns* 30: 140–7

Schultz GS, Barillo DJ, Mazingo DW, Chin GA (2004) Wound bed preparation and a brief history of TIME. *Int Wound J* 1(1): 19–32

Sibbald RG, Browne AC, Coutts P, Queen D (2001) Screening evaluation of an ionized nanocrystalline silver dressing in chronic wound care. *Ostomy Wound Manage* 47(10): 38–43

Thomas S, McCubbin P (2003) A comparison of the antimicrobial effects of four silver-containing dressings on three organisms. *J Wound Care* 12(3): 101–5

Tredget EE, Shankowsky HA, Groeneveld A, Burrell R (1998) A matched-pair, randomised study evaluating the efficacy and safety of Acticoat silver-coated dressing for the treatment of burn wounds. *J Burn Care Rehabil* 19(6): 531–7

Trengrove NJ, Stacey MC, Macauley S et al (1999) Analysis of the acute and chronic wound environments: the role of proteases and their inhibitors. *Wound Repair Regen* 7: 442–52

Vermeulen H, Ubbink DT, Storm-Versloot MN (2005) Topical silver for treating infected wounds (Protocol). *Cochrane Database Syst Rev* (1): CD005486

Warriner R, Burrell R (2005) Infection and the chronic wound: A focus on silver. *Adv Skin Wound Care* 18(Suppl 1): 2–12

Wright JB, Lam K, Buret AG, Olson ME, Burrell RE (2002) Early healing events in a porcine model of contaminated wounds: effects of nanocrystalline silver on matrix metalloproteinases, cell apoptosis, and healing. *Wound Repair Regen* 10: 141–51

Wright JB, Lam K, Burrell RE (1998) Wound management in an era of increasing bacterial antibiotic resistance: a role for topical silver. *Am J Infect Control* 26: 572–5

Yin HQ, Langford R, Burrell RE (1999) Comparative evaluation of the antimicrobial activity of Acticoat antimicrobial barrier dressing. *J Burn Care Rehabil* 20(3): 195–200