

# Evaluating Flexi-Seal® FMS: a faecal management system

Alison Johnstone

## Abstract

**Background:** Faecal incontinence can cause extensive damage to perineal/peri-anal skin resulting in excoriation and possibly tissue breakdown. **Aims:** To evaluate the benefits of using Flexi-Seal® FMS, a new faecal management system, in patients with liquid or semi-liquid faecal incontinence. The main outcomes assessed were resolution of excoriation, patient comfort, and ease of application. **Methods:** Results were collected using observation and verbal reporting by nursing staff and patients. **Results:** The system was evaluated by three patients and was tolerated well with resolution of perineal dermatitis. None of the patients reported discomfort on insertion of the FMS, and all clinicians reported that the system was simple to use. **Conclusions:** Although these findings are limited by the small cohort of patients involved, they suggest that in patients with liquid or semi-liquid faecal incontinence, Flexi-Seal® FMS may contribute to prevention of skin breakdown and/or improve dermatitis as part of a holistic care package. **Declaration of interest:** ConvaTec supplied the Flexi-Seal® FMS for use in this evaluation.

## KEY WORDS

Faecal incontinence  
Perineal/peri-anal skin injury  
Flexi-Seal® FMS  
Faecal management system  
Cross infection

Extensive skin damage can be caused by prolonged contact with excessive moisture from urine or liquid stool incontinence. Faecal incontinence causes more irritation to the perineal skin than urinary incontinence because faeces contain bacteria and digestive enzymes that damage the skin.

Patients with incontinence are also at risk of developing moisture lesions; breaks in the skin's integrity which increase susceptibility to pressure ulceration and secondary dermal infection (Cutting and White, 2002; Gray et al, 2002; Defloor et al, 2005). In patients with faecal incontinence, skin injury can occur within minutes of onset (Faria et al, 1996). Additionally, in

Alison Johnstone is Tissue Viability Nurse in Glasgow Royal Infirmary, Glasgow

patients with infective bacteria present in their faeces, e.g. *Escherichia coli*, incontinence may add to the risk of cross-infection.

The traditional devices used to manage faecal incontinence include bed pads, incontinence pads, faecal pouches, and rectal tubes/catheters, most of which are considered by the medical profession to be inadequate (Birdsall, 1986). Other methods of faecal management include the use of rigid or semi-rigid tubes such as nasopharyngeal airways (Grogan and Kramer, 2002). This practice has no evidence base, however, and it may cause damage to the delicate rectal tissue.

### Flexi-Seal Faecal® FMS

Flexi-Seal® FMS, a new faecal management system (ConvaTec, Ickenham, Middlesex), has been developed to assist clinicians in the management of faecal incontinence and infection control, and the prevention of associated skin damage.

The Flexi-Seal® FMS is a temporary containment device consisting of a soft, flexible, silicone catheter with a low-pressure balloon, which is filled

with water or saline to aid retention, and which is easily inserted into the patients' rectum (Figure 1). The catheter is attached to a closed-end collection bag. The FMS is suitable for the collection of liquid or semi-liquid stools and has a port to allow for the flushing of the system if required.

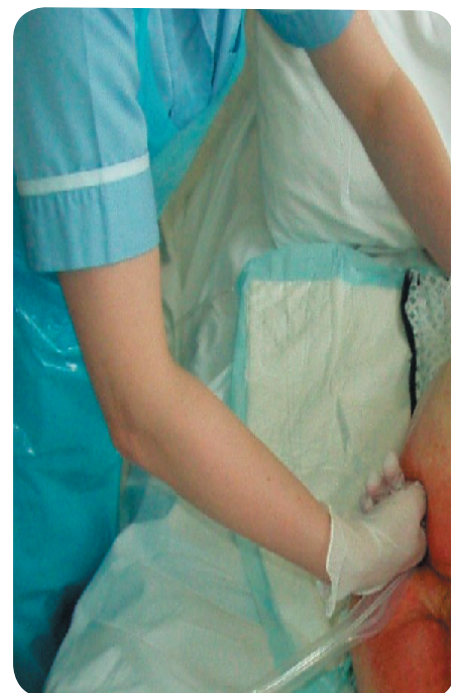

Figure 1. Flexi-Seal® FMS is easily inserted into the patient's rectum.

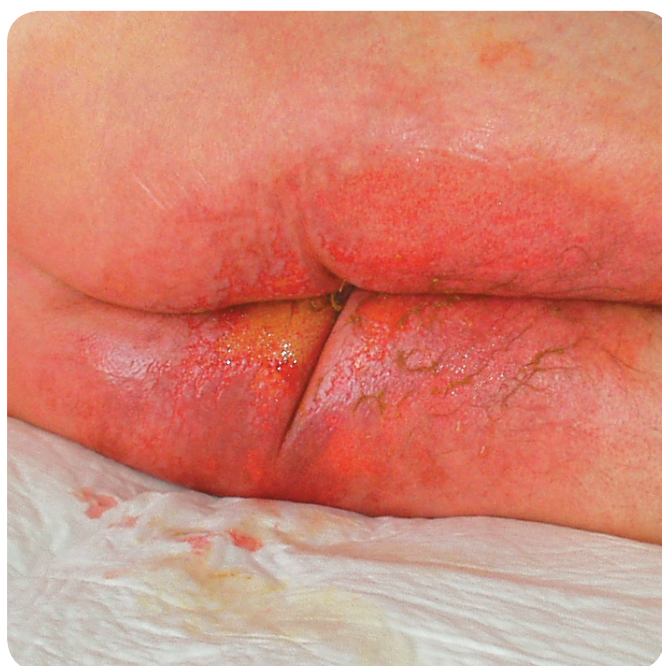

Figure 2. Extreme excoriation of the peri-anal region.

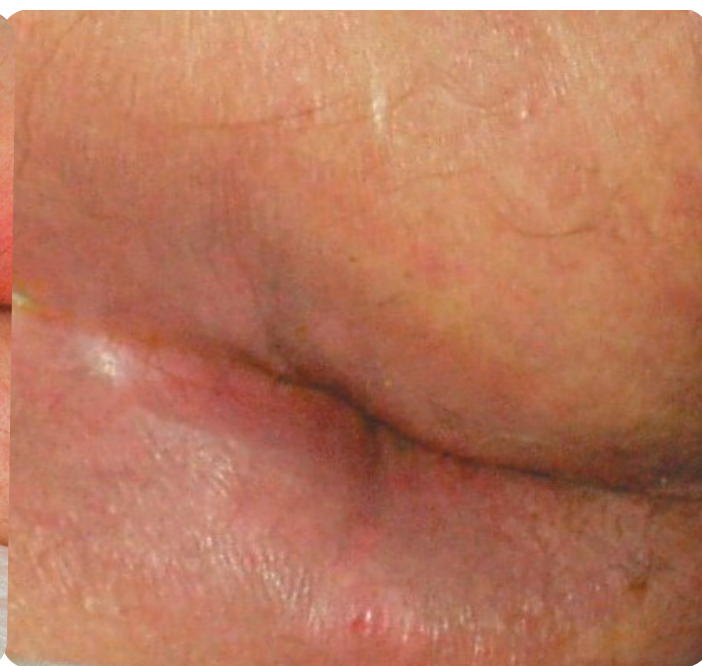

Figure 3. By day 7, skin integrity had returned to normal.

This paper will now report on the outcome of the use of the FMS in three case studies.

#### Patient 1

Mr A, a 46-year-old man, was admitted to hospital with jaundice secondary to alcohol-related liver disease. In order to eliminate toxins, thus preventing encephalitis and delirium tremens, aperients (lactulose 30–40mls) were given four times daily. Parenteral vitamins B and C (pabrinex) were also administered intravenously for the first 72 hours to allow rapid correction of severe vitamin depletion/malabsorption due to alcoholism. Diazepam was given as required in accordance with the Canadian Institute Withdrawal Alcohol tool (CIWA). After 72 hours, intravenous pabrinex was replaced with oral vitamin B<sub>12</sub>, four times daily and vitamin B<sub>1</sub>, three times daily.

Due to the aggressive nature of the aperients regime, patients often develop faecal incontinence. In this patient, the resultant faecal incontinence caused extreme excoriation of the peri-anal region (Figure 2) and upper thigh. The tissue viability nurse specialist (TVNS) was contacted for advice

on the maintenance of skin integrity. Staff were advised to insert a FMS in order to reduce the risk of further skin breakdown and promote healing of the already excoriated area, so the Flexi-Seal® FMS was introduced.

#### Results

Perineal dermatitis caused by faecal incontinence was reduced 48 hours after insertion of the FMS. The Flexi-Seal® FMS allowed for better observation of skin integrity and prevented additional exposure to damaging irritants and bacteria by establishing a local environment conducive to healing. By day 7, skin integrity had returned to normal (Figure 3).

#### Patient 2

Mr B, a 67-year-old man, was admitted to hospital with vomiting and diarrhoea, and was found to be infected with *Escherichia coli*. *E. coli* is part of the normal commensal gut flora and is normally referred to as enteric bacteria (Timbury et al, 2003). Certain strains are responsible for gastroenteritis, resulting in severe diarrhoea and dehydration.

In this patient, faecal incontinence resulted in perineal dermatitis. Fluid

intake and output was monitored and lost fluids and electrolytes were replaced. The Flexi-Seal® FMS closed-end collection bag collected faecal matter effectively and fluid output could be monitored more accurately than if incontinence pads were used. Additionally, the monitoring of faecal blood/melena and the taking of specimens was facilitated by the bag. In some circumstances, antimotility agents, antibiotics or opioids would be used to treat symptoms with the aim of stopping diarrhoea, however; where *E. coli* infection is present, this is not advisable as it is important that the infection is cleared and toxins are eliminated.

#### Results

Bacteria are present in infected faeces and may be a source of cross infection. The disposable, closed-end collection bag with non-return valve and integrated cap helped to minimise the risk of spreading infection, while also providing effective odour control. The soft flexible silicone catheter diverted stools away from the patient, minimising the risk of further skin breakdown and also facilitating the monitoring of frequency and characteristics of the patient's stools.

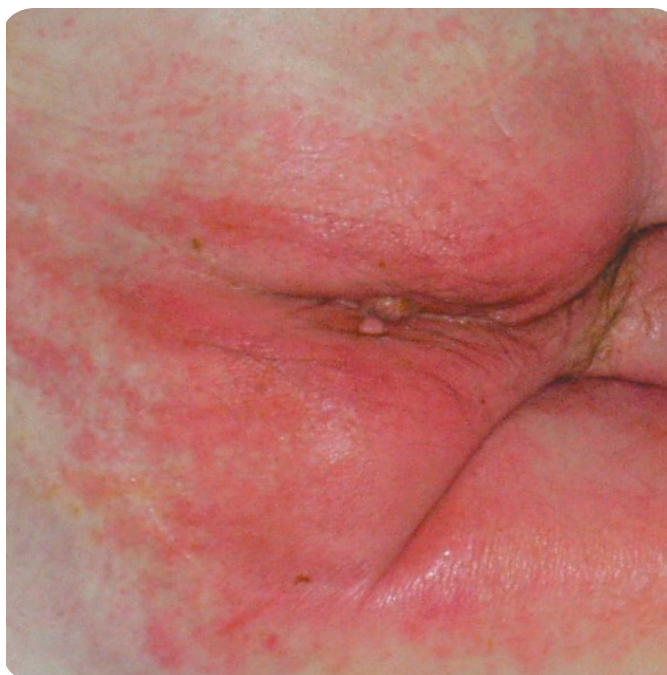


Figure 4. Faecal incontinence resulted in perineal dermatitis.

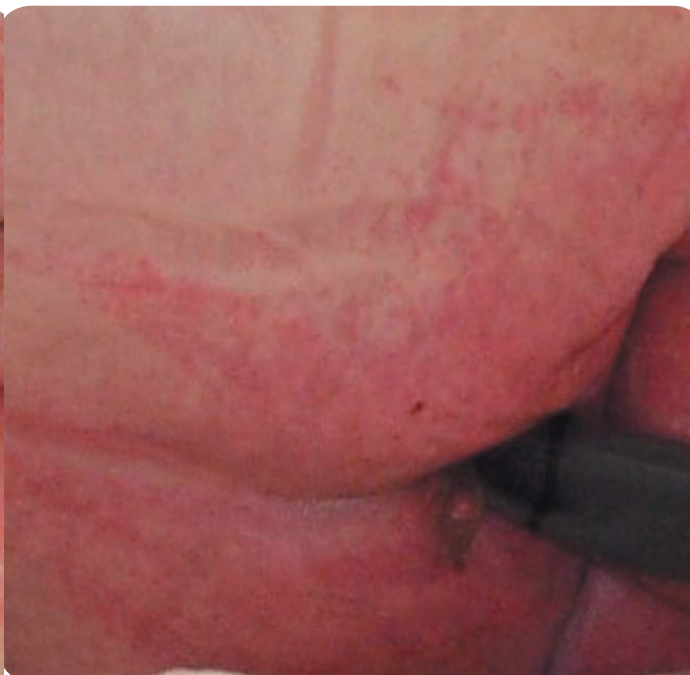

Figure 5. Perineal dermatitis was reduced within 24 hours of Flexi-Seal® FMS insertion.

Following insertion of the FMS, perineal dermatitis caused by faecal incontinence was reduced within 24 hours (Figures 4 and 5).

### Patient 3

Ms C, a 69-year-old woman, was admitted to hospital with unexplained diarrhoea. A stool sample was obtained and sent for culture, which diagnosed *Clostridium difficile* infection.

On assessment it was noted that she had recently taken antibiotics for a chest infection. Overgrowth of *C. difficile*, a normal inhabitant of the human large intestine, is a recognised complication of some antibiotic therapies and produces a specific condition called 'pseudomembranous colitis' which is life-threatening if not treated promptly (Martin, 1998).

Soon after admission, Ms C developed perineal dermatitis and excoriation to both groins (Figure 6). Following assessment by the TVNS, a FMS was applied to manage the diarrhoea, prevent cross infection and promote healing.

### Results

There was a marked improvement to the perineal region and groins within a 24-hour period of insertion of the FMS (Figure 7). Patient discomfort was reduced and the closed system may have helped to minimise the risk of spreading infection. However, it was noted on day 7 that the catheter was bypassing faecal fluid. This was rectified by using the irrigation port within the catheter to maintain a free flow of faeces. At day 28, the patient's condition had improved and stools were becoming formed. As the system is only designed for liquid or semi-liquid stools, it was removed at this point. Throughout the period that the FMS was in situ, no excoriation was noted on the patient's skin. The patient reported no discomfort and all the nurses involved found the Flexi-Seal® FMS easy to insert.

### Discussion

Loose stools and subsequent faecal incontinence can arise as a result of a medical condition or treatment. When faecal incontinence does occur, limiting contact with the patient's skin is extremely important as breakdown

can occur rapidly. The damage can range from mild napkin dermatitis to moisture lesions (Defloor et al, 2005). In addition to tissue injury, faecal incontinence can have a major impact on the patient's dignity and result in prolonged hospital stay.

Hartley (2005) reported on a recent mandatory study of acute and specialist trusts in England where cases of *C. difficile*-related diarrhoea were reported. From January to December 2004, 44488 cases were identified. Management of this health care-associated infection and other causes of faecal incontinence pose many challenges for health care professionals. Traditional methods of managing faecal incontinence have their shortfalls and are considered inadequate (Birdsall, 1986). As well as diverting faecal fluid away from the skin, closed systems such as the Flexi-Seal® FMS may assist with the control of infection, and allow for more accurate fluid balance and blood/melena monitoring.

### Cost-effectiveness

A small evaluation and cost-time analysis was carried out in the intensive care

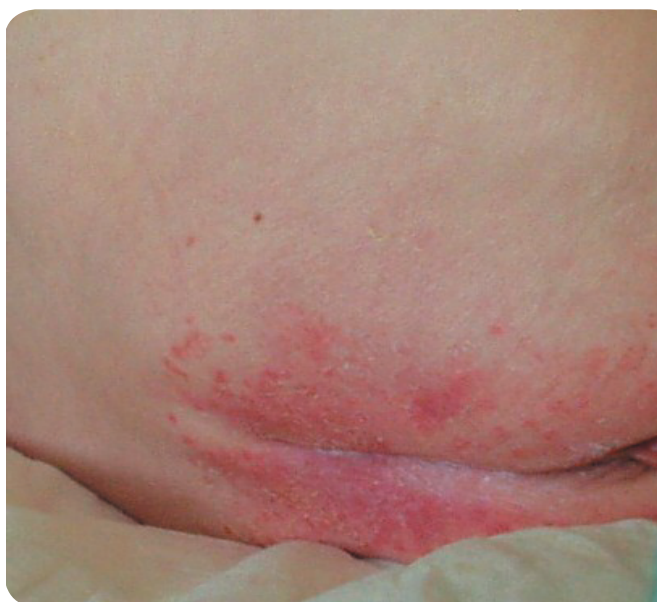

Figure 6. Perineal dermatitis.

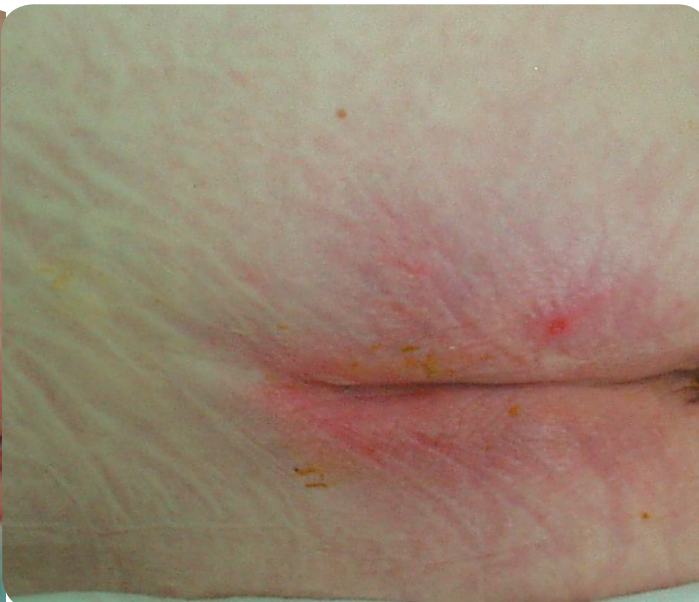

Figure 7. Marked improvement within a 24-hour period.

unit. Based purely on nursing time, linen and laundry, and assuming the patient is changed (due to faecal incontinence) three times a day, the cost would be £78.96 daily or £550.83 per week. Flexi-Seal® FMS costs £250. The system can stay in place for up to 29 days, making it extremely cost-effective.

### Conclusion

The main outcomes assessed in the case studies were: resolution of excoriation as a result of faecal incontinence, patient comfort, and ease of application of the FMS.

In this cohort of patients, the soft, flexible catheter was easily inserted with no discomfort to the patients. It gently conformed to the rectal vault, reducing the risk of necrosis, unlike rectal tubes, which are associated with perforation and sphincter damage (ConvaTec, 2003).

Flexi-Seal® FMS was successful in diverting faecal fluid away from the perineal/peri-anal tissue and resolved any dermatitis with excoriation that had developed, resulting in reduced nursing time. The patients found the device comfortable and application was simple as reported by all clinicians. Additional psychological benefits for the patients including decreased emotional trauma and embarrassment, and an increase in

physical comfort and dignity. The Flexi-Seal® FMS may represent a significant, new, cost-effective development in the care of faecally incontinent patients.

WUK

### References

- Birdsall C (1986) Clinical savvy: Would you put a foley catheter in the rectum? *Am J Nurs* 29(4): 193–201
- ConvaTec (2003) *FMS Cost-effective Survey*. Data on File, ConvaTec, Ickenham, UK
- Cutting KF, White RJ (2002) Maceration of the skin 1: the nature and causes of skin maceration. *J Wound Care* 11(7): 275–8
- Defloor T, Schoonoven L, Fletcher J, et al (2005) Pressure ulcers and moisture lesions. European Pressure Ulcer Advisory Panel Open Meeting, Aberdeen (Oral presentation)
- Faria DT, Shwayder T, Krull EA (1996) Perineal skin injury: extrinsic environmental factors. *Ostomy Wound Management* 42(7): 28–34
- Gray M, Ratcliff C, Donovan A (2002) Perineal skin care for the incontinent patient. *Advances in Skin and Wound Care* 15(4): 170–5
- Grogan TA, Kramer DJ (2002) The rectal trumpet: use of a nasopharyngeal airway to contain faecal incontinence in critically ill patients. *JWCON* 29(4): 193–201
- Hartley J (2005) C.diff rates expose wider HAI challenge. *Nursing Times* 101(35): 2
- Martin AM (1998) *Concise Colour Medical Dictionary*. Oxford University Press, Oxford: 133

Timbury MC, McCartney AC, Thakker B, Ward KN (2003) *Notes on Medical Microbiology*. Churchill Livingstone, Edinburgh

### Key Points

- ▶▶ Faecal incontinence can lead to excoriation and tissue breakdown.
- ▶▶ Traditional devices to manage faecal incontinence are considered inadequate.
- ▶▶ Flexi-Seal® FMS has been developed to assist clinicians in the management of faecal incontinence, infection control, and associated skin damage.
- ▶▶ Flexi-Seal® FMS is a temporary containment device consisting of a soft, flexible, silicone catheter, attached to a closed-end collection bag.
- ▶▶ Flexi-Seal® FMS may be an alternative which contributes to improvement in skin excoriation and the prevention of skin breakdown.