

## Stages of wound healing: application in practice

Jeanett Collins is Senior Sister Dermatology and Tissue Viability Specialist, and Anita Heron is Ward Sister, Dermatology and Tissue Viability, Lurgan Hospital, Craigavon Area Health Trust, Northern Ireland

Healing the intractable chronic wound demands skill, experience and an excellent knowledge base from the nurse. The theory of wound healing needs to be matched with the practical aspects of the patient's care in terms of available treatments and the patient's wishes. This article will review a case study where the principles of wound management were used by the nurses of Ward 5 to assess a patient and to select an appropriate dressing in order to promote an ideal wound healing environment, while still relieving the symptoms of the chronic wound and allowing the patient to have some input into her care.

### The patient

This case study reviews the care of a 77-year-old independent and hard-working female. The patient was a shop owner who had long periods of standing while serving in her shop. Her husband was confused and required care, so she was solely responsible for the shop and this led to her being somewhat depressed. Four years previously, the patient had developed a venous leg ulcer. She was philosophical about her wound and she considered her leg ulcer unimportant. Nevertheless, she had concerns about the odour, and also had continuous pain which was a constant reminder that the wound was there. Unfortunately, the patient could not tolerate oral analgesia and so the GP provided her with 'patches' to relieve the pain.

### Previous treatments

Previous treatments had included larvae, Iodoflex (Smith and Nephew Healthcare, Hull), Inadine (Johnson and Johnson Wound Management, Ascot) and hydrocolloids. All of these had helped to clean the wound, and the wound appeared ready to heal, but did not progress, and the pain was not relieved. The patient had also refused antibiotics and there was always the potential risk of clinical infection. The patient tended to interfere with the bandages after they have been applied, so it was important to ensure the products used to prepare the wound bed, treat the symptoms, and heal the ulcer were acceptable to her.

### Assessment of the wound

ActiFormCool (Activa Healthcare, Staffordshire) was first applied on the 1st September 2004 (Figure 1) with Actico Short-Stretch bandages (Activa Healthcare, Staffordshire) and the recommendation to change the dressing three times weekly. The wound appeared very red and beefy and there was surrounding maceration due to large amounts of exudate, making it difficult to dress (Young, 1995).

### Treatment

The patient was in constant pain, so the dressing needed to be moist in order to bathe the nerve endings (Flanagan, 1997). Although the wound required a moist dressing, because of the large amounts of exudate and maceration, the dressing should not increase 'wetness' in the wound. Therefore, ActiFormCool was selected as it would assist with reducing the pain (Hampton, 2004), and would be moist without being too wet.

On 17th January (Figure 2) the wound was overgranulated. The assessing nurse was reluctant to continue with the dressing but the patient insisted on having ActiFormCool because of the pain relief, as previous treatments had not coped with this. By the 16th of March, the tissues had flattened with the first signs of epithelialisation and some bridging (Figure 3). Assessment on the 18th March 2005 (Figure 4) found the ulcer bed pale and less vascularised with signs of continued granulation and epithelialization evident from the bridging. Dressing changes were twice weekly.

Assessment and reassessment was an important aspect of this patient's care to ensure the wound progressed through all stages of healing. The wound moved from optimal inflammation through to granulation, but then halted, becoming overgranulated in appearance. However, through continued use of the dressing (at the patient's insistence), the wound moved from the stage of granulation to epithelialisation to complete the stages of wound healing.

### Conclusion

Removing the pain and reducing the exudate was of prime importance and the selection of ActiFormCool was correct for this patient as it met both of these criteria.

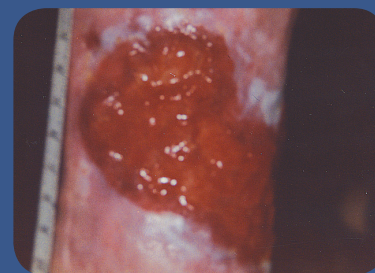

Figure 1. Red and beefy wound with maceration requiring exudate management.

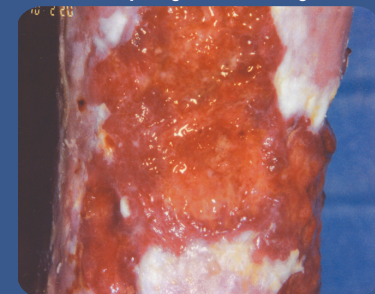


Figure 2. Wound starting to debride with some maceration evident.

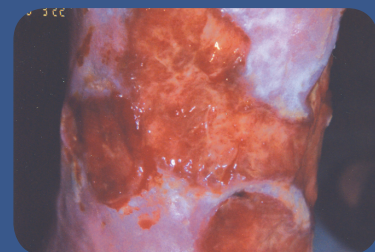


Figure 3. Hypergranulation tissue flattened and evidence of epithelialisation.

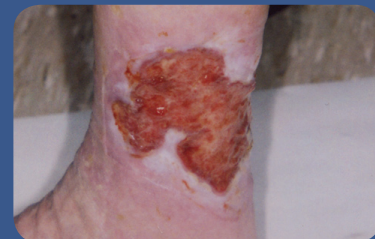

Figure 4. Continued granulation and epithelialisation; wound is pale and less vascularised.

The patient's wound progressed to a healing state passing through the stages of wound healing. Continuous assessment is essential to move the wound effectively on to the next stage through appropriate dressing selection. Sometimes it is not easy to make the right decision, but through the use of an assessment tool, and working with the patient, the decision becomes a common-sense process. **WUK**

Flanagan M (1997) *Wound Management*. Churchill Livingstone, Edinburgh: 64

Hampton S (2004) A small study in healing rates and symptom control using a new sheet hydrogel dressing. *J Wound Care* **13(7)**: 297

Young T (1995) Common problems in wound care: overgranulation. *Br J Nurs* **4(3)**: 169-70