

ARE HYDROCOLLOID DRESSINGS SUITABLE FOR DIABETIC FOOT ULCERS?

Caroline McIntosh is Senior Lecturer in Podiatry, Centre for Health and Social Care Research, University of Huddersfield, West Yorkshire

The controversy surrounding the use of hydrocolloid dressings on diabetic foot ulcers (DFUs) has stemmed from reports of infection and other adverse events. This article reviews the literature and evidence for and against the use of hydrocolloids for this type of wound and questions whether anecdotal reports and the inappropriate application of dressings has led to this confusion. Recommendations for how and when to use hydrocolloid dressings on DFUs are also presented.

Hydrocolloids are a particular category of wound dressings that are widely used in clinical practice to manage a number of different wound types (*Figure 1*). Pudner (2001) advises that they should be used for necrotic or sloughy wounds to promote wound debridement as their occlusive nature facilitates autolysis (the body's natural process of breaking down dead or devitalised tissue).

Hydrocolloids are also indicated for granulating and epithelialising wounds. They contain gel-forming agents, such as gelatin, so when the dressing comes into contact with wound exudate it absorbs fluid and forms a gel which creates a moist healing environment (Heenan, 1998). Generally hydrocolloids are suitable for light to moderately exuding wounds and are unsuitable for heavily exuding wounds as they are unable to

absorb large amounts of wound fluid (Pudner, 2001).

It is clear that hydrocolloids have many beneficial properties to warrant their use in modern wound care (*Table 1*), however, much controversy exists regarding their use for diabetic foot ulcers. This has largely stemmed from subjective reports of infection associated with their use (Foster et al, 1997) and adverse events, such as contact dermatitis (Seheiz et al, 1996) which has been directly attributed to their use.

This article aims to review the literature and make recommendations for clinical practice regarding the use of hydrocolloids on the diabetic foot.

Hydrocolloids and DFUs

There is limited evidence within medical literature to determine whether hydrocolloids are

safe to use on the diabetic foot (*Figure 2*). The evidence that does exist is largely contradictory, based on subjective reports of clinical experience or small studies that do not provide conclusive evidence.

One randomised controlled trial compared adhesive zinc oxide

Table 1

Properties of hydrocolloid dressings

- » The occlusive nature of the dressing promotes a moist environment, a recognised requirement for optimal healing (Winter, 1962)
- » All hydrocolloids have an outer waterproof layer that is impermeable to bacteria (*Figure 1*)
- » The inner hydrocolloid layer, seen in *Figure 1*, interacts with wound exudate to form a gel which promotes autolysis
- » The occlusive nature of the dressing is thought to stimulate new tissue formation
- » Hydrocolloids provide thermal insulation enabling the wound bed to remain near body temperature

(Heenan, 1998; Pudner, 2001)

tape with Duoderm (ConvaTec, Deeside) — a hydrocolloid dressing — in the management of necrotic diabetic foot ulcers (Apelqvist et al, 1990). Fifteen of the 44 patients in the study showed an increase in the area of necrosis during the five-week study, 10 of whom had been treated with the hydrocolloid dressing. However, the sample size investigated was small and limited to individuals with necrotic foot ulcers, thus excluding other types of diabetic foot wounds.

Knowles et al (1993) undertook a retrospective study on the use of Granuflex hydrocolloid dressing (ConvaTec, Deeside) and other dressings in the treatment of diabetic foot ulcers. Information was collected on 250 ulcers that required 2,316 dressing changes.

Their findings suggest that healing and infection rates were similar in the Granuflex group when compared with the other groups. They concluded that Granuflex is equally effective and safe to use as other dressings commonly used on diabetic foot ulcers. Gill (1999) reviewed the literature on the use of hydrocolloids on the diabetic foot and suggested that the concerns regarding the use of hydrocolloids on DFUs has largely centred on subjective reports of adverse events, which often arose due to the inappropriate use of these dressings.

Gill (1999) recommends that practitioners should base dressing choice on careful wound

assessment and a thorough knowledge of dressing properties, in addition to local policy.

Key considerations before selecting a hydrocolloid for a DFU should include:

- ▶▶ Assessment of the viability of the surrounding skin before application as the skin can be vulnerable to tearing when the dressings are removed
- ▶▶ Assessment of signs of infection. Foster et al (1997) reported eight cases of wound deterioration following application of hydrocolloid dressings on DFUs. However, dressings were left in situ for 5–7 days, which Gill (1999) argues is an inappropriate use of the dressing. While there is a recognised need for further studies to investigate hydrocolloid use and infection rates in DFUs, in the absence of such evidence it is suggested that caution should be exercised in the presence of infection (Heenan, 1998; Gill, 1999; Pudner, 2001)
- ▶▶ As hydrocolloids contain gelatin, a derivative of animal products, it is important to establish whether the patient has any religious or cultural preferences which might mean they are unwilling to consent to the application of the dressing
- ▶▶ If in any doubt about the suitability of hydrocolloid dressings for a patient, always seek advice from your local tissue viability nurse specialist before commencing treatment.

Applying hydrocolloid dressings

When applying a hydrocolloid on a DFU it is important to address the following:



Figure 1. Example of a hydrocolloid dressing.

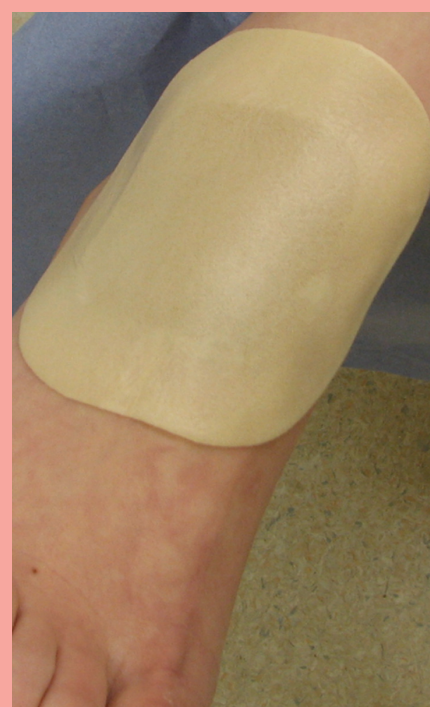

Figure 2. Hydrocolloid on the foot.

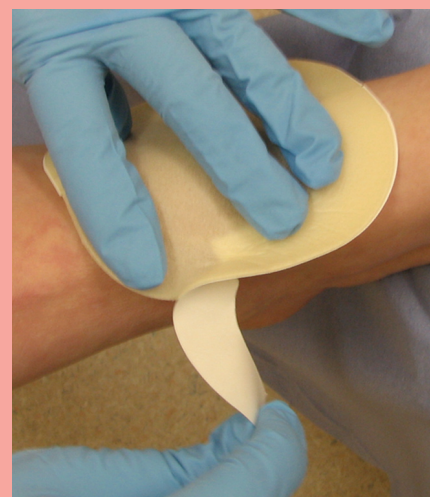


Figure 3. Applying a hydrocolloid dressing.

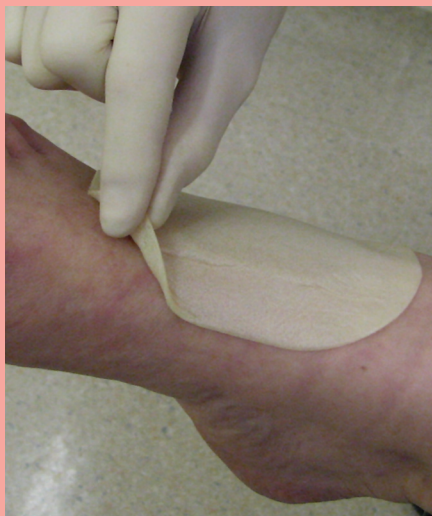

Figure 4a. To remove the hydrocolloid, gently lift the edge of the dressing.

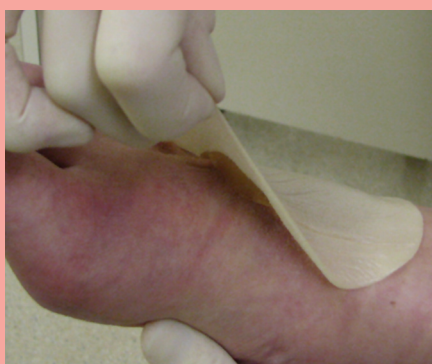

Figure 4b. Use a gentle upward pulling motion to reduce the seal of the dressing on the skin.

- ▶▶ Ensure the correct size of dressing is chosen. Pudner (2001) suggested that leakage will occur if the dressing is too small. A clear margin of 2cm from the wound edge should be achieved
- ▶▶ Ensure the skin is dry before application to ensure adherence
- ▶▶ Any backing should be removed (Figure 3), before the dressing is smoothed onto the skin
- ▶▶ A secondary dressing is not required.

Removal of dressings

Frequency of dressing change should be judged clinically on

the level of wound exudate. Pudner (2001) advises that hydrocolloids can alter appearance as they absorb exudate and can give a visual indication of the need for a change of dressing. Removal of the dressing is best achieved by gently lifting an edge of the dressing (Figure 4a) and pulling carefully in an upwards motion to reduce the seal of the dressing on the skin (Figure 4b) and minimise trauma to the wound bed and surrounding skin.

It is not uncommon after initial application of a hydrocolloid dressing for the wound to increase in size and the patient should be made aware of this to avoid unnecessary concern. Such an increase is usually only noticeable on removal of the initial dressing (Pudner, 2001). Additionally, a slight malodour and gel residue are often reported after dressing removal which can resemble pus (Pudner, 2001). While this is normal, it is not surprising that the inexperienced practitioner might confuse this with infection, which may have contributed to the previous reports of adverse events associated with hydrocolloid use on DFUs.

Conclusion

Controversy currently exists in published literature on the use of hydrocolloid dressings on DFUs with some sources reporting adverse events while others support their use. It is suggested that hydrocolloids can be used safely on DFUs, providing that they are used on appropriate wounds after a thorough patient assessment,

the wound is superficial with no signs of infection, there is low to moderate exudate and dressings are changed frequently. **WE**

Apelqvist J, Larsson J, Lstenström (1990) Topical treatment of necrotic foot ulcers in diabetic patients: a comparative trial of Duoderm and MeZinc. *Br J Dermatol* **123** (6): 787–92

Foster AVM, Spencer S, Edmonds ME (1997) Deterioration of diabetic foot lesions under hydrocolloid dressings. *Pract Diabetes Int* **14**(2): 62–4

Gill D (1999) The use of hydrocolloids in the treatment of diabetic foot. *J Wound Care* **8**(4): 204–6

Heenan A (1998) Frequently asked questions: hydrocolloid dressings. *World Wide Wounds* www.worldwidewounds.com/1998/april/Hydrocolloid-FAQ/hydrocolloid-questions.html (Last accessed 2nd February 2007)

Knowles EA, Westwood B, Young MJ et al (1993) A retrospective study of the use of Granuflex and other dressings in the treatment of diabetic foot ulcers. In: Harding KG, Cherry G, Dealey C, Gottrup F (1993) *Proceedings of the 3rd European Conference on Advances in Wound Management Harrogate 19–22 October*. Macmillan, London: 117–20

Pudner R (2001) Hydrocolloid dressings in wound management JCN (online) www.jcn.co.uk/journal.asp?MonthNum=04&YearNum=2001&Type=backissue&ArticleID=343 (Last accessed 7th February 2007)

Seheiz M, Rauterberg A, Weib J (1996) Allergic contact dermatitis from hydrocolloid dressings. *Contact Dermatitis* **34**(2): 146

Winter G (1962) Formulation of the scab and the rate of epithelialisation in the skin of the domestic pig. *Nature* **193**: 293–4