

HydroClean® plus: a new perspective to wound cleansing and debridement

KEY WORDS

- ▶ Wound care
- ▶ Wound healing
- ▶ Pain
- ▶ Wound infection
- ▶ Clinical effectiveness
- ▶ Quality of life
- ▶ Superabsorbent
- ▶ Wound progression
- ▶ Debridement
- ▶ Wound cleansing
- ▶ Desloughing

A number of clinical studies and case reports have shown that HydroClean plus effectively cleanses wounds of necrotic tissue, fibrinous slough and bacteria-laden wound exudates. Due to the innovative technology inherent in the polyacrylate superabsorbent material at the core of these dressings, the wound is actively cleansed by the rinsing and absorbing effect of this pad core. Optimisation of the moist wound environment and promotion of autolytic debridement supports the formation of new granulation tissue and leads to progression of wound healing response. This product focus explores the evidence supporting HydroClean plus and hydro-responsive wound dressings.

The process of debridement is an important step in the preparation of the wound bed in chronic wounds. Ways in which wound debridement can be achieved include surgical, sharp, mechanical, enzymatic and autolytic debridement. Expert opinion and clinical experience suggest that removal of the material such as necrotic tissue and fibrinous slough from the surface of a wound is necessary for the preparation of the surface for healing progression to take place (Schultz et al, 2003; Wolcott et al 2012; Strohal et al, 2013). A number of clinical papers have focused on the importance of debridement in the preparation of the wound bed for subsequent healing (Kirshen et al, 2006; Marazzi et al, 2006; Ousey and McIntosh, 2010; Milne, 2015).

Tissue necrosis and fibrinous slough present on the wound act as a physical barrier for wound epithelialisation. The devitalised tissue can also act as a reservoir for bacterial contamination. As well as the potential for the development of wound infection, the uncontrolled release of bacterial toxins and other irritant molecules can cause an intensification of wound inflammatory reactions, further inhibiting healing.

Moist wound healing is a concept which lies at the heart of many of today's modern wound dressings (Bishop et al, 2003; Sibbald et al, 2015). Optimising the moisture levels of the wound provides the ideal environment for wound healing to progress. One of the important advantages of an ideally hydrated

wound bed is wound cleansing through the promotion of autolytic debridement.

The requirements of the modern wound dressing are manifold: effective control of exudate balanced against promotion of an appropriate level of wound hydration to optimise a moist wound healing environment, promote autolytic debridement of devitalised tissue and aid its removal, as well as reduce the bacterial burden of the wound bed. HARTMANN have developed a range of dressings that can deliver or absorb moisture depending on the environmental fluid balance (i.e. hydro-responsive dressings) based upon a chemically inert superabsorbent polyacrylate (SAP) material which is 'activated' with Ringer's solution (*Table 1*). The Ringer's solution is made available to the wound bed and fibrinous slough coatings and necrotic tissue are softened and detached. At the same time, the SAP within the wound dressing pad absorbs bacteria- and proteinase-laden wound exudate into its absorbent core and binds it away from the wound surface (Bruggisser, 2005; Eming et al, 2008). This article describes the benefits of these hydro-responsive wound dressings.

HYDROCLEAN RANGE

The first version of the dressing received the CE mark in 1995. Over the years, the core technology of the hydro-responsive wound dressings has remained unchanged, though there have been

KAREN OUSEY
Reader Advancing Clinical Practice, School of Human and Health Sciences, Institute of Skin Integrity and Infection Prevention, University of Huddersfield, Queensgate, Huddersfield, UK

ALAN A ROGERS
Independent Wound Care Consultant, Flintshire, UK

MARK G RIPPON
Visiting Clinical Research Fellow, School of Human and Health Sciences, Institute of Skin Integrity and Infection prevention, University of Huddersfield, Queensgate, Huddersfield, UK

Table 1. Summary of how the hydro-responsive dressing has evolved from 1995 to date				
Product	TenderWet®	TenderWet 24	HydroClean	HydroClean plus
Pre-moistened SAP			Yes	Yes
PHMB included				Yes
Duration of use (h)	12	24	24	72
On the market	1995	1999	2004	2011
Notes	Now discontinued	Now discontinued	Unavailable in the UK	Currently available in the UK

slight modifications in dressing design as part of a drive for continual improvement (e.g. ease of application). Early dressing iterations required a ‘pre-activation’ step with application of a defined volume of Ringer’s solution to the dressing in order to hydrate the superabsorbent core and allow capacity to further absorb. In contrast, the current product, HydroClean plus, is pre-activated with Ringer’s solution and is presented in a ready-to-use form.

For the purpose of this product focus, clinical studies based on previous iterations of the product are also referenced and therefore the evolving HydroClean product range is detailed in *Table 1*.

For the purposes of this review, as the evolution of the product is based on the same mechanism of action, the term hydro-responsive wound dressing (HRWD) is used as a general term for the product group.

HYDROCLEAR PLUS

HydroClean plus (*Figure 1*) consists of a superabsorbent wound dressing pad which creates, in combination with Ringer’s solution, a moist environment when applied. It is presented as a ready-to-go ‘pre-activated’ dressing that provides a moist wound environment for up to 3 days (Spruce et al, 2016). Wound bed tissue necrosis and slough are softened and easily removed. The absorbent core of HydroClean plus is a SAP, contained within

a cellulose matrix (*Figure 2*). These polymers are able to absorb large amounts of fluid due to the material’s chemical properties (Buchholz and Graham, 1998). The material’s ability to donate moisture and absorb bacteria and proteins within the pad is facilitated by the presence of Ringer’s solution-activated SAP (Bruggisser, 2005; Eming et al, 2008). Bound bacteria and proteins are then removed from the wound when the dressing is changed (*Figure 3*). In addition, the antiseptic Polyhexanide (polyhexamethylene biguanide, [PHMB]) is bound to the SAP core. PHMB, a synthetic compound, has become increasingly used in wound dressings and has been identified as an antiseptic with a broad spectrum of activity. PHMB is able to act at multiple sites within the bacteria and presents a low risk of generating resistance in micro-organisms (Gilliver, 2009; Sibbald et al, 2011). The presence of PHMB provides an antibacterial effect for the inhibition of bacterial proliferation within the wound dressing.

The wound contact layer of HydroClean plus is composed of a non-adherent hydrophobic layer which conforms well to the wound surface. The presence of pores within the wound contact layer allows free exchange of Ringer’s solution and wound exudate (Mwipatayi et al, 2005). This layer also contains silicone strips to prevent the dressing from adhering to the wound, aid atraumatic dressing removal and minimise irritation of the wound or periwound skin (Rippon et al, 2007, 2012; Rogers et al, 2013). The atraumatic removal of wound dressings provides significant benefits for patient care (Rippon et al, 2012). Dressing-dependent tissue trauma is reduced with a concomitant reduction in pain at dressing change being reported (Rippon et al, 2012; Rogers et al, 2013). The reduction in experienced pain leads to a corresponding reduction in patient stress levels at dressing changes (Rippon et al, 2012). HydroClean plus also has a moisture-proof

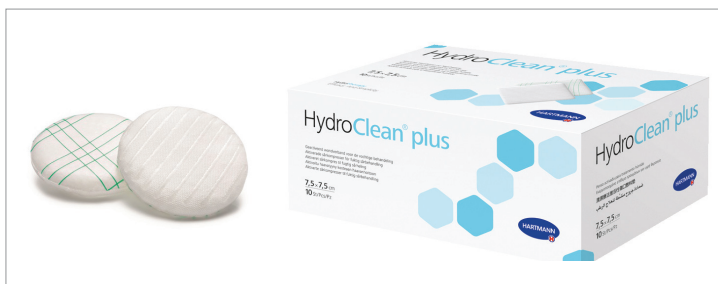

Figure 1. HydroClean plus — a hydro-responsive dressing (HRWD)




Figure 2. Cut-away schematic of the superabsorbent polyacrylate core of HydroClean plus. (A) Waterproof covering film; (B) non-adherent wound contact layer with silicone strips; and (C) superabsorbent polyacrylate core with Ringer's solution

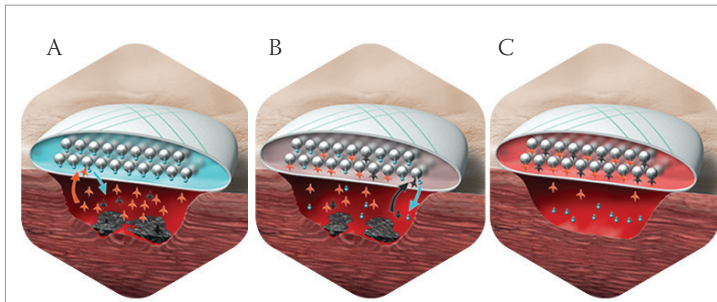


Figure 3. Schematic diagram showing the unique rinsing and absorbing action of HydroClean plus. (A) Continuous release of Ringer's solution (blue) from the superabsorbent polyacrylate core leading to softening of necrotic tissue and fibrin coatings (black) and uptake of bacteria- and protein-laden wound exudate (red); (B) absorption of necroses, fibrinous material, bacteria and exudate into the polyacrylate core; and (C) wound cleansing and generation of optimal wound environment for starting and facilitating the healing process

layer to prevent strikethrough of the dressing.

HYDROCLEAN PLUS CAVITY

A modification in the design of HydroClean plus, HydroClean plus Cavity, has no silicone strips nor a film backing, making the dressing suitable for packing deep wounds.

INDICATIONS FOR USE OF HYDROCLEAN PLUS

HydroClean plus dressing is designed to be used in wounds where wound debridement, desloughing and cleansing (i.e. wound conditioning) are required, e.g. in chronic wounds with high exudation, in clinically infected wounds or in chronic wounds of various aetiologies (e.g. diabetic foot ulcers, leg ulcers). HydroClean plus cavity can also be used for the packing of deep wounds. *Figure 4* shows clinical examples of HydroClean plus *in situ*.

CLINICAL EVALUATIONS

Debridement and wound cleansing

In a multi-centre, open, prospective, randomised and two-arm parallel group study with blinded outcome assessment, Humbert et al (2014) reported on a 75-patient study undertaken to assess the influence of HRWD in wound bed preparation via autolytic debridement of fibrinous slough and necrotic tissue. The proportion of ulcer area covered by slough and necrosis decreased by $39.6 \pm 29.9\%$ in the HRWD group and by $16.8 \pm 23.0\%$ in the comparator (amorphous gel group) compared with baseline ($P=0.004$). After 14 days of treatment, 12/22 (54.5%) chronic ulcers treated with HRWD had <50% surface coverage by slough/necrosis compared to 7/30 (23.3%) ulcers in the amorphous gel group ($P=0.0209$). The proportion of ulcer area covered by granulation tissue was $36.0 \pm 27.4\%$ and $14.5 \pm 22.0\%$ in the HRWD and amorphous gel groups, respectively ($P=0.005$).

These results are supported by a large, prospective, non-comparative multicentre observational study in 403 patients which showed the wound cleansing properties of HRWD in a variety of chronic wounds (HARTMANN, 2010). At the start of the treatment, 56% of the wounds were coated >50% with fibrin which reduced to 8% within one month of commencement of treatment. Thirty-two percent wounds were coated with necrotic tissue and this proportion reduced to 5%. Wound bed granulation tissue increased during the course of the treatment.

König et al (2005) examined the effectiveness of HRWD in desloughing venous leg ulcers. During the first 2 weeks of treatment, slough was reduced by almost 20% for HRWD and by almost 10% for the comparator (enzyme ointment), with an increase of 26% and 10%, respectively, in granulation tissue. Overall, no statistically significant difference could be found between the two treatment groups and the conclusion of the study was that both autolytic debridement by HRWD and the enzyme debridement were equally effective.

Spruce et al (2016) reported results from a community-set HydroClean plus evaluation in 20 patients with a variety of chronic wounds, with the primary outcome being an evaluation of the overall performance of HRWD in promoting wound bed preparation and wound progression.

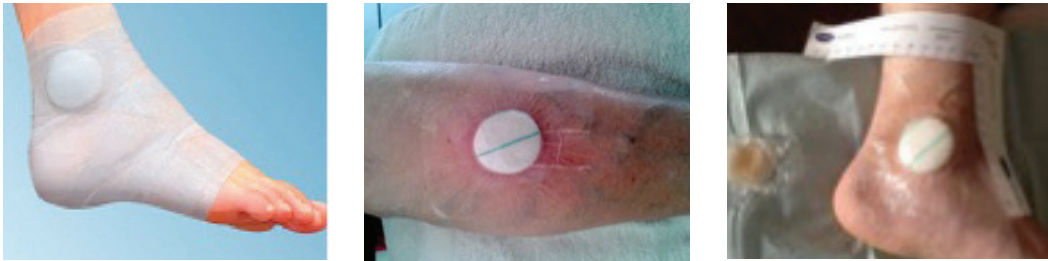

Figure 4. Schematic representation of HRWD fixed at ankle wound (left) and two clinical examples of HRWD fixation over wound using transparent film (middle and right).

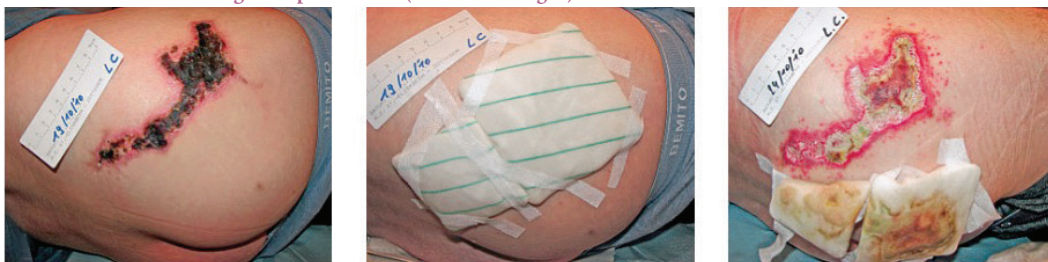


Figure 5. Clinical example of wound debridement following application of a HRWD to a wound with significant tissue necrosis.

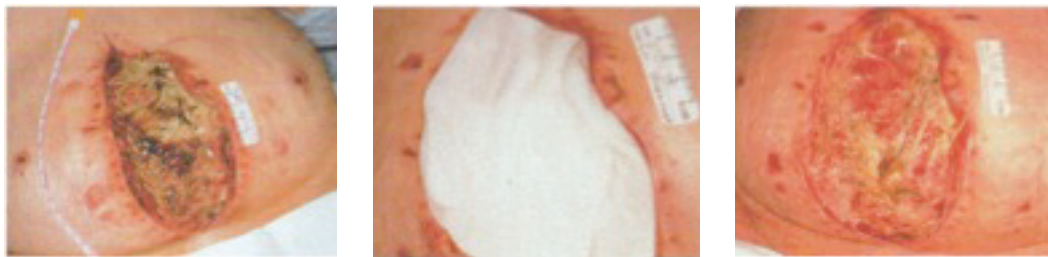

Figure 6. Clinical example of wound debridement following application of HydroClean plus to a dehisced abdominal wound. Significant removal of necrosis and slough by Day 2 after dressing application

Over the course of the evaluation period, there was a mean reduction of 62% in the level of devitalised tissue present in the wounds. Forty-five percent ($n=9$) of patients were >80% debrided to healthy tissue in the wound bed. In addition, there was a reduction in wound size and/or depth in 50% ($n=10$) of patients. Wound area was reduced by 21.5% and there was a 45.7% reduction in wound depth in the wounds over the treatment period, indicating a progression in the healing response. In a cost benefit analysis, the author highlighted the potential for cost savings associated with the standard practice use of this dressing compared with other comparative treatments.

In a study of 37 patients with leg ulceration by Scholz et al (1999), there was a significant wound cleansing effect and a concomitant increase of granulation and epithelialisation when venous leg ulcers were treated with HRWD. Reductions in fibrinous slough and necrosis of 40–60% was reported for 7 patients, 60–80% in 18 patients and

80–100% in 7 patients. In 10 patients, granulation increased by 40–60%, in 17 patients by 60–80% and in 5 patients by 80–100%.

A similar trend highlighting the beneficial effects of HRWD in the promotion of wound debridement was found in two studies by Kaspar et al. A prospective, open-label observational multi-centre study of 221 patients with a variety of chronic wounds patients treated with HRWD showed the number of wounds completely or partly (>50% surface area) covered with fibrinous slough decreased from 54% to 9%. In addition, the number of wounds showing granulation tissue (>50% surface area) increased from 5% to 74% (Kaspar et al, 2008). More recently, Kaspar (2011) reported that the use of HydroClean plus in 170 patients with chronic wounds which resulted in a reduction in the proportion of wounds containing slough and necrosis and a corresponding increase in wounds with granulation tissue. The establishment of a moist environment by HydroClean plus promoted

autolytic debridement and removal of devitalised tissues in chronic wounds.

A retrospective, non-controlled, descriptive study on the use of HRWD on the debridement of chronic wounds indicated that there was a significant difference in the mean debridement rates among a group of 55 patients (Paustian and Stegman, 2003). As well as reporting effective debridement, when divided into three age groups, the older patients (>80 years) had significantly lower mean rates of wound debridement (18.1%) than the mean rate found in those patients of <51 years (36%).

There have been numerous case reports of the benefits of HRWD in cleansing and debriding chronic wounds of a variety of aetiologies. Although limited in their generalisation to the wider population, a number of case studies illustrate wound cleansing properties of the dressing. Recently, Zollinger et al (2014) and Scherer et al (2015) describe a number of case reports on the use of HydroClean plus in cleansing venous leg ulcers, decubitus ulcers and arterial ulcers. Several are worthy of note. Zollinger et al (2014) report the case of a 60-year hospital patient discovered to have had a venous leg ulcer for 16 years. Upon presentation, the wound was completely covered by fibrinous slough. After 3 weeks of treatment, the devitalised wound tissue had softened and could be peeled off and by the 4th week fibrinous material has been completely removed and the next stage in the treatment regimen could be started. In a second case of venous leg ulcer, a 74-year old patient also presented with pyoderma gangrenosum and it was felt that surgical debridement was not a treatment option. Two days after treatment with HydroClean plus commenced, the fibrin slough covering the wound had softened and could be removed gently with a compress. In two cases where immobility resulted in the formation of decubitus ulcers on the heel, a 94-year old patient with a history of diabetes and another 94-year old patient whose ulcer resulted from immobility due to a fractured femur, showed good wound debridement after treatment with HydroClean plus was started (Zollinger et al, 2014). Scherer et al (2015) report a case study of a 73-year old patient who had been suffering with an arterial leg ulcer for 9 months, where a tendon was exposed. Treatment with HydroClean plus led to the softening of devitalised tissue and its removal from the wound. The clinicians reported the uptake of

bacterial contaminants into the wound dressing for easy removal. By the end of the observation period, HydroClean plus therapy resulted in significant wound progression of this previously-stagnant wound.

Figures 5 and 6 show illustrative clinical examples of wound debridement using HRWD and *Boxes 1–3* summarise clinical experience of using HydroClean plus for wound cleansing.

Bacterial sequestration and MMP modulation

In a study of 221 patients with chronic wounds of a variety of aetiologies by Kaspar et al (2008), the use of HRWD resulted in a reduction in the clinical signs of infection in a significant number of wounds studied (from 53% to 9%). Investigating the efficacy of HRWD in promoting wound cleansing and inducing new granulation tissue formation in patients with ulcers of varying aetiologies, 53% of the wounds showed clinical signs of infection at the start of the 4-week evaluation period. By the end of the observational period, treatment with HRWD resulted in a reduction in the number of wounds showing signs of infection to 9%.

In a subsequent observational study in 170 patients, with a variety of chronic wounds, the efficacy of HydroClean plus to influence the number of wounds showing clinical signs of infection was assessed (Kaspar, 2011). At the initial examination of the wounds, 24% of wounds exhibited clinical signs of infection that had reduced to 17% after an average of 8 days treatment. The high retention capacity for bacteria of the dressing together with the presence of PHMB in the wound dressing pad to kill retained bacteria, resulted in the decline in the infections during the course of the study.

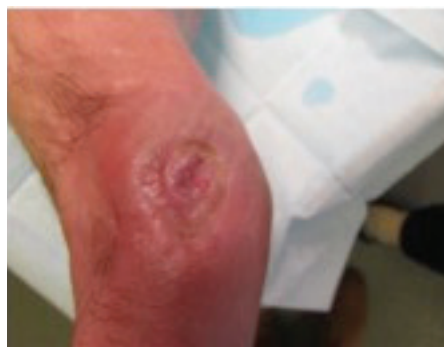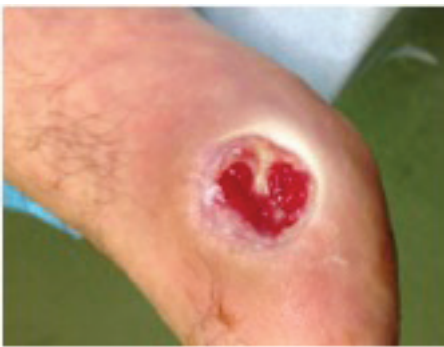In a previously described multi-centre prospective, observational study of 403 patients with a variety of chronic wounds, HRWD decrease the level of wound infections (HARTMANN, 2010). At the commencement of the observation period, 32% of wounds were affected by ‘moderate’ to ‘severe’ infections. Over the course of a 1 month treatment period where patients are treated with HRWD, only 4% of wounds exhibited ‘moderate’ or ‘severe’ infection levels.

Two case studies also describe the benefits of HRWD in cleansing infected wounds (Knestele, 2004). In a 50-year old diabetic patient with an infected diabetic foot ulcer on the right big toe,

Box 1. Case report of 51-year old male with non-healing foot ulcer treated with HydroClean plus

A 51-year old male patient, who had HIV for which he was being treated with retroviral therapy, developed a wound that had originated as a blister on the 1st metatarsophalangeal joint of his right foot 8 weeks previously. After treatment with a number of different wound dressings and three courses of antibiotics, the wound had failed to heal.

The wound was malodorous and, despite the wound being small (approximately 3.8 cm² in area), the wound was painful and was distressing for the patient. Upon presentation, the wound contained 30% slough and 70% granulation tissue, there was a moderate level of exudate production and the periwound skin showed signs of maceration. Upon application of HydroClean plus, the wound became pain-free and the wound odour was eliminated. The dressing was changed every 3 days and after 7 weeks the wound had progressed to healing.



after an initial surgical debridement, treatment was begun with a HRWD and wound cleansing was seen alongside the formation of new healthy-looking granulation tissue. Removal of tissue debris and bacterial contaminants promoted an optimal healing environment where healing of the wound was reported within 4 months. In a second case, a 57-year old patient underwent an amputation due to an ischaemia above the knee. After the operation, the wound deteriorated and there was the formation of large quantities of devitalised tissue and the foul-smelling wound produced large quantities of exudate. Tests revealed that the wound had become infected by *Staphylococcus aureus*. After 2 weeks of treatment with a HRWD, the devitalised tissue had been removed and newly formed granulation tissue was present. Wound cleansing removed the necrotic and sloughy material and sequestered any remnants of bacterial contamination (Knestele, 2004).

Managing wound exudate and protecting the wound edge

In the study from Kaspar et al (2008) examining the efficacy of HRWD on chronic wounds in 221 patients, wounds showing clinical infection reduced significantly over the course of the 1 month observation period. This reduction in infection was accompanied by a reduction of

wounds with high exudate levels from 74% to 10%. Clinical evaluation of the peri-lesional skin around the wounds reported reductions in a number of observed conditions including erythema (72% to 29%), maceration (28% to 8%), eczema (25% to 8%) and hyperkeratosis (11% to 5%).

Protection of the peri-lesional skin and management of wound exudate have been confirmed by a large study of 403 patients with chronic wounds (HARTMANN, 2010). In a prospective, multi-centre observational study of patients with wounds of varying aetiologies, 75% of the wounds had 'moderate' to 'severe' exudate levels. This level was reduced to 4% after 1 month treatment with HRWD and resulted in an improvement in a number of indicators of skin irritation. The proportion of wounds showing 'pathological symptoms' increased from 10% at the initial examination to 52% at the final examination. Within this period reporting of maceration decreased from 25% to 6%, tissue reddening reduced from 70% of patients to 26% of patients and eczema reduced from 21% to 6%.

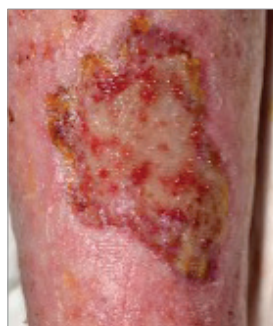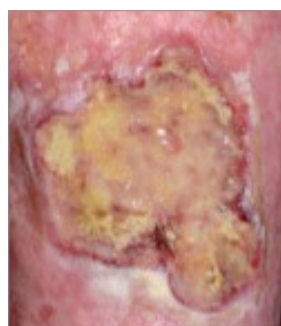
Kaspar (2011), reporting the results from a multi-centre observational study on the efficacy of HydroClean plus in the treatment of chronic wounds with a number of aetiologies, set out to assess the ability of HydroClean plus to protect

Declaration of interest
This paper was supported by HARTMANN LTD. The authors have provided consultative services to HARTMANN LTD.

Box 2. Case report of 69-year old male with mixed aetiology ulcer treated with HydroClean plus

A 69-year old male with diabetes and peripheral vascular disease developed a mixed aetiology leg ulcer on his left shin and had been present for 50 weeks. The patient was unable to tolerate reduced compression and the wound was treated topically with a hydrogel-impregnated dressing used under a light retention bandage in an attempt to reduce the slough present over the surface of the wound.

The wound measured 90 cm² and was extremely painful and malodorous, there was a moderate level of exudate production from the wound and the periwound skin was macerated. HydroClean plus was applied to the wound under a wool/crepe combination to secure the dressing and the periwound skin was



treated with a skin protectant. After 3 dressing changes the slough had been reduced by 60%, the exudate level reduced and the periwound skin appeared healthy. The wound size had reduced to 64 cm². The wound was no longer malodorous and the patient was sufficiently pain free as to allow further assessment and possible treatment with reduced compression therapy.

wound margins. At the start of the treatment, 71% of wounds had 'conspicuous' (irritated) surroundings and this was reduced to 62% of patients after the observation period. The high absorption capacity of the superabsorber contained in the wound dressing pad resulted in the evaluation of the absorption capacity and moisture retention capacity of HydroClean plus being rated as 'good' or 'very good' in 80% and 88%, respectively, of those questioned.

A clinical evaluation study of HydroClean plus treatment in 20 patients with wounds of a number of different aetiologies reported that over 50% of patients exhibited a reduction in the level of wound exudate between baseline and final assessment (mean, 15 days) (Spruce et al, 2016). There was an increase in the percentage of patients with healthy periwound skin from 25% to 55% over the course of the evaluation. The percentage of patients with wound margin skin inflammation reduced from 25% to 5% over the same period. When questioned, 96% of clinicians were satisfied with the way HydroClean plus managed wound exudate.

The clinical benefits of HRWD in managing wound exudate and protecting the wound edge were also observed in a number of case reports. Knestele (2004) reported the case of a 51-year old patient with deep dermal burns. The HRWD managed the excessive levels of wound exudate produced. In the

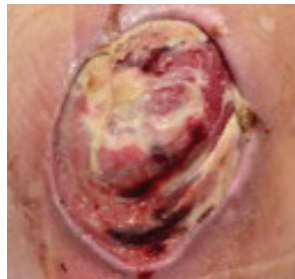
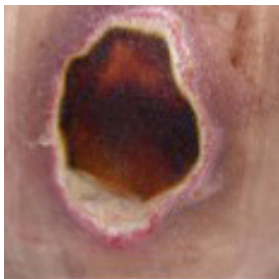case of an 83-year old patient who had undergone a laparotomy which led to the production of large quantities of foul-smelling exudate when the wound site dehiscid, the application of a HRWD controlled the wound exudate produced and facilitated wound progression. In a second case report of a patient with a dehiscid surgical abdominal wound (Parker, 2014), the use of a HRWD in the 84-year old patient maintained the periwound skin in a healthy condition, minimising complication such as wound margin maceration. In a third case, Meuleneire (2011) describes the care of a patient who presented with a trauma-induced leg ulcer. Upon inspection, the wound bed was covered in a yellow fibrinous slough and the wound margins were inflamed. Wound margin skin improvement was noted within 3 days of starting treatment with hydro-responsive wound dressing with the periwound skin becoming less inflamed and less macerated.

IMPACT ON QUALITY OF LIFE

In an observational study of 37 patients with venous leg ulcers, Scholz et al (1999), patients were questioned about the presence of wound pain and the painfulness of dressing changes as part of the HRWD evaluation assessment. In response to these questions, 14 patients said that they had experienced no pain at dressing changes, 19 patients reported

Box 3. Case report of 86-year-old male with pressure ulcer treated with HydroClean plus

An 86-year old male who had become immobile following a cerebrovascular accident developed a pressure ulcer on his hip which had been present for 4 weeks. The patient complained of pain. Previous treatment of the wound included use of a hydrogel and adhesive foam dressing but were ineffective at debriding the wound. The wound measured 120 cm² and was covered in black eschar. There was minimal wound exudate but the wound was malodorous. HydroClean plus was applied to the wound using an adhesive foam dressing to secure and protect the wound from contamination from incontinence. HydroClean plus was changed every 3 days and after the first dressing change minimal necrotic tissue was visible with the underlying wound bed containing large areas of slough.



After a further week of treatment, the wound was improving with evidence of a reduction in sloughy material and a corresponding increase in granulation tissue present. The patient reported a reduction in pain experienced and the wound was no longer malodorous.

'slight' pain, and 4 patients 'severe' pain.

In a group of 221 chronic wounds patients receiving treatment with HRWD, an improvement in wound pain perception at the end of the observation period compared with that experienced at the beginning was reported. Pain reporting for 'intermediate' to 'high' pain perception decreased from 64% to 19% of patients over the course of 4 weeks (Kaspar et al, 2008).

In a previously described multi-centre prospective, observational study of 403 patients with a variety of chronic wounds, HRWD had a significant impact on quality of life (HARTMANN, 2010). During the course of treatment by HRWD in chronic wounds of varying aetiologies, whereas more than half of the patients (69%) reported 'mild' or 'severe' wound pain at the start, this proportion reduced to 13% at the end of the treatment. More than 90% of physicians evaluated HRWD as 'good' or 'very good' and this proportion increased when patients were asked to rate the dressing. More than 90% of patients questioned found the product to be 'good' or 'very good' on wearing and tolerability and 89% rated the product 'good' or 'very good' when questioned about improvements in pain perception during dressing changes. Overall, 94% of patients rated the dressing overall as 'good' or 'very good'.

In this study, 35% of patients reported suffering from 'moderate' to 'severe' wound pain. By the conclusion of the observation period, this proportion had decreased to 19% when treated with HydroClean

plus. The proportion of patients suffering 'moderate' to 'severe' pain during dressing changes decreased from 28% at the start to 11% at the end of treatment (Kaspar, 2011). The positive findings in relation to the reduction in pain experienced at dressing change, may be reflected in the atraumatic nature of the dressing. An evaluation by the treating clinicians rated the removability and skin compatibility of HydroClean plus as 'good' or 'very good' in 96% and 86%, respectively. Eighty-seven percent and 83% of patients questioned found the dressing was 'good' or 'very good' on wearing comfort and that 62% of the patients found their expectations 'fulfilled', with 15% expressing an opinion that the dressing 'exceeded' their expectations.

In a 20-patient clinical evaluation (Spruce et al, 2016), HydroClean plus was applied to wounds of different aetiologies in the community setting. At the start of the evaluation period 95% ($n=19$) of patients experienced some degree of wound pain and this value reduced to only 35% ($n=7$) (a reduction of 58%). The mean pain score was ranked as 2.5 and this reduced to 1.0 by the end of the evaluation. The number of patients taking analgesia reduced from 9 to 4. The experience of patients and clinicians during the application, removal and wear of the dressings was very positive. Ninety-five percent ($n=92$) of dressing changes were noted as easy. Patients reported that the dressing was comfortable to wear at 99% of dressing changes, there were no reports of the dressing moving out of place from the

wounds and the dressing was easy to remove in 100% of dressing changes. No patients reported pain on dressing removal. Both clinicians and patients were satisfied with the dressing performance.

Several case report studies repeatedly confirm the findings found in multi-patient clinical studies of the benefits of HRWD in the quality of life of patients (Azevedo, 2004; Meuleneire, 2011, 2013; Zollinger et al, 2014; Scherer, 2015).

CONCLUSION

The presence of devitalised tissue on a wound bed is a significant physical barrier to the progression of chronic wounds. Wound bed necrosis and fibrinous slough are known as sites for the accumulation of bacterial populations due to the isolation of these populations from the patient's own immune defences. The release of bacterial toxins from these areas of devitalised tissue can contribute significantly to the damaging environment of the wound bed and may also delay healing.

The ability of a wound dressing to promote the autolytic debridement of devitalised tissues and facilitate their removal from the wound would be a significant step forward in providing the tools for wound care clinicians to aid healing.

HydroClean plus provides both autolytic debridement, together with rinsing and absorbing the wound environment, thus necrotic tissue and fibrinous slough coatings are removed from the wound bed. The existing evidence from clinical trials and numerous case reports support this novel class of hydro-responsive wound dressing's role as an effective method for promoting autolytic debridement, wound cleansing and wound progression which leads to healing. Although further studies are needed, particularly those of a comparative design, initial results are very promising.

From the evidence currently available, HydroClean plus provides significant benefits for the management of chronic and acute wounds of different aetiologies.



REFERENCES

Azevedo M, Simoes L, Sousa R, Sampaio R (2004) *Viabilidade Tecidual em Queimados: Optimizatao do Processo Autolftico com a Utilizatao do Penso de Poliacrilato Superabsorvente Saturado com Solutao de Ringer*. Available at: <http://bit.ly/1QtmLmW> (accessed 11.02.2016)

Bishop SM, Walker M, Rogers AA, Chen WYJ (2003) Importance of moisture balance at the wound-dressing interface. *J Wound Care* 12(4):125–8

Bruggisser R (2005) Bacterial and fungal absorption properties of a hydrogel dressing with a superabsorbent polymer core. *J Wound Care* 14(9):438–42

Buchholz F, Graham A (1998) *Modern Superabsorbent Polymer Technology*. John Wiley and Sons, New York

Eming S, Smola H, Hartmann B et al (2008) The inhibition of matrix metalloproteinase activity in chronic wounds by a polyacrylate superabsorber. *Biomaterials* 29(19):2932–40

Gilliver S (2009) PHMB: a well-tolerated antiseptic with no reported toxic effects. *J Wound Care Supplement*:9–14

HARTMANN (2010) *Effective Wound Cleansing with TenderWet Active – Observational Study with 403 patients*. Available at: <http://bit.ly/1RswlLY> (accessed 11.02.2016)

Humbert P, Faivre B, Véran Y et al (2014) Protease-Modulating Polyacrylate-Based Hydrogel Stimulates Wound Bed Preparation in Venous Leg Ulcers - a Randomized Controlled Trial. *J Eur Acad Dermatol Venereol* 28(12):1742–50

Kaspar D, Dehiri H, Tholon N et al (2008) Efficacité clinique du pansement irrigo-absorbant HydroClean active contenant du polyacrylate superabsorbant dans le traitement des plaies chroniques – étude observationnelle conduite sur 221 patients. *J Plaies Cicatrisations* 13(63):21–4

Kaspar D (2011) TenderWet plus. Therapeutic effectiveness, compatibility and handling in the daily routine of hospitals or physician's practices. Published by HARTMANN

Knestele M (2004) The treatment of problematic wounds with TenderWet – tried and tested over many years in clinical practice. *WundForum*. Special Issue: 3

König M, Vanscheidt W, Augustin M, Kapp H (2005) Enzymatic versus autolytic debridement of chronic leg ulcers: a prospective randomised trial. *J Wound Care* 14(7):320–3

Kirshen C, Woo K, Ayello EA, Sibbald RG (2006) Debridement: a vital component of wound bed preparation. *Adv Skin Wound Care* 19(9):506–17

Marazzi M, Stefani A, Chiaratti A et al (2006) Effect of enzymatic debridement with collagenase on acute and chronic hard-to-heal wounds. *J Wound Care* 15(5):222–7

Meuleneire F (2011) Clinical evaluation of TenderWet plus. Published by HARTMANN

Meuleneire F (2013) TenderWet plus in the treatment of patients with problem wounds. Published by HARTMANN

Milne J (2015) Wound-bed preparation: the importance of rapid and effective desloughing to promote healing. *Br J Nurs* 24(Suppl.20):S52–8

Mwipatayi BP, Angel D, Dixon P et al (2005) Clinical experiences with activated polyacrylate dressings (TenderWet 24). *Primary Intention* 13(2):69–74

Ousey K, McIntosh C (2010) Understanding wound bed preparation and wound debridement. *Br J Community Nurs* 15(3):S22, S24, S26, passim

Parker B (2014) Rapid healing in a dehiscd abdominal surgical wound using hydro-active dressings. Australian Wound Management Association. *Connective Issue* 16(4): 11–4

Paustian C, Stegman MR (2003) Preparing the wound for healing: the effect of activated polyacrylate dressing on debridement. *Ostomy Wound Manage* 49(9):34–42

Rippon M, White R, Davies P (2007) Skin adhesives and their role in wound dressings. *Wounds UK* 3(4):76–89

Rippon M, Davies P, White R (2012) Taking the trauma out of wound care: the importance of undisturbed healing. *J Wound Care* 21(8):359–60, 362, 364–8

Rogers AA, Rippon M, Davies P (2013) Does “micro-trauma” of tissue play a role in adhesive dressing-initiated tissue damage? *Wounds UK* 9(4):128–134

Scherer R, Kägi M, Geiges R et al (2015) HydroTherapy. Application study. Published by HARTMANN

Scholz S, Rompel R, Petres J (1999) A new approach to wet therapy of chronic leg ulcers. *Arzt Praxis* 53(816):517–22

Schultz G, Sibbald G, Falanga V et al (2003) Wound bed preparation: a systematic approach to wound management. *Wound Rep Regen* 11(Suppl. 1):1–28

Sibbald RG, Coutts P, Woo KY (2011) Reduction in bacterial burden and pain in chronic wounds using a new polyhexamethylene biguanide antimicrobial foam dressing – clinical trial results. *Adv Skin Wound Care* 24(2):78–84

Sibbald RG, Elliott JA, Ayello EA, Somayaji R (2015) Optimizing the moisture management tightrope with Wound Bed Preparation 2015. *Adv Skin Wound Care* 28(10):466–76

Spruce P, Bullough L, Johnson S, O'Brien D (2016) Benefits of HydroClean Plus in wound bed preparation: a case study series. *Wounds International* 7(1):26–32

Strohal R, Dissemond J, Jordan O'Brien J et al (2013) EWMA document: debridement. *J Wound Care* 22(Suppl 1):S1–52

Wolcott RD, Rumbaugh KP, James G et al (2010) Biofilm maturity studies indicate sharp debridement opens a time-dependent therapeutic window. *J Wound Care* 19(8):320–8

Zollinger C, Schwab R, Locherer E et al (2014) HydroTherapy. Application study. Published by HARTMANN