

Topical oxygen-haemoglobin use on sloughy wounds: positive patient outcomes and the promotion of self-care

KEY WORDS

- ▶ Haemoglobin spray
- ▶ Healing, slow healing and non-healing wounds
- ▶ Self-care
- ▶ Slough
- ▶ Topical oxygenation

Sloughy wounds are challenging because they are time consuming to manage, often require specialist input for slough removal, and have a significant effect on quality of life. **Method:** A descriptive evaluation was undertaken within a community setting, exploring 100 patients who presented with sloughy wounds and the effects of twice-weekly, topically administered haemoglobin therapy over a 4-week period. Normal standard wound cleansing and dressing regimens were continued, with wound care being provided by the cohort group independently or with supervision and support from a designated carer. Data were collected weekly in relation to primary outcomes of slough reduction, wound surface area reduction, patient ease of self-care use, and overall product experience. **Results:** At 4 weeks, all wounds had demonstrated positive measured endpoints of slough elimination (100%) and continued wound size reduction (99%), with 100% of patients and carers finding the product easy to use and having an overall positive wound care experience. **Conclusion:** The administration of a haemoglobin spray solution in patients presenting with sloughy wounds resulted in slough elimination and wound reduction, along with positive self-care and product satisfaction.

The concept of self-care is becoming more prominent as a productive way to support patients with their lifestyle choices, healthcare needs and managing wounds, particularly within the community setting (Bateman 2015a). It is invaluable to explore new avenues of wound healing to ensure that the right care is provided for the right patient at the right time, making best use of limited resources and ensuring patients are involved from the outset in their care (While, 2015). NHS England (2014) states that consistency, continuity and patient ownership is paramount if resources and outcomes are to be satisfactorily achieved. The development of therapies that are simple to use, promoting self-care and reducing the reliance on clinical teams, is the way forward (Bateman, 2015a; Dowsett, 2015).

Of course, self-care is not appropriate for all patients, and this needs to be investigated during the holistic assessment, which should examine the patient and their support network and obtain the patient's consent to take ownership of their care.

SLOUGH

Slough is a combination of dead white cells, dead bacteria, rehydrated necrotic tissue and fibrous tissue (Bateman, 2015b). It often presents as a creamy yellow tissue, and can be wet or dry (Young, 2015). Sloughy tissue has a supple texture, fibrous in consistency. It quickly affixes to the wound bed and may not be easily removed through normal cleansing (Tong, 1999; Vuolo, 2009).

Slough is part of the healing process and the presence of sloughy matter within the wound bed is not necessarily a sign that the wound is not healthy and healing. Rather, slough is an indicator that the body is removing devitalised tissue and waste, allowing granulation to occur (Flanagan 1977; 1992). However, when slough attaches to the granular base, it provides an optimum environment for bacterial growth, infection and increased exudate, which may lead to stalled healing and increased maceration to the periwound area (Cutting, 2004; Martin, 2013). Given the right environment, slough

SHARON DAWN HUNT
Nurse Practitioner, Independent
Specialist in Tissue Viability
South Tees NHS Hospitals
Foundation Trust

will be autolysed naturally as the inflammatory stage evolves (Young, 2015). It has been suggested that chronic wounds trapped in the inflammatory phase of healing have an increased incidence of slough formation, often relating to increased levels of exudate (Gardiner, 2012).

The extent of slough formation is determined by the stage of healing, the wound type, whether the wound is acute or chronic, and the way in which the wound is managed.

OXYGENATION AND WOUND HEALING

Wounds cannot progress to full healing without adequate oxygenation (Chadwick et al, 2015). Oxygen delivery and uptake is important within the key wound healing phases (Flanagan, 2000; Norris, 2014). The human body cannot store oxygen so tissue regeneration requires a steady supply to the cells (Timmons, 2006; Chadwick et al, 2015). Without oxygen, developing tissue cells can become inert and dysfunctional, leading to the wound becoming static, necrotic and sloughy (Flanagan, 2000; Dow, 2001). Chronic or non-healing wounds are more likely to have some elements of hypoxia, and hypoxic tissue often fails to progress to full closure healing (Hauser, 1987).

Topical delivery of oxygen direct to the wound bed through solution mediums or hyperbaric pressure is beneficial to wound healing (Ladizinsky and Roe, 2010; Norris, 2014; Winfeld, 2014; Bateman 2015a; 2015b; Tickle, 2015). Topical oxygen therapy allows haemoglobin-mediated oxygen diffusion within the wound bed through an aqueous solution which aids the wound healing process through an increased uptake of oxygen (Arenbergerova et al, 2013; Babadagi-Hardt et al, 2014).

GRANULOX®

Granulox (Infirst Healthcare) is a topical spray containing an oxygen-haemoglobin medium derived from sterile porcine (pig's) blood, which is recommended for wounds categorised as slow healing or non-healing. It acts by aiding oxygen diffusion into the wound bed tissues. A number of authors have highlighted the benefits of wound tissue oxygenation through diffusion using topical haemoglobin therapy (Green and Mohamud, 2014; Norris, 2014; Bateman 2015a; 2015b; Tickle, 2015).

Granulox requires little education to use, has no

reported negative side-effects, and has been used by clinicians, patients and carers with no adverse events (Bateman 2015a; 2015b; Tickle, 2015). Within the evaluations undertaken and at patient focus group discussions, there has been no objection to its application for religious, cultural or dietary reasons.

Granulox is approved for use as a non-wound contact spray, to be applied at least every 72 hours on chronic wounds (Arenbergerova et al, 2013). The optimum application rates and long-term benefits are not yet evidenced (Chadwick et al, 2015). Granulox is not recommended for use with certain disinfectants, proteolysis or mechanical debridement because these may impair its benefits. It is to be avoided on tissue where diagnosed infection is present, and in pregnant or breastfeeding women. Wounds should be clean, with no devitalised tissue present, before product application. The product requires a cool storage temperature (2–8°C). It must be emphasised that Granulox is not to be used as a replacement or a delaying tactic when specialist referral is required (Chadwick et al, 2015).

EVIDENCE

Several authors have shown the positive outcomes of increased healing, wound reduction and no adverse reactions using Granulox. The studies covered a range of wounds, including common chronic wounds (Arenberger et al, 2011), leg ulcers (Arenbergerova et al, 2013; Norris, 2014), chronic wounds/compression and Budd-Chiari syndrome (Babadagi-Hardt et al (2014) and pressure ulcers (Tickle, 2015). Recent evaluations carried out on diabetic foot ulcers and sloughy wounds additionally demonstrated slough reduction, pain reduction, positive patient education, wound care experience and the promotion of patient/carer self-care (Bateman, 2015a; 2015b).

An expert wound care working group has developed consensus recommendations on the management of slow and non-healing wounds with topical haemoglobin spray (Chadwick et al, 2015). The group acknowledges the use of topical haemoglobin treatments in wounds which have failed to respond within 2 to 4 weeks of normal care, and also moves away from the traditional concept of acute or chronic wounds, instead classifying wounds as healing, slow healing or non-healing.

Table 1. Inclusion and exclusion criteria.

Inclusion criteria	Exclusion criteria
<ul style="list-style-type: none"> » Healing, slow-healing and non-healing wound with slough. » Non infected wound. » Not administered antibiotic therapy. » Patient/carer verbal consent for 4 weeks of Granulox therapy in clinic and home setting. » Patient/carer able to use Granulox spray device. 	<ul style="list-style-type: none"> » Diagnosis of infected wound. » Antibiotic therapy administered. » Patient/carer declined verbal consent. » Patient/carer unable to use Granulox spray device.

AIM

This study aimed to explore the use of Granulox in 100 patients who presented with sloughy wounds at a general practice or walk-in centre and who were able to self-manage their wounds at home.

Assessing the products’ benefits on sloughy wounds may suggest a contraindication to the product recommendations because some levels of slough could be classed as infected and some wounds as healing as expected. The conservative care which was in place prior to the evaluation commencing was maintained for all patients. They were deemed at low risk of infection and were not taking systemic antibiotics.

The primary outcomes were: slough reduction, wound surface area reduction, patient ease of self-care use, and overall product experience. All patients were supported by an expert clinician in wound care on a weekly basis.

Table 2. Wound status criteria

Wound status	Criteria	Patients
Healing	>40% wound reduction in 4 weeks pre evaluation	61%
Slow healing	5%–40% wound reduction in 4 weeks pre evaluation	29%
Non-healing	<5% or static wound reduction wound reduction in 4 weeks pre evaluation	10%

METHODS

All patients who met the inclusion criteria in *Table 1* had Granulox applied to the wound bed twice weekly over a 4-week period alongside their normal cleansing and dressing regimen. As per Chadwick et al (2015), wounds were assessed as healing, slow-healing or non-healing (*Table 2*). All patients were followed up for a further 5 weeks.

Wound care before entering into the study included soft silicone foams (adhesive/non adhesive) hydrofiber adhesive foams, compression therapy and retention bandages, with 29% of wounds managed by self-care and/or carers and 71% being solely managed by clinicians twice a week. Wound data were collated on designated evaluation forms using the Applied Wound Management assessment (Gray et al 2005), which is the standard wound care documentation used within the Trust. Data collection sets included: slough percentage, wound size, consistency of standards/dressing regimen, and amount of granulation and epithelium present. The author carried out weekly observations at clinic dressing change and cross-checked all data for accuracy alongside reporting the patient/carer experience.

At weeks 1 and 3, each patient and/or carer was asked set questions about the acceptability/ease of use of the product (1= very difficult and 5= extremely easy), and overall product experience (1= poor and 4= excellent).

Patient demographics and wound types are shown in *Table 3*. Sloughy material present at recruitment ranged from 10% to 100%. The length of time for wounds *in situ* prior to the study ranged from 1 to 72 weeks (mean 16 weeks).

Ethical approval was not required, as is Trust policy in regards to clinical review of CE marked products. Informed consent was documented in relevant notes.

RESULTS

As shown in *Figure 4*, slough levels reduced to 0% by week 1 for 23% of patients (*n*=23; two Granulox applications). Slough continued to reduce, with 54% (*n*=54) of patients being slough free at week 2 (four applications), 96% at week 4 (*n*=96; eight applications) and the complete cohort being slough free cohort at week 5 (10 applications). These figures correlate with previous evaluations

(Bateman 2015a; 2015b), where all patients were deemed slough free in these time periods.

Wound reduction was achieved in all patients (Figure 5), with 80% (n=80) reaching complete healing within the 10-week treatment and follow-up period, with large peaks at week 3 (n=20) at week 3 and week 6 (n=17), replicating the peak healing rates in previous evaluations (Bateman 2015a; 2015b).

Of those patients who did not heal within the evaluation time frame, three underwent successful interventional surgery and 17 had wounds which slowly continued to reduce in size. Table 6 shows the patients who did not heal in regards to their wound status criteria at study onset. It is interesting to note that Granulox had a positive outcome on healing rates in all groups, with the least impact on non-healing wounds. Three (3%) of those non-healing wounds are the patients who underwent interventional surgery.

The wounds that healed within the treatment and follow-up period demonstrated no commonalities with the patient demographics, wound types and secondary dressings. There was no relapse or slough development in the treatment period and follow-up period and no patients were documented as receiving antibiotic therapies. Effects over a period of time beyond 10 weeks are not evidenced within available literature.

Patient and clinician satisfaction

The majority of patients (n=93) were able to apply the Granulox therapy independently at both the clinic review appointment and within their own living environments, with the remainder requiring assistance from a parent or carer, either because they had musculoskeletal or disability issues, or were young children. All the cohort was self-managed, with only verbal, educational and observational support from the wound care expert leading the clinic appointments and data collection.

When asked: ‘How easy is the product to use?’, patients replied it was extremely easy (n=78) or very easy (n=22). Each patient received a short demonstration of use at the first dressing application and was supervised by the clinician at weekly appointments thereafter. This level of satisfaction replicates previous experiences with Granulox (Bateman 2015a; 2015b), emphasising the ease with which patients can administer this therapy with minimal or no supervision.

Table 3. Patient demographics at the beginning of the evaluation.

Patients (n=100)	Number	% or mean
Gender	Male Female	n=49 n=51
Age (years)	male = 5–81 female= 5–90	male = 48 female= 52
Wound duration (weeks)	1–72	mean = 16
Wound type	Venous ulcer Arterial ulcer Skin tear Burn Intravenous drug abuse Surgical Abscess Shingles Insect bite wound Trauma *	n=12 (12%) n=2 (2%) n=10 (10%) n=9 (9%) n=7 (7%) n=7 (7%) n=12 (12%) n=2 (2%) n=9 (9%) n=30 (30%)
Wound size	Length Width Depth	1–18 cm mean = 12 cm 1–12 cm mean = 8cm 0.2–4 cm mean = 1.2cm
Slough range %	10–100%	mean = 65%
Self-care pre-therapy	n=29	29%
Assisted care pre-therapy	n=71	71%

* Trauma relates to wounds from falls, gun shot, knife attack, self-harm and road traffic accident

When asked: ‘What has been your overall experience with this product and your wound healing?’, 79% (n=79) replied excellent and 21% (n=21) good. Again, this concurs with previous studies (Bateman, 2015a; 2015b). All patients/carers found the product education and instruction leaflet informative and helpful, particularly when independently using the product at home. They were all willing to continue with the product throughout the 4-week evaluation period and for longer if their wound required it.

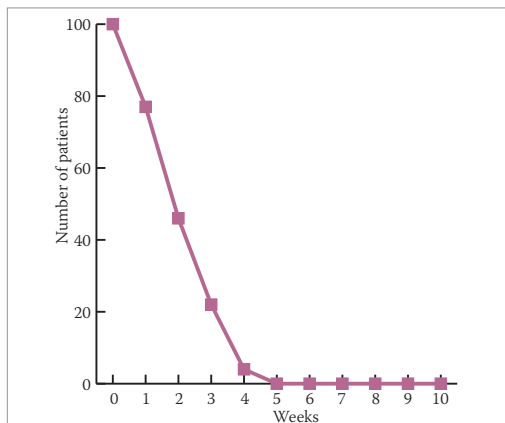


Figure 4. Slough reduction

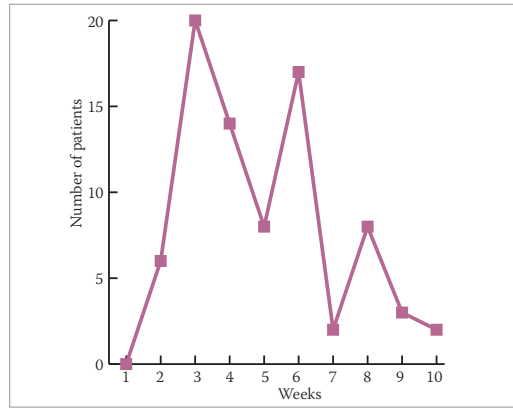


Figure 5. Wound closure

Adverse events

On presentation, all the wounds within the evaluation had levels of slough ranging from 10% to 100%. This was cleansed with normal cleansing regimens and no debridement. There were no reports of adverse events. None of the patients reported any irritation or skin reactions to the product. There were no declines of consent because of cultural, religious or dietary preferences.

DISCUSSION

This small but unique evaluation explored the use of Granulox haemoglobin spray for patients who presented with sloughy wounds at a community walk-in centre. All 100 patients demonstrated slough elimination by week 5, alongside progressive wound healing and reduction.

The wound healing results of this study mirror the work of Arenberger et al (2011) and Arenbergerova et al (2013), who found healing rates of 93% vs 7% at 6 months on standard care and 53% vs 21% respectively within leg ulcers. Evaluations carried out by Norris (2014) on venous leg ulcers and Tickle (2015) on pressure ulcers also demonstrated positively conforming results in wound size reduction and exudate minimisation with the use of topical haemoglobin spray.

Table 6. Patients who did not heal during evaluation

Wound status	% of patients pre-Granulox	% of patients post-Granulox
Healing	61%	5%
Slow healing	29%	6%
Non-healing	10%	9%

Most recently, Bateman’s (2015a; 2015b) work on non-healing diabetic foot ulceration and sloughy wounds evaluated further benefits of Granulox therapy, suggesting that slough reduction was a significant factor as a non-set outcome.

The results of this evaluation additionally support and emphasise the vital concept of patient self-care and how clinicians can encourage patients to self-manage and take active roles within their wound care regimens. The education card and minimal support the patients received was very positive in the data outcomes, with all patients happy to continue with their own self care and be monitored weekly. This reduced nursing dressing time by 50% and gave empowerment and control to the patient/carer – interesting outcomes which need further exploration.

Limitations of evaluation

The cohort group represented a moderate sample of patients who presented with sloughy wounds. Although clear benefits of a 4-week Granulox treatment and 5-week follow-up has been demonstrated, the product’s effects over a longer period of time with increased applications has not been examined and thus the full benefits are not known.

Although one could argue that the clinician’s measurement of slough within the wounds was subjective, as it was observational, it was clear that at week 5 all wounds were slough free. The evaluation included patients of a wide age range and various typical sloughy wound groups. Positive patient ease of use and overall experience has enriched and strengthened positive outcomes. There were no patient drop-outs, and data were collected and cross-checked by the author. This evaluation data expands upon the increasing positive outcomes within current available literature for the use of topical haemoglobin spray within the community setting.

CONCLUSION

Sloughy wounds will continue to be a challenge, particularly in the current healthcare climate where best effective care provision alongside tight financial constraints is the norm. Wound care experts can support patients to take responsibility for their own health needs and carry out their own dressing regimens. This will clearly have an impact on how

services are restructured while continuing to meet today's holistic patient needs (While, 2015).

The management of sloughy wounds requires timely assessment, management, evaluation and review, with specialist referral when standard conservative management is not aiding the wound healing process. The use of innovative products such as haemoglobin therapy alongside robust patient and carer education and self-involvement in care are vital in ensuring that care is appropriate, consistent, beneficial and cost effective.

This moderate evaluation has used Granulox in an area only briefly explored to date, and has successfully demonstrated positive and effective outcomes alongside a positive experience for patients involved with and directing their own self-care. Further work is required to demonstrate this product's benefits from procurement and cost analysis perspectives if clinicians are to successfully submit requests for its wider use and FP10/supply chain formulary inclusion. **WUK**

REFERENCES

Arenberger P, Engels P, Arenbergerova M et al (2011) Clinical results of the application of a haemoglobin spray to promote healing of chronic wounds. *GMS Krankenhhyg Interdisziplinär* 6(1):Doc05

Arenbergerova M, Engels P, Gkalpakiotis S et al (2013) Effect of topical haemoglobin on venous leg ulcer healing. *EWMAJ* 13(2):25–30

Babadagi-Hardt, Engels P, Kanya S (2014) Wound management with compression therapy and topical haemoglobin solution in a patient with Budd-Chiari syndrome. *J Dermatol Case Rep* 8(1):20–3

Bateman S (2015a) Use of topical haemoglobin on sloughy wounds in the community setting. *Br J Community Nurs* 20(Suppl 9):S32–9

Bateman S (2015a) Topical haemoglobin spray for diabetic foot ulceration. *Br J Nurs* 24(12):S24–9

Bateman S (2015c) Presentation at Wound Expo, Liverpool, October

Chadwick P, McCardle J, Mohamud L et al (2015) Appropriate use of topical haemoglobin in chronic wound management: consensus recommendations. *Wounds UK EWMA Special*:30–5

Cutting KF (2004) Exudate: composition and functions. In: White RJ (ed). *Trends in Wound Care*. Quay Books

Dow G (2001) Infection in chronic wounds. In: Krasner DL, Rodeheaver GT (eds), *Chronic Wound Care*. 3rd ed. HMP Communications, Wayne (PA). pp385–6

Dowsett C (2015) Breaking the cycle of hard to heal wounds: balancing cost and care. *Wounds International* 6(2):17–21

Flanagan M (1992) Wound Care Society Wound Assessment Leaflet. Wound Care Society, Northampton

Flanagan M (1997) Wound healing and management. *Primary Health Care* 7(4):31–9

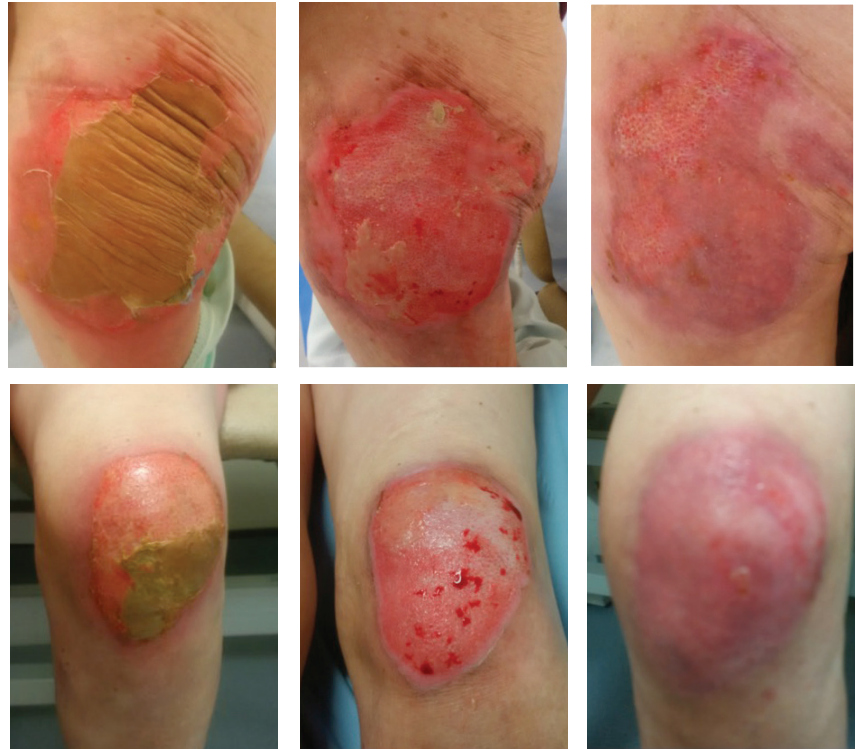Flanagan M (2000) The physiology of wound healing. *J Wound Care* 9(6):287

Gardiner S (2012) Managing high exudate wounds. How to guide. *Wound Essentials*. Available at: http://www.wounds-uk.com/pdf/content_10474.pdf (accessed 05.10.15)

Gray D, White R, Cooper P et al (2005) Understanding applied wound management. *Wounds UK* 1(1):62–8

Green M, Mohamud L (2014) Use of Granulox haemoglobin spray in clinical practice: case report series. *J Community Nurs* (Supp):S1–8

Hauser CJ (1987) Tissue salvage by mapping of skin surface transcutaneous oxygen tension index. *Arch Surg* 122(10):1128–30



Case study. A female patient, aged 87, hypertensive, stable type 2 diabetes, attended the walk-in centre with 10-day-old burns to left hip, thigh and patella from accidentally pouring scalding hot water over herself. She is independent, self-cares at home and has a good strong family support when required. She had been caring for these wounds herself before her daughter found out and brought her to the walk-in centre. Wounds continued to be dressed with adhesive silicone foam dressing. She was discharged from care at week 10. **Top (left to right): hip on day 0; week 1 (two applications of Granulox); week 10 (10 applications of Granulox).** **Bottom (left to right): Patella, day 0; week 1 and week 10.**

Kingsley A (2001) A proactive approach to wound infection. *Nurs Stand* 15(30):50–8

Ladizinsky D, Roe D (2010) New insights into oxygen therapy for wound healing. *Wounds* 22(12):294–300

Martin M (2013) Physiology of wound healing. In Flanagan M (ed). *Wound Healing and Skin Integrity*. Wiley-Blackwell, West Sussex.

NHS England (2014) The Forward View into action: planning for 2015/16. Available at: <http://www.england.nhs.uk/ourwork/forward-view/> (accessed 03.10.15)

Norris R (2014) A topical haemoglobin spray for oxygenating chronic venous leg ulcers: a pilot study. *Br J Nurs* 23(Suppl 20):S48–53

Tickle J (2015) A topical haemoglobin spray for oxygenating pressure ulcers: a pilot study. *Br J Community Nurs* S12–18

Timmons J (2006) 'Third line therapies'. *Wounds UK e-newsletter*, July

Tong A (1999) The identification and treatment of slough. *J Wound Care* 8(7):442–52

Vuolo J (2009) *Woundcare Made Incredibly Easy*. Lippincott, Williams and Wilkins, London

While A (2015) Rising health-care costs within limited resources. *Br J Community Nurs* 20(6):310

Winfield B (2014) Topical oxygen and hyperbaric oxygen therapy use and healing rates in diabetic foot ulcers. *Wounds* 26(5):E39–47. Available at: <http://bit.ly/1V5qu0C> (accessed 03.10.15)

Young T (2015) Accurate assessment of different wound tissue types. *Wounds Essentials* 10(1):51–4

Declaration of interest
All products for the evaluation were provided by Infirst Healthcare, which had no control over or involvement within this data or any previous data collections, analysis or article submissions.