

# DESCRIBING A WOUND: FROM PRESENTATION TO HEALING

Being able to identify the tissue types within a wound is an essential skill when caring for wounds, because it informs understanding of the stage of wound healing and selection of safe and appropriate dressing products. Incorrect identification can have serious consequences, or simply lead to ineffective treatment and prolonged healing. Understanding and using wound healing terminologies correctly is therefore very important.

*“An accurate description reflects a careful, thorough wound assessment.”*

Nurses and other healthcare professionals can occasionally struggle to describe a wound, either because they do not know the correct terminology to use or are unsure of what they are seeing when they look at a wound. This article aims to explain the main wound tissue types, how they can be accurately identified, and what they represent in terms of the stages of healing. Appropriate treatment goals for each tissue type will be mentioned. Reasons for the importance of an accurate description of tissue type will be discussed, and examples of some common misidentifications will be provided.

Why is the description important? Accurate use of terminology helps provide consistency in assessment and reassessment, which is essential when different nurses are caring for the same wound. It ensures everyone interprets what they see uniformly. It is important when reassessing a wound to identify whether the wound is progressing as expected or to spot abnormal changes early. Incorrect use of terminology can lead to mismanagement or misidentification of important changes. For example,

tendon could be mistaken for slough or skin carcinoma for overgranulation. An accurate description reflects a careful, thorough wound assessment. Subtle changes are noticed and appropriate interventions can be made. Accurately identifying tissue type will help identify the stage of healing the wound is at (Russell, 1999). Knowing the physiological processes taking place in the wound will help the clinician to identify suitable treatment goals and dressing products. It will also assist in understanding appropriate timescales for healing and prevent impatience and frequent changes of dressing products.

## **Necrotic tissue**

The word comes from the Greek *nekros*, meaning “corpse”. It refers to dead tissue, usually caused by interruption to the blood supply to tissue and cells, resulting in local ischaemia and tissue death. It is also referred to as devitalised tissue, meaning ‘without life’.

The presence of necrotic tissue in a wound will delay healing and predispose it to infection because it acts as a source of nutrients for bacteria (Leaper, 2002). Necrotic tissue needs expedient removal to

facilitate healing. It may also mask deeper damage beneath, which explains why a wound will sometimes appear larger once necrotic tissue has been removed (Gray et al, 2011).

Necrotic tissue appears black/brown in colour and can be hard, dry and leathery, or soft and wet in texture and either firmly or loosely attached to the wound bed (Figure 1).

Removal of necrotic tissue is known as debridement. Separation of necrotic tissue from healthy tissue occurs naturally to some extent in all wounds and is known as autolytic debridement. The body's natural processes break down dead tissue by liquefying it through the action of proteolytic enzymes in the wound exudate (Schultz et al, 2003). However, this process can be slow, and intervention will be needed to speed up the debridement process in most cases (Wounds UK, 2013). Methods include surgical or sharp debridement where a surgical blade or scalpel is used to cut away the dead tissue. This should be performed only by those with additional competencies and training in this procedure.

Larval therapy (maggots) is also very effective for soft necrotic tissue, but may not be easily accessible in all areas without specialist input. Other specialist forms of debridement include ultrasound and hydrosurgery, but these are not routinely available to non-specialists. For most nurses, the most widely available method of debridement is dressings that promote a moist wound environment. These work by assisting the natural autolytic debridement process. Examples include hydrogels, hydrocolloids and honey.

In most cases, necrotic tissue will need to be removed to facilitate healing, but there are a few important exceptions. Ischaemic digits and necrotic tissue anywhere below the ankle should never be debrided until a full vascular

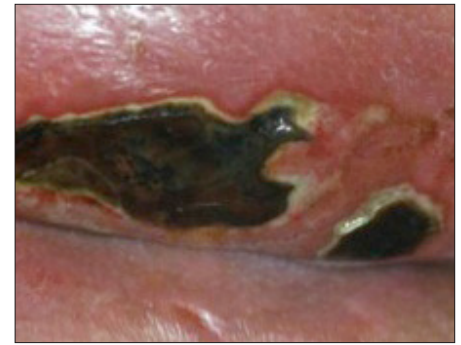assessment has been performed. In these cases it is advised to keep the digit or area of necrosis dry and refer for specialist assessment. It may also not be suitable for patients who are dying or have blood clotting disorders, or if sited near to blood vessels, nerves and tendons (Wounds UK, 2013). Specialist advice should be sought in such cases.

Sometimes necrotic tissue can be mistaken for other tissue types. The normal physiological response to injury is haemostasis and the formation of a fibrin clot of platelets. If a wound is left exposed to the air it will desiccate (dry out) and a scab will form. Dry scabs and sero-crusts are sometimes mistakenly referred to as necrotic eschars. Congealed blood clots in a wound and haematomas can appear dark in colour and these can also be mistaken for necrotic tissue (Figure 2). Blood clots are not the same as dead tissue.

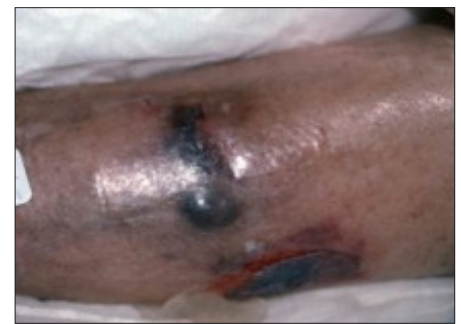### Slough

Slough refers to the yellow/white material in the wound bed; it is usually wet, but can be dry. It generally has a soft texture. It can be thick and adhered to the wound bed, present as a thin coating, or patchy over the surface of the wound (Figure 3). It consists of dead cells that accumulate in the wound exudate. During the inflammatory stage of healing, neutrophils congregate at the wound site to fight infection and clear away debris and devitalised tissue. They will often die faster than they can be removed by the macrophages and so accumulate in the wound as slough (Dealey, 2012).

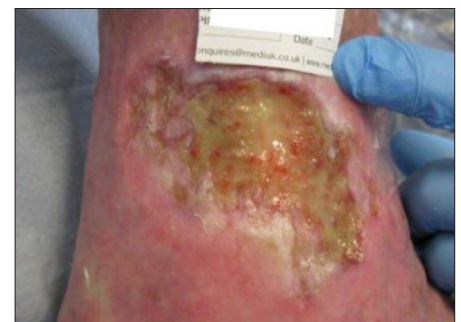
Given the right environment, slough will usually disappear as the inflammatory stage resolves and granulation develops. However, in chronic wounds the inflammatory stage can be prolonged and the excessive number of neutrophils results in the release of matrix metalloproteinases (MMPs) which destroy the developing extracellular



**Figure 1. Necrotic tissue. Autolytic debridement is beginning to occur at the wound margins where the black necrotic tissue is pulling away. Photo courtesy of Medetec.**



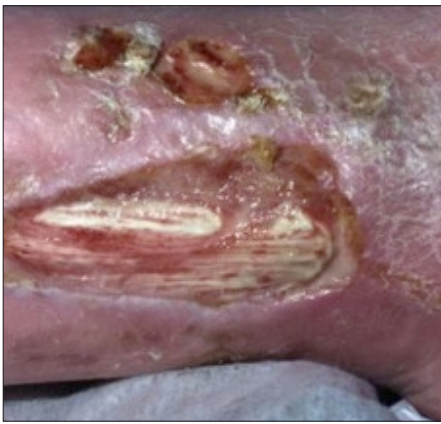**Figure 2. Haematoma is a collection of blood underneath the skin surface. Photo courtesy of Medetec.**



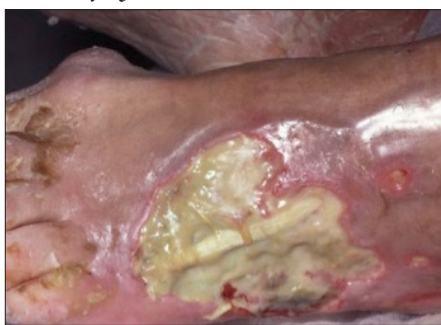**Figure 3. Slough with some buds of red granulation tissue visible at the distal aspect, and some pink epithelial tissue at the distal margins. Photo courtesy of Medetec.**

matrix (ECM; Hart, 2002). Therefore, slough may persist and require active removal by debridement, otherwise it will predispose the wound to infection and delay healing. Options for debridement are dressings that promote autolysis, such as UrgoClean® (Urgo Medical), or larval therapy.

A lack of understanding about what slough is and its relation to the stages



**Figure 4.** Tendon visible in the wound bed. Fibrous, stringy appearance of white tissue. Photo courtesy of Medetec.



**Figure 5.** Tendon visible in wound bed covered by slough. Photo courtesy of Medetec.

of wound healing, as well as what it looks like, can lead to a misdiagnosis which could have significant implications. It is not unknown for exposed tendon to be mistaken for slough, with attempts made to debride it with dressings. Tendon can present as creamy white in colour and can appear as thick substance in a wound bed. However, tendon will be fixed and firm and stringy in texture. It will move as the limb or joint flexes (Figures 4 and 5). Exposed tendon must not be allowed to dry out or it could snap; it is important to be kept moist. Referral must be made to a specialist.

Sometimes debris left in the wound from a previous dressing can be mistaken for slough; occasionally, wet alginates or hydrofibers left in the wound bed can appear similar in colour to slough. A deep-dermal or full-thickness burn can also appear similar to slough because it has a

creamy white or grey surface, and a waxy or leathery texture.

### Granulation tissue

Granulation derives from the term 'granular', and describes the appearance of the red, bumpy tissue in the wound bed as the wound heals. This bumpy appearance is the visible tops of the new capillary loops as a new vascular supply develops to serve the newly forming tissue with oxygen and nutrients (Dealey, 2012). Angiogenesis is the term describing the formation of new blood vessels. To repair the tissue defect, a scaffolding of ECM is formed by fibroblasts and proteoglycans to support the new developing blood vessels and collagen. It gives the tissue strength and elasticity. Fibroblasts also change into myofibroblasts to contract and draw the edges of the wound together (Timmons, 2006).

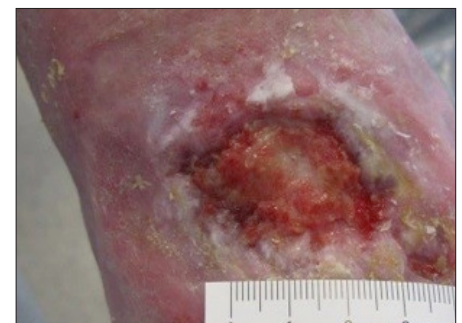Granulation is composed of collagen and elastin, proteoglycans and other components synthesised by fibroblasts. It is a temporary matrix that will eventually form scar tissue, replacing the lost dermis (Ovington and Schultz, 2004).

Normal granulation tissue is bumpy, moist and shiny and bright red. (Figures 6 and 7). Changes to this can indicate underlying problems. For example, pale granulation tissue can be observed in anaemic patients; and critical colonisation should be suspected if the granulation tissue is dark, brick red or friable, and bleeds easily (Cutting and Harding, 1994). If granulation tissue develops to the extent that it sits proud of the surrounding skin, this is known as hypergranulation, or overgranulation, tissue. Unhealthy, atypical granulation tissue that is not responding to recommended treatments may indicate a possible malignancy (Lloyd Jones, 2014). Although not common, nurses should be alert to this possibility if a wound is failing to heal despite appropriate treatment.

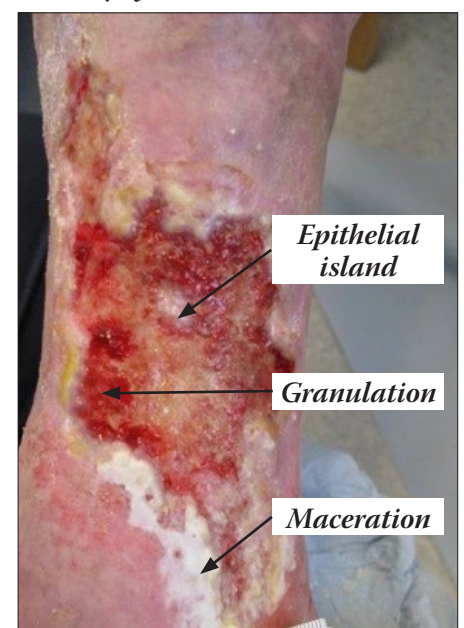
Granulation tissue needs to be treated gently. The aim of treatment should be to promote a warm, moist environment through the balanced control of exudate. Foams, hydrofibers, and alginates are all suitable product choices. Hydrocolloids can also be used, but they are occlusive and may create a hypoxic environment. Hypoxia is needed initially to stimulate angiogenesis, but thereafter oxygen is required for granulation tissue development (Ovington and Schultz, 2004).

### Epithelial tissue

Epithelialisation is the final stage of wound healing, during which epithelial cells (new skin cells) migrate across the wound surface to cover it. The cells arise from hair follicles,



**Figure 6.** Granulation tissue is bright red and bumpy. Photo courtesy of Medetec.



**Figure 7.** Leg ulcer showing mix of tissue types. Photo courtesy of Medetec.

sebaceous glands and sweat glands in the skin, and from the margins of the wound. Growth factors are needed to stimulate the proliferation of these new cells and their migration across the wound. Once they cover the wound surface and meet, they stop dividing. This is known as contact inhibition. The barrier function of the skin is now restored.

Epithelial tissue appears as pale pink/white in colour and is very delicate and fragile. Care is needed when cleansing the wound and when removing dressings. It is preferable to avoid strong adhesives in order to prevent skin stripping and shearing damage.

As with all other tissue types, epithelial tissue can also be misidentified. Maceration also appears white and is also usually found at the wound margins. If the margins are too wet, this will prevent new epithelial cells from forming and moving across the wound surface, so care must be taken to avoid excessive exudate and protect the surrounding skin. Because epithelial cells can arise from glands and hair follicles within the wound bed, they can appear as small islands (Figure 7). It is important that these be identified correctly to ensure attempts are not made to remove them when cleaning the wound, thinking they are debris or superficial slough.

Treatment of epithelialising wounds requires the creation of a warm moist environment (Winter, 1962). It is important not to allow the wound to dry out, as the epithelial cells will have to burrow deeper underneath the scab to close the wound, and this will prolong healing and result in a less cosmetically acceptable appearance (Schultz et al, 2003).

**Documentation**

After careful observation of the wound and correct identification of the tissue type, it is essential that

this be documented as a record of the wound at the time. Thorough documentation provides a baseline for measuring progress or identifying deterioration at subsequent dressing changes (Keast et al, 2004; Fletcher, 2008). Most organisations will have wound assessment charts or forms to capture this information, which could be in paper or electronic formats. It is important to provide as much detail as possible. Most wounds will have a mixture of tissue types within them at any one stage and, therefore, it is helpful to try to estimate the percentage of each tissue type. This will help to gauge over time if the wound is healing as expected (for example, the percentage of slough is decreasing). A series of photographs can be a really useful way of recording the appearance of a wound over time, provided certain techniques are followed (Sperring and Baker, 2014).

Other parameters of wound assessment include measurement, exudate amount, colour and consistency, pain, odour, infection, and condition of the surrounding skin, but these are beyond the scope of this article.

Describing the anatomical position of the wound is very important. This is an area where some nurses struggle to find the correct vocabulary. It has not been unknown for the same wound to be variously described as being on the buttocks, back of the thigh and ischial tuberosity, as an example. This can lead to confusion as to how many wounds are present and whether they are new or not. Being accurate in the description is a mark of a diligent clinician. Describing a wound as being on the heel, for example, might be true, but stating whether it is on the back (posterior) or side (lateral or medial) or sole of the heel (plantar) will be much more helpful in trying to establish how the wound occurred, and how to position the foot to promote healing. Some common descriptors are given in Table 1. A

**Table 1. Anatomical location descriptors. These terms are particularly useful when describing several wounds in relation to each other.**

Proximal	Near to
Distal	Away from
Lateral	Outside edge/aspect
Medial	Inside edge/aspect
Posterior	Behind
Anterior	In front of
Plantar	Sole of foot
Dorsal	Upper aspect/front of foot
Palmar	Surface/palm of hand

body map may also be helpful to accompany the description. Accurate documentation is the mark of a skilled and safe practitioner (Nursing and Midwifery Council, 2010).

**Conclusion**

It is important to accurately describe wounds using correct terminologies. The nurse needs to recognise the main tissue types seen in wounds and how they relate to the stage of healing, and understand the appropriate treatment methods. WE

**References**

Cutting KF, Harding KG (1994) Criteria for identifying wound infection. *Journal of Wound Care* 3(4): 198–201

Dealey C (2012) *The Care of Wounds*. (4th edn). Wiley-Blackwell, Chichester

Fletcher J (2008) Optimising wound care in the UK and Ireland: A best practice statement. *Wounds UK* 4(4): 73–81

Gray D, Acton C, Chadwick P et al (2011) Consensus guidance for the use of debridement techniques in the UK. *Wounds UK* 7(1): 77–84

Hart J (2002) Inflammation 1: Its role in

the healing of acute wounds. *Journal of Wound Care* 11(6): 205–9

Hart J (2002) Inflammation 2: Its role in the healing of chronic wounds. *Journal of Wound Care* 11(7): 245–9

Leaper D (2002) Surgical debridement. *World Wide Wounds*. Available at: <http://bit.ly/1qp2dW5> (accessed 07.05.15)

Lloyd Jones M (2014) How does hypergranulation tissue work? *Wound Essentials* 9(1): 8–13

Keast DH, Bowering CK, Evans AW et al (2004) MEASURE: A proposed assessment framework for developing best practice recommendations for wound assessment. *Wound Repair Regen* 2(3 Suppl): S1–17

Nursing and Midwifery Council (2010) *Record Keeping: Guidance for Nurses and Midwives*. NMC, London

Ovington LG, Schultz GS (2004) The physiology of wound healing. In: Morrison M, Ovington LG, Wilkie K (eds) *Chronic Wound Care*. Mosby: London

Russell L (1999) The importance of wound documentation and classification. *Br J Nurs* 8(20): 1342–8

Schultz GS, Sibbald RG, Falanga V et al (2003) Wound bed preparation. *Wound Repair Regen* 11(Suppl 1): S1–28

Sperring B, Baker R (2014) Ten top tips for taking high-quality digital images of wounds. *Wound Essentials* 9(2): 62–4

Timmons J (2006) Skin function and wound healing physiology. *Wound Essentials* 1: 8–17

Winter GD (1962) Formation of the scab and the rate of epithelialisation of superficial wounds in the skin of the domestic pig. *Nature* 193: 293–4

Wounds UK (2013) *Effective debridement in a changing NHS: A UK consensus*. Wounds UK, London

## Glossary

**Angiogenesis:** The growth of new blood vessels.

**Autolytic debridement:** The body's own natural process of breaking down dead, devitalised tissue.

**Collagen:** A protein that forms the connective tissue matrix.

**Debridement:** The process of removal of dead tissue through various means (also used to refer to removal of hard callous or hyperkeratotic skin).

**Devitalised tissue:** Dead tissue.

**Epithelialisation:** Final stage of wound closure. Keratinocytes migrate from wound margins and/or hair follicles and sebaceous glands to cover the wound surface.

**Extracellular matrix (ECM):** Supportive matrix of proteins such as collagen and elastin to give structure and strength to the new tissue.

**Exudate:** Wound bed fluid. Produced during inflammatory stage. Contains white blood cells, various growth factors and chemicals needed for wound healing but in excess can inhibit healing by the destructive proteinases (enzymes) it contains.

**Fibrin clot:** A network of protein fibres to trap blood components and stop bleeding.

**Fibroblast:** Cells that produce collagen and develop into myofibroblasts to help wound contraction.

**Granulation tissue:** Clusters of fragile, newly formed capillary loops that grow into the damaged tissue to form new tissue. Appears bright red and bumpy or granular.

**Growth factors:** Proteins that direct the healing process by stimulating the action of certain cells at specific stages of healing.

**Haematoma:** Collection of blood in the tissues beneath intact skin as a result of injury or trauma, or after surgery.

**Haemostasis:** Process of blood clotting and cessation of bleeding.

**Hypergranulation:** Over-production of granulation tissue that sits above the surface of the surrounding skin. Can be caused by friction, occlusion, chronic inflammatory response or bacterial load.

**Maceration:** Moist/wet, soggy tissue, usually at wound margins, caused by exposure to excessive exudate or external moisture. Inhibits epithelialisation and causes wound to extend.

**Macrophage:** White blood cell. Produces enzymes that break down devitalised tissue and then phagocytoses them. Produces growth factors and chemicals needed for tissue repair.

**Matrix metalloproteinases:** Group of enzymes that break down ECM and delay healing; found in excessive amounts in chronic wounds

**Necrosis:** Dead tissue. Appears black or brown in colour and can be dry and hard, or soft. Requires removal in most, but not all, cases

**Neutrophil:** White blood cell. First responder at inflammatory stage and responsible for phagocytosis of bacteria and devitalised tissue.

**Proteoglycans:** Components of the ECM that bind it together.

**Slough:** Devitalised tissue containing white blood cells and wound debris. Appears yellow/white and can be soft or leathery, and thick or thin. Requires removal to facilitate healing.