

# Preventing skin-stripping and blistering using a non-adherent perforated ethylene methyl acrylate film dressing: a case study evaluation




Figure 1. TIELLE® Lite is a composite dressing that incorporates non-adherent perforated ethylene methyl acrylate film at the wound contact interface.

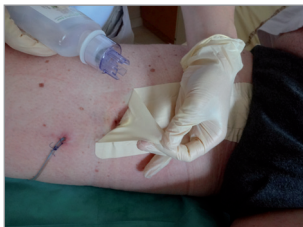

Figure 2. The water removal technique is used to deactivate TIELLE® Lite's adhesive border. Apply sterile water or saline to a swab or gauze. Lift one corner of the dressing edge and apply to the underside of the border. Gently peel back the dressing, breaking the adhesive seal with the swab or gauze as you proceed.

FRANCK DUTEILLE  
 Chief of Service, Chirurgie  
 Plastique Reconstructrice et  
 Esthétique, Centre des Brûlés,  
 Nantes, France

This series of five case studies focuses on maintaining the integrity of the peri-wound skin in a variety of post-operative incisions. To prevent skin-stripping and blistering, TIELLE® Lite was used as primary dressing. In each case, TIELLE Lite's non-adherent wound interface and ability to wick fluid from the wound surface was successful in preventing trauma to the skin around the incision sites.

Surgical wounds generally heal by primary intention with few complications (Ousey et al, 2011). However, certain patient factors and surgical types may predispose postoperative incisions to skin blistering, particularly if an unsuitable postoperative wound dressing is used. Skin blistering occurs when the epidermis becomes separated from the dermis and results from continued friction on the skin (Ravenscroft et al, 2006); postoperative dressing choice can influence the development of blisters. Skin stripping can also occur when adhesive dressings are removed, particularly on patients with fragile skin (Cutting, 2008).

## INCIDENCE OF SKIN BLISTERING AND STRIPPING

The incidence of skin blistering varies according to surgical specialty, but has been estimated to be generally 13–35% in the UK (Wright, 1994). Ravenscroft et al (2006) suggested that the main

complications in surgical wounds after hip and knee surgery are blistering, increasing the risk of secondary infection. A prospective clinical audit of wound blistering after hip and knee arthroplasties found a blister rate of 19.5% in an orthopaedic unit (Clarke et al, 2009). Studies focusing on orthopaedic procedures put the incidence of blistering at 6–24%, making it the second most common surgical incision-related adverse event (Polatsch et al, 2004; Cosker et al, 2005; Jester et al, 2000). And in a study of patients undergoing breast reconstructive surgery (Meuleneire et al, 2008) more than 80% of patients treated in the centre had suffered from postoperative skin lesions; in this case, the prevalence was attributed to poor dressing choice.

The literature is scant on rates of skin-stripping. However, in a trust-wide audit of coronary artery bypass graft patients, Rochon (2012) reports that the combined blister and skin-stripping rate was approximately 7%.

### Box 1. Causes of/risk factors for skin blistering and stripping

- ▶▶ Movement of the wound site
- ▶▶ Choice of dressing
- ▶▶ Adhesive tape use
- ▶▶ Age (children and the elderly, who tend to have immature or frail skin)
- ▶▶ Gender (females)
- ▶▶ Type of incision (open rather than minimally invasive)
- ▶▶ Anatomical location (near a bony prominence)
- ▶▶ Medications (e.g. corticosteroids)
- ▶▶ Lifestyle (e.g. alcohol consumption and smoking status)
- ▶▶ Comorbidities (e.g. vascular disease, diabetes)

Adapted from Ousey et al, 2011a; Koval et al, 2007

## WHY BLISTERING AND STRIPPING OCCUR

When there is increased friction and/or tension at the interface between the skin and the wound dressing, shear forces loosen the connections between the epidermis and dermis, which causes the separation of the two skin layers and allows interstitial fluid to seep into the newly created space to form blisters (Johansson et al, 2012). The presence of wound exudate (or any moisture, such as perspiration), even at normal healing levels, can exacerbate the risk for skin blistering and stripping because moisture increases friction forces and softens the skin, which weakens its outer layers (Johansson et al, 2012).

In addition, risk for skin stripping or the development of blistering on postoperative surgical wounds has been associated with a number of patient, procedure and care factors (*Box 1*). Orthopaedic procedures pose a particular risk. For example, a wound blister on or around such an incision is likely to occur because the dressings are applied for a long period of time, usually over a joint, where movement causes friction between the skin and the dressing, resulting in a shear force and, therefore, a blister (Ravenscroft et al, 2006). Patients undergoing joint replacement surgery are also subject to further risk factors, such as skin changes inherent in older patients and increased soft-tissue oedema after surgery. All these factors can be exacerbated by the type of dressing used and the mode of dressing application (although dressing choice does not have an impact where blistering arises from necrosis of the skin) (Ousey et al, 2011a).

## IMPACT OF SKIN BLISTERING AND STRIPPING

The development of skin blistering negatively affects both patient and practice, and poses potentially damaging financial ramifications. Blistering can cause pain, discomfort and persistent wound leakage, which decrease patient quality of life (Jester et al, 2000; Bhattacharyya et al, 2005). Wound leakage encourages a breakdown of skin integrity/development of maceration, which in turn makes the wound and blistering area more susceptible to infection (Cosker et al, 2005; Gupta et al, 2002). In addition, blistering and stripping can compromise the quality of the scar, particularly

from a cosmetic point of view — a serious concern from the patient's point of view (Young and Hutchison, 2009).

The presence of blisters and wound leakage require extra dressing changes, which necessitate additional nursing time and can delay hospital discharge (Abuzakuk et al, 2006). A recent Delphi survey (Ousey et al, 2011b) found that respondents strongly agreed that postoperative wound blistering could lead to wound infection, reduce patient mobility and increase inpatient length of stay.

Skin stripping can also result in high levels of pain for patients. A large-scale study in a French hospital found that pain during dressing change was rated as moderate to severe pain during dressing changes by approximately 80% of patients during a medical screening visit, and as very severe by 47% of acute wound patients in self-evaluation questionnaires completed at home (Meaume et al, 2004). The authors of the study write that, "Dressing removal was most painful when there was adherence to the wound bed"; adherence is a cause of skin-stripping.

## ROLE OF DRESSINGS IN PREVENTING BLISTERS AND SKIN-STRIPPING

Because a limited number of studies have examined the effect of different dressings on skin stripping and blister prevention, there are no conclusive recommendations regarding the most appropriate and effective choice of postoperative wound dressing (Tustanowski, 2009). However, in a Delphi survey, clinicians reported they believed the most important factor in preventing a wound blister was the choice of postoperative wound dressing (Ousey et al, 2011b).

Skin stripping and skin blistering generally occur at the point of dressing adherence. Dressing choice is, therefore, an important consideration. Dressings that lack elasticity, or those that are applied too tightly, in some cases to provide compression, create greater tension at the skin/dressing interface (Johansson et al, 2012). Adhesive dressings and tapes can strip skin and cause pain on removal (Meaume et al, 2004). Using a non-adherent dressing reduced pain during dressing change for 95% of patients in the large-scale French study (Meaume et al, 2004).

The ideal postoperative dressing (*Box 2*) should maintain a warm, moist healing environment

*Skin stripping and skin blistering generally occur at the point of dressing adherence. Dressing choice is, therefore, an important consideration*

**Acknowledgements:**  
*This article reports on five case studies supported by an unrestricted educational grant from Systagenix.*

## Box 2. Qualities of an ideal postoperative dressing

- ▶▶ Easy to apply
- ▶▶ Conformable to the wound, especially over bony prominences and during articulation/movement
- ▶▶ Accommodating to swelling
- ▶▶ Easy to remove/does not adhere to the wound or incision line, even in the presence of blood
- ▶▶ Flexible
- ▶▶ Comfortable for the patient to wear and pain-free on removal
- ▶▶ Able to manage low levels of exudate
- ▶▶ Bacterial barrier properties
- ▶▶ Extended wear time (7–14 days)
- ▶▶ Shower-/waterproof
- ▶▶ Stays in place
- ▶▶ Available in variety of sizes
- ▶▶ Cost effective
- ▶▶ Supported by research

Adapted from Ousey et al (2011b)

but should not damage the periwound area that could lead to blister formation (Ousey et al, 2011a). The dressing should be easy to apply and flexible, especially for orthopaedic wounds, which are at risk of friction and shear due to the necessity for patient mobilisation after surgery (Ousey et al, 2011a). A dressing should also be permeable; be transparent, to allow visualisation of the wound without the need to remove the dressing; have the ability to act as a barrier to bacteria and water but not moisture vapour; and be waterproof. Finally, the dressing should stay in place and handle low levels of exudate, to minimise frequency of dressing changes that increase skin vulnerability (Gillibrand, 2014).

## Box 3. Rationale for using TIELLE® Lite

- ▶▶ Acute, bleeding wounds, such as post-operative incisions
- ▶▶ Wounds in the final stages of healing
- ▶▶ Lightly exuding or epithelialising wounds
- ▶▶ Where fragile skin, pain, or skin-blistering or skin-stripping are concerns
- ▶▶ Where extended wear time (up to 7 days) is desired

**EVIDENCE FOR TIELLE® LITE HYDROPOLYMER ADHESIVE DRESSING**  
 TIELLE Lite is an all-in-one hydropolymer adhesive dressing that incorporates a non-adherent wound contact film (Data on file). There are several indications for use, and the only contraindication is in patients known to be sensitive to any of its components (Box 3). The dressing can manage low levels of exudate, as the island foam is absorbent, and also provides a moist environment that aids the wound-healing process (Figure 1). The non-adherent film minimises the risk of adhering to newly formed granulation tissue in the wound bed, even in the presence of blood (Taylor et al, 1999).

In a multicentre trial with 244 applications of TIELLE Lite, the dressing did not adhere to the wound bed 98.4% of the time even though 67% of the wounds were recorded as containing blood (a common cause of adherence) present at baseline. During the study, 82% of dressing changes were rated by patients as painless, with 10% being rated as causing only minimal pain; patients also scored the dressing highly in terms of comfort and performance with regard to quality of life (Taylor et al, 1999). The authors conclude the dressing was comfortable, easy to remove and suitable for treatment of bleeding wounds or those with low levels of exudate.

In a recent pilot study (Traynor and Dougall, 2013), 12 patients undergoing elective hip replacements had TIELLE Lite applied in theatre to ensure the dressing would have a chance to stretch and adapt to postoperative oedema and inflammation. During the evaluation, there was no evidence of blistering and no reports of any patient developing signs or symptoms of infection. The dressing stayed in place during showering, and only one dressing was needed for each patient during the evaluation, supporting cost-effective care. The authors concluded that the initial findings were positive and reported that they planned to conduct a larger study to evaluate TIELLE Lite (Traynor and Dougall, 2013).

## USING TIELLE LITE

Wound dressing choice should be made before surgery, skin should be protected during surgery, and the dressing should be applied immediately and consistently in the postoperative period, ideally before the patient leaves the operating theatre (Gillibrand, 2014).

Pay special attention to the condition of the surrounding skin — e.g. friable, damaged, any areas of previous trauma, any underlying medical conditions that may affect the patients skin condition (e.g. rheumatoid arthritis, medication) (Ousey et al, 2011a). Blistering in patients with vascular disease should be referred for specialist care. TIELLE Lite should be used with caution over wound areas that are infected or critically colonised, under the supervision and direction of the lead physician.

Prepare the postoperative wound according to local protocol, and ensure periwound skin is clean and dry before application (NICE, 2008). The size of

the dressing selected should let the absorbent island overlap the wound edge by approximately 1 cm.

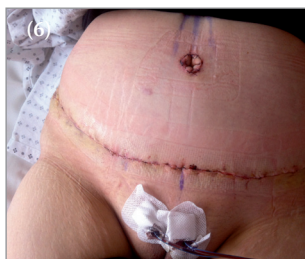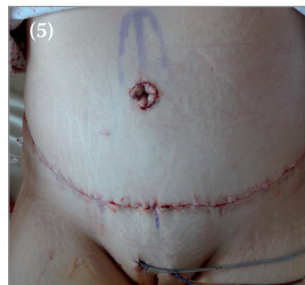
The primary postoperative wound dressing should be left in place for as long as exudate levels remain low and there are no signs of infection (Ousey et al, 2011b). TIELLE Lite may be left in place up to 7 days, depending on the amount of exudate, with dressing changes performed when wound fluid is present at the edges of the foam pad. To remove, a water removal technique is recommended (Figure 2).

Clinicians should fully document the condition of the peri-operative wound area at baseline assessment and throughout the course of treatment to establish a plan of care to prevent the formation of wound blisters should the skin appear to be vulnerable (Ousey et al, 2011a).

**CASE STUDIES**

This paper focuses on five post-surgical case studies using TIELLE Lite post-operatively to prevent skin stripping and blistering. The dressing was used over a variety of sensitive anatomies, and outcomes in terms of skin trauma prevention were excellent, with no incidences of stripping or blistering.

**Case 2: Incision after abdominoplasty**



**Figure 5. Abdominoplasty incision at first dressing change (1 day after surgery). Figure 6. Abdominoplasty incision at second dressing change (3 days after surgery).**

Ms P is a 43-year-old female and a smoker, who was taking levothyroxine for a thyroid disorder. An abdominoplasty resulted in a 48cm incision closed by overlock suturing with absorbable thread. TIELLE Lite was applied in theatre. At dressing change the next day, the water removal technique was used. Coupled with the EMA film, this meant there was no adherence to the incision line or periwound skin. There was no exudate present, and no evidence of blistering or skin stripping.

Because of the dressing's ease of application, conformability while *in situ* and ability to stay in place, as well as the patient's comfort during wear (rated 'very good') and removal ('good'), the decision was made to continue with TIELLE Lite, with dressing change scheduled 2 days later.

Between reviews, the patient showered with the dressing in place. Upon removal, the wound area was free from blistering, stripping and signs of infection, and healing well. The dressing was easy to apply and remove, with no adherence and 'excellent' patient comfort. It conformed well and stayed in place. TIELLE Lite was discontinued on discharge due to the incision's healing progress.

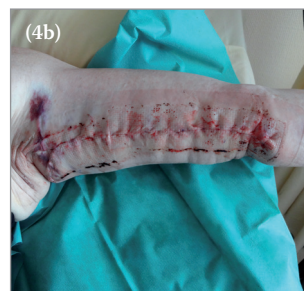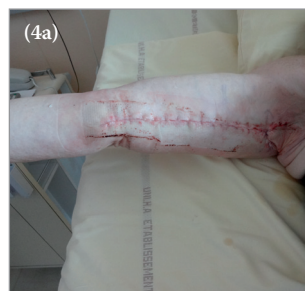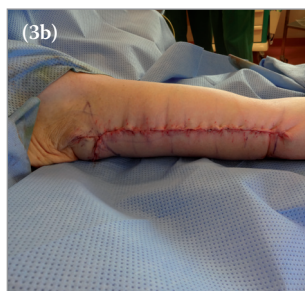
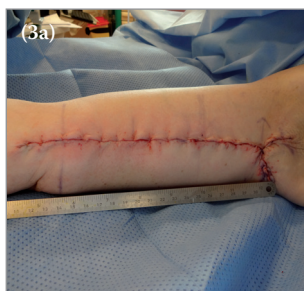**Case 1: Bilateral brachioplasty incisions after weight loss**

Mr GE is a 51-year-old male, who had a history of arterial hypertension and significant weight loss due to bariatric surgery. He was admitted to hospital to undergo bilateral brachioplasty to lift sagging, extra skin on his underarms. He was on levothyroxine for hypothyroidism. The incisions — 22 cm on the right arm, 23 cm on the left — were closed by overlock suturing with absorbable thread.

TIELLE Lite was applied in the operating theatre, with dressing change scheduled for the next day. When the dressing was changed using the water removal technique, there was no evidence of skin/wound trauma, and the dressing did not adhere to the wound or sutures, due to the EMA film. The wound was clean, with no inflammation or maceration.

Because the incision was moving towards healing, and the dressing did not result in any evidence of blistering or skin stripping, the decision was made to continue with TIELLE Lite. The patient was discharged and came back for consultation 1 week later, by which time the wound had healed completely.

TIELLE Lite was easy to apply and remove, with good absorption and no adherence to the wound and periwound skin. Its conformability while *in situ* was rated 'excellent', and its ability to stay in place 'very good'. The patient rated comfort during wear as 'excellent' and comfort during removal as 'very good'.



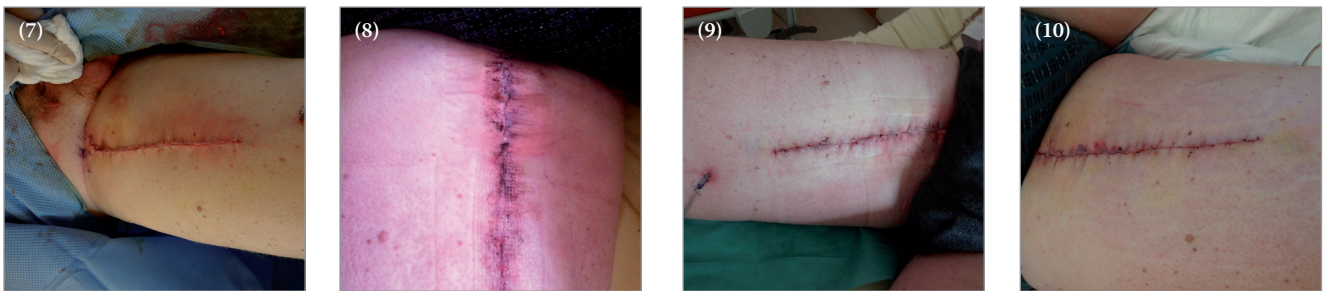
**Figures 3a/3b. Bilateral brachioplasty incisions at baseline | Figures 4a/4b. Bilateral brachioplasty incisions at first dressing change (1 day after surgery).**

**Case 3: Inguinal lymphadenectomy incision for malignant melanoma**

Mr CE is a 50-year-old man who underwent inguinal lymphadenectomy for treatment of malignant melanoma. He was on interferon injections to treat the melanoma, but had no known co-morbidities. The surgery resulted in a 21cm incision that was closed by intradermal overlock using absorbable point thread. TIELLE Lite was applied while the patient was still in theatre, with dressing change scheduled for 3 days later. Upon removal using the water removal technique to deactivate the adhesive border, the incision was healthy. Coupled with the EMA film, this meant there was no evidence in the wound area of blistering or stripping. There was no exudate and no signs of infection. Because of the ease of use and the patient's comfort during wear and removal, the decision was made to continue with TIELLE Lite, with dressing change in 3 days. On removal, the dressing did not adhere to the skin or sutures. The wound was found to be healing well, and the wound area did not have blistering or stripping. There was a low level of exudate, which TIELLE Lite managed effectively. On removal the patient experienced no pain. As the wound continued to progress towards healing, the decision was made to continue with TIELLE Lite and the next dressing change was scheduled for 4 days later.

At the final dressing change, the incision showed good progress towards healing, and the surrounding tissue was healthy. There was no exudate, blistering or stripping. The dressing was found to be easy to use with no adherence and good absorption. Patient comfort was 'excellent' during wear, and removal of TIELLE Lite did not cause pain.

**Figure 7. Inguinal lymphadenectomy incision after surgery. Figure 8. Inguinal lymphadenectomy incision at first dressing change (3 days after surgery). Figure 9. Inguinal lymphadenectomy incision at second dressing change (6 days after surgery). Figure 10. Inguinal lymphadenectomy incision at final dressing change (10 days after surgery).**



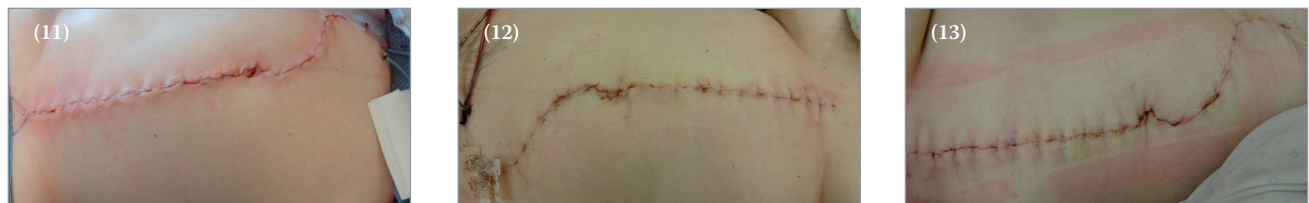**Case 4: Harvesting of free flap from rectus abdominis**

Ms CA is a 60-year-old female with depression and a past history of a chronic wound with bone infection. She was taking pregabalin, prazepam and trimebutine maleate. After harvesting of a free flap from the rectus abdominis, the 48cm surgical wound was closed using absorbable staples and suture in the overlock stitch.

TIELLE Lite was applied in the operating theatre, with dressing change scheduled for 1 week later. The dressing was changed using the water removal technique, and there was no evidence of skin/wound trauma or blistering; the incision line and surrounding skin were healthy, with no inflammation. Due to the EMA film, the dressing did not adhere to the wound or sutures. It stayed in place well, and the patient did not complain of pain during wear or removal.

The surrounding skin was healthy and the incision site was moving towards healing. As the dressing had performed well, TIELLE Lite was continued. At dressing change 3 days later, the incision site was free of inflammation and maceration, and the patient reported no pain. Because the incision had healed completely, TIELLE Lite was discontinued.

TIELLE Lite was easy to apply and remove, conformed well, and stayed in place without adhering to the wound and periwound skin. Its conformability while in situ was rated 'excellent', and its ability to stay in place 'very good'. The dressing was effective in preventing post-operative blistering and skin-stripping, and healing progressed quickly.



**Figure 11. Free flap incision after surgery. Figure 12. Free flap incision at first dressing change (1 week after surgery). Figure 13. Free flap incision second dressing change (10 days after surgery).**

Case 5: Incision after bilateral mammoplasty

Ms NE is a 21-year-old female who underwent bilateral mammoplasty for breast hypertrophy. She was healthy, with no comorbidities or medications. The surgery resulted in a 46cm incision, which was closed using subcutaneous knot, absorbable suture and cutaneous knot.

TIELLE Lite was applied in the operating theatre. The water removal technique was used a dressing change 2 days later. Coupled with the EMA film, this meant the dressing did not adhere to the wound or periwound skin. The patient was reassured by the absence of maceration, inflammation and pain. She was able to shower with the dressing in place between reviews. There was no exudate present, and no evidence of blistering or skin stripping.

Because the incision had progressed so well TIELLE Lite was discontinued. The patient was discharged home and asked to return in 1 month for a postoperative consultation, TIELLE Lite was discontinued. The dressing was easy to apply and remove, stayed in place without adherence, and was comfortable for the patient. Both clinician and patient were pleased with the dressing performance.

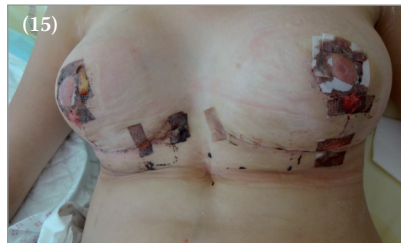
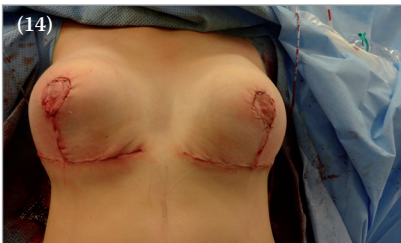
Figure 14. Incisions after bilateral mammoplasty

Figure 15. Bilateral mammoplasty incisions at dressing change (2 days after surgery).

SUMMARY

Blistering and stripping are common problems with many risk factors. It's important to review the patient factors that might affect skin fragility after surgery, as well as the location of the incision, to prevent post-operative skin trauma. Skin blistering and stripping can cause pain, impede cosmetic results, allow SSIs to develop and, potentially, extend hospital stays. It's therefore crucial to avoid blistering and stripping of skin around surgical incisions.

In all five case studies, there were no incidences of skin blistering or stripping. As TIELLE Lite incorporates a non-adherent wound interface layer, no adherence to incision lines was reported. The dressing remained in place during wear and was easy to apply. TIELLE Lite can be seen as an effective choice for proactively managing incision sites to reduce the risk of associated post-operative complications.



REFERENCES

Abuzakuk TM, Coward P, Shenava Y, et al (2006) The management of wounds following primary lower limb arthroplasty: a prospective, randomised study comparing hydrofibre and central pad dressings. *Int Wound J* 3(2): 133-7

Bhattacharyya M, Bradley H, Holder S, Gerber BA (2005) Prospective clinical audit of patient dressing choice for post-op arthroscopy wounds. *Wounds UK* 1(1):30-4

Clarke JV, Deakin AH, Dillon JM, Kinninmonth AWG (2009) A prospective clinical audit of a new dressing design for lower limb arthroplasty wounds. *J Wound Care* 18(1):5-8, 10-11

Cosker T, Elsayed S, Gupta S, et al (2005) Choice of dressing has a major impact on blistering and healing outcomes in orthopaedic patients. *J Wound Care* 14(1):27-9

Data on file. TIELLE® Lite Hydropolymer Adhesive Dressing, Systagenix.

Gillibrand W (2014) Ten top tips: Preventing orthopaedic surgery-related wound blisters. *Wounds International* 5(2):16-9. Available at: <http://www.woundsinternational.com/practice-development/ten-top-tips-preventing-orthopaedic-surgery-related-wound-blisters>

Gupta SK, Lee S, Moseley LG (2002) Postoperative wound blistering: is there a link with dressing usage? *J Wound Care* 11(7):271-3

Jester R, Russell L, Fell S, et al (2000) A one hospital study of the effect of wound dressings and other related factors on skin blistering following total hip and knee arthroplasty. *J Orthop Nurs* 4(2):71-7

Johansson C, Hjalmarsson T, Bergentz M, et al (2012) Technology update: Preventing post-operative blisters following hip and knee arthroplasty. *Wounds International* 3(2): 1-6. Available at: <http://www.woundsinternational.com/product-reviews/preventing-post-operative-blisters-following-hip-and-knee-arthroplasty>

Koval KJ, Egol, KA, Hiebert R, Spratt KF (2007) Tape blisters after hip surgery: Can they be eliminated completely? *Am J Orthop* 36(5): 261-5

Meaume S, Téot L, Lazareth I, et al (2004) The importance of pain reduction through dressing selection in routine wound management: the MAPP study. *J Wound Care* 13(10):409-13

National Institute for Health and Care Excellence (NICE) (2008) Surgical site infection: Prevention and treatment of surgical site infection. Manchester, UK: NICE. Available at: <http://www.nice.org.uk/guidance/cg74/resources/guidance-surgical-site-infection-pdf>

Ousey K, Gillibrand W, Stephenson J (2011a) Understanding and preventing wound blistering. *Wounds UK* 7(4):50-6

Ousey K, Gillibrand WP, Lui S, Stephenson J (2011b) An investigation into the prevention of blistering in post operative wounds — results of a Delphi survey. Poster presented at: Wounds UK Annual Conference; Harrogate, UK: 14-16 Nov. Available at: <http://www.wounds-uk.com/case-series/harrogate-2013-conference-posters>

Polatsch DB, Baskies MA, Hommen JP, et al (2004) Tape blisters that develop after hip fracture surgery: a retrospective series and a review of the literature. *Am J Orthop (Belle Mead NJ)* 33(9):452-6

Ravenscroft MJ, Harker J, Buch KA (2006) A prospective, randomised, controlled trial comparing wound dressings used in hip and knees surgery: Aquacel and Tegaderm versus Cutiplast. *Ann R Coll Surg Engl* 88(1):18-22

Rochon M, Morais C, Mahiou F (2014) Blistering and skin stripping affecting coronary artery bypass graft patients. *Wounds UK* 10(1):40-4. Available at: <http://www.wounds-uk.com/journal-articles/blistering-and-skin-stripping-affecting-coronary-artery-bypass-graft-patients>

Rochon M (2012) Primary closure of clean surgical wounds. *Clin Services J* April:22-5

Stephens S, Addison D, Mistry P, et al (2011) The design principles of non-adherent materials and the challenges of maximising dressing performance without compromising the mode of action. Poster presented at: Wounds UK Annual Conference; Harrogate, UK: 14-16 Nov. Available from: <http://bit.ly/1orBBgD> (accessed 10.09.2014)

Taylor A, Lane C, Walsh J, et al (1999) A non-comparative multi-centre clinical evaluation of a new hydropolymer adhesive dressing. *J Wound Care* 8(10):489-92

Traynor C, Dougall H (2013) A pilot study for evaluating the clinical benefits of TIELLE Lite for post-operative incisions. Poster presented at: Wounds UK Annual Conference; Harrogate, UK: 11-13 Nov. Available at: <http://bit.ly/1ukCfC9> (accessed 10.09.2014)

Tustanowski J (2009) Effect of dressing choice on outcomes after hip and knee arthroplasty: a literature review. *J Wound Care* 18(11):449-58

Wright M (1994) Hip blisters. *Nurs Times* 90(16):86-8

Young VL, Hutchison J (2009) Insights into patient and clinician concerns about scar appearance: semiquantitative structured surveys. *Plast Reconstr Surg* 124(1):256-65