

Hydroconductive debridement

made easy

Introduction

Wound bed preparation is now well established and forms the basis for wound management where healing is delayed. It offers clinicians a comprehensive approach to removing the barriers to healing, helping to stimulate the repair process. This Made Easy discusses Drawtex[®] Hydroconductive Debridement Dressing (Martindale Pharma), which combines three modes of action (debridement, exudate management and bacterial control) to promote wound healing where healing is delayed. Studies show how nurses can save time and treatment costs using this innovative wound dressing, and improve patient quality of life.

Author: Bullough L

IMPACT OF DELAYED HEALING

For the majority of wounds, healing is a simple and rapid process, with evidence of progress usually visible within a two- to four-week period (Sheehan, 2003). However, in 1–2% patients, healing is prolonged and incomplete, often accompanied by excessive exudate, odour and persistent pain, which adversely affect quality of life (Vowden, 2011). In the UK, chronic wounds represent a significant burden to patients and the costs of caring for patients with a chronic wound is estimated at £2.3–3.1 billion per year (Posnett and Franks, 2008).

FACTORS THAT AFFECT WOUND HEALING

Wounds that become chronic do not follow the normal pattern of repair. Barriers to healing include wound aetiology, patient age and the presence of comorbidities (e.g. diabetes or vascular disease), as well as factors such as wound size, depth, location of the wound and wound duration.

Wounds usually contain bacteria and other microorganisms, and most are not harmful. However, the presence of microorganisms in a wound, even in the absence of signs of local or systemic infection, has long been recognised as a potential cause of delayed healing (WUWHS, 2008).

Bacteria in wounds may delay healing by exaggerating the inflammatory response in the wound. This induces the release of protein-digesting enzymes and free radicals which, in excess, can cause tissue damage.

The inflammatory response also increases the permeability of blood vessels in the wound, increasing exudate production, which in turn may cause problems such as maceration and excoriation of the wound bed and periwound skin, pain, and wound enlargement (Wounds UK, 2013a).

In recent years, it has been recognised that in addition to existing in a free form, microorganisms in wounds can be present in a slimy layer — a biofilm. A study that used electron microscopy to study biofilms in wounds found that 60% of chronic wound biopsies contained biofilm, but biofilm was found in only 6% of acute wound biopsies (James et al, 2008).

There is increasing interest in biofilms as a contributor or direct cause of delayed wound healing. Efforts are being directed at discovering interventions that reduce their impact and aid healing.

ROLE OF WOUND BED PREPARATION

Wound bed preparation (WBP) is a recognised systematic approach to removing barriers to wound healing and is considered an essential element of wound management. The concepts of wound bed preparation and TIME were created in 2003 to help clinicians identify the key barriers to healing in individual patient's wounds (Dowsett and Newton, 2005).

The four main components of WBP are tissue management (T), control of infection and inflammation (I), moisture imbalance (M), and advancement of the epithelial edge (E) (EWMA, 2004). The TIME framework is a practical assessment tool based on identifying the barriers to healing and implementing a plan of care to remove these barriers and promote wound healing (Dowsett and Newton, 2005). It is important, however, to understand wound bed preparation and TIME within the context of total patient care.

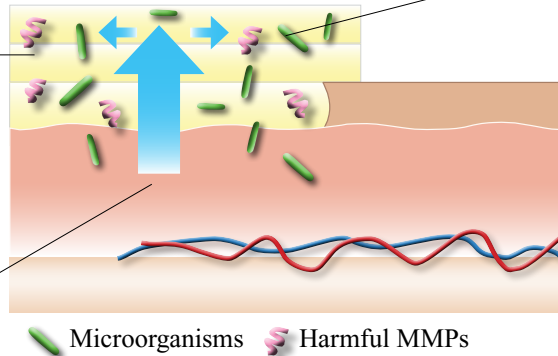
Clinicians must therefore undertake and document a holistic assessment to determine the treatment goals. The assessment should comprise the wound/periwound areas and their characteristics (e.g. redness, unexplained pain or malodour), as well as account for patient factors (e.g. immunocompromised, presence of metabolic disease, vascular status) (EWMA, 2004).

Since 2003, the science of WBP has advanced in several important areas and new technologies have been created, including the development of innovative dressing technologies to promote high-quality healing.

BOX 1: UNDERSTANDING HOW HYDROCONDUCTIVE DEBRIDEMENT WORKS (OCHS ET AL, 2012)

LevaFiber™ Technology refers to a combination of hydroconductive, capillary and electrostatic activities generated by the structure of the dressing:

- **The hydroconductive action** allows the dressing fibres to lift, hold and transfer large volumes of wound exudate and devitalised tissue vertically and horizontally in the dressing



- **The capillary action** allows the exudate to be drawn upward against the force of gravity

- **An electrostatic action** occurs when the negatively charged dressing comes into contact with wound exudate, altering the charge on the surface of the dressing to positive. Negatively charged harmful organisms (e.g. bacteria, proteases) within the exudate are drawn into the positively charged material, trapping them in the dressing

HYDROCONDUCTIVE DEBRIDEMENT AND WBP

Hydroconductive debridement is a selective process that actively promotes and accelerates autolysis, removing adherent fibrin, slough and necrotic tissue (debriding action) as well as sequestering exudate containing potentially harmful substances away from the wound bed (infection/moisture management), leaving healthy granulation tissue in place for accelerated healing (edge advancement).

A hydroconductive debridement wound dressing (Drawtex®, Martindale Pharma) can be used to prepare the wound where barriers to healing have been identified. It is highly absorbent, comprising three layers that actively draw fluid and wound debris from the wound into the dressing (Box 1). The dressing is available on Drug Tariff and NHS Supply Chain.

Tissue management

The presence of necrotic or devitalised tissue is common in chronic, non-healing wounds. It is generally accepted that unhealthy tissue must be removed as quickly and efficiently as possible to assist with wound assessment, reduce bioburden, remove biofilm and prevent infection (Wounds UK, 2013b). Effective debridement is therefore an essential part of wound management to promote healing. Although its role in wound healing is well documented, there is no consensus on which method of debridement is best (Vowden and Vowden, 2011). The rationale for selecting a debridement method must be based on the wound management plan and the goals for each patient and wound. A range of different methods may be required over time, depending on the need to accelerate or stabilise healing.

Drawtex Hydroconductive Debridement Dressing facilitates debridement by creating a moist wound environment to soften and remove devitalised tissue. The dressing's capillary action (known as 'wicking') draws the exudate through the tissue into spaces in the dressing, helping to it break up non-viable tissue

and cells, which are then also pulled into the dressing (Ortiz et al, 2012). The goal of debridement is to restore the wound base and functional extracellular matrix (ECM) proteins, leaving behind a viable wound base for healing (Dowsett and Newton, 2005). Recent data has revealed that wound debridement plays an important role in reducing the levels of bacterial biofilms (Kirschen et al, 2006).

Control of infection and inflammation

Chronic wounds are often heavily colonised with bacterial or fungal organisms. Bacteria may stimulate a persisting inflammation leading to the production of inflammatory mediators and proteolytic enzymes (such as MMP-2 and MMP-9). These may inhibit normal wound healing by slowing down or even preventing cell proliferation, degrading the ECM and causing periwound skin problems. Bacterial burden must therefore be controlled to facilitate healing or to maximise the effectiveness of advanced wound care modalities.

Drawtex Hydroconductive Debridement Dressing exhibits bacterial sequestration and retention capabilities (Edwards-Jones et al, 2014), helping to control bacterial levels within the wound by trapping microorganisms in the dressing fibres (Couch, 2012; Ortiz et al, 2012; Ochs et al, 2012; Wolcott, 2012).

Moisture imbalance

Any factor that increases capillary leakage or predisposes to the development of tissue oedema (e.g. inflammation, bacterial contamination or limb dependency) may increase exudate production (Romanelli et al, 2010).

The aim of exudate management is to achieve a moist but not macerated wound bed, and when managed effectively, can reduce time to healing, reduce exudate-related problems (e.g. infection) and reduce dressing change frequency. Dressings are the main option for managing exudate at wound level and these may vary in their ability to handle fluid and may have other properties.

Drawtex Hydroconductive Debridement Dressing is composed of a variety of different fibres collectively referred to as LevaFiber™ technology. When in contact with exudate, the fibres draw exudate vertically and horizontally into the dressing. The combination of absorbent and cross-action structures in LevaFiber, transfer and retain exudate and harmful substances in the body of the dressing, absorbing up to 8 times its own weight (Ochs et al, 2012; Wendelken et al, 2012; Edwards-Jones et al, 2014). The dressing can be layered to maximise absorbency, helping to keep moisture away from the edges of the wound and reducing the risk of maceration (Wendelken et al, 2012). In addition, research shows that the dressing can draw MMP-9 and transport cytokines up to 7cm from the wound (Wendelken et al, 2012). Exudate is also a potentially important nutrient source for biofilm and removing exudate may inhibit biofilm activity (Wolcott, 2012).

Advancement of the epithelial edge

Lack of improvement in wound dimensions and non-progression of the wound edge indicate failure to heal. The presence of abnormalities such as devitalised tissue (e.g. areas of necrosis or slough) at the wound edge can delay wound-margin advance and wound-surface reduction. Epithelial advancement can be promoted by removing the physical and biochemical barriers to healing (EWMA, 2004).

SUMMARY OF EVIDENCE

Results from laboratory and clinical studies have demonstrated that Drawtex Hydroconductive Debridement Dressing is capable of drawing wound exudate and soluble debris into the dressing to sequester bacteria (Wolvos, 2012; Ortiz et al, 2012; Ochs et al, 2012), important nutrients for biofilm production (Wolcott, 2012) and deleterious cytokines and harmful proteases (e.g. MMPs) that inhibit wound healing (Ochs et al, 2012; Couch, 2012; Wolcott, 2012). These actions can facilitate WBP (Spruce, 2012), leading to a reduction in wound area (Ochs et al, 2012) and faster healing compared to standard care (Wendelken et al, 2012).

WHEN IS HYDROCONDUCTIVE DEBRIDEMENT INDICATED?

Drawtex Hydroconductive Debridement Dressing is indicated for any wound with moderate to high levels of exudate and/or containing devitalised tissue (slough/necrosis). It can be used on a variety of wound types, including venous leg ulcers (under compression), pressure ulcers, cavity wounds, diabetic foot ulcers, stoma sites, postoperative wounds and partial-thickness burns. It should not be used on wounds where there is a risk of bleeding (e.g. fungating wounds, arterial wounds).

HOW TO APPLY DRAWTEX

The 3mm thick dressing is very easy to use and can be cut to the size of any wound and applied in layers. Cutting allows the dressing to conform to the wound bed, while the number of layers (minimum of 2) will depend on the depth of the wound

and amount of exudate. The fibrous cross-structure of the dressing means it stays intact when saturated. It can be used as a flat dressing or as a drain for deeper wounds.

The dressing should be covered with an appropriate secondary dressing according to the level of exudate. Ideally this should be a vapour permeable transparent film dressing.

Frequency of dressing changes

The dressing can be used on infected wounds when dressing changes should occur on a daily basis. On non-infected wounds where the aim is to remove devitalised tissue to clean the wound bed and manage exudate levels, dressing changes can be undertaken every two to three days.

Drawtex Hydroconductive Debridement Dressing should be continued until the treatment goals have been met (e.g. when the wound bed is granulating and exudate levels have decreased).

BENEFITS OF HYDROCONDUCTIVE DEBRIDEMENT

Drawtex Hydroconductive Debridement Dressing can help to remove the barriers to healing using one modality rather than a combination of different methods (Box 2). It has been shown to reduce the percentage of devitalised tissue to allow the wound to progress. It can also manage exudate volume (reducing frequency of dressing changes), improve the condition of the surrounding skin and reduce the need for skin barrier products (Johnson, 2012).

Patients treated with the dressing have reported a significant impact on their quality of life. Pain levels were reduced, exudate levels were well managed and odour was controlled. Debridement of the wound was safe and rapid, resulting in advancement in wound bed preparation, which allowed normal resumption of daily activities (Bullough, 2014).

Bullough and Spruce (2013) in their 10-patient evaluation found that, in addition to the speed of debridement, the total cost of dressing changes used to debride wounds was reduced. The comparative cost of the dressings included primary and secondary dressings and methods of fixation (e.g. retention bandage). The comparative costs were recorded, showing an actual cost saving of £264.48 per week.

BOX 2: BENEFITS OF HYDROCONDUCTIVE DEBRIDEMENT

- Combines three modes of action to optimise the wound environment (Brown and Yorke, 2013)
- Decreases wound bioburden/biofilm activity (Wolcott and Dowd, 2011; Lichtenstein et al, 2011; Wolcott, 2012)
- Modulates harmful inflammatory markers such as cytokines and proteases (Ochs et al, 2012)
- Debrides devitalised tissue (Johnson, 2012)
- Reduces exudate level (Ochs et al, 2012)
- Improves quality of life (Bullough, 2014)
- Is cost-effective (Bullough and Spruce, 2013)

CASE 1: MIXED-AETIOLOGY LEG ULCERS WITH 100% SLOUGH**Background**

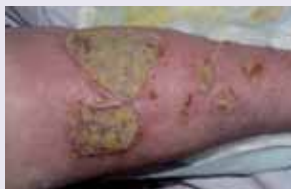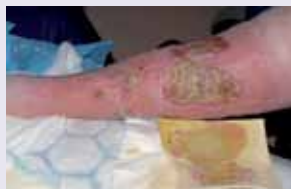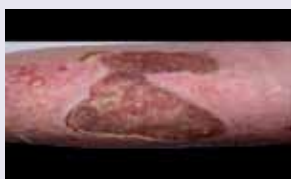A 68-year-old male with mixed-aetiology ulcers on his left leg was admitted to hospital with sepsis. He had undergone a below-knee amputation of his right leg three years previously. The wounds, which had been present for 18 months, contained 100% slough. Peri-wound skin was macerated and red, and the exudate level was high (Figure 1). The patient scored his pain 5 out of 10 on a visual analogue scale (VAS) and was very conscious of malodour from the wound. The wound had been dressed with a Hydrofiber® dressing that was secured with wool and a support bandage. Dressing changes were being performed daily due to the malodour and high levels of exudate.

Treatment

The primary aim of treatment was to prepare the wound bed by removing the devitalised tissue safely and quickly, and to manage the exudate. Drawtex Hydroconductive Debridement Dressing (three layers of 20cm x 15cm) was applied and secured with wool and a support bandage. Dressings were scheduled to be changed daily.

Dressing change day 3: The wound showed signs of debridement, with moderate levels of exudate (Figure 2). The patient rated pain as 3 out of 10 and stated that wound-associated pain had reduced significantly. Due to the initial success in debridement, the dressing regimen was continued, but frequency of changes was altered to every 2–3 days.

Dressing change day 5: Two days later, slough had significantly reduced, revealing 90% granulation in the wound bed (Figure 3). Malodour had resolved and the patient rated pain as a 2 on the VAS. The patient was discharged back to the community at this time.

**Figure 1. Wound at baseline****Figure 2. Wound at day 3****Figure 3. Wound at day 5****AUTHOR DETAILS****Bullough L¹**

1. Tissue Viability Nurse, Wrightington, Wigan and Leigh NHS Trust, UK

Supported by Martindale Pharma

CRIT/06/2014/262 Date of preparation: June 2014. To cite this document: Bullough L (2014) Hydroconductive debridement Made Easy. Wounds UK 10(2). Available from www.wounds-uk.com

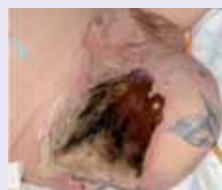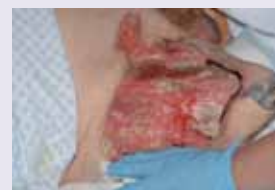CASE 2: NECROTISING FASCIITIS WITH 100% NECROSIS**Background**

A 66-year-old male with diabetes, peripheral vascular disease, history of stroke, chronic obstructive pulmonary disease and heavy smoker was admitted to hospital with sepsis due to a Category IV* sacral pressure ulcer. Three days after admission, he developed necrotising fasciitis to the stump of his right leg. The wound bed contained 100% necrosis, with high exudate levels (Figure 1). The patient rated his pain as 5 out of 10 on the VAS, and received medical nitrous oxide and oxygen for pain relief during dressing changes. He was also conscious of wound malodour. The patient was deemed unfit for surgery.

Treatment

The primary aim of treatment was to prepare the wound bed by removing the devitalised tissue safely and quickly, and to manage the exudate. Drawtex Hydroconductive Debridement Dressing (three layers of 20cm x 15cm) was applied and secured with a film dressing. Dressing changes were performed daily due to high exudate levels.

Dressing change day 5: The patient was formally assessed after 5 days' treatment. The wound was 95% debrided, with low levels of exudate (Figure 2). The patient rated pain as a 2 out of 10 and noted that malodour had significantly reduced. The patient was discharged back to the community at this time.

**Figure 1. Wound before treatment****Figure 2. Wound at 5 days**

*EPUAP, 2009 www.epuap.org

References

- Brown A, Yorke M (2013) Drawtex: breaking the vicious circle of cellular and molecular imbalances. *Br J Community Nurs Suppl* S42, S44, S46–9
- Bullough L (2014) Using hydroconductive debridement to improve the quality of life for patients. E-Poster presentation. European Wound Management Association, Madrid.
- Bullough L, Spruce P (2013) Removing all barriers: a 10-patient evaluation in the acute care setting. *Br J Nurs* 22(20): S38, S40–4
- Couch KS (2012) Discovering hydroconductive dressings. *Ostomy Wound Manage* 58(4): 8–10
- Dowsett C, Newton H (2005) Wound bed preparation: TIME in practice. *Wounds UK* 1(3):58–70.
- EWMA (2004) Position document: *Wound bed preparation in practice*. London: MEP Ltd.
- Edward-Jones V, Vishnyakov V, Spruce P (2014) Laboratory evaluation of Drawtex Hydroconductive Dressing with LevaFiber technology. *J Wound Care* 23(3): 118–27
- James GA1, Swogger E, Wolcott R, (2008) Biofilms in chronic wounds. *Wound Repair Regen* 16(1): 37–44
- Johnson S (2012) Reducing the barriers to wound healing using a hydroconductive dressing.
- Kirshen C, Woo K, Ayello EA, Sibbald RG (2006) Debridement: a vital component of wound bed preparation. *Adv Skin Wound Care* 19(9): 506–17.
- Lichtenstein P, Wendelekn M, Alvarez OM (2011) Detoxification of venous ulcers with a novel hydroconductive wound dressing that transfers chronic wound fluid away from the wound. Poster presentation: SAWC, Dallas.
- Ochs D, Uberti MG, Donate GA, et al (2012). Evaluation of mechanisms of action of a hydroconductive wound dressing, Drawtex, in chronic wounds. *Wounds* 24(9)(Suppl):6–8.
- Ortiz RT, Moffat LT, Robson MC, et al (2012) In vivo and in vitro evaluation of the properties of DrawtexLevaFiber wound dressing in an infected burn wound model. *Wounds* 24(9)(Suppl):3–5
- Posnett J, Franks PJ (2008) The burden of chronic wounds in the UK. *Nursing Times* 104(3): 44–5
- Romanelli M, Vowden K, Weir D (2010) Exudate management made easy. *Wounds International* 1(2).
- Sheehan PI, Jones P, Caselli A, et al (2003) Percent change in wound area of diabetic foot ulcers over a 4-week period is a robust predictor of complete healing in a 12-week prospective trial. *Diabetes Care* 26(6):1879–82.
- Spruce P (2012) Preparing the wound to heal using a new hydroconductive dressing. *Ost Wound Manage* 58(7): 2–3
- Vowden P (2011) Hard to heal wounds Made Easy. *Wounds International* 2(4)
- Vowden K, Vowden P (2011) Debridement made easy. *Wounds UK* 7(4):S1–S4.
- Wendelken M, Lichtenstein P, DeGroat K, Alvarez O (2012) Detoxification of venous ulcers with a novel hydroconductive wound dressing that absorbs and transports chronic wound fluid away from the wound. *Wounds* 24(9)(Suppl):11–13.
- Wolcott R, Dowd S (2011) Drawtex effects on VLU healing and biofilm. Poster Presentation, SAWC
- Wolcott RD (2012) The effects of a hydroconductive dressing on the suppression of wound biofilm. *Wounds* 24(5): 132–7
- Wolvos T (2012) Analysis of wound bed documentation in advanced wound care using Drawtex, a hydroconductive dressing with LevaFiber Technology. *Wounds* 4(9)(Suppl):9–10.
- Wounds UK (2013a) *Best Practice Statement: Effective exudate management*. Wounds UK
- Wounds UK (2013b) *Effective debridement in a changing NHS. A consensus document*. Wounds UK
- WUWHS (2008) Principles of best practice: Wound infection in clinical practice. A consensus document. London: MEP. Available from www.woundsinternational.com