

Treating infection and malodour using a dressing with charcoal and silver: a case study evaluation

KEY WORDS

- ▶ Antimicrobial dressing
- ▶ Silver dressing
- ▶ Skin infection
- ▶ Wound infection

This series of three case studies focuses on patients with wounds with malodour, infection and stalled healing treated with ACTISORB® Silver 220 (Systagenix). The series evaluation covers a wide range of wound types, including an overgranulating wound, black/necrotic toes and skin infection. In each case, ACTISORB Silver 220's combination of activated charcoal and metallic silver was successful in achieving the treatment goals.

ACTISORB® Silver 220 (Systagenix) is composed of a sealed non-woven nylon sleeve containing activated charcoal impregnated with metallic silver. It has been indicated for use as an antimicrobial and odour-control dressing for more than a decade (Hampton, 2001; Leak, 2002; Keriheul, 2009; 2010; White, 2013).

Charcoal is extremely porous on activation, a process in which the charcoal is heated to approximately 1000°C in the absence of oxygen, achieved either by steaming or heating in a vacuum (Marsh and Rodriguez-Reinoso, 2006). The result is activated charcoal, with large pores that increase the surface area of the charcoal. An activated charcoal cloth dressing — such as ACTISORB Silver 220 (Naka et al, 2001; Keriheul, 2009) — can adsorb bacteria, toxins, spores and wound products.

Cell lysis produces endotoxins, which have an inflammatory effect and can disrupt the healing process; activated charcoal also adsorbs these endotoxins, thus giving it anti-inflammatory properties (Fleck, 2006).

Silver has long been shown to have an antimicrobial effect and has been used for medicinal purposes since the 19th century (White, 2001). Discussion on the antimicrobial action of silver in wound care has centred on: interference with bacterial electron system and binding to DNA of bacteria and spores impairing cell replication; binding causing structural and receptor function damage (Thurman and Gerba, 1989). In ACTISORB Silver 220, bacteria are bound to the activated charcoal cloth fibres and in addition to the adsorption effect, silver ions kill the bacteria and so reduce bacterial burden in the wound. Keriheul

(2009) also suggested that ACTISORB Silver 220 participated in the reduction of biofilm growth.

In addition to activated charcoal and metallic silver, ACTISORB Silver 220 features a non-woven nylon sleeve that reduces the risk of adherence to the wound bed, reducing trauma on removal.

EVIDENCE FOR ACTISORB SILVER 220

Clinical studies have demonstrated activated charcoal cloth with silver to be effective in reducing malodour and exudate in leg ulcers; researchers have also suggested it was cost-effective in terms of reduced frequency of dressing change and improved healing compared to previous treatments (Millward, 1991).

Studies have shown that chronic wounds dressed with activated charcoal cloth with silver have reduced bacteria levels after 2 weeks (Verdú Soriano et al, 2004). Keriheul (2010) found an increase in signs of healing in leg ulcers (ACTISORB Silver 220) and reductions in the wound area within a week. Adverse events were low and the dressing well tolerated.

These findings are supported by other studies that have demonstrated improved healing rates in leg ulcers (Wunderlich and Orfanos, 1991). Further work on leg ulcers and pressure ulcers by Tebbe and Orfanos (1996) demonstrated a reduction in frequency of dressing change, a reduction in the time to change the dressing, a reduction in wound size, and an increase in granulation and epithelial tissue in both leg and pressure ulcers. Keriheul and Dujardin-Detrez (2003) found similar results with clinical benefit identified across a variety of clinical situations.

The ACTISORB Silver 220 instructions for use leaflet — found inside the product packaging

AILSA SHARP
*Lecturer in Adult Nursing,
Edinburgh Napier University,
Edinburgh*

TANYA BRANDON
*Plastics Nurse Specialist,
St John's Hospital, Livingston,
Edinburgh*

LORRAINE THURSBY
*Service Lead, Manual Handling
and Tissue Viability, George
Eliot Hospital NHS Trust,
Nuneaton*

— should always be referred to before use. The dressing is not absorbent and so may require a secondary absorbent dressing depending on level of exudate. ACTISORB Silver 220 can remain in place for up to 7 days. The dressing should be removed before magnetic resonance imaging or radiotherapy (Wounds UK, 2013).

In the following case studies, ACTISORB Silver 220 was demonstrated to be efficacious and easy to use, with high patient satisfaction, over a wide range of wound types:

- Friable/bleeding tissue
- Black toe/nonhealing wound
- Fungal infection of the skin.

CASE STUDIES

Case 1: Post-surgical wound with friable/bleeding tissue

Mr M is a 39-year-old man who had undergone left shoulder surgery 9 months earlier. The incision failed to heal and had become painful, leading him to seek treatment.

At presentation, the 9-month-old wound measured 5 cm × 3 cm (Figure 1a). It was bright red, with areas of hypergranulation, and would bleed when touched. Tissue was friable, and the wound edges had become dormant. Exudate levels were high and had recently increased, according to the patient. He rated his wound pain as an 8 of 10 on the visual analogue scale (VAS; 1–10). ACTISORB® Silver 220 dressing was initiated to address local infection. An absorbent soft-adherent foam dressing with an adhesive border (UrgoTul Absorb Border®, Urgo Medical) was used as a secondary dressing to manage exudate, and dressing changes were scheduled every 3 days.

At 1 week, wound size was unchanged, overgranulation was settling and signs of healing were noted. Tissue was still friable and bleeding but had improved, exudate level was low/moderate, and the patient rated his wound pain as 7 on the VAS.

The patient reported improvement in quality of life, because he could see positive improvement in the wound and felt comfortable with the dressing on. The dressing was easily applied and removed. A non-adhering silicone dressing (Adaptic Touch®; Systagenix) was used as a wound contact layer, as exudate levels had reduced. Dressing changes were scheduled every 3 days.

At week 2, the wound had reduced to 4 cm × 2.5 cm (a 33% reduction from baseline), and tissue was no longer friable/bleeding (Figure 1b). Overgranulation had settled but was still present and exudate level was minimal. The patient rated wound pain as 5, on the VAS, noting that it felt as if it were associated with the deeper muscular/bony injury. Due to continued improvement in the wound, the decision was made to continue with the dressing regimen, with dressing changes scheduled every 3 days.

At week 3, the wound measured 4 cm × 2 cm (a 47% reduction from baseline) and continued to show signs of healing and reduced overgranulation. Exudate levels remained minimal, and the patient reported pain associated with the original injury/surgery as 7 on the VAS. Given the good progress made, the dressing regimen was continued unchanged.

At week 4, the wound measured 3.7 cm × 1.6 cm (a 61% overall reduction). Overgranulation had resolved distally and further reduced proximally. The patient continued to report pain in the shoulder due to the deeper bony issues, but reported no wound-related pain. ACTISORB Silver 220 was continued to achieve complete healing.

ACTISORB Silver 220 was easy to apply and remove. It was comfortable for the patient, and both patient and clinician were happy with the results. With the dressing in place, the exudate, erythema, friable tissue and wound-associated pain resolved, overgranulation was all but eliminated, and the wound edges began moving towards healing.

“ACTISORB® Silver 220 (Systagenix) contains silver to reduce bacterial load and the dressing allows exudate to filter through, removing it from the wound surface.”

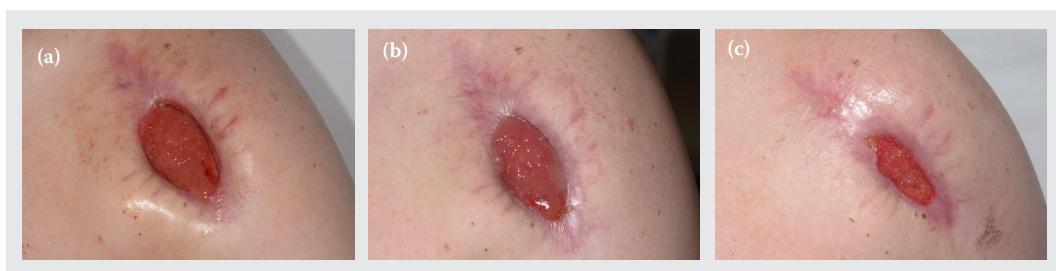

Figure 1. Mr M’s post-surgical wound with friable/bleeding tissue at (a) presentation, and (b) weeks 2 and (c) 4.

“ACTISORB® Silver 220 (Systagenix) was easy to apply and remove ... the exudate, erythema, friable tissue and wound-associated pain resolved, overgranulation was all but eliminated, and the wound edges began moving towards healing.”

Case 2: Maintenance of foot ulceration despite multiple comorbidities

Mr P is a 69-year-old man who is a heavy smoker, with emphysema, poor nutritional status, issues with excessive alcohol consumption, chronic kidney disease and recently developed bilateral lower-limb ischaemia. He had long-standing care in the community, administered by a GP, for ulcers that had endured for several years. He was admitted to hospital with respiratory issues and referred to a vascular team due to peripheral vascular disease and arterial disease. The patient had required three visits per week to his GP's surgery for dressing changes; bandages were constantly wet and smelly, and his legs were painful.

The patient presented with a mummified distal digit on the fourth toe of the right foot (2 cm × 1 cm) and 100% wet slough at the wound bed (Figure 2a). There was another ulcer on the third toe on the right foot (1.5 cm × 1.5 cm) with 100% slough to the wound bed. The second toe had deep ulceration measuring 2 cm × 2 cm, with bone exposed and 90% slough to the wound bed. Deep ulceration on the great toe measured 2 cm × 2.2 cm, with 80% slough to the wound bed. There was a 3.3 cm × 2.5 cm area of superficial ulceration on the medial dorsum and a 2 cm × 2.2 cm area of superficial ulceration on the lateral dorsum. Previous treatments included silver, honey and alginate dressings.

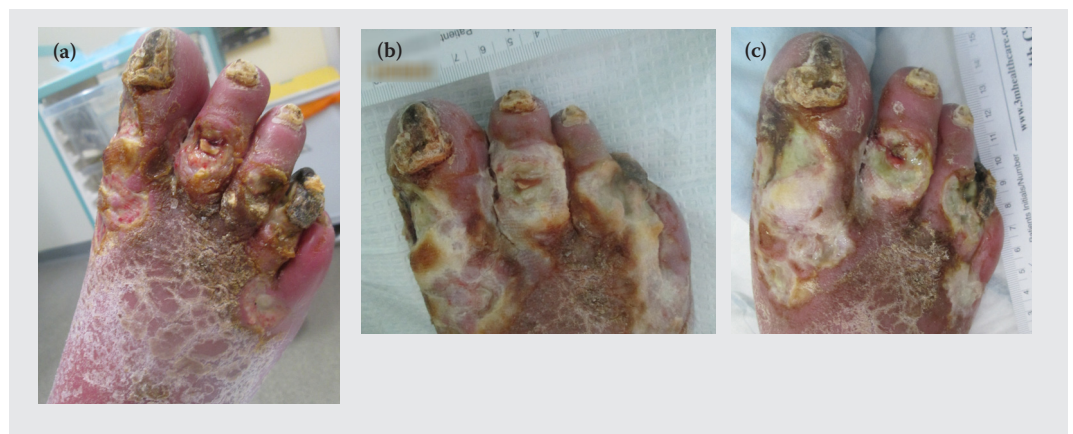
Malodour was intense and had been present for >6 weeks. The patient rated wound-related pain as 6 on the VAS. Maintaining the foot and quality of life was of the utmost importance in this non-

healing wound. To prevent further deterioration of the wounds, reduce bacterial burden and manage malodour, ACTISORB® Silver 220 was initiated. An absorbent pad was used as a secondary dressing, along with a stockinette, wool and crepe from toe to knee. Dressing changes were scheduled for every 5 days, more frequently if exudate levels required, with his practice nurse.

At week 1, the patient was readmitted for acute inpatient care due to sepsis that was urinary in origin and unrelated to the wound. He had removed the dressing prior to readmission and the wound had rapidly deteriorated due to the presence of *Pseudomonas*. Dorsum ulceration on the medial aspect had increased to 7 cm × 3 cm, and the lateral aspect to 7.5 cm × 2.5 cm; slough was thick and the exudate level was high (Figure 2b). The malodour was more intense at readmission. The mummification of fourth toe had extended (+2 cm). The bone remained marginally exposed on the second toe and palpable beneath the slough. Wound-related pain was reported as 7 on the VAS (likely due to limb deterioration and increased ischaemia); pain associated with dressing change was reported as 2.

Intravenous antibiotic therapy was initiated to address the urinary tract infection and haematuria that had caused the sepsis. An emollient was applied for skin care surrounding the ulcers. The ulcers were irrigated with saline before dressing application. ACTISORB Silver 220 was continued due to the presence of *Pseudomonas*, and the rest of the dressing regimen maintained. Mr P was also put into surgical appliance footwear. Dressing

Figure 2. Mr P's multiple foot ulcers at (a) presentation and



“ACTISORB® Silver 220 (Systagenix) was found to be easy to fold and position, and it stayed in place well over a large area.”

change was scheduled to be undertaken at the next assessment in a week.

At week 2, exudate levels and slough had reduced despite continued issues with limb ischaemia (Figure 2c). Malodour was present on dressing removal, but dissipated within 5 minutes. Despite limb ischaemia and other comorbidities that dictated the wound would be non-healing, the ulcers remained stable in size, and maceration of the surrounding skin had decreased. The patient mobilised as ischaemia-related pain allowed; there was no pain due to the wound, and pain at dressing removal was reported as 2 on the VAS. Due to the reduction in exudate he was more comfortable. Antibiotic therapy for urinary sepsis had been completed. The dressing and footwear regimen continued unchanged and an emollient was used for skin care.

The patient was discharged and no further assessments took place. However, during his inpatient stay, the dressing was found to be easy to remove and apply, and the patient found it to be comfortable. The key in this case to the clinician’s satisfaction with the overall use of the dressing was that, despite many systemic issues that were deeply problematic, there was no further deterioration of the wound.

Case 3: Fungal infection of groin skin folds

Mr B is a 56-year-old man with insulin-dependent diabetes and morbid obesity. Intertrigo of the groin had developed due to the excessive weight of the skin folds, which collected and trapped excess moisture. Before hospital admission, the patient was treated with oral antibiotics and

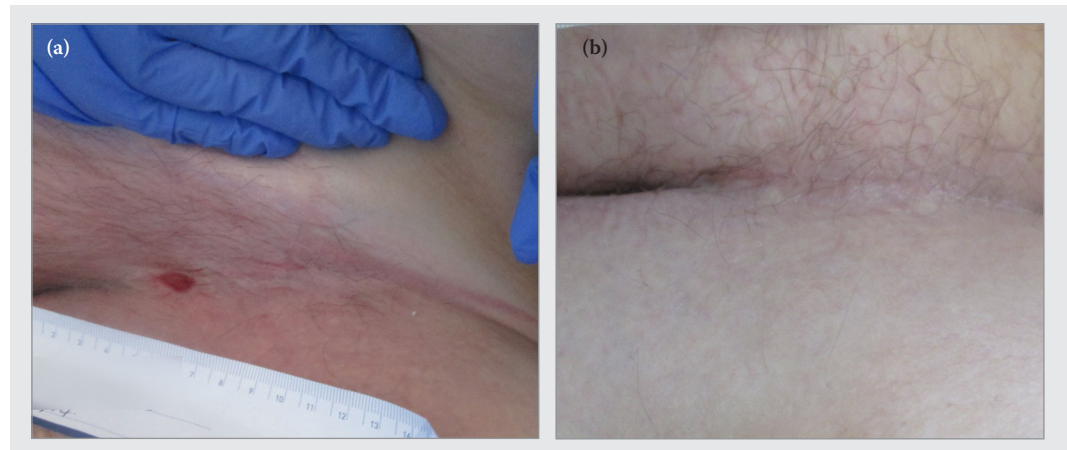
a commercial antifungal cream for extensive *Candida* colonisation and infection. After more than 4 weeks’ duration, Mr B was experiencing extreme discomfort and was embarrassed by the malodour.

On examination, it was found that the skin folds were extremely malodorous and that the antifungal cream had been collecting in the folds and exacerbating excoriation and skin breakdown. There was generalised malodour on approach to the bed space, and intense, offensive malodour when the skin folds were lifted. Dermal ulceration (1.5 cm × 1 cm) was present in the left groin and epidermal loss was present in the right groin and on the abdominal apron (Figure 3a). The patient rated the pain as 4 on the VAS.

The decision was made to use ACTISORB® Silver 220 due to its antifungal properties, while providing a soft material between the skin folds and so reducing skin-on-skin friction. Good skin hygiene was completed before application of ACTISORB Silver 220. No secondary dressing was required. The patient was encouraged to lift the skin fold and wash/cleanse with water, to avoid perfumed soaps/washes and to dry gently before changing the dressing. The dressing frequency was dictated by the ability to control odour or weekly.

At week 1, the ulceration had healed and the pain and fungal infection had resolved (Figure 3b). There was no malodour, even when skin folds were lifted. Although treatment goals had been achieved, due to concern arising from the intertrigo, it was decided to continue with ACTISORB Silver 220 as prophylaxis while ambulation improved, allowing the patient to better attend to his hygiene.

Figure 3. Mr B’s fungal infection of groin skin folds at (a) presentation and (b) healed at week 1.



Both the patient and clinician were satisfied with the way the dressing stayed in place — it was simply folded and placed deep into the skin's natural fold. The 10.5 cm × 19 cm dressing size was sufficient to cover each side of the groin, and two pieces were used on the abdominal apron. The patient reported improvement in his quality of life due to the resolution of the malodour and the ability to increase his mobility. Due to the simplicity of application and ease of use, he was able to be essentially self-caring during treatment for infection and for prophylactic treatment going forward. The skin remained healed and infection-free at discharge.

CONCLUSION

This case series evaluation shows the wide range of wounds for which the combination of activated charcoal and metallic silver can achieve treatment goals, including elimination of local infection, control of malodour and progress towards healing.

In case 1, the exudate, erythema, friable tissue and wound-associated pain resolved, overgranulation was all but eliminated, and wound edges began moving towards healing. Case 2 presented with a variety of difficult and entrenched comorbidities, but use of the dressing appeared to prevent further deterioration of the wound, which would have otherwise been expected. And case 3 demonstrated the broad antimicrobial action of the dressing, resolving a fungal infection in 1 week.

In all cases, ACTISORB Silver 220 was found to be easy to fold and position, staying in place over a variety of anatomical areas with a range of sizes. Patients were comfortable with the dressing — in one case, able to essentially self-manage — and dressing change-related pain was low across the board. Patients also reported improvements in quality of life due to resolution of malodour.

Overall, the literature and this series of case studies promote the role of an activated charcoal/metallic silver dressing as an effective option for managing local infection and malodour and aiding wound healing.

Acknowledgements: This article reports on three case studies undertaken as part of a wider case series supported by an unrestricted educational grant from Systagenix.



REFERENCES

Bale S, Tebble N, Price P (2004) A topical metronidazole gel used to treat malodorous wounds. *Br J Nurs* 13(11):S4–S11.

Fleck CA (2006) Differentiating MMPs, biofilm, endotoxins, exotoxins, and cytokines. *Adv Skin Wound Care* 19(2):77–81

Hampton S (2001) ACTISORB Silver 220: a unique antibacterial dressing. *Br J Nurs* 6(Suppl 1):17–9

Keriheul JC, Dujardin-Detrez S (2003) ACTISORB Plus 25, a review of its clinical experience based on more than 12000 various wounds. *Journal des Plaies et Cicatrisations* 8(39):3–7

Keriheul JC (2009) Charcoal combined with silver for the treatment of chronic wounds. *Wounds UK* 5(3):87–93

Keriheul JC (2010) Effect of activated charcoal dressings on healing outcomes of chronic wounds. *J Wound Care* 19(5):208–15

Leak K (2002) PEG site infections: a novel use for Actisorb Silver 220. *Br J Community Nurs* 7(6):321–5

Marsh H, Rodriguez-Reinoso F (2006) *Activated Carbon*. Elsevier, Oxford

McGrath A (2011) Overcoming the challenge of overgranulation. *Wounds UK* 7(1):42–9

Millward P (1991) Comparing treatment for leg ulcers. *Nursing Times* 87(13):70–2

Naylor W (2013) Malignant wounds. In: Flanagan M (ed.) *Wound Healing and Skin Integrity: Principles and Practice*. Wiley-Blackwell, Chichester

Slater R (2009) Percutaneous endoscopic gastrostomy feeding: indications and management. *Br J Nurs* 18(17):1036–43

Spruce P, Warriner L, Keast D, Kennedy A (2012) Exit site wounds made easy. *Wounds International* 2(3):1–6

Tebbe B, Orfanos CE (1996) Therapy of leg ulcers and decubitus ulcers with a xero-dressing: modern wound dressings with antibacterial activity. In: Hampton S (2001) ACTISORB Silver 220: a unique antibacterial dressing. *Br J Nurs* 6(Suppl 1):17–9

Thomas S (2009) *Formulary for Wound Management Products (10th edn)*. Euromed Communications, Hampshire

Thurman RB, Gerba CP (1989) The molecular mechanisms of copper and silver ion disinfection of bacteria and viruses. *CRC Critical Reviews in Environmental Control* 18(4):295–315

Verdú-Soriano J, Rueda López J, Martínez Cuervo F, Soldevilla Agreda J (2004) Effects of an activated charcoal silver dressing on chronic wounds with no clinical signs of infection. *Journal of Wound Care* 13(10):419–23

White RJ (2001) An historical overview of the use of silver in wound management. *Br J Nurs* 10(Suppl 15):3–8

White RJ (2013) Wound malodour and the role of ACTISORB Silver 220. *Wounds UK* 9(1):101–4

Wounds UK (2013) *Best Practice Statement: The Use of Topical Antimicrobial Agents in Wound Management*. Wounds UK, London

Wunderlich U, Orfanos CE (1991) [Treatment of venous ulcers cruris with dry wound dressings. Phase overlapping use of silver impregnated activated charcoal xerodressing]. *Hautarzt* 42(7):446–50 [Article in German]