

# Electroceutical therapy to manage complex leg ulcers: a case series of three patients

KEY WORDS

- ▶ Venous leg ulcers
- ▶ Electroceuticals
- ▶ Innovation
- ▶ Accel-Heal

Despite efforts to promote tissue repair, many wounds heal slowly, do not heal or deteriorate. Management of these chronic wounds is a growing problem. Innovation and cost cutting is key to current health policy and therefore clinicians should be taking advantage of emerging technologies that can improve outcomes for patients while reducing costs. Accel-Heal is an innovative electroceutical device that uses a patented synapse sequence programmed to deliver a specific series of electric energy interactions through the skin to manipulate gene expression and modify specific physiological functions in dermal tissue, improving and accelerating healing. This article examines the use of Accel-Heal in three case studies.

Venous leg ulcers (VLUs) are estimated to affect around one in 500 people in the UK. They become much more common with age and it is estimated that around two per 100 people over the age of 80 have a VLU (NHS Choices, 2014). The average time taken for a VLU to heal is 6–9 months (Briggs and Clos, 2003), with 60% present for longer than 6 months, 33% present over a 1 year (Harrison et al, 2001) and 20% present for more than 5 years (Price and Harding, 1996). Guest et al (2013) suggested that 90% of VLUs remained unhealed at 6 months and that accepted best practice (compression bandaging) is not always successful at healing VLUs.

Factors that contribute to a VLU being a complex poorly healing wound include:

- ▶ Comorbidities such as diabetes and rheumatoid arthritis, which affects small vessels
- ▶ Lifestyle, such as drug/alcohol abuse and smoking (Milic et al, 2009; Wigstone et al, 2013)
- ▶ Multiple medications (Wigstone et al, 2013)
- ▶ Age and non-concordance (Moffatt et al, 2009)
- ▶ Infection (Hurlow and Bowler, 2012)
- ▶ Pain (Cole-King and Harding, 2001, Broadhurst et al, 2003).

Depression and/or social isolation and seasonal changes also contribute to VLUs not healing (Simka, 2010). Opportunities are therefore open to innovative treatments and advanced modalities such as electroceuticals to improve

healing outcomes. One of such electroceuticals is Accel-Heal, a class IIA medical device. It is a 12-day treatment course, consisting of six 48-hour single-use units delivering a sequence of electric current through electrode pads placed on healthy skin either side of the VLU, which has been demonstrated to be effective in wound healing (Tadej et al, 2010; Taylor et al, 2011). The treatment is an adjunct treatment applied alongside the patient's standard wound therapy regimen and can be used under compression bandage.

## WHAT ARE ELECTROCEUTICALS?

Unlike the universal term 'electrical stimulation' previously used for such devices, electroceutical implies a more accurately targeted application more akin to its pharmaceutical equivalent. Neural circuits communicating via electrical impulses regulate many physiological functions, therefore it is possible to interpret the electrical language of health and disease from the level of gene expression upwards. It is now possible to inhibit or change a malfunctioning electrical pathway in order to correct a potential defect.

The tissue viability team at the Hillingdon NHS Foundation Trust has used Accel-Heal on a number of patients with complex wounds. Before the Accel-Heal product evaluation, the clinical staff and patients were made aware that Accel-Heal is not designed to heal the wound within the

LIZ OVENS  
*Clinical Service Lead Tissue Viability, Central North West London NHS Foundation Trust, Hillingdon Community Health*

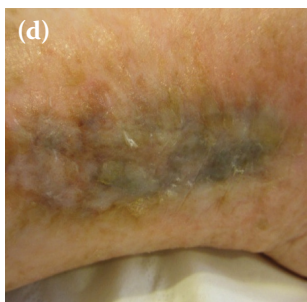
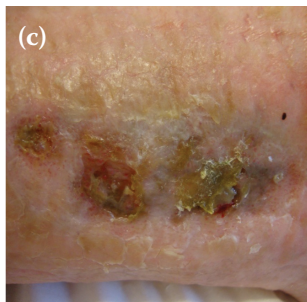
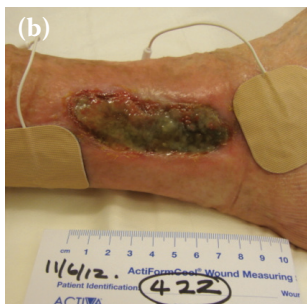
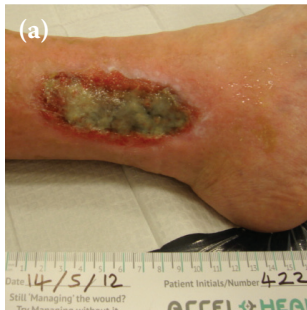

Figure 1. Case study 1: (a) The patient's wound at the start of treatment with Accel-Heal on 14 May 2012; (b) on 11 June 2012; (c) on 6 July. (d) The wound has completely healed 1 October 2012.

12-day treatment course but it aims to induce the healing process while standard care is continued.

This article features three case reports on patients using Accel-Heal with complex leg ulceration that had failed to heal adequately following the prolonged use of standard therapies for varying lengths of time, from 4 months to 2 years. All patients were assessed prior to commencement of treatment with Accel-Heal, including the recording of all relevant medical history, medication and allergies. This is relevant due to prevalence of comorbidities.

Funding for innovative treatment was approved by medicines management. Photographs and wound measurements were taken with patient consent prior to commencing therapy and at various stages throughout. When appropriate the ankle brachial pressure index (ABPI) was used (Box 1).

**CASE STUDY 1**

**Presentation**

A 92-year-old lady with recurrent VLUs. This patient had a non-healing venous ulcer at the inner side of the left leg for approximately 2 years.

**Medical history**

Bilateral hip replacements, transient ischaemic attack, emphysema, hypertension, osteoarthritis and fixed ankles bilaterally, rheumatoid arthritis, recurrent leg ulcers with persistent cellulitis, elderly and frail.

**Medication and allergies**

Levothyroxine, bendroflumethiazole, enalapril, aspirin, co-dydramol. Allergic to clarithromycin, and flucloxacillin. Tramadol intolerant.

**Current assessment and treatment prior to commencing treatment with Accel-Heal**

ABPI was measured at 1.1 for the right leg and 1.2 for the left leg, indicating venous disease. Vascular assessment had determined that the patient had venous disease caused by fixation of ankles, reducing the effect of the foot and calf pump, which was compounded by small vessel disease. High levels of pain and persistent infection prevented the use of high-compression therapy. Despite several courses of long-term antibiotics,

antimicrobial dressings, anti-gravitation methods and analgesia, the venous hypertension and oedema remained resulting in periods of wound exacerbation and failure to progress.

At the start of the treatment with Accel-Heal, the ulcer measured 13cm<sup>2</sup> (Figure 1a). The wound had 100% thick green adherent slough with malodour and periwound was inflamed.

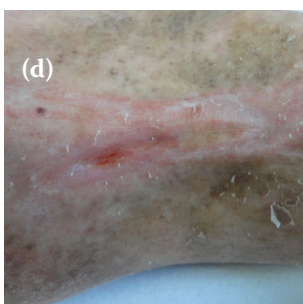
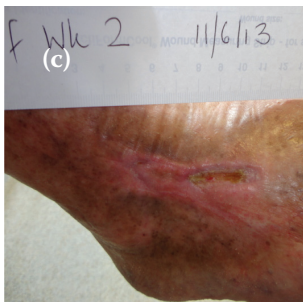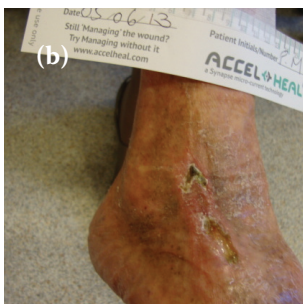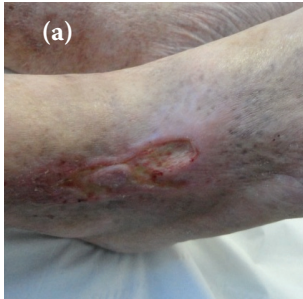The patient's pain score was 8/10 on the visual analogue scale (VAS) despite taking co-dydramol regularly. The patient had an intolerance to Tramadol. The patient's quality of life was affected reducing her mobility, causing social isolation and she often became tearful during her visits to the clinic. All other treatment options had been considered and other advanced modalities such as negative pressure wound therapy (NPWT) or larva therapy were not indicated due to the pain. Pain during dressing changes is a common complaint of NPWT (Upton et al, 2013)

**Treatment and results**

Accel-Heal treatment commenced on 14 May 2012. Previous topical primary dressings using a silver Hydrofiber and high-absorbency dressing continued with a support crepe bandage. The patient attended the clinic three times a week for dressing change and change of the unit (Accel-Heal). The treatment electrode pads were changed as required or on a weekly basis to allow the usual skin care and leg washing. On 21 May 2012, the pain score reduced to 5/10 and the

**Box 1. Ankle brachial pressure index (ABPI)**

The ankle brachial pressure index (ABPI) is the ratio of the highest ankle to brachial artery pressure. The ABPI is widely used across healthcare settings to determine safe application of compression therapy for venous leg ulcers alongside clinical judgement. An ABPI of 0.8–1.2 in combination with the type of sounds present in the vessel, and a holistic and limb assessment is considered normal (free from significant peripheral artery/vascular disease) and suitable for compression therapy, while an ABPI <0.8 may indicate some arterial disease requiring further investigation. An ABPI value that is >1.2 suggests calcification of the walls of the arteries and incompressible vessels, which may require further investigation to eliminate peripheral arterial disease.



**Figure 2. Case study 2:** (a) The patient's wound in March 2013; (b) 1 week after treatment started with Accel-Heal on 5 June 2013; (c) 2 weeks after start of treatment on 11 June. (d) The wound has completely healed by 30 July 2013.

periwound inflammation was considerably reduced. On 1 June 2012, the wound edges were advancing and new epithelial tissue was noted. Wound dimensions were approximately 11 cm<sup>2</sup> with 30% granulation tissue. At dressing change, on visual inspection the periwound was considerably less inflamed and the exudate reduced to the point where it was contained within the dressing. On assessment on 11 June, the wound dimensions remained unchanged with thick adherent slough (Figure 1b) and the primary dressing was changed to honey. Three weeks later, on 6 July (Figure 1c), the pain had reduced to 4/10, enabling the patient to tolerate reduced compression therapy of 18 mmHg.

The compression therapy was well tolerated and the wound continued to progress to full healing with evidence of good deposition of collagen (Figure 1d), which has allowed the wound to remain healed to date.

**Treatment Summary Results**

- ▶ 14 May 2012: Ulcer 13 cm<sup>2</sup>, pain level 8/10, exudate high and green
- ▶ 21 May 2012: Pain 5/10 periwound inflammation reduced
- ▶ 1 June 2012: Ulcer 11 cm<sup>2</sup>, pain 5/10, exudate moderate
- ▶ 11 June 2012: Ulcer 11 cm<sup>2</sup>, pain 4/10, exudate moderate
- ▶ 1 October 2012: Ulcer 0 cm<sup>2</sup>, pain 0/10, exudate none.

**CASE STUDY 2**

**Presentation**

A 75-year-old female presented in March 2013 with recurrent foot ulcers to the dorsum right foot that had been present for four months (Figure 2a). The patient had previous foot ulcers in 2009 with a methicillin-resistant *Staphylococcus aureus* (MRSA) infection. A vascular assessment had diagnosed stenosis in the mid-superficial femoral artery; conservative management was recommended. The patient was a smoker, with poor ankle movement, claw toes and poor mobility, poor appetite and non-concordance issues relating to analgesia and treatment options. The patient had been self-caring for her wounds with support from her brother and husband who were podiatrists.

**Medical history**

Hysterectomy, bilateral varicose vein surgery × 2, appendectomy, hypertension, curvature of spine/scoliosis, rheumatoid and osteoarthritis, bladder/vaginal repair, cholecystectomy, varicose eczema.

**Medication and allergies**

Adalat, Candesartan, paracetamol. Allergic to penicillin, elastic, latex, trimethoprim and clarithromycin.

**Current assessment and treatment prior to commencing treatment with Accel-Heal**

The patient presented with two wounds of approximately 6 cm<sup>2</sup>. The wound beds were 100% dry devitalised yellow slough and was punched out with slightly thickened rolled edges, non-advancing and periwound skin was dry and taut with keloid scar tissue present.

The patient's pain score of 8/10 on the VAS scale was described as cramp-like but the patient would only tolerate paracetamol. The ABPI was measured at 0.72 in the right leg and 0.67 in the left leg, with monophasic and dampened sounds indicating arterial disease. She had marked oedema with inverted champagne bottle-shaped legs that were hard to touch and fibrotic. The patient could not tolerate any bandages. An additional arterial duplex scan confirmed significant stenosis in the superficial femoral artery and the patient was added to a waiting list for angioplasty. Smoking cessation was discussed but the patient declined. Further screening for MRSA was negative.

A sheet gel was applied to the wound to donate fluid to the wound bed allowing better hydration and softening of the adherent slough. This reduced the pain score to 4/10 and Accel-Heal therapy was discussed with the patient since the wound did not progress. However, at the end April 2013 the patient developed a urinary tract infection along with a chest infection and wished to delay commencing Accel-Heal until these health issues were resolved.

**Treatment and results**

Treatment with Accel-Heal started on 28 May 2013 for 12 days. Wound dimensions were 6 cm<sup>2</sup>. The patient's daughter was taught to change the units every 48 hours. The team were concerned

regarding tolerance of the gel electrodes, so these were changed twice weekly and dressing regimen with the gel sheet dressing was continued to debride the wound and reduce pain. A crepe bandage to support the leg was applied but this was not tolerated. Improvement was noted within one week of Accel-Heal treatment with reduction in wound pain to 0/10 (*Figure 2b*). The patient continued to progress (*Figure 2c*) following completion of Accel-Heal treatment with healing achieved at the end of July 2013 (*Figure 2d*). In August 2013, the patient had an angioplasty to prevent recurrence as surgery is normally indicated to correct superficial venous disease and prevent ulcers from reoccurring.

**Treatment summary results**

- » 28 May 2013: Ulcer 6 cm<sup>2</sup>, pain level 8/10, dry, no exudate
- » 6 June 2013: Ulcer 6 cm<sup>2</sup>, pain 0/10, no exudate
- » 30 July 2013: Ulcer healed 0 cm<sup>2</sup>, pain 0/10, exudate none.

**CASE STUDY 3**

**Presentation**

A 56-year-old male presented on 8 April 2013. The patient had a past medical history of a fracture of the right tibia and fibula following a road traffic accident with insertion of a metal plate in 1986. The patient was an ex-smoker and suffered from anaemia, depression and back pain. He was the main carer for his mother.

**First assessment**

He developed complex wounds to the right tibial crest and medial malleolus following the development of chicken pox scabs in July 2012. Radiology in February 2013 excluded osteomyelitis. At initial assessment, ulcers were present to right tibial crest along the scar line measuring 4cm<sup>2</sup> and 1cm<sup>2</sup> and medial malleolus of the right leg measuring 5.5cm<sup>2</sup> with surrounding erythema (*Figure 3a* and *3b*). His ABPI was within normal limits (right leg 1.34, left leg 1.32), he had a pain score of 6/10 on the VAS scale and was prescribed co-codamol and ibuprofen, although he reported not taking this regularly.

The pain was assessed as being allodynia with hypersensitivity to touch. No allergies were noted.

He had been treated previously with numerous antibiotics and antimicrobial dressings. Wound swabs indicated *Enterococcus* species sensitive to amoxicillin, which was prescribed for two weeks.

**Treatment**

The team treated the wounds with a polyhexanide gel sheet to reduce bacterial burden and pain at dressing change, with a light support bandage. On 23 April 2013, the pain score was reduced to 4/10, and he was taking regular co-codamol and the wound swab was now clear following the course of antibiotics. The patient continued with various dressing treatments to reduce bacterial load and de-slough.

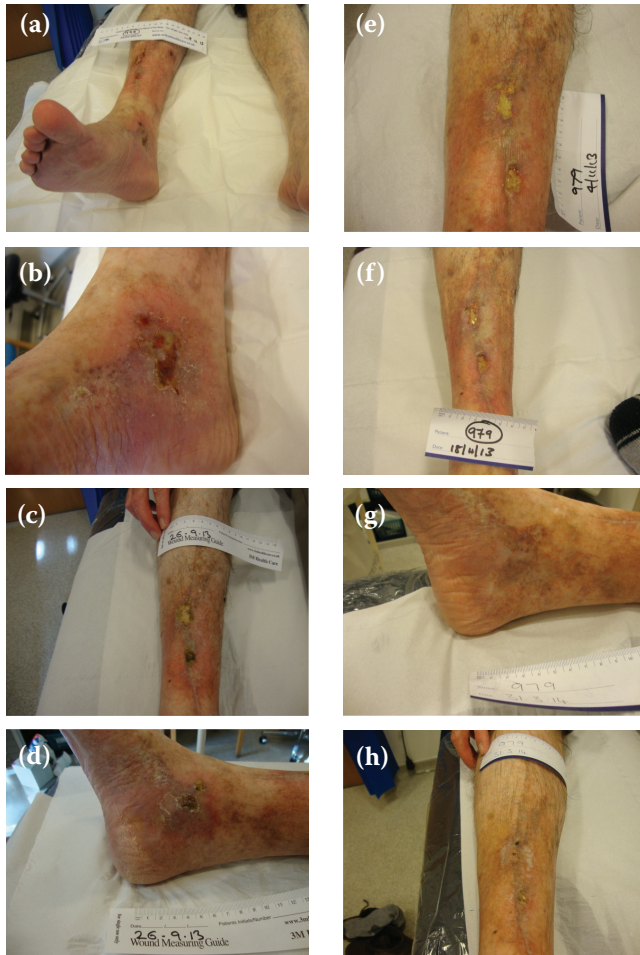
**Reassessment**

Despite an ABPI within normal limits the patient would not tolerate any compression bandage or indeed even a light crepe support bandage or 10 mmHg compression liner. The patient described these treatments as causing a “burning sensation in his leg”. He therefore only tolerated an adhesive secondary dressing and a cotton stockinette toe to knee despite regular education given by the team regarding the benefits of the bandage regimen.

The patient was frequently withdrawn when he attended clinic, with little eye contact and minimal smiling or interaction with the nursing team. He often became frustrated with the treatment regimens, particularly when no progression was noted, and he would occasionally become angry and swear at the team. Continual reassurance and listening skills from the team were needed to work with the patient and gain his trust.

The patient expressed concerns with regard to being the main carer for his mother and the increasing difficulties in managing this with his leg wounds and pain. The team signposted him to support agencies available for carers and his mother underwent a social care assessment. He had previously been prescribed antidepressants but the patient reported that these caused more anxiety and did not help.

The patient was referred to the vascular consultant. Radiology demonstrated plate screws overlying the distal right tibia at the site of the previous fracture and fusion at the fracture site between the tibia and fibula. Diagnostic



**Figure 3. Case study 3: The patient's right tibial crest (a) and medial malleolus right leg (b) on 8 April 2013; right tibial crest (c) and medial malleolus right leg (d) on 26 September 2013; right tibial crest at the start of treatment on 4 November 2013 (e) and on completion of Accel-Heal treatment on 18 November (f). Radial crest (g) and medial malleolus (h) were healed by 31 March 2014.**

ultrasound showed no deep vein thrombosis but some venous incompetence and that he would be suitable for closure of the greater saphenous vein. However, the patient declined. The vascular consultant suggested that the wounds were unlikely to heal with conservative measures and recommended referral to the plastics team. Pregabalin was prescribed to manage the pain but the patient discontinued this stating it "made him feel weird".

The patient remained negative regarding his wounds and treatment regimen and often stated that "he was fed up with all this". The team discussed a referral to the pain clinic, which again

he declined. By September 2013, there was little progress with the wounds. (Figures 3c and 3d). The pain score remained at 4/10 but he was becoming more anxious and withdrawn and angry with regard to the wound treatments/regimens, stating he just wanted the team to "chop the leg off". Use of Accel-Heal was discussed again and the patient stated he would consider this treatment option.

**Accel-Heal treatment**

Due to ongoing non-progression and the regular recurrence of infection and increasing pain, the patient consented to treatment with Accel-Heal. Treatment started on 4 November 2013. Wound dimensions to the tibial crest were 3.5cm<sup>2</sup> and 4cm<sup>2</sup> and the medial malleolus was 2.5cm<sup>2</sup> (Figure 3e). His pain score measured 8/10, down from a previous score of 4/10 on the VAS scale. The electrode pads were applied near the tibial crest wounds.

On 11 November, within 1 week of Accel-Heal treatment, the pain score was reduced to 4/10. On completing the treatment after 12 days, although no changes in wound dimensions were noted there was evidence of some collagen being laid down along the scar line (Figure 3f) and the medial malleolus wound had reduced in size to 1cm<sup>2</sup>. Shared management was undertaken with the practice nurse.

On 20 January 2014 there was significant improvement and pain was reduced to 2/10. At this point the patient felt a great improvement in his mental health and indeed he started attending clinic smiling and chatting, which was probably due to the great reduction in pain and noticeable improvement of the wounds. He attended the plastics out-patient appointment at which no intervention was indicated.

On 31 March 2014 all the wounds were healed (Figure 3g and 3h), with a small dry scab remaining to the tibial crest and no pain present. The patient was absolutely delighted with the treatment and the positive effect of Accel-Heal on his previously non-progressing wounds.

**Treatment summary results**

▶ July 2012: Assessment ulcer on right tibial crest along scar line measuring 4cm<sup>2</sup> and 1cm<sup>2</sup> and medial malleolus right leg measuring 5.5cm<sup>2</sup>

with surrounding erythema. ABPI was within normal limits; right leg 1.34, left leg 1.32. Pain score of 6/10. Polyhexanide gel sheet was used

- ▶ 23 April 2013: Pain score of 4/10, taking regular co-codamol
- ▶ 4 November 2013: Treatment with Accel-Heal started. Wound dimension of Tibial crest were 3.5 cm<sup>2</sup> and 4 cm<sup>2</sup>, medial malleolus was 2.5 cm<sup>2</sup>. Pain score of 8/10
- ▶ 11 November 2013: Pain score reduced to 4/10
- ▶ 20 January 2014: Pain score of 2/10. Significant improvement in patient's mental health so he started regularly attending the clinic
- ▶ 31 March 2014: All the wounds were healed.

### CONCLUSION

Not only do indolent wounds cause many challenges for healthcare professionals and huge cost pressures, they cause misery, pain and reduce patients' wellbeing. Using Accel-Heal in association with standard treatment, which when previously used alone proved to ineffective, has been shown in these three cases to promote significant changes in these complex wounds.

The treatment is well tolerated by the patients, easy to apply and is used alongside the patient's standard treatment. Signs and symptoms such as pain, exudate and malodour were demonstrated to improve quickly after commencing the treatment. Given that without using Accel-Heal these wounds were continuing in their complex state, a strong association with an improved outcome and the use of Accel-Heal seems likely. WUK

### REFERENCES

- Briggs M, Closs SJ (2003) The prevalence of leg ulceration: a review of the literature. *Wound management Association Journal* 3(2): 14–20
- Broadhurst E, Petrie KJ, Alley PG Booth RJ (2003) Psychological stress impairs wound repair following surgery. *Psychosom Med* 65(5):865–9
- Cole-King A, Harding KG (2001) Psychological factors and delayed healing in chronic wounds. *Psychosom Med* 63(2):216–20
- Guest JF, Charles H, Cutting K (2013) Is it time to re-appraise the role of compression in non-healing venous leg ulcers? *J Wound Care* 22(9): 453–60
- Harrison MB, Graham I, Friedberg E, Lorimer K, Vandeveld-Coke S (2001) Regional planning study. Assessing the population with leg and foot ulcers. *Can Nurse* 97(2):18–23
- Hurlow J, Bowler P (2012) Potential implications of biofilm in chronic wounds: a case series. *J Wound Care* 21(3):109–10, 112, 114 passim
- Milic DJ, Zivic SS, Bogdanovic DC, Karanovic ND, Golubovic ZV (2009). Risk factors related to the failure of venous leg ulcers to heal with compression treatment. *J Vasc Surg* 49(5): 1242–7
- Moffatt C, Kommala D, Dourdin N, Choe Y (2009). Venous leg ulcers: patient concordance with compression therapy and its impact on healing and prevention of recurrence. *Int Wound J* 6(5):386–93
- NHS Choices (2014) *Venous Leg Ulcer*. Available at: <http://www.nhs.uk/conditions/leg-ulcer-venous/pages/introduction.aspx> (accessed 30.05.2014)
- Price P, Harding K (1996) Measuring health-related quality of life in patients with chronic leg ulcers. *Wounds: A Compendium of Clinical Research and Practice* 8:91–4
- Simka M (2010) Seasonal variations in the onset and healing rates of venous leg ulcers. *Phlebology* 25(1):29–34
- Tadej M, Young SI, Hampton S. (2010) Accel-Heal: A new therapy for chronic wounds. *J Comm Nurs* 24(5):16–20
- Taylor RR, Sladkevicius E, Guest JF (2011) Modelling the cost effectiveness of electrical stimulation therapy in non-healing venous leg ulcers. *J Wound Care* 20(10):464–72
- Wigstone C, Hassan S, Turvey S et al (2013) Impact of medication and lifestyle factors on wound healing: A pilot study. *Wounds UK* 9(1): 22–8
- Upton D, Stephens D, Andrews A (2013) Patients' experiences of negative pressure wound therapy for the treatment of wounds: a review. *J Wound Care* 22(1):24–39

## Writing for Wounds UK

Wounds UK welcomes a range of articles relating to the clinical, professional, and educational aspects of wound care. If you have written an article for publication it can be submitted online at <http://www.epress.ac.uk/wuk/webforms/author.php>

If you are interested in writing for us and would like to discuss an idea for an article, please contact the managing editor, Edda Hendry on 0207 960 9612 or email [edda.hendry@woundsgroup.com](mailto:edda.hendry@woundsgroup.com)

