

# The effects of smoking on wound healing

## KEY WORDS

- ▶ Collagen
- ▶ Fibroblasts
- ▶ Necrosis
- ▶ Nicotine
- ▶ Smoking

Cigarette smoking is a key risk factor for poor wound healing, with a greater risk of infection and scarring. The various tobacco-derived chemicals — including nicotine — are detrimental to tissue oxygenation and the immune response, affecting leukocytes and fibroblasts, and leading to necrosis, inadequate microbial eradication and poor collagen production; resulting in low-tensile wound strength. This article examines the steps that healthcare practitioners should take when treating and managing individuals with wounds who smoke. Smokers should be identified with biochemical monitoring and then counselled about the detrimental effects of smoking. They should be advised about the use of pharmacotherapy, such as nicotine replacement therapy, and assisted to attend specialist support facilities provided by the NHS and pharmacies.

Smoking is an important and preventable lifestyle factor that affects both the rate and quality of wound healing, and it significantly increases the risk of postoperative, wound-related complications (Manassa et al, 2003). Since the 1940s, there has been increasing evidence that smoking has a negative impact on both wound healing and tissue repair (Sorensen, 2012), with longer-term complications, such as fistulas and incisional hernia, linked to smoking (Sorensen et al, 2005).

Many investigations have reported that smokers have more postoperative complications than non-smokers (Kean, 2010). For example, in patients undergoing elective abdominoplasty, 48% of smokers were found to experience problems with necrosis, infection or skin sloughing, compared with only 15% of non-smokers (Manassa et al, 2003). In an investigation into elective breast surgery, smoking was shown to increase the risk of mastectomy flap and abdominal wall necrosis following flap reconstruction, with a significant increase in wound healing problems following reduction mammoplasty (Chan et al, 2006).

The problems with smoking are especially profound following aesthetic surgery. Smokers undergoing facelifts were found to suffer more likely from skin slough, had significantly higher overall complication and tissue necrosis rates, and often required further surgery (Rees et al, 1984).

A randomised controlled trial (RCT) examining the effects of smoking on wound healing complications involved 78 healthy volunteers with uniform elective incisional wounds. The results showed a higher rate of wound infection in the current smoking group, with 12% of wounds infected compared with only 2% of wounds in the never-smoking group. There was also a significant difference in wound dehiscence, with 12% of the smokers' wounds breaking down in the absence of infection, compared with no dehiscence in the non-smokers. There were no wound-healing differences between the abstaining smokers and the continuing smokers after 4, 8 or 12 weeks (Sorensen et al, 2003).

These complications, in turn, result in longer hospital stays, higher rates of intensive care unit admission, greater need for repeat surgery and higher overall cost of care. Smoking at the time of surgery is also associated with inferior long-term surgical outcomes and decreased overall patient satisfaction with the procedure (Khullar and Maa, 2013). These effects also have serious financial implications during the first year after hospital discharge (Warner et al, 2014).

## TOBACCO SMOKE CONSTITUENTS

Cigarette smoke is a heterogenous mix of thousands of compounds that are generated by

***“Nicotine is the addictive substance in tobacco, and it is a powerful neurotoxin, stimulating nicotine receptors in many areas of the brain, inducing relaxation and increased cognitive function.”***

the burning of tobacco leaves. The chemicals created are divided into two phases — the gaseous phase and the particulate phase. The gaseous phase consists of volatile, small molecular weight chemicals, which are inhaled and partially exhaled, producing ‘second-hand’ smoke. The particulate phase, often called tar, is made up of large molecular weight compounds and contains many of the carcinogens and high molecular weight toxins associated with the damaging effects of cigarette smoke (Talhout et al, 2011).

The gaseous phase includes carbon monoxide, which is absorbed into the blood stream, and then attaches to the haemoglobin to form carboxyhaemoglobin that reduces the oxygen-carrying ability of the blood. Cancer-forming compounds, such as nitrosamines, are present in this phase, along with nicotine. Nicotine is the addictive substance in tobacco, and it is a powerful neurotoxin, stimulating nicotine receptors in many areas of the brain, inducing relaxation and increased cognitive function.

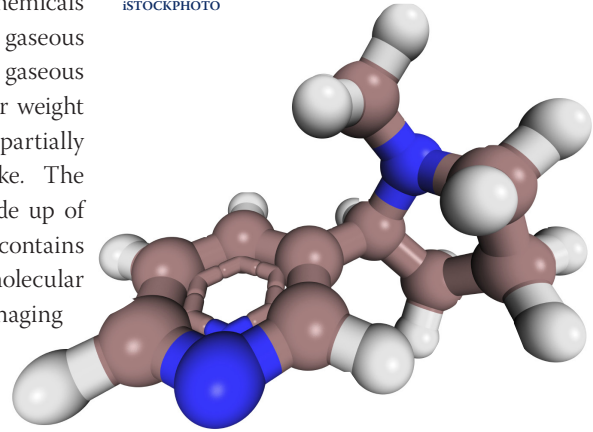
Present in both phases are short-lived, but highly reactive, free radicals — compounds such as hydrogen peroxide, superoxides and hydroquinines — that have the energy to damage macromolecules, such as DNA, and lipids and specifically polymers, which are the structural building blocks of connective tissue and fibres, such as collagen (Ortiz and Grando, 2012).

While it is difficult to identify every effect of smoking on wound healing, the main toxic components of interest are nicotine, carbon monoxide and hydrogen cyanide (Campanile et al, 1998). Wounds require an adequate circulating blood supply to receive the oxygen, various nutrients and chemicals required in the complex healing process (Enoch et al, 2006).

### NICOTINE

In cells and tissues, nicotine (*Figure 1*) causes vasoconstriction, increased platelet adhesion (resulting in thrombotic microvasculature occlusion) and reduced proliferation of keratinocytes, fibroblasts and macrophages (Campanile et al, 1998). Nicotine acts directly on many of these cell types through cholinergic nicotinic receptors in the cell membrane.

ISTOCKPHOTO



**Figure 1. A nicotine molecule (C<sub>10</sub>H<sub>14</sub>N<sub>2</sub>)**

Circulating nicotine has an inhibitory effect on keratinocyte migration distance (Zia et al, 2000) and in wounds that lack a protective epidermal barrier, it decreases the number and activity of the immune cells, which increases the risk of contamination and local infection (Hart, 2002).

Paradoxically, Morimoto et al (2008) found that while high and chronic concentrations of nicotine impaired wound healing, low concentrations of topically applied nicotine actually improved healing, by promoting angiogenesis. Although this seems counterintuitive, it may offer a potential for a new approach to wound therapy, but the detrimental effect of high and chronic concentrations of nicotine may not balance the potential for faster healing.

### LEUKOCYTES

In normal wound healing, inflammation attracts cells to the wound site via a cascade process of chemical messengers and interactions (Hart, 2002). Neutrophils, monocytes and T-lymphocytes remove cellular debris and bacteria — thus reducing the chance of infection — creating an environment that is ready for the synthesis of new tissue within the wound (Hart, 2002). Neutrophils and monocytes defend against wound infection by oxidative killing of bacteria by the effects of free radicals or reactive oxygen species (ROS). An RCT involving a cohort of 70 healthy volunteers to examine the effect of smoking on neutrophil and monocyte oxidative burst activity found bacteriocidal potential was 50% and 68% less in

***“If, then, smoking is such an important factor contributing to slow wound healing, as well as an increased risk of infection, then all smokers should be identified for specialist treatment.”***

smokers than in non-smokers, respectively; the effect being reversible as seen following smoking cessation (Sorensen et al, 2004).

#### **FIBROBLASTS**

During the early stages of wound healing, there is a complex, co-ordinated growth of tissue, with the migration of fibroblasts, deposition of the extracellular matrix, the formation of granulation tissue and a new epithelial layer is created (Enoch and Leaper, 2005). The morphology and mobility of fibroblasts are affected by smoking, even at low levels of exposure, with changes to the secretion of adhesion molecules (Wong and Martins-Green, 2004). In addition, these abnormal cells are allowed to persist by stress response proteins that regulate cell survival. This results in the build up of abnormal fibrous tissue, which contributes to slow, poor wound healing with a tendency toward scarring (Wong and Martins-Green, 2004).

#### **COLLAGEN**

The strength and progress of a healing wound largely depends on the structure and integrity of mature collagen. This is determined by adequate perfusion and oxygenation at the wound bed for it to be deposited and remodelled (Jorgensen et al, 1998). A building block of collagen is the amino acid hydroxyproline and smokers have been shown to have less available hydroxyproline, and this appears related to the level of smoking as measured by cigarette consumption (Jorgensen et al, 1998). This lack of collagen formation in the smokers' wounds equates to less tensile wound strength, and may be a potential cause of the increased incidence of wound dehiscence in smokers' postoperative wounds (Sorensen et al, 2003).

Fibroblasts and collagen production are affected by ROS and cigarette smoke is a highly concentrated source of these free radicals. The natural occurrence of ROS is tightly controlled by dietary and synthetic antioxidants. Smokers generally have a low dietary intake of antioxidant vitamins and yet have a high ROS assault. This imbalance is important as it disrupts protein function, as well as enhances and perpetuates chronic inflammation, which disturbs processes involved in wound healing. Targeting oxidative

stress in inflammatory skin conditions may reduce infections and assist fibroblast and collagen production (Wagener et al, 2013).

#### **IDENTIFICATION OF SMOKERS**

If, then, smoking is such an important factor contributing to slow wound healing, as well as an increased risk of infection, then all smokers should be identified for specialist treatment. But there is strong evidence that many smokers feel compelled to misrepresent their current status (Gorber et al, 2009). A high percentage of patients undergoing elective surgery have been shown to deny their habit, with levels varying from 4% (Coon et al, 2013) to 26% (Payne and Southern, 2006), depending on how much advice been given to the patient about smoking and any policy to restrict treatment to smokers.

There is also a low level of awareness among patients about the effects of smoking on wound healing with one study reporting only 40% of patients surveyed had any knowledge that smoking was detrimental to postoperative recovery (Webb et al, 2013).

Self-reported smoking is widely accepted as prone to bias and false reporting so there is an increasing use of simple biochemical tests to identify and quantify smoking habit. A well-established method is expired-air carbon monoxide (eCO) levels. Simple handheld monitors provide measurements of tobacco use, but CO is not specific to tobacco, being generated by traffic exhausts and faulty domestic heaters. Also, eCO is a by-product of carboxyhaemoglobin, which as a short half-life (3 hours), meaning eCO is only monitoring smoking habit over a 6–8 hour period (Christenhusz et al, 2007). A more sensitive and specific test is cotinine, a breakdown product of nicotine, which can be detected in urine or saliva and can be carried out using 5-minute point of care tests (Cope et al, 2012). This can monitor smoking for up to 3 days, but by detecting cotinine, it will also test positive in anyone using nicotine replacement therapy (NRT).

Cotinine measurements have been shown to be a more accurate method of monitoring the effects of smoking on wound healing, with one investigation reporting that smokers who experienced wound-healing problems had higher levels of urinary

*“Trials investigating smoking cessation and wound healing have found universal improvements in reducing infection rates, complications and speed of wound healing.”*



**Figure 2. Smoking is a risk factor for postoperative complications, such as pneumonia, infections and impaired wound healing. These can be reduced by pre-operative stop-smoking intervention 6 to 8 weeks before surgery.**

cotinine than the smokers who healed without complication (Bartsch et al, 2007).

### **HELP TO QUIT**

Once identified, smokers should be instructed by specially trained nurses about the damaging effects of smoking on wound healing and the possibility of tissue necrosis, infection or skin sloughing. The patient should also be encouraged to attend the local smoking cessation service for more general support on how to quit. Attendance can be improved by booking an appointment with the clinic and the clinician stressing to the patient this is an essential part of their treatment.

The smoking cessation services usually involve group sessions with advice about NRT. This should ideally involve a slow-release formula, such as a patch in combination with a rapid-release form, such as a gum or lozenge, but patients should be told not to exceed the recommended course of treatment, as there are cases of people becoming addicted to using NRT. There are alternative non-nicotine pharmaceutical aids to quitting, notably varenicline (Champix®, Pfizer) or bupropion (Zyban®, GlaxoSmithKline), both of which have shown promising clinical results and should be considered as an alternative.

A new tool has emerged as a possible means of reducing tobacco consumption and that is the electronic or e-cigarettes. These are currently

unregulated and are sold over the counter as an alternative source of nicotine, but there is little knowledge of the long-term effects of these products.

Good advice about pharmaceutical aids and smoking cessation is available at pharmacies, which have been shown to be a useful source of behavioural smoking cessation advice (Taskila et al, 2012). Patients should also be directed to the NHS Smokefree website (<http://smokefree.nhs.uk>) and also to the telephone helpline.

Trials investigating smoking cessation and wound healing have found universal improvements in reducing infection rates, complications and speed of wound healing (*Figure 2*). These are realistic to implement and are cost-effective; resulting in reduced hospital stays and cheaper follow-up care (Møller et al, 2006).

### **CONCLUSION**

It must be recognised that smoking is detrimental to wound healing and must not go unchallenged or neglected. The identification and monitoring of smoking habit and the intervention at every opportunity to get smokers to quit or to consider doing so should not be left to others. There is no controversy in correcting hypertension, uncontrolled diabetes and various heart conditions in order to decrease the risk of postoperative complications and poor wound healing. Smokers

should be enrolled into an effective treatment programme to optimise surgical outcomes and subsequent wound healing (Haney et al, 2014). **WUK**

## REFERENCES

- Bartsch RH, Weiss G, Kastenbauer T et al (2007) Crucial aspects of smoking in wound healing after breast reduction surgery. *J Plast Reconstr Aesthet Surg* 60(9): 1045–9
- Campanile G, Hautman G, Lotti T (1998) Cigarette smoking, wound healing, and face-lift. *Clin Dermatol* 16(5): 575–8
- Chan LK, Withey S, Butler PE (2006) Smoking and wound healing problems in reduction mammoplasty: Is the introduction of urine nicotine testing justified? *Ann Plast Surg* 56(2): 111–5
- Christenhusz L, De Jongh F, Van Der Valk P et al (2007) Comparison of three carbon monoxide monitors for determination of smoking status in smokers and nonsmokers with and without COPD. *J Aerosol Med* 20(4): 475–83
- Coon D, Tuffaha S, Christensen J, Bonawitz SC (2013) Plastic surgery and smoking: a prospective analysis of incidence, compliance, and complications. *Plast Reconstr Surg* 131(2): 385–91
- Cope GF, Wu HHT, O'Donovan GV, Milburn HJ (2012) A new point of care cotinine test for saliva to identify and monitor smoking habit. *Eur Respir J* 40(2): 496–7
- Enoch S, Grey JE, Harding KG (2006) ABC of wound healing - Recent advances and emerging treatments. *Br Med J* 332(7547): 962–5
- Enoch S, Leaper DJ (2005) Basic science of wound healing. *Surgery* 23(2): 37–42
- Gorber SC, Schofield-Hurwitz S, Hardt J et al (2009) The accuracy of self-reported smoking: A systematic review of the relationship between self-reported and cotinine-assessed smoking status. *Nicotine Tob Res* 11(1): 12–24
- Hart J (2002) Inflammation 1: its role in the healing of acute wounds. *J Wound Care* 11(6): 205–9
- Haney M, Löfvenberg R, Svensson O (2014) Optimize perioperative health and begin with insistence on pre-operative smoking cessation. *Acta Anaesthesiol Scand* 58(2): 133–4
- Jorgensen LN, Kallehave F, Christensen E et al (1998) Less collagen production in smokers. *Surgery* 123(4): 450–5
- Kean J (2010) The effects of smoking on the wound healing process. *J Wound Care* 19(1): 5–8
- Khullar D, Maa J (2012) The impact of smoking on surgical outcomes. *J Am Coll Surg* 215(3): 418–6
- Manassa EH, Hertl CH, Olbrisch RR (2003) Wound healing problems in smokers and nonsmokers after 132 abdominoplasties. *Plast Reconstr Surg* 111(6): 2082–7
- Møller AM, Kjellberg J, Pedersen T (2006) Health economic analysis of smoking cessation prior to surgery – based on a randomised trial. *Ugeskr Laeger* 168(10): 1026–30
- Morimoto N, Takemoto S, Kawazoe T, Suzuki S (2008) Nicotine at a low concentration promotes wound healing. *J Surg Res* 145(2): 199–204
- Ortiz A, Grando SA (2012) Smoking and the skin. *Int J Dermatol* 51(3): 250–62
- Payne CE, Southern SJ (2006) Urinary point-of-care test for smoking in the pre-operative assessment of patients undergoing elective plastic surgery. *J Plast Reconstr Aesthet Surg* 59(11): 1156–61
- Rees TD, Liverett DM, Guy CL (1984) The effect of cigarette smoking on skin-flap survival in the face lift patient. *Plast Reconstr Surg* 73(6): 911–5
- Sorensen LT, Karlsmark T, Gottrup F (2003) Abstinence from smoking reduces wound infection: a randomized controlled trial. *Ann Surg* 238(1): 1–5
- Sorensen LT, Nielsen HB, Kharazmi A, Gottrup F (2004) Effect of smoking and abstinence on oxidative burst and reactivity of neutrophils and monocytes. *Surgery* 136(5): 1047–53
- Sorensen LT, Hemmingsen UB, Kirkeby LT et al (2005) Smoking is a risk factor for incisional hernia. *Arch Surg* 140(2): 119–23
- Sorensen LT (2012) Wound healing and infection in surgery: the pathophysiological impact of smoking, smoking cessation, and nicotine replacement therapy. *Ann Surg* 255(6): 1069–79
- Talhout R, Schulz T, Florek E et al (2011) Hazardous compounds in tobacco smoke. *Int J Environ Res Public Health* 8(2): 613–28
- Taskila T, MacAskill S, Coleman T et al (2012) A randomised trial of nicotine assisted reduction to stop in pharmacies - the redpharm study. *BMC Public Health* 12: 182
- Warner DO, Borah BJ, Moriarty J et al (2014) Smoking status and health care costs in the perioperative period. *JAMA Surg* 149(3): 259–66
- Wagener FADTG, Carels C, Lundvig DMS (2013). Targeting the redox balance in inflammatory skin conditions. *Int J Mol Sci* 14(5): 9126–67
- Webb AR, Robertson N, Sparrow M (2013) Smokers know little of their increased surgical risks and may quit on surgical advice. *ANZ J Surg* 83(10): 753–7
- Wong LS, Martins-Green M (2004) First hand cigarette smoke alters fibroblast migration and survival: implications for impaired healing. *Wound Repair Regen* 12(4): 471–84
- Zia S, Ndoye A, Lee TX et al (2000) Receptor-mediated inhibition of keratinocyte migration by nicotine involves modulations of calcium influx and intracellular concentration. *J Pharmacol Exp Ther* 293(3): 973–81