

Pilonidal sinus wounds: Successful use of the novel negative pressure wound therapy device PICO™

KEY WORDS

- ▶ Negative pressure wound therapy
- ▶ PICO
- ▶ Pilonidal sinus disease

PICO™ (Smith & Nephew) is a novel device that delivers negative pressure wound therapy via a negative pressure dressing powered by a small battery pack. This provides a discreet alternative for patients requiring the therapy. This article describes the use of PICO in treating the challenging wounds that follow excision of pilonidal sinus and demonstrates the suitability of the device for use in the natal cleft.

Negative pressure wound therapy (NPWT) is an advanced wound therapy that speeds healing by applying sub-atmospheric pressure to the wound bed (Hunter et al, 2007). A Cochrane review of the supporting evidence for NPWT reported mixed results (Ubbink et al, 2008), however there are more than 1000 peer-reviewed case reports describing its use and effectiveness (Vig et al, 2011) and this has promoted an increase in its use.

CASE REPORT DEVICE

PICO™ (Smith & Nephew, Hull) is a small, portable product that has been developed as an adjunct to traditional NPWT systems. Unlike the original systems, PICO does not have a canister or pump, but uses a negative pressure dressing powered by a battery pack. The unobtrusive design of the device makes it very acceptable to patients. The negative pressure dressing is capable of holding 150ml of exudate, which, combined with the vapour permeability of the dressing, negates the need for a canister. The negative pressure is preset at -80mmHg and the small battery pack runs on two AA lithium batteries and weighs just 70g (Figure 1).

As with the pump systems, the success of the therapy is dependent upon achieving a good seal around the dressing which is aided by the use of additional adhesive tapes. The battery pack is simple to operate, with an on/off button and lights that indicate whether there is a leak or low battery. Dressings generally require changing twice a week, providing exudate levels do not exceed the capacity of the dressing. If exudate is low however, the dressing can be left in place for a week.

Mode of action

Sub-atmospheric pressure has been shown to cause a vasodilation that improves the blood flow to the treated area (Banwell and Musgrave, 2004). This enhances oxygenation and the delivery of essential blood cells such as cytokines, growth factors and fibroblasts to the wound (Kamolz et al, 2004). Coupled with the negative pressure, a stimulation of cell growth which contributes to faster healing is seen (Armstrong et al, 2005). The effective exudate management reduces oedema within the tissues which can inhibit healing (Kilpadi and Cunningham, 2011). Some bacteria is thought to be removed in the exudate but, perhaps more importantly, the wound is protected from external bacteria.

A prospective, non-comparative multicentre clinical trial demonstrated that a continuous negative pressure was maintained at the wound

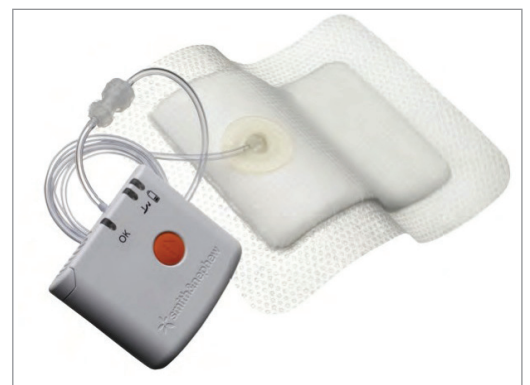

Figure 1. The lightweight and unobtrusive design of the PICO™ (Smith & Nephew) device makes it very acceptable to patients.

SUE MURPHY
*Tissue Viability Specialist Nurse,
Wound Care Service, Bristol
Community Health CIC, Bristol*

GAIL POWELL
*Clinical Specialist Nurse,
Wound Care Service, Bristol
Community Health CIC, Bristol*

interface using PICO (Hudson et al, 2013). Although this was a small study on 20 wounds of different types (either wounds that were healing by secondary intention or incisional wounds), the results were positive, with 95% of wounds closed or progressing to closure after two weeks. As a relatively new concept, more clinical studies and case reports are important to demonstrate where PICO may be used effectively rather than the traditional NPWT pump system.

The additional benefits in using PICO are its size and weight, which allows the patient to receive the therapy discreetly. Patients have reported that the size of the pump and potential noise usually associated with NPWT can be difficult to endure and has a negative impact on quality of life during use of the therapy (Mendonca et al, 2007). This can be particularly pertinent to certain groups of patients, such as those affected by pilonidal sinus disease, who are often young and either studying or working. The case reports in this article demonstrate the successful use of PICO in the management of patients post-operatively following excision of pilonidal sinus disease.

PILONIDAL SINUS

Pilonidal sinus disease is characterised by an abscess in the natal cleft (between the buttocks) with sinus formation often resulting from blocked hair follicles (Timmons, 2007). The disease is more prevalent in males than females, estimated at a ratio of four men to one woman, and usually affects those between the ages of 19 and 40 (Harris et al, 2012). Treatment requires surgical excision followed by primary closure or healing by secondary intention (Millar and Harding, 2003). Infection and healing is often problematic post-operatively, due to either bacteria remaining in the tissue or bacterial contamination due to the close proximity to the anus. The periwound skin in the natal cleft often contains bacteria and the surrounding hair can trap faeces and other debris which can potentially contaminate the open wound (Harris and Holloway, 2012).

CASE REPORT ONE

A 50-year-old man underwent elective surgical excision of a pilonidal sinus that was left to heal by secondary intention. The resulting cavity required

daily dressings due to the exudate levels, proximity to the anus and patient comfort. Modern dressings can often be left longer, however individual assessment and clinical judgement is important in deciding the duration. He was allowed to shower at home before attending for the dressing change, which is standard practice.

The wound initially progressed with a hydrofiber® (ConvaTec) dressing, but was observed to have become static so he was referred to a specialist wound care service for assessment.

Wound assessment

On assessment the wound was of 12 weeks duration and had been static for 4 weeks. The wound was photographed and measured 7cm long and 1.5cm wide. The granulation tissue was of poor quality, being friable and bleeding easily. The patient reported considerable pain which he rated at 8–10 using a numerical analogue scale (World Union of Wound Healing Societies, 2004). Hair growing from the wound edges and into the wound was acting as a foreign body, causing an inflammatory response that inhibited wound healing (Miller and Harding, 2003). There was no cellulitis, but there were signs of bacterial burden, such as pain, friable tissue and stasis of wound healing (Percival and Cutting, 2010).

Treatment

Attention to hygiene was paramount and it was important that the hair was shaved away from the wound margins. The Delphi panel recommends shaving the natal cleft at least weekly in a 5cm wide strip extending at least 2.5cm from all edges of the wound, from the anal verge to the presacrum, to remove all hair in the area between the distal wound of the anus (Harris and Holloway, 2012).

An ACTICOAT™ Flex 3 silver dressing (Smith & Nephew) was prescribed as an antimicrobial to be applied three times a week. After 2 weeks, the wound had reduced in length by 2cm, and now measured 5cm long. The pain had greatly reduced and was rated at 1–2 on a numerical analogue scale. ACTICOAT Flex 3 was continued for a further 2 weeks. On review the wound had once again become static and still measured 5cm × 1.5cm (Figure 2).

“The additional benefits in using PICO™ (Smith & Nephew) are its size and weight, which allows the patient to receive the therapy discreetly.”

“Despite attention to hygiene and removal of hair, there remains a risk of faecal contamination of the wound due to proximity to the anus.”

Despite attention to hygiene and removal of hair, there remained a risk of faecal contamination of the wound due to proximity to the anus. This was considered as a possible contributory factor to the delayed wound healing. Using PICO would prevent any further contamination and stimulate healing.

The dressing is also flexible and moulded into the natal cleft avoiding the friction and shear (Harris et al, 2012). The patient found the dressing very acceptable, he had been required to return to work and therefore the therapy being discreet was important to him. The dressing changes also reduced to twice weekly which was beneficial for both the patient and the nurses.

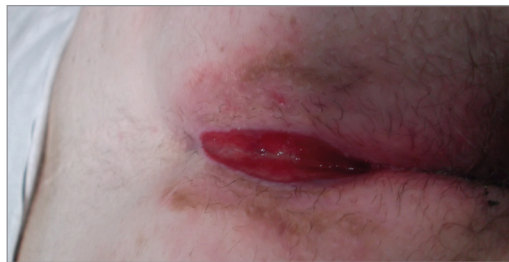

Figure 2. Using a silver dressing initially reduced wound size, but after a further 2 weeks, the wound had become static and had not reduced in size any further.

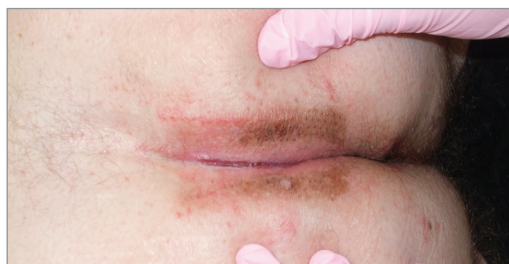

Figure 3. The patient was reviewed after 3 days of PICO™ (Smith & Nephew) use and there was a marked reduction in wound size and clear signs of epithelialisation.

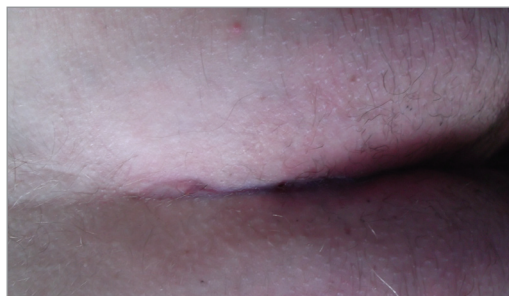


Figure 4. The wound remained completely healed 2 weeks after cessation of PICO™ (Smith & Nephew) therapy.

The patient was reviewed 3 days later and progress was outstanding (Figure 3). There was a marked reduction in wound size and clear signs of epithelialisation. PICO was reapplied for another 4 days and on review was healed. At a further check 2 weeks later the wound remained healed (Figure 4).

CASE REPORT 2

A 20-year-old man presented to the wound care service following a move to the area to commence university studies. He had undergone a surgical excision of a pilonidal sinus a year previously and despite regular dressing interventions he reported that his wound had failed to heal.

Assessment

The wound was photographed and measured 7 cm long and 2.5 cm wide. The granulation tissue was of poor quality, friable and bleeding easily (Figure 5). There were pockets in the tissue at either end of the wound which extended a further 1 cm deep and there was bridging at the base of the wound. These were all signs suggesting bacterial burden and inflammation (Harris et al, 2012). The patient reported considerable pain which he rated at 8–10, using a numerical analogue score, and assessment was difficult due to this.

There was a large amount of hair in the base of the wound and at the wound edges contributing to the inflammatory response inhibiting wound healing (Miller and Harding, 2003). A swab was taken and antibiotics were commenced as, although cellulitis was not present, friable tissue, bridging in the wound bed, pain and increase in wound size are considered indications of infection requiring antibiotics (Harris et al, 2012).

Treatment

Hair was shaved away from the wound margins and at every dressing change hair was lifted from the wound bed. This became easier as the pain lessened. Management was difficult due to the patient's university commitments and, therefore, Flaminal® Forte (Crawford Healthcare, Knutsford, Cheshire), an antimicrobial gel, was considered the best option as the patient could apply this himself after a shower each day.

The condition of the wound bed improved and the width decreased to 1 cm, although the pockets

remained at each end of the wound and there was concern that more hair in these areas was causing a delay in healing (Figure 6).

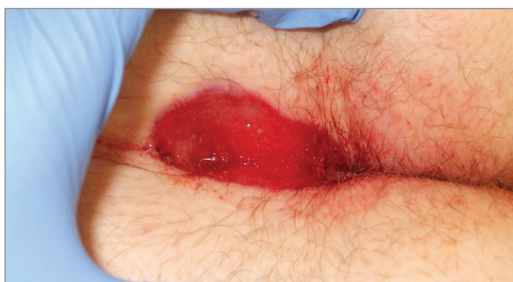

Figure 5. One year after excision of pilodal sinus the wound had failed to heal. The granulation tissue was of poor quality, friable and bleeding easily.

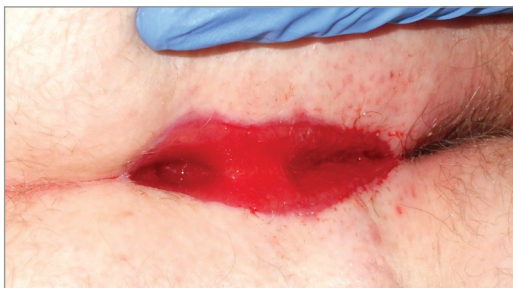


Figure 6. The condition of the wound bed improved with hair removal and the use of an antimicrobial gel.

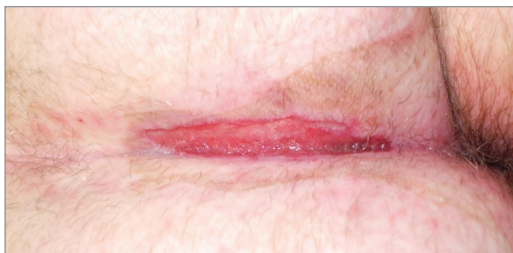

Figure 7. Despite management with antimicrobial dressings, the wound still failed to epithelialise, although the length reduced.

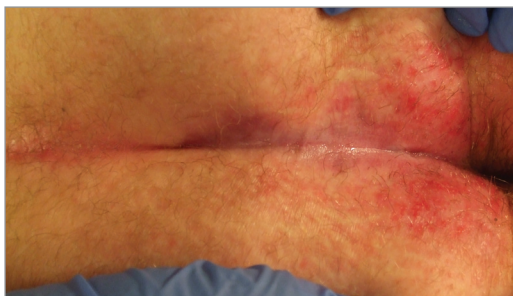


Figure 8. Following four weeks of PICO[®] (Smith & Nephew) therapy the wound had completely healed.

The decision was made to commence NPWT. This was timed during the Christmas break from studies. After 1 week there was a significant improvement to the wound, which measured 5 cm long and 0.5 cm wide. The therapy was discontinued as the patient was returning home for Christmas and, unfortunately, on his return in January the wound had deteriorated again and measured 7 cm x 1 cm. Hair had regrown and had not been effectively managed, contributing to further contamination and deterioration.

Although he conceded that NPWT was the best solution he did not feel he could tolerate it while trying to attend university. The wound was continued to be managed by antimicrobial dressings and the wound alternated between improvement and deterioration. The length had reduced to 4.5 cm and the depth was superficial but the wound failed to epithelialise (Figure 7). The patient suffered from loose stool and the area was often contaminated, inhibiting healing (Harris et al, 2012).

PICO was commenced as this was much more acceptable to the patient. He was able to place the battery pack in his trouser pocket and attend lectures without anyone noticing. Following four weeks of PICO therapy the wound had completely healed (Figure 8). Being able to seal the wound was particularly important in this case since it prevented faecal contamination.

CONCLUSION

These case reports demonstrate an area for which treatment with PICO is particularly effective. There are several contributory factors to the success of PICO:

- ▶▶ Sealing the wound in the natal cleft prevents ongoing contamination.
- ▶▶ Since this area of the body is particularly prone to warmth and moisture, removal of exudate and moisture, discourages bacterial growth and improved healing.
- ▶▶ By sealing the wound, further contamination from loose hair is prevented.
- ▶▶ The system is very acceptable to the patient due to the device being so discreet.



REFERENCES

Armstrong D, Lavery L, Diabetic Foot Study Consortium (2005) Negative pressure wound therapy after partial diabetic foot amputation: a multicentre, randomised controlled trial. *Lancet* 366(9498): 1704–10

Banwell PE, Musgrave M (2004) Topical negative pressure therapy: mechanisms and indications. *Int Wound J* 1(2):95–106

Harris CL, Holloway S (2012) Development of an evidence-based protocol for care of pilonidal sinus wounds healing by secondary intent using a modified Reactive Delphi procedure. Part 2: methodology, analysis and results. *Int Wound J* 9(2):173–88

Harris CL, Laforet K, Sibbald RG, Bishop R (2012) Twelve common mistakes in pilonidal sinus care. *Adv Skin Wound Care* 25(7):324–32

Hudson DA, Adams KG, Huyssteen AV et al (2013) Simplified negative pressure wound therapy: clinical evaluation of an ultraportable, no-canister system. *Int Wound J* May 7 [Epub ahead of print]

Hunter JE, Teot L, Horch R, Banwell PE (2007) Evidence-based medicine: vacuum-assisted closure in wound care management. *Int Wound J* 4(3):256–69

Kamolz LP, Andel H, Haslik W et al (2004) Use of subatmospheric pressure therapy to prevent burn wound progression in human: first experiences. *Burns* 30(3): 253–8

Kilpadi DV, Cunningham MR (2011) Evaluation of closed incision management with negative pressure wound therapy (CIM): hematoma/seroma and involvement of the lymphatic system. *Wound Repair Regen* 19(5): 588–96

Mendonca DA, Drew PJ, Harding KG, Price PE (2007) A pilot study of the effect of topical negative pressure on quality of life. *J Wound Care* 116(2):49–53

Miller D, Harding K (2003) Pilonidal sinus disease. *World Wide Wounds*. Available at: <http://bit.ly/aYYUPm> (accessed 14.10.2013)

Percival S, Cutting K (2010) *Microbiology of Wounds*. CRC Press, Boca Raton, FL

Timmons J (2007) Diagnosis, treatment and nursing management of patients with pilonidal sinus disease. *Nurs Stand* 21(52):48–56

Ubbink DT, Westerbos SJ, Evans D et al (2008) Topical negative pressure for treating chronic wounds. *Cochrane Database Syst Rev* 16(3):CD001898

Vig S, Dowsett C, Berg L et al (2011) Evidence-based recommendations for the use of negative pressure wound therapy in chronic wounds: steps towards an international consensus. *J Tissue Viability* 20(Suppl 1):S1–18

World Union of Wound Healing Societies (2004) *Principles of Best Practice. Minimising pain at Wound Dressing-Related Procedures. A Consensus Document*. MEP Ltd, London