

Successful use of negative pressure wound therapy with an exposed kidney

Negative pressure wound therapy (NPWT) is an advanced wound healing technique that is used to accelerate the healing process. Its use has steadily grown, as increasingly positive outcomes have been demonstrated. Recently, NPWT has been used on more complex wounds, where previously, only reconstructive surgery would have been considered. This article describes the use of NPWT to treat an exposed kidney following renal transplant surgery, facilitating the transfer of treatment to the community.

KEY WORDS

- ▶▶ Negative pressure wound therapy
- ▶▶ Post-surgical wound
- ▶▶ Renal transplant

Negative pressure wound therapy (NPWT) is a high-tech treatment that promotes the acceleration of wound healing by applying subatmospheric pressure to the wound bed (Hunter et al, 2007). It has been used extensively for a wide variety of acute surgical wounds, such as open and dehiscent abdomens, and sternal and amputation wounds (Bovill et al, 2008).

As clinical evidence mounts, clinicians are viewing NPWT as an efficient and safe adjunct to managing complex cases. NPWT has also changed the way that patients with complex wounds are treated, allowing discharge in instances where they would previously have needed to remain in hospital.

The first NPWT device, known as vacuum-assisted closure (V.A.C.[™]; KCI) was pioneered in 1993 (Morykwas et al, 1997), and the seminal prospective study on this therapy demonstrated positive results, with increased healing rates in 98% of patients (Argenta and Morykwas, 1997). Since then, experimental studies have also demonstrated positive healing outcomes, including increased perfusion and proliferation (Kamolz et al, 2004).

A Cochrane review of NPWT in chronic wounds reported mixed results when compared with conventional dressings (Ubbink et al, 2008). However, there is a growing body of evidence in the form of case studies reporting positive outcomes related to the use of NPWT (Leaper, 2009). As a result, negative pressure has now moved into areas of wound management that would not ordinarily have been considered.

MODE OF ACTION

Subatmospheric or negative pressure is applied at the wound bed via suction through surgical grade foam or gauze interface, which is sealed into the wound using a film dressing (Gustafsson et al, 2007). It has been demonstrated that subatmospheric pressure causes vasodilation, increasing vascular perfusion, and interstitial fluid flow (Banwell and Musgrave, 2004). This enhances oxygen and nutrient delivery, and increases levels of cytokines and fibroblasts, which encourages cell division and the deposition of collagen, contributing to faster healing (Argenta and Morykwas, 1997).

Under negative pressure, the foam interface material also causes mechanical stress within the granulation tissue and this interaction stimulates cell proliferation and wound contraction (Kamolz et al, 2004). In addition, exudate is removed from the wound oedema, which reduces in the tissues.

Bacteria are also removed in the exudate, helping reduce the development of critical colonisation and subsequent infection (Morykwas et al, 1997). Finally, slough that is not too fibrous or dense may be broken down, further enhancing the healing environment.

CASE REPORT

This case report demonstrates the successful use of NPWT in the community-based management of a 56-year-old man with an exposed kidney. After development of end-stage renal failure due to diabetic nephropathy, the patient underwent an elective renal transplant. The patient had no other comorbidities.

SUE MURPHY

*Tissue Viability Specialist Nurse,
Bristol Community Health CIC,
Bristol*

LYNNE MYERS

*Tissue Viability Specialist Nurse,
North Bristol NHS Trust, Bristol*

“When the patient was transferred to the community, the wound measured 17 cm in length and varied in depth, ranging from 3–5 cm, with some undermining and the kidney was clearly visible.”

Postoperative infection and debridement

Seven days after the transplant, the patient developed abdominal pain. A wound swab identified the presence of coliform bacteria and *enterococci*. A computed tomography (CT) scan was taken after the patient started experiencing increased abdominal pain, vomiting, and diarrhoea. The CT scan revealed an anterior abdominal wall defect containing gas, and a defect in the fascia of the anterior abdominal wall. There was also some compromise to the perfusion of the lower pole of the transplanted kidney.

Infection following renal transplant often leads to the loss of the kidney (Faizal et al, 2011). To try and prevent this, the patient began a course of antibiotics and was taken to theatre to drain the abscess. This subsequently required a further three surgical interventions for washout.

Following debridement, and as the infection resolved, the lower third of the transplanted kidney became visible in the dehisced wound.

Application of NPWT

Exposure of the kidney to the environment is a threat to its viability (Faizal et al, 2011). Although an ultrasound scan identified that the kidney had good vascular flow, there was concern that the exposure, and any further wound infection, could lead to the loss of the kidney.

The consultant surgeon recommended starting NPWT to stimulate granulation tissue over the kidney and ensure that it did not remain exposed. It should be noted that the application of NPWT in a wound with an exposed organ is an off-licence use of this modality.

Two layers of soft silicone dressing (Mepitel[®]; Mölnlycke) were initially used to protect the kidney. This technique of protecting the organ from the negative pressure with the Mepitel had been used in cases of exposed liver and bowel within the same hospital setting, but there has been limited experience of using NPWT over a kidney.

The previously recommended treatment for covering the kidney would have been plastic surgery using soft tissue reconstructive flaps (Faizal et al, 2011), however, it was imperative to act immediately. Having covered the kidney with Mepitel, black foam was used to fill the wound. The NPWT was set at 125 mmHg on continuous therapy.

After 48 hours, the wound showed signs of granulation at the margins, while areas of slough were beginning to resolve. There was an area of thicker fibrous slough adjacent to the kidney, which required monitoring, as at this point there was uncertainty as to whether granulation tissue would cover the kidney successfully.

The kidney function was monitored closely and found to be stable, while the protective covering that the therapy provided meant that the patient could be discharged, despite the complexity of the wound.

Continuity of care

The tissue viability nurses (TVNs) in secondary care liaised closely with those in primary care and provided excellent continuity in treatment. This collaboration ensured that the correct dressing procedure and adequate protection of the kidney took place.

The TVNs in primary care performed all of the dressing changes, which were conducted three times a week, and monitored progress closely. The patient was supplied with a portable device, and was taught how to change it, in order to facilitate mobility. He was also taught how to change the canister that collects the exudate, should this become necessary, between his visits.

Not all Trusts in the UK have funding for this therapy in the community and in a lot of cases the patient would have to remain in hospital to receive NPWT. In this case, due to the complex nature of the wound, communication was vital for the success of transferring the patient into the community (Murphy, 2011).

In the authors' location, there is an excellent liaison network and this enables support between community and hospital. It was imperative that the primary care nurses felt well-supported so that, in the event of any concerns on behalf of the patient, medical advice could be easily obtained.

The TVNs ensured that close assessment at every dressing change was carried out to monitor for any external signs of kidney damage or signs of infection. They also monitored the progress of granulation tissue and removed any slough.

Wound dimensions

When the patient was transferred to the community, the wound measured 17 cm in length

and varied in depth, ranging from 3–5 cm, with some undermining and the kidney was clearly visible (Figure 1a). A comprehensive initial assessment was performed at the first visit in the community, which included measurements, examination of tissue type in the wound bed, and a photograph. There was concern that the tissue might not granulate over the kidney, so it was particularly important to monitor this closely.

The NPWT was changed three times per week, continuing to protect the kidney with one layer of Mepitel. Progress was made rapidly and granulation tissue started to proliferate over the kidney 1 week after application of NPWT (Figure 1b).

Follow-up

The patient was followed up closely by the renal unit within the hospital where he underwent blood tests twice weekly. Close liaison was maintained between the tissue viability services in secondary and primary care, and the surgical team.

By week 2, concern was expressed regarding a thick plug of slough at the distal end of the cavity

and whether this would lift with NPWT (Figure 1c). As this was an innovative use of NPWT, the outcome of this slough could not be anticipated based on prior experience.


Continued progress was made with granulation tissue over the kidney and contraction of the wound. However, the fibrous slough was still evident and arrangements were made for debridement by the surgeon at week 3. Following the removal of this fibrous slough, rapid improvement was observed 5 weeks after application (Figure 1d).

Factors affecting wound healing

One observation made in earlier studies (Armstrong and Lavery, 2005; Braakenburg et al, 2006) is that NPWT increases healing despite the presence of complexities that normally have the opposite effect. This patient had unstable glycaemia, which is thought to contribute to delayed and dysfunctional wound healing and impaired vasculogenesis (Rai et al, 2005). The patient was also taking immunosuppressant

Cost Effective Resolution of Overgranulation Tissue

Overgranulation tissue can be slow to heal using foam dressings or silver alginates and foams and these dressings can be expensive. Haelan Tape, a protective, waterproof, self-adhesive tape impregnated with the moderately potent steroid, fludrocortide, offers a cost effective solution. Published studies show that using Haelan Tape to treat overgranulation tissue in the following sites results in faster and therefore more cost effective healing¹:



Treatment	Cost per patient for complete resolution
Haelan Tape	£5 on average (unit price of 50cmTape = £9.27)
Silver dressings	£18 - £24
Foam dressing	£20 - £30

- Traumatic wounds on the forearm, leg and neck
- Post operative wounds on the abdomen, back, forearm and forehead
- PEG stoma sites
- Supra-pubic catheter stoma sites
- Chronic abdominal wound sites

For further information please call 01603 722480 or email enquiries@typharm.com quoting OGINFO

POM

Reference: 1. Overgranulation tissue: a new approach, Sue Johnson, Clinical Nurse Specialist, Doncaster & Bassetlaw NHS FoundationTrust.

Abridged Prescribing Information - Haelan Tape. Presentation: Transparent, plastic surgical tape impregnated with 4 µg/cm² fludrocortide. **Uses:** Adjunctive therapy for chronic, localised, recalcitrant dermatoses that may respond to topical corticosteroids and particularly dry, scaling lesions. **Dosage and Administration:** Adults and the Elderly: For application to the skin, which should be clean, dry and shorn of hair. In most instances the tape need only remain in place for 12 out of 24 hours. Application: The tape is cut so as to cover the lesion and a quarter inch margin of normal skin. Corners should be rounded off. After removing the lining paper, the tape is applied to the centre of the lesion with gentle pressure and worked to the edges, avoiding excessive tension of the skin. If longer strips of tape are to be applied, the lining paper should be removed progressively. Children: Courses should be limited to five days and tight coverings should not be used. If irritation or infection develops, remove tape and consult a physician. **Contra-indications:** Haelan Tape is contraindicated in patients with: Chicken pox. Vaccinia. Tuberculosis of the skin. Hypersensitivity to any of the components. Facial rosacea. Acne vulgaris. Perioral dermatitis. Perianal and genital pruritus. Dermatoses in infancy including eczema, dermatitic napkin eruption, bacterial (impetigo), viral (herpes simplex) and fungal (candida or dermatophyte) infections. **Special Warnings and Precautions for Use:** Not advocated for acute and weeping dermatoses. Local and systemic toxicity of medium and high potency topical corticosteroids is common, especially following long-term continuous use, continued use on large areas of damaged skin, flexures and with polythene occlusion. Systemic absorption of topical corticosteroids has produced reversible hypothalamic-pituitary-adrenal (HPA) axis suppression. Long-term continuous therapy should be avoided in all patients irrespective of age. Application under occlusion should be restricted to dermatoses in very limited areas. If used on the face, courses should be limited to five days and occlusion should not be used. In the presence of skin infections, the use of an appropriate antifungal or antibacterial agent should be instituted. For children, administration of topical corticosteroids should be limited to the least amount compatible with an effective therapeutic regimen. Children may absorb proportionally larger amounts of topical corticosteroids and thus may be more susceptible to systemic toxicity. **Side Effects:** The following local adverse reactions may occur with the use of occlusive dressings: burning, itching, irritation, dryness, folliculitis, hypertrichosis, acneform eruptions, hypopigmentation, perioral dermatitis, allergic contact dermatitis, maceration of the skin, secondary infection, skin atrophy, miliaria, striae and thinning and dilatations of superficial blood vessels producing telangiectasia. **Legal Category:** POM NHS Cost: 50cm £9.27; 200cm £24.95. **Marketing Authorisation Number:** PL 00551/0014 **Marketing Authorisation Holder:** Typharm Limited, 14D Wendover Road, Rackheath Industrial Estate, Norwich, NR13 6LH. Tel 01603 722480 or email enquiries@typharm.com quoting OGINFO **Date of Preparation:** March 2006.

Information on adverse event reporting can be found at www.mhra.gov.uk/yellowcard and should also be reported to Typharm Limited. Further information can be found in the Summary of Product Characteristics available from Typharm Limited. Code: 1HT12/1303



www.typharm.com

REFERENCES

Argenta L, Morykwas MJ (1997) Vacuum-assisted closure: a new method for wound control and treatment: clinical experience. *Ann Plast Surg* 38(6):563–76

Armstrong D, Lavery L (2005) Negative pressure wound therapy after partial diabetic foot amputation: a multicentre, randomised control trial. *Lancet* 366(9498):1704–10

Banwell PE, Musgrave M (2004) Topical negative pressure therapy: mechanisms and indications. *Int Wound J* 1(2):95–106

Bovill E, Banwell PE, Teot L et al (2008) Topical negative pressure wound therapy: a review of its role and guidelines for its use in the management of acute wounds. *Int Wound J* 5(4):511–29

Braakenburg A, Obdeijn MC, Feitz R et al (2006) The clinical efficacy and cost effectiveness of the vacuum assisted closure technique in the management of acute and chronic wounds: a randomised controlled trial. *Plast Reconstr Surg* 118(2):390–7

Chen SZ, Li J, Li XY et al (2005) Effects of vacuum-assisted closure on wound microcirculation: an experimental study. *Asian J Surg* 28(3):211–17

Faizal A, Bujang Safawi E, Sundram M et al (2011) Soft tissue cover for an exposed transplanted kidney with a pedicled myocutaneous anterolateral thigh perforator and vastus lateralis flap. *Urol Int* 87:117–9

Franz M, Robson MC, Steed DL et al (2008) Guidelines to aid healing of acute wounds by decreasing impediments of healing. *Wound Repair Regen* 16(6):723–48

Gustafsson R, Sjögren J, Ingemansson R (2007) Understanding topical negative therapy. In: Calne S (ed) *Topical negative pressure in wound management. Position Document*. EWMA, London:2–4

Hunter JE, Teot L, Horch R et al (2007) Evidence-based medicine; vacuum assisted closure in wound management. *Int Wound J* 4(2):256–69

Kamolz L, Andel H, Haslik W et al (2004) Use of subatmospheric pressure therapy to prevent burn wound progression in human: first experiences. *Burns* 30(3):253–8

Leaper D (2009) Evidence-based wound care in the UK. *Int Wound J* 6(2):89–91

Morykwas MJ, Argenta LC, Shelton-Brown EI et al (1997) Vacuum-assisted closure: a new method for wound control and treatment: animal studies and basic foundation. *Ann Plast Surg* 38(6):553–62

Murphy F (2011) Managing post-transplant patients in primary care. *Practice Nursing* 22(6):292–7

Rai NK, Suryabhan, Ansari M et al (2005) Effect of glycaemic control on apoptosis in diabetic wounds. *J Wound Care* 14(6):277–281

Schimp VL, Worley C, Brunello S et al (2004) Vacuum-assisted closure in the treatment of gynaecological oncology wound failures. *Gynaecol Oncol* 92(2):586–91

Ubbink DT, Westerbos SJ, Evand D et al (2008) Topical negative pressure for treating chronic wounds. *Cochrane Database Syst Rev* 3:CD00189

medication, which depresses the humoral and cellular inflammatory response, a fundamental part of acute wound healing (Franz et al, 2008). In addition, the patient was also taking corticosteroids,

which can interfere with inflammation, fibroblast proliferation, collagen synthesis and degradation, deposition of ground substances of connective tissue, angiogenesis, wound contraction, and re-epithelialisation, resulting in delayed wound healing (Franz et al, 2008). Despite these factors, complete healing was achieved 10 weeks after application (Figure 1e).

CONCLUSION

In this case, the initial benefit of using NPWT was that, as a closed system, it provided protection to the kidney, supporting it while it was exposed in the wound and protecting it from infection. The other major benefit was the removal of exudate from the wound, which decreased skin turgor and capillary engorgement, thus improving blood perfusion and oxygenation of the tissues (Chen et al, 2005).

Achieving granulation tissue over the kidney and wound closure as quickly as possible was also a priority and the increased rate of granulation demonstrated by using NPWT (Schimp et al, 2004) contributed to the successful outcome.

The patient had previously endured a prolonged stay in hospital following the postoperative problems, therefore, being able to be with his family and undergo therapy at home was beneficial to his psychological wellbeing.

The success of this case study demonstrates the positive contribution of NPWT to the treatment of complex, postsurgical wounds with an exposed kidney. The medical and nursing profession are using this therapy in new ways to benefit patient outcomes, even in the presence of factors that would normally delay or prevent healing. In addition, the contribution to the psychological wellbeing of the individual cannot be underestimated, allowing them to receive care in their own home.

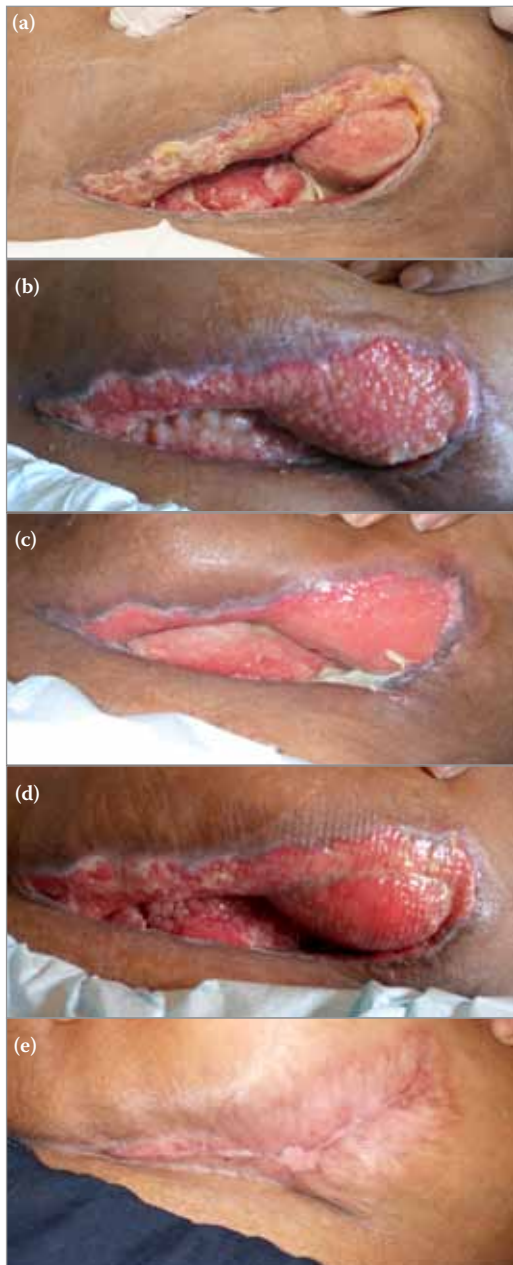


Figure 1. (a) Dehiscent wound exposing the kidney after renal transplant surgery. (b) Granulation tissue proliferating over the kidney treated with NPWT three times per week. (c) Fibrous slough and granulation over the contracting wound. (d) The wound after the debridement of fibrous slough. (e) Complete healing was achieved.