

# Treating non-hypoxic wounds with hyperbaric oxygen therapy

## KEY WORDS

- ▶▶ Chronic wound
- ▶▶ Hyperbaric oxygen therapy
- ▶▶ Hypoxic wound
- ▶▶ Inflammation

Hyperbaric oxygen therapy (HBO) may be a useful adjunct for chronic nonhealing wounds when the aetiology includes a hypoxic component. Occasionally, HBO is administered in unusual cases that have no obvious hypoxic involvement. The aim of this case series was to assess whether HBO would be beneficial in the management of chronic wounds with no obvious hypoxic component. Three chronic wounds with no apparent hypoxic complications were treated with HBO and the outcomes reviewed. All three cases demonstrated improved wound healing during the course of HBO, suggesting it may be a beneficial adjunct in the management of chronic wounds with no obvious hypoxic component.

Hyperbaric oxygen therapy (HBO) involves the inhalation of pure oxygen at pressures greater than those present at sea level (Thom, 1992). HBO is administered in a pressurised chamber (*Figure 1*). For patients with chronic wounds, the pressure used is between 2.0 and 2.8 atmospheres absolute (ATA). HBO is usually administered for 90 minutes, 5 days a week for 20–40 treatments, depending on wound progress.

Exposure to oxygen is essential in wound healing. Even those wounds without overt hypoxic symptoms are hypoxic towards the centre (Bishop, 2008); this oxygen gradient towards the intact tissue acts as a stimulus to tissue repair (LaVan and Hunt, 1990). The increased partial pressure of oxygen during HBO elevates oxygen tension in the tissues and so increases the oxygen gradient.

Studies suggest that HBO may be a useful adjunct for some patients with chronic nonhealing wounds, particularly when the aetiology includes a hypoxic component (Hunter et al, 2010). This could be of benefit in all wounds that are not healing in a timely manner.

The high levels of oxygen at increased pressure during HBO have been shown to highly oxygenate circulating haemoglobin and lead to more oxygen being dissolved into plasma (Niinikoski, 2004). Oxygen dissolved in plasma is more readily utilised by body tissues than that bound to haemoglobin (Jain, 2009).

The increased tissue oxygen levels achieved during HBO have been demonstrated to stimulate angiogenesis, increase cell proliferation, facilitate infection prevention and treatment, and reduce oedema (Nylander et al, 1985; Cianci, 2004).

In Plymouth, the Diving Diseases Research Centre (DDRC) receives referrals for the treatment of chronic wounds and occasionally these are for unusual cases of chronic wounds that appear not to have an overt hypoxic element, but show no signs of healing. Consultants referring cases like these are often hoping that HBO will promote healing by encouraging these processes after other treatments have failed.

The treatment and outcomes of three such referrals are discussed in this article. It was hypothesised that the benefits of HBO described above would lead to improvements in wound healing in these cases, despite there being no clear hypoxic element.

## CASES

All HBO treatments in these patient cases were delivered once per day, five times a week at a pressure of 2.4 ATA.

### Patient A

Patient A was a 72-year-old man with an ulcer over his right achilles that had been present for 36 months at the time of referral. He had a history of mild hypertension for which no medication was required.

ALEXANDRA BISHOP  
Senior Clinical Nurse,  
Diving Diseases Research Centre,  
The Hyperbaric Medical Centre,  
Plymouth, UK

The ulcer was being treated with short-stretch compression bandaging and the wound had remained static despite surgical debridement.

The patient's consultant felt further surgical interventions would not be successful and he was referred to the DDRC.

The patient presented to the DDRC with 90% slough to the wound bed (*Figure 2a*). He continued to receive short-stretch bandaging, which was changed on a weekly basis during his course of HBO.

On completion of 40 treatments, Patient A's wound showed improvement with only 30% slough to the wound bed and a 28% reduction in wound area (from 2.6cm<sup>2</sup> to 3.6cm<sup>2</sup>) (*Figure 2b*). The referring consultant reviewed the patient after the course of HBO and considered surgical debridement under local anaesthetic with subsequent skin grafting to be of potential benefit. However – as is common in patients who have received HBO – the wound continued to heal and surgical intervention was not required and one year after HBO, the wound was 90% epithelialised (*Figure 2c*).

Patient A was pleased with the outcome of HBO and the continued progress of his wound following completion of the treatment.


#### Patient B

Patient B was a 72-year-old man with a pressure ulcer to his right heel (*Figure 3a*). The heel ulcer developed during an inpatient stay for the treatment of a ruptured oesophagus.

The ulcer had been present for 42 months at the time of presentation to the DDRC. A small difference in leg length was believed to be delaying wound healing due to increased pressure at the wound site. Three months prior to referral for HBO, surgery with primary closure had failed, despite apparent good circulation to the area.

The referring consultant was particularly concerned about recurrent infection of the wound. Magnetic resonance imaging (MRI) did not reveal osteomyelitis of the underlying bone. The patient's past medical history included a previous hernia repair, a knee replacement, and mild asthma.

Patient B completed 40 HBO treatments. Although wound improvement was initially slow, a 75% reduction in wound depth from 1.2cm to 0.3cm was seen on completion of treatment (*Figure 3b*). The wound did not become reinfected during this time. The consultant was pleased with Patient B's progress and discharged him from the clinic.



**P** is for People.  
At Urgo, we take the time to understand what you, and all your patients need. It helps us to provide the very best wound care solutions we possibly can.

To see more of our wound care patient stories and to discover our full range of **compression** and **advanced dressing** products visit us at [www.urgopeople.co.uk](http://www.urgopeople.co.uk)

Urgo – We're here to help you help your patients

Urgo Limited Tel: 01509 502051  
Email: [urgopeople@uk.urgo.com](mailto:urgopeople@uk.urgo.com)

Figure 1. View of a hyperbaric oxygen therapy chamber.

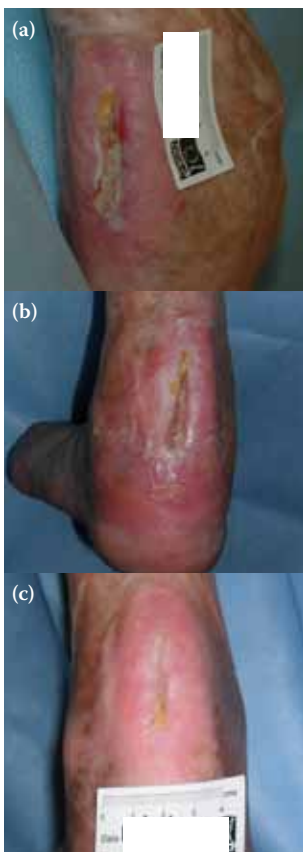

Figure 2. (a) Patient A's wound at presentation to the Diving Diseases Research Centre (DDRC) with 90% slough; (b) after 40 hyperbaric oxygen (HBO) treatments with 30% slough; (c) and at 1-year follow-up with 90% epithelialisation.

Four months after completion of HBO, healing had continued and 90% epithelialisation (Figure 3c) had been achieved. Patient B was happy with the outcome.

### Patient C

Patient C was a 64-year-old woman referred to the DDRC with ulceration resulting from pyoderma gangrenosum.

Pyoderma gangrenosum is a rare ulcerative skin condition that generally begins with a painful nodule or pustule that eventually breaks down into ulceration. The resulting ulcers usually have a blue-black edge.

Patient C had bilateral wounds (two on each leg) that had been present for 18 months, and were deteriorating. She was unable to tolerate anti-inflammatory therapy with prednisolone or cyclosporine, and methotrexate had been ineffective. Patient C's extensive medical history included diabetes, hypertension, oesophageal ulcers, a hysterectomy, and fibromyalgia.

There were a number of interruptions to Patient C's course of HBO in the initial stages due to urinary tract infections and headaches. She also had a break for a holiday.

One of the wounds to Patient C's right leg healed after 17 HBO treatments, the other healed after

40 treatments. On the patient's left leg, after a total of 60 treatments, the lateral wound reduced in size by 58% (from 86.3cm<sup>2</sup> to 36.4cm<sup>2</sup>) (Figure 4) and the left medial wound was 80% smaller (from 18.4cm<sup>2</sup> to 3.7cm<sup>2</sup>) (Figure 5). The referring consultant described the improvement in the wounds as dramatic.

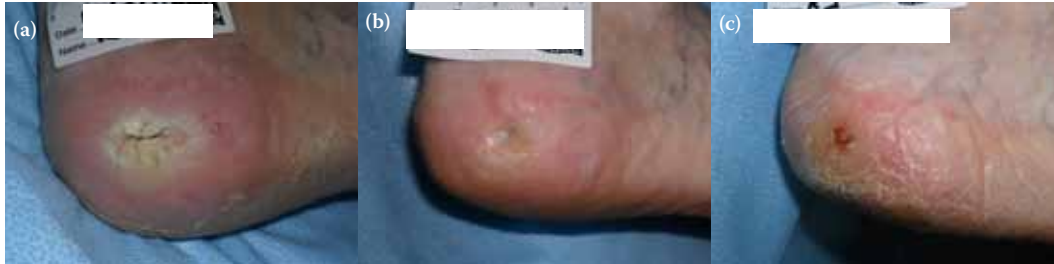### DISCUSSION

Despite there being no evidence of hypoxia as a major contributor to delayed healing in these cases, all experienced favourable outcomes following HBO. The reasons for this could include reduction of inflammation, enhanced neutrophil function, reduction of oedema, or increased neovascularisation and collagen deposition, all of which are known benefits of HBO (Nylander et al, 1985; Broussard, 2003; Cianci, 2004).

Rangaraj et al (2011) suggested chronic wounds often have a persistent and uncoordinated mix of acute and chronic inflammatory responses. HBO can alter a wound's cellular and molecular activities, and this may restart or recoordinate the healing process, allowing the phases of wound healing to progress in an orderly and synchronised manner.

Bacteria can cause a significant increase in oxygen consumption in a wound, and chronic wounds are believed to have greater bacterial loads

Figure 3. (a) Patient B's wound at presentation to the Diving Diseases Research Centre. (b) The wound's depth reduced from 1.2 cm to 0.3 cm after 40 episodes of hyperbaric oxygen therapy (HBO). (c) The wound 4 months after completion of the course of HBO showing 90% epithelialisation.



than acute wounds, even when not showing clear signs of infection (Edwards and Harding, 2004). Therefore, the increased oxygenation of the wound during HBO may allow the patient's immune system to more effectively combat infection. For example, Patient B's recurrent infections ceased during HBO, suggesting a change in his ability to fight infection.

In complex chronic wounds, such as those reported here, complete healing may not be the primary goal of HBO. Often, any improvement in a wound that has been static or deteriorating for a long period of time can be sufficient to improve the health and quality of life of the patient. HBO can initiate a series of improvements in the wound environment that continue between and following treatment completion.

## CONCLUSION

These cases suggest that HBO can be beneficial for chronic wounds with no obvious hypoxic component. However, the use of HBO as an adjunct therapy in wound care should be carefully considered and outcomes closely monitored. Patient history and comorbidities,

as well as recent interventions and why they failed should be assessed. Clear aims must be established and agreed prior to HBO so that outcomes can be evaluated.

WUK

## REFERENCES

- Bishop A (2008) Role of oxygen in wound healing. *J Wound Care* 17(9):399–401
- Broussard CL (2003) Hyperbaric oxygenation and wound healing. *J Wound Ostomy Continence Nurs* 30(4):210–16
- Cianci P (2004) Advances in the treatment of the diabetic foot: is there a role for adjunctive hyperbaric oxygen therapy? *Wound Repair Regen* 12(2):2–10
- Hunter S, Langemo DK, Anderson J et al (2010) Hyperbaric oxygen therapy for chronic wounds. *Adv Skin Wound Care* 23(3):116–9
- Jain KK (2009) *Textbook of Hyperbaric Medicine* (5<sup>th</sup> ed.) Hogrefe & Huber, Göttingen
- LaVan FB, Hunt TK (1990) Oxygen and wound healing. *Clin Plast Surg* 17(3):463–72
- Niinikoski JHA (2004) Clinical hyperbaric oxygen therapy, wound perfusion, and transcutaneous oximetry. *World J Surg* 28(3):307–11
- Nylander G, Lewis D, Nordstrom H, Larsson J (1985) Reduction of postischemic edema with hyperbaric oxygen. *Plast Reconstr Surg* 76(4):596–603
- Rangaraj A, Harding K, Leaper D (2011) Role of collagen in wound management. *Wounds UK* 7(2):54–63
- Thom SR (1992) *Hyperbaric Oxygen Therapy: A Committee Report*. UHMS, Bethesda MD

*“These cases suggest that HBO can be beneficial for chronic wounds with no obvious hypoxic component. However, the use of HBO as an adjunct therapy in wound care should be carefully considered and outcomes closely monitored.”*

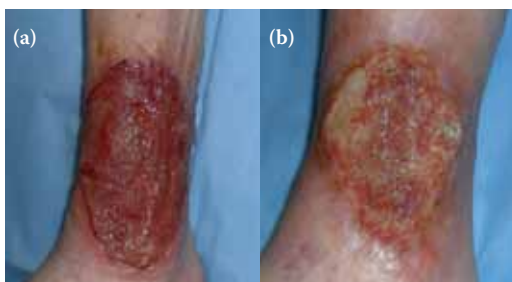

Figure 4. (a) Patient C's left lateral ulcer shown at presentation of the Diving Diseases Research Centre; (b) and after 60 hyperbaric oxygen therapy treatment.

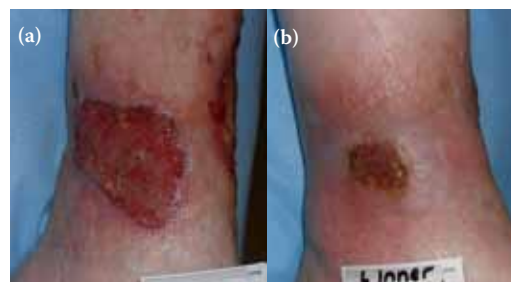

Figure 5. (a) Patient C's left medial ulcer shown at presentation to the Diving Diseases Research Centre; (b) and after 60 hyperbaric oxygen therapy treatments.