

‘For patients undergoing complex abdominal or bowel surgery, the risk of infection and the resultant dehiscence if an infection occurs can pose a great challenge’

LINDSEY BULLOUGH
Tissue Viability Nurse, The Royal Albert & Edward Infirmary, Wigan

GERALDINE LITTLE
Staff Nurse, The Royal Albert & Edward Infirmary, Wigan

JANET HODSON
Staff Nurse, The Royal Albert & Edward Infirmary, Wigan

ANNE MORRIS
Tissue Viability Nurse, The Royal Albert & Edward Infirmary, Wigan

THE USE OF DACC-COATED DRESSINGS FOR THE TREATMENT OF INFECTED, COMPLEX ABDOMINAL WOUNDS

Surgical site infections have been shown to be the source of up to 20% of all of healthcare-associated infections and at least 5% of patients undergoing a surgical procedure develop a surgical site infection (National Institute for Health and Clinical Excellence [NICE], 2008). On average, such an infection will add three to 10 days onto a patient's hospital stay and incur an additional cost of between £4,000 and £10,000 for extra treatment (Department of Health [DH], 2008).

For patients undergoing complex abdominal or bowel surgery, the risk of infection and the resultant dehiscence if an infection does occur, can pose a great challenge. Not only will the local infection need to be managed, but cross-contamination from faecal matter if a stoma has been formed, must be prevented. If infection does occur, wound healing can be delayed (Bateman, 2012) as tissues are damaged, tensile strength reduced and an undesirable inflammatory response induced (Percival and Bowler, 2004).

When looking at treatment options for such wounds it is important to avoid the formation of small bowel fistulae; if they occur it can lead to a significant increase in mortality and morbidity (Becker et al, 2007).

If the abdominal wound is open, due to its complexity, negative pressure wound therapy (NPWT) should be used only by specialists with appropriate training and expertise (Kaplan et al, 2005) with more conservative options needing to be considered. Furthermore, its use in the reduction of bacterial burden in the wound remains controversial (Herrero

Valiente et al, 2012).

For the purpose of this study, the author treated four patients with complex abdominal wounds following wound dehiscence in a critical care setting. Three of these patients had an open abdominal wound following wound dehiscence, while the remaining patient returned from theatre with an open abdominal wound.

In all of these cases bowel was exposed and protected by a surgical mesh, a stoma was in close proximity and there was an increased risk of developing fistulae. The normal treatment within the trust for large complex wounds is NPWT.

However, due to the wound infection, close proximity of the stoma and concerns about developing a fistula, it was decided to treat the wounds conservatively using Cutimed® Sorbact® (BSN medical) antimicrobial dressings. These dressings are particularly suitable for wounds that are not only infected, but where there is a high risk of recurrence as they can be used for prolonged periods of time (Haycocks et al, 2011) with no contraindications.

CUTIMED SORBACT DACC-COATED DRESSINGS

Unlike dressings which depend on antimicrobials or antiseptics to remove bacteria from contaminated and infected wounds, Cutimed Sorbact dressings work without a chemically active agent. This is due to a coating of DACC, a hydrophobic fatty acid, which has the ability to reduce the microbial load in a moist wound by irreversibly binding bacteria and fungi to the dressings (Ljungh, 2006). This process is

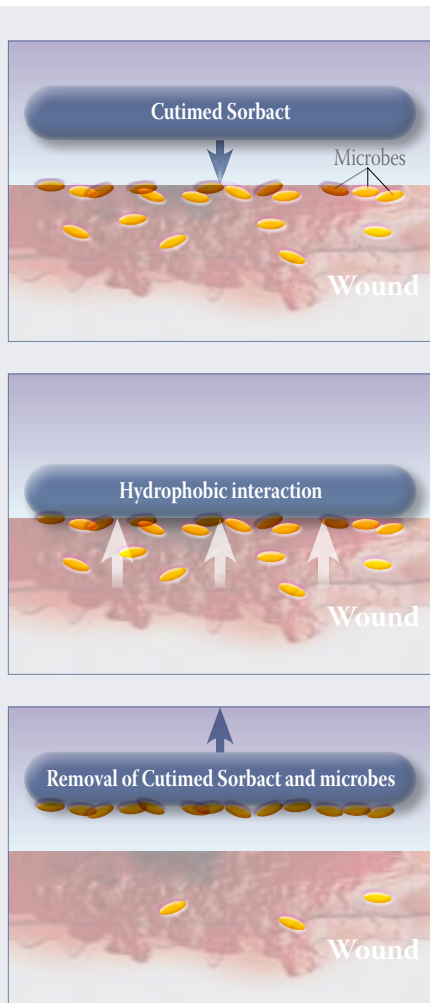


Figure 1: Cutimed Sorbact mode of action.

known as hydrophobic interaction (Figure 1). Once bound, bacteria and fungi are rendered inert and are prevented from proliferating or releasing harmful exotoxins and endotoxins (Hardy, 2010).

MODE OF ACTION

Cutimed Sorbact dressings are effective against a wide range of bacteria and fungi including:

- ▶ *Staphylococcus aureus*
- ▶ Methicillin-resistant *Staphylococcus aureus* (MRSA)
- ▶ *Pseudomonas aeruginosa*
- ▶ *Enterococcus faecalis*
- ▶ *Escherichia coli*
- ▶ *Candida albicans*.

INDICATIONS

Cutimed Sorbact is available in a wide range of shapes and sizes and can be used on all types of colonised or infected wounds, regardless of their aetiology, as long as moisture is present:

- ▶ Chronic wounds such as venous, arterial, pressure or diabetic foot ulcers
- ▶ Postoperative or dehisced surgical wounds
- ▶ Traumatic wounds
- ▶ Wounds after excision of fistulae and abscesses.

infection (Derbyshire, 2010). The properties and benefits of using this technology are highlighted below.

Properties of Cutimed Sorbact dressings

- ▶ In the presence of moisture, bacteria are irreversibly bound to the dressings, providing effective antimicrobial control combined with a low risk of bacterial spread at dressing change. There is no upper binding capacity
- ▶ There are no contraindications and the dressing can be used safely during pregnancy and breastfeeding, as well as on children
- ▶ The dressing binds bacterial toxins, which are also hydrophobic, reducing damage to the wound bed
- ▶ No development of microbial resistance
- ▶ No risk of allergies or systemic absorption (Denyer, 2009), so suitable for all patients with sensitivities or those unable to tolerate other antimicrobial agents
- ▶ As no chemicals are released into the wound bed, treatment can continue for extended periods of time, compared with traditional topical antimicrobials.

Cutimed Sorbact Range

- ▶ **Cutimed Sorbact swabs:** Made of an acetate swab coated with DACC. Primary wound contact dressing for either deep or superficial wounds
- ▶ **Cutimed Sorbact dressing pads:** A Cutimed Sorbact swab with an absorbent pad for low exuding wounds
- ▶ **Cutimed Sorbact ribbon:** Made of DACC-coated cotton gauze. For

References

Bateman S (2012). The dehisced abdomen following invasive intervention. *Wounds UK* Vol 8, No 2

Becker HP, Willms A, Schwab R. (2007) Small bowel fistulae and the open abdomen *Scandinavian Journal of Surgery* 96: 263–271

Denyer J (2010) Antimicrobial management for children with epidermolysis bullosa. *Proceedings from Oxford Summer School Symposium 2010; Daily Challenges, Innovative Solutions.*

Derbyshire A (2010). Innovative solutions to daily challenges: Cutimed Sorbact follow-up case studies. *British Journal of Nursing, Tissue Viability Supplement* 19(11): S30-36

DH (2008) Clean, Safe Care Reducing Infections and Saving Lives. DOH, London

Hardy D (2010). Chronic oedema and associated complications. *Wounds UK* Vol 6 No 4

Haycocks S, Chadwick P (2011a). Use of a DACC-coated dressings in diabetic foot ulcers: A case series. *Diabetic Foot Journal* 14(3) 133–37

Table 1: Wound dimensions

Patient	Treatment start date	Treatment end date	Wound dimensions prior to treatment with Cutimed Sorbact	Wound dimensions at the end of treatment	Length of treatment (weeks)	Reduction in wound size (%)
1	12/03/12	15/05/12	28cm x 15cm	9cm x 6cm	9	87
2	12/02/12	23/04/12	23cm x 17cm	15cm x 6cm	10	77
3	17/04/12	01/06/12	16cm x 14cm	6cm x 7cm	6	81
4	14/09/11	22/02/12	28cm x 28cm	8cm x 19cm	3	81

Patient 1

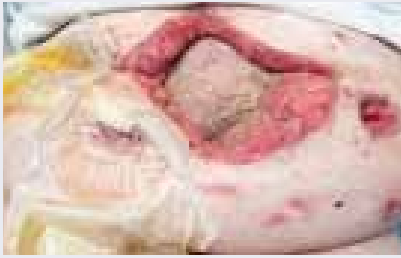

Figure 2: Patient 1: 19 March, 2012.



Figure 3: 5 April 2012
Wound measurements: 22cm x 15cm.

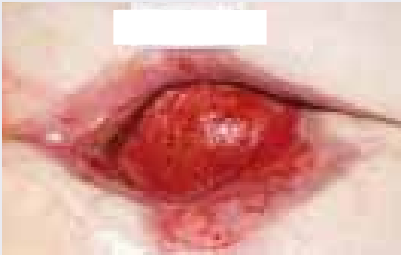

Figure 4: 13 April 2012
Wound measurements: 19cm x 9cm.

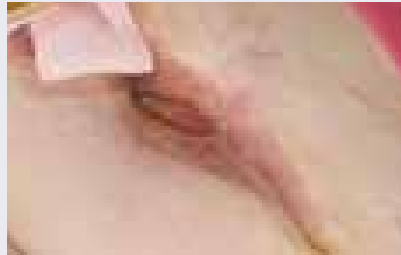


Figure 5: 15 May 2012
Wound measurements: 9cm x 6cm.

Patient 2

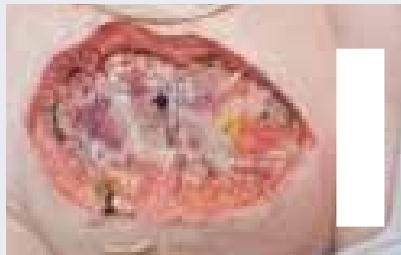

Figure 6: 12 February 2012 the wound measured 23cm x 9cm.

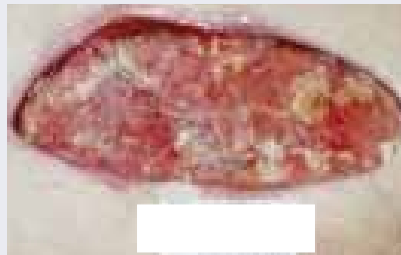

Figure 7: Patient 2: visible wound contraction.

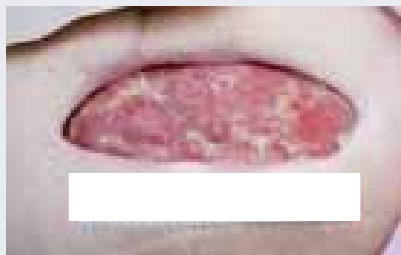

Figure 8: 23 April 2012
Wound measurements: 23cm x 9cm.



Figure 9: 23 April 2012 the wound measured 15cm x 6cm. The wound bed is healthy with visible granulation and epithelial tissue.

use in deep or cavity wounds or wrapping around digits and skin folds where fungal infections may be a problem

- ▶ **Cutimed Sorbact round swabs:** Made of DACC-coated acetate fabric. For filling small wounds
- ▶ **Cutimed Sorbact gel:** A Cutimed Sorbact swab coated with an amorphous hydrogel. For dry, sloughy or low exuding wounds
- ▶ **Cutimed Sorbact Hydroactive:**

A unique combination of a Cutimed Sorbact swab combined with an absorbent hydropolymer gel matrix. These dressings stimulate autolytic debridement, reduce bacterial load, absorb and lock exudate, while maintaining a moist environment.

METHOD

Cutimed Sorbact DACC-coated swabs were used as a primary wound

References

- Haycocks S and Chadwick P (2011b) Use of a DACC-coated Antimicrobial Dressing in People with Diabetes and a History of Foot Ulceration. *Wounds UK* 7(11): 108–14
- Herrero Valiente, L., Garcia-Alcala, D.G., Serano Paz, P., Rowen, S., (2012) The challenges of managing a complex stoma with NPWT. *Journal of Wound care* 21(3): 120–23
- International Consensus (2012) Appropriate use of silver dressings in wounds. An expert working consensus. *Wounds International*, London
- Kaplan M, Banwell P, Orgill DP, et al (2005) Guidelines for the management of the open abdomen. *Wounds* 17: S1–S24
- Ljungh et al (2006). Using the principle of hydrophobic interaction to bind and remove wound bacteria. *J Wound Care* 15(4): 175–80
- NICE 2008 Surgical Site Infections
- Percival S, Bowler P (2004) Impact of bacterial communities and biofilms on wound healing. *World Wide Wounds*
- Powell G. (2009) Evaluating Cutimed Sorbact: using a case study approach. *British Journal of Nursing*; 18(15): S30–36
- Schultz, GS, Sibald RG, Falanga V (2003) Wound bed preparation: a systematic approach to wound management. *Wound Rep Regen*, 11; (Suppl 1), S1–28

contact layer covered with absorbent gauze and either a super-absorbent or foam dressing to manage high exudate levels. Dressing changes were undertaken as often as considered clinically necessary; initially daily, but reducing to three times per week over the course of treatment. Determination of infection was based on clinical assessment of the wound bed and swab results.

Cutimed Sorbact swabs were continued for the duration of the patients' hospital stay, not only to treat the infection, but also as a prophylactic approach to reduce the risk of recurrence in these high-risk wounds.

All patients were given a postoperative, five-day course of intravenous antibiotics, but required no other wound-related antibiotics during treatment.

RESULTS

Infection

For all patients, infection had resolved within 14 days, but Cutimed Sorbact was continued prophylactically. No patients had a recurrence of infection during their hospital stay.

Wound Dimensions

Wound size reduced dramatically by 6–10% on a weekly basis throughout treatment (*Table 1*). One patient went onto heal, but the other three were discharged into the community where

regular follow-up was not possible. Of these three patients, one died and two continued to heal.

Wound Healing

The dressings effectively managed devitalised tissue, resulting in 100% granulation tissue within two weeks.

Pain

For all patients, there was a significant reduction in pain associated with dressing changes. Initially, nitrous oxide was administered during dressing changes due to the lengthy procedure. However, following a two-week period this was replaced by oral analgesia administered prior to treatment.

Exudate and odour

In each case, odour and exudate levels reduced significantly over the course of treatment with Cutimed Sorbact. This is due to the effective reduction of wound bioburden by the dressings.

CASE STUDY

Patient 1

February 2012, a 27-year-old female was admitted to hospital after suffering abdominal pain, vomiting and diarrhoea over a period of four days. A laparotomy revealed a sigmoid volvulus, which was corrected. However, four days postoperatively, the patient became unwell and so a second laparotomy was performed, revealing a perforated colon. An ileostomy was formed along with a mucus fistula.

Patient 3

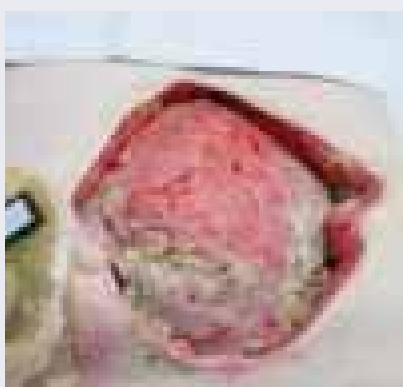

Figure 10: 17 April, the wound measured 16cm x 14cm.

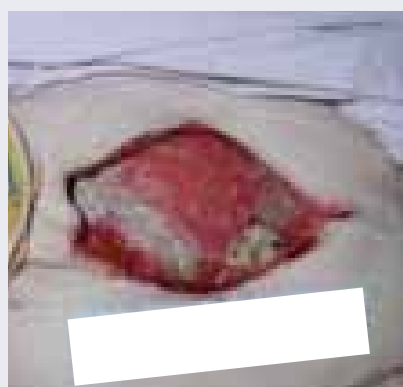

Figure 11: Four weeks later the wound had reduced to 14cm x 7cm.

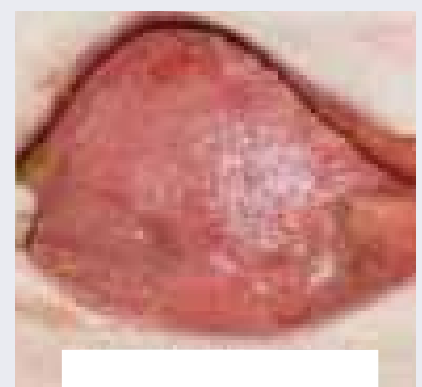


Figure 12: 1 June 2012, the wound bed is clean and granulating with a 50% reduction in length to 6cm x 7cm.

A month later, the incision dehiscid resulting in a wound 28cm x 5cm x 7cm deep with multiple areas of devitalised tissue over the wound bed. The use of Cutimed Sorbact swabs was commenced at this point.

By 19 March, the wound bed was clean and starting to granulate but the mesh remained exposed (*Figure 2*). Two weeks later (*Figure 3*; 5 April), the wound had reduced in size to 22cm x 12cm with granulation tissue now covering the mesh. Progress continued to be made with the wound reducing to 19cm x 9cm by 13 April (*Figure 4*) and to 9cm x 6cm one month later (*Figure 5*; 5 May).

Patient 2

In February 2012, a 52-year-old woman presented with abdominal pain due to a Psoas abscess and sepsis. Past medical history included a gastrointestinal bleed, depression and alcoholism. A laparotomy was performed, which revealed multiple perforated areas of bowel and a large retro-peritoneal abscess. The ischaemic colon was removed from the rectosigmoid to the distal transverse and a colostomy formed.

Nine days postoperatively, purulent discharge was observed at the incision site, resulting in dehiscence creating a wound measuring 23cm x 17cm with slough covering 20% of the wound bed (*Figure 6*). A wound swab indicated the presence of *Escherichia coli*. Cutimed Sorbact swabs were commenced to manage the infection and covered with a foam dressing to absorb exudate. Due to leakage of faecal matter into the wound, daily dressing changes were required.

Twenty-one days postoperatively and following the above dressing regimen, the patient was free from signs of infection, with minimal slough on the wound bed (*Figure 7*). Daily dressing changes were continued to prevent further cross contamination and the wound continued to reduce in size (*Figures 8 and 9*).

Patient 3

Patient 3 is a 78-year-old female who was admitted to hospital following a fall in March, 2012. A computed

Patient 4

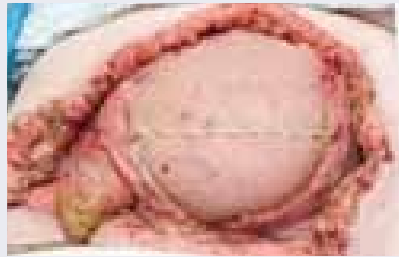

Figure 13: 14 September, 2011 the wound measured 28cm x 28cm.

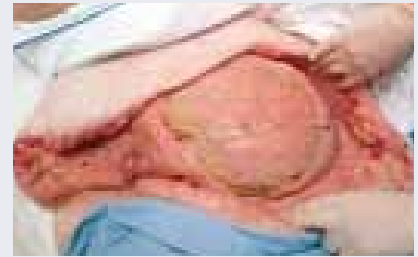

Figure 14: 26 September, 2011, granulation tissue observed.

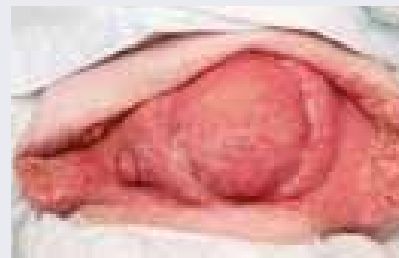

Figure 15: 17 October, 2011 the wound measured 8cm x 26cm.

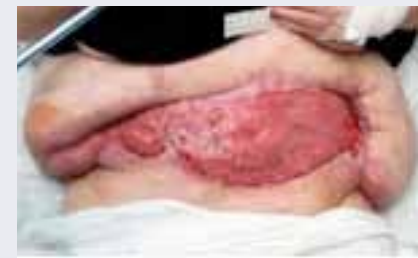

Figure 16: 22 February, 2012 the wound had reduced in size to 8cm x 19cm.

tomography (CT) scan revealed a ruptured spleen and blood in the peritoneal cavity resulting in a splenectomy being undertaken.

Three days postoperatively the patient started vomiting; IV fluids and 'nil by mouth' were initiated. However, the vomiting continued and leakage from the wound was suggestive of faecal matter. A second laparotomy was undertaken, resulting in a colostomy being formed and the patient returned to critical care with an open abdomen.

To prevent infection as a result of

cross-contamination from the stoma, the use of Cutimed Sorbact swabs was commenced. The dressings lined the wound and were then covered with absorbent pads plus an adhesive foam dressing to absorb exudate.

On 17 April, the wound measured 16cm x 14cm (*Figure 10*); a month later it had reduced to 14cm x 7cm (*Figure 11*) and by 1 June it measured 6cm x 7cm (*Figure 12*).

This was deemed to be good progress due to the close proximity of the stoma and continual faecal contamination of the wound bed.

Patient 4

A 69-year-old female was admitted to hospital in September 2011 for a repair of an incisional hernia using a strattice mesh, plus closure of a loop colostomy. Two drains were inserted and an abdominal support applied, but six days post-operatively yellow, thick exudate was observed at the wound site. A second laparotomy was performed, which revealed faecal fluid leaking from the anastomosis site.

Initially, daily dressings were performed under general anaesthetic.



Figure 17: The Cutimed Sorbact range.

A Tissue Viability referral was made and the patient commenced Cutimed Sorbact swabs plus absorbent dressings to manage the high levels of exudate. Due to the inability to isolate the stoma, the wound became contaminated resulting in a need for daily dressing changes. At this stage (14 September), the wound measured 28cm x 28cm (*Figure 13*).

Two weeks later, granulation was observed at the mesh site (*Figure 14*); after a further two weeks (17 October) the wound had reduced to 8cm x 26cm with full granulation tissue over the mesh (*Figure 15*). The wound continued to be treated with this dressing regimen and by February 2012, the wound had reduced in size again to 8cm x 19cm (*Figure 16*).

CONCLUSION

Wound infection complicates treatment and impedes the healing process by damaging tissue, reducing wound strength and inducing an undesirable response. Therefore, controlling or preventing infection and optimising the potential for healing by maintaining an ideal wound environment remains central to good wound care (Schultz et al, 2003).

DACC is a hydrophobic fatty acid that is used to coat Cutimed Sorbact dressings. Wound pathogens are also hydrophobic and in the moist environment of an infected wound bind to the dressing, reducing the bacterial load and helping to kick-start the healing process (Ljungh et al, 2006; Powell, 2009).

As chemicals are not donated into the wound bed, the dressings can be used safely for periods longer than the two-week period recommended for other antimicrobial dressings (International Consensus, 2012) and on all patients and all moist wounds with none of the drawbacks of conventional antimicrobial dressings (Haycocks and Chadwick, 2011b).

These were extremely complex cases, with many barriers to a positive wound healing outcome. However, due to the use of Cutimed Sorbact (*Figure 17*), the wounds continued to progress, remaining free from infection during the patient's stay in hospital. **WUK**