

# THE USE OF TISSUE EXPANSION IN BURN DEFORMITY RECONSTRUCTION: PART ONE

**‘Tissue expanders can be used regardless of the size or location, thus replacing the need for dermabrasion’**

Tissue expansion has been used extensively in the treatment of chronic burn sequelae for three decades. Since the works of Radovan and Austad in 1975, several techniques and indications have been reported. In part one of this two-part review the authors look at the history, pathophysiology and applications to different areas of the body. Part two will deal with expansion techniques and their post-operative complications.

Since their introduction in 1975, tissue expanders have been used for many procedures that encompass both aesthetic and reconstructive aims (Argenta and Marks, 2006). Expanders are used in both paediatric and adult patients (Argenta and Marks, 2006).

Tissue expanders are inflatable reservoirs that are placed under the skin. These reservoirs are connected to a port via tubing that is tunnelled under the skin. Saline solution is injected through the port and transferred to the expander, causing it to increase in size and stretch the overlying skin.

One of the major indications for tissue expansion in paediatric patients is following the excision of congenital nevi (Petres and Muller, 1987; Quaba, 1988). Tissue expanders can be used regardless of the size or location of the defect, thus replacing the need for dermabrasion and the incomplete resection of these lesions (Petres and Muller, 1987; Quaba, 1988). Other indications for tissue expansion in paediatrics include the treatment of:

- ▶▶ Aplasia cutis congenita
- ▶▶ Meningomyelocele
- ▶▶ Microtia
- ▶▶ Hemangioma
- ▶▶ Scrotal reconstruction
- ▶▶ Clubfoot deformity

- ▶▶ Midfacial cleft
- ▶▶ Parry-Romberg syndrome
- ▶▶ Poland syndrome
- ▶▶ Tumor ablation
- ▶▶ Vaginal agenesis
- ▶▶ Volkmann contracture
- ▶▶ Reconstruction for conjoined twins (LoGiudice and Gosain, 2003).

In adults, tissue expansion has been used in the form of implants for aesthetic purposes (breast, buttock or cheek augmentation and flap formation for the reconstruction of scalp defects post hair loss) and for reconstructive purposes (post-mastectomy breast reconstruction, reconstruction of nasal defects, expanded reverse abdominoplasty) (Argenta and Marks, 2006).

Despite some indications specific to either adult or paediatric patients, some are common to both age groups. Examples include the reconstruction of post-burn scars, nasal defects, pre-placement of pumps and other implantation devices, flap preparation for the closure of sternal lesions and hypertrophic scars, and the repair of alopecia caused by trauma or burn injuries (Netscher et al, 2000).

With the advancement in aesthetic and reconstructive surgery, and with the advent of several modalities to replace human skin with synthesised autologous, homologous, and allogenic

## SHADY HAYEK

Assistant Professor in Plastic and Reconstructive Surgery, Hand Surgery, Burn Surgery, American University of Beirut – Medical Center, Beirut, Lebanon

## AMIR IBRAHIM

Senior Resident in Plastic and Reconstructive Surgery, American University of Beirut – Medical Center, Beirut, Lebanon

## ELIAS ZGHEIB

Resident in Plastic and Reconstructive Surgery, American University of Beirut – Medical Center, Beirut, Lebanon

## SHAGHIC CHORBAJIAN

PGY3 at the Department of Family Medicine, Tallahassee Memorial Hospital Tallahassee, Florida, USA

## BISHARA ATIYEH

Professor in Clinical Surgery, Plastic and Reconstructive Surgery, American University of Beirut – Medical Center Beirut, Lebanon

substitutes, tissue expanders have been found to be useful in both required and elective procedures. Nevertheless, the major contribution of tissue expansion is in reconstructive procedures.

The objective of this review is to highlight where tissue expansion is most beneficial, and to review the different expansion techniques used in burns, along with their side effects and complications. This will give the reader an armamentary to choose from when faced with the task of reconstructing a post-burn defect; encouraging the use of autologous tissue over synthetic replacements.

The authors will discuss the use of tissue expanders for the reconstruction of scars obtained after a post-burn injury. They will divide the discussion into sections as per the anatomic area involved in the expansion as well as looking specifically at the paediatric population.

## HISTORY

Tissue expansion is not a modern phenomenon. Perhaps the earliest evidence of tissue expansion in response to tension lies in the biomedical ramifications of pregnancy. Another natural example of tissue expansion is obesity which, when followed by weight loss, will, in most cases, lead to tissue laxity and redundancy (LoGiudice and Gosain, 2003).

Tribes in Africa and Central America deliberately increase the size of their lips and earlobes by ritualistically wearing metallic and wooden rings of increasing sizes, recognising that the labial soft tissues and ear lobes can be stretched to immense proportions by slow mechanical stress. The people of Thailand and Chad have also practised the rituals of cervical and oral-labial expansion, respectively, for centuries (LoGiudice and Gosain, 2003).

The concept of soft tissue expandability appeared as early as 1905 as a concomitant and secondary result of bone lengthening (femur) performed by Codvilla. Unfortunately, the benefits of this went unrecognised at that time (Codivilla, 1904; Matev, 1970; LoGiudice and Gosain, 2003). It was

not until 1957 that the concept of tissue expansion in surgical practice was first reported by Neumann, who described expanding the periauricular skin over a four-month period using a subcutaneously placed rubber balloon and an external port to fill the balloon with air (LoGiudice and Gosain, 2003). He then used the expanded skin to reconstruct a traumatic ear lobe defect in a 52-year-old man. As with many great inventions, his work was treated as anecdotal and generally forgotten.

In 1975, Radovan and Austad took tissue expansion into a new era when they independently developed the concept of adjacent flaps by using a silicone implant (Manders, 1984; Argenta and Austad, 1990; Ghalambor, 2007).

After presenting his experience with breast reconstruction in 1976, Radovan performed his first tissue expansion procedure in 1982. His device contained a self-sealing valve through which saline was periodically injected to increase the size of the prosthesis. He was the first surgeon to gain extensive clinical experience with this method since he immediately started clinical trials without undertaking previous animal or laboratory studies (Radovan, 1982; Nazerani and Motamedi, 2008).

During this period, Austad and Rose (1982) was developing self-inflating silicone prosthesis using osmotic gradients driven by salt placed within the expander. His work was mainly experimental but critical to elucidating the underlying physiological and histological changes of tissue expansion in the laboratory.

In 1981, Argenta et al were the first to describe the application of tissue expansion in the paediatric population, for the treatment of neck contractures in burn patients (Argenta et al, 1983b; LoGiudice and Gosain, 2003). In 1984, Manders et al reported the successful reconstruction of nearly half of the scalp area by expanded hair-bearing tissue (Manders et al, 1984).

These small but important advancements made tissue expansion what it is today and paved the way for future progress.

## KEY WORDS

Tissue expansion  
Burn sequelae  
Capsule  
Adipose skin layer

## References

- Almeida M (2001) Expanded shoulder flap in burn sequela. *Acta Chir Plast* 43(3): 86–90
- Argenta LC, Austad ED (1990) Principles and techniques of tissue expansion. In: McCarthy J (ed). *Plastic Surgery*. W.B. Saunders Company, Orlando, 475–507
- Argenta LC (1984) Controlled tissue expansion in reconstructive surgery. *Br J Plast Surg* 37: 520–529
- Argenta LC, Marks M, Grabb W (1983a) Selective use of serial expansion in breast reconstruction. *Ann Plast Surg* 11(3): 188–95
- Argenta LC, Marks M (2006) Principles of tissue expansion. In: Mathes S, Hentz V (eds). *Mathes Plastic surgery*, Saunders, Philadelphia: 539–568
- Argenta LC, Watanabe MJ, Grabb WC (1983b) The use of tissue expansion in head and neck reconstruction. *Ann Plast Surg* 11: 31–7
- Austad ED, Rose GL (1982) A self-inflating tissue expander. *Plast Reconstr Surg* 70(5): 588–94
- Azzolini A, Riberti C (1991) Programmazione dell'espansione. L'espansione cutanea. Milano: Fogliazza Editore 29–31
- Baker SR (1991) Fundamentals of expanded tissue. *Head Neck* 13(4): 327–33
- Birgfeld CB, Low DW (2006) Total face reconstruction using a pre-expanded, bilateral, extended, parascapular free flap. *Ann Plast Surg* 56(5): 565–8
- Bishop JB, Fisher J, Bostwick J 3rd (1980) The burned female breast. *Ann Plast Surg* 4(1): 25–30
- Buhrer P, Huang T, Yee H, Blackwell S (1988) Treatment of burn alopecia with tissue expanders in children. *Plast Reconstr Surg* 81(4): 512–5.

## KEY POINTS

- ▶ In tissue expansion, changes occur in all tissue layers, including the epidermis, dermis, subcutaneous fat, muscle and bone layers
- ▶ It is important to preserve the capsule as it adds to the blood supply of the flaps and constitutes a smooth surface between the flap and the recipient site
- ▶ Patients with burns and defects in hair-bearing areas present a complicated issue

## References

- Cherry G, Austad E, Pasyk K et al (1983) Increased survival and vascularity of random-pattern skin flaps elevated in controlled, expanded skin. *Plast Reconstr Surg* 72(5): 680–7
- Chun J, Rohrich R (1998) Versatility of tissue expansion in head and neck burn reconstruction. *Ann Plast Surg* 41(1): 11–16
- Codivilla A (1904) On the means of lengthening in the lower limbs, the muscle and tissues which are shortened through deformity. *Am J Orthop Surg* 2: 353–69
- De Filippo R, Atala A (2002) Stretch and growth: the molecular and physiologic influences of tissue expansion. *Plast Reconstr Surg* 109(7): 2450–462
- Diley R, McGeachie G, Prendergast F (1983) Experimental vein grafts in the rat. *Br J Plast Surg* 70(1): 7–12
- Edmond J, Padilla J (1994) Preexpansion galeal scoring. *Plast Reconstr Surg* 93(5): 1087–9
- El-Saadi M, Nasr M (2008) The effect of tissue expansion on skull bones in the paediatric age group from 2 to 7 years. *J Plast Reconstr Aesthet Surg* 61(4): 413–8
- Erçöçen AR, Yilmaz S, Can Z et al (1998) The effects of tissue expansion on skin lymph flow and lymphatics: an experimental study in rabbits. *Scand J Plast Reconstr Surg Hand Surg* 32(4): 353–8
- Filho JM, Belerique M, Franco D, Porchat C, Franco T (2007) Tissue expansion in burn sequelae repair. *Burns* 33(2): 246–51
- Friedman R, Ingram J, Rohrich R, Byrd H, Hodges P, Burns A et al (1996) Risk factors for complications in pediatric tissue expansion. *Plast Reconstr Surg* 98(7): 1242–6
- Gibstein L, Abramson D, Bartlett R, Orgill D, Upton J, Mulliken JB (1997) Tissue expansion in children: a retrospective study of complications. *Ann Plast Surg* 38(4): 358–64.

## PHYSIOLOGICAL CHANGES

Although the end result of tissue expansion and the augmented tissues caused by tumors, pregnancy and other natural phenomena is similar, the pathophysiologic changes underlying these processes are different. In tissue expansion, changes occur in all tissue layers, including the epidermis, dermis, subcutaneous fat, muscle and bone layers. Expansion also affects the lymphatic and blood vessels, both at the macro- and micro-levels.

At the molecular level, several changes occur in tissue expansion, including the loss of elasticity to calmodulin and keratins (Baker, 1991), an increase in fillagrin, and changes to cellular mechanisms, such as the cytoskeletal system, extracellular matrix, enzyme activation, secondary messages, and ion channels.

These changes prove that the mechanical strain of tissue expansion has an effect on the different tissue layers. Studies of the subject were pioneered by Baker and complemented by several others (De Filippo and Atala, 2002).

Prior to Baker's experiments, histopathological studies of the expanded skin showed thickening of all layers of the epidermis. The most common was in the corneum and granulosum layers (Austad et al, 1982). This early thickening was originally thought to be secondary to post-operative oedema, especially since it returns to normal within four to six weeks, although some thickness may persist for a period of months (Azzolini and Riberti, 1991).

It was Austad and Rose (1982) who, using tritiated thymidine integrated into deoxyribonucleic acid (DNA), concluded that the epidermis exhibits increased mitotic activity early after expansion begins, with a subsequent spike in activity seven days later, and that such mitotic activity occurs only in the epidermis and does not involve the dermis (Azzolini and Riberti, 1991). This shows the difference in changes between the various layers of the skin, reflecting macroscopically in the elasticity and future malleability of the skin.

## HAIR

Hair follicles and accessory skin structures are compressed and redistributed during expansion but show no signs of atrophy (Prakash et al, 2006). A study conducted by Lee et al (2000) demonstrated that hairs in the expanded scalp have short telogen cycles and show a significant increase in the proportion of anagen to telogen hair, which compensates for a further reduction in the density of terminal follicles. Consequently, slow tissue expansion has been proposed in order to conserve the integrity of the hair follicle (Ramos, 2007).

Regardless of the processes used to compensate for hair loss — which involve increasing the proportion of anagen to telogen hair, which compensates for a further reduction in the density of terminal follicles — the result is a clear decrease in hair density; a result of increased area with unchanged hair follicle count (Prakash et al, 2006). This finding is important to consider while expanding 'hairy' tissues for use in areas of the body that are both hairbearing and non-hairbearing. It gives the physician the option of transferring different types of tissues while taking into consideration the ethnic background, beliefs, and preferences of the patient.

As for melanotic activity, this has been shown to increase during the process of expansion but usually returns to normal after a few months (Van Rappard et al, 1988).

In contrast to the epidermis, the dermis, the hypoderm and muscle layers become atrophic (Cherry et al, 1983) and new blood vessels are formed within the expanded tissue (Johnson et al, 1988). Thinning of the dermis and flattening of the rete ridges is more pronounced during the initial weeks and usually persists for at least 36 weeks after the expander is removed. It is not affected by either the size or the position of the expander. Thinning is maximal near the dome of the expander and minimal around its edges (Johnson et al, 1988). Expanded tissue also demonstrates a quantitative increase in the collagen content of the dermis but no change in the ratio of type I to

type III collagen (Knight et al, 1990). In addition, there does not seem to be any histologic difference in tissue expansion between adult and paediatric patients (LoGiudice and Gosain, 2003).

### CAPSULE

The capsule is a collection of dense fibrous connective tissue that forms around the implant, and becomes cellular over time (Leighton et al, 1988). It reaches its maximum thickness at two months after expansion and starts developing well-organised collagen deposition in bundles at three months (Thomson, 1973).

It has been argued that the formation of a capsule around the expander masks the thinning of the dermis clinically (Leighton et al, 1988). Thus, the strength of the skin, manifested by the collagen content in its dermis, is slightly altered but strengthened by the capsule formation, and can be used safely in any part of the body, even with a lower blood supply and higher risk of infection.

The capsule is not at risk of dysplastic changes although it may form dystrophic calcifications during the resolving phase of a hematoma, if one should occur (Cherry et al, 1983). It is important to preserve the capsule as it adds to the blood supply of the flaps and constitutes a smooth surface between the flap and the recipient site leading to the optimal adaptation of the flap (Thomson, 1973; Cherry et al, 1983; Leighton et al, 1988).

In an animal study followed by a retrospective review of clinical cases, Kovach et al (2008) demonstrated that the thickness of the capsule can be decreased by administering the expander through a balloon-dissector-assisted approach rather than an open dissection approach. They also concluded that expanders placed in a minimally invasive way, i.e. by making small incisions and using scopes, resulted in shorter expansion times due to the ability to institute immediate expansion. It also improved expansion compared with open placement (Kovach et al, 2008).

Among all the layers of the skin and subcutaneous tissue, the adipose

layer was found to be most affected by thinning (as much as 50% thinning caused by the flattening of the adipocytes and necrosis that takes place compared with non-expanded skin) (Cherry, 1983; Van Rappard et al, 1988; Leighton et al, 1988). This was noticed during the early expansion trials and was also supported by the later studies that were conducted on both pigs and humans (Cherry et al, 1983; Van Rappard et al, 1988; Leighton et al, 1988).

### ATROPHY

Fat atrophy, although considered to be a negative process in certain instances — such as those that occur after fat transfer for augmentation, or fat necrosis in the subcutaneous tissues after suturing a wound in different layers — can be beneficial in tissue expansion. It produces a flap that can be transferred to a recipient site with less fat content than the donor site, and, thus, increases the reconstructive options by giving a flap that is thinner, which can be transferred to places that would need thinner and less bulky flaps, such as the face and neck.

Muscle also atrophies significantly during tissue expansion and is replaced by fibrous tissue (Van Rappard et al, 1988). This process occurs regardless of whether the prosthesis is placed above or below the muscle. Studies have shown that muscle degeneration occurs and the tissue is replaced with glycogen and fibrosis. When expansion occurs under the muscle layer, it has also been shown that the muscle cells grow and that the number of sarcomeres per fibre increases as a response to the stress created by stretching, thus inferring that the expansion of the muscles is secondary to growth (Van Rappard et al, 1988).

### BONES

Bones are also affected by tissue expansion. It has been shown that there is a decrease in bone thickness below the muscle and the expander. This is compensated by an increase in the thickness around the expander's periphery, thus keeping the bone density unaffected (Van Rappard et al, 1988). Because of the transient relative ischaemia that occurs during expansion, blood flow to the expanded

### References

- Gao JH, Ogawa R, Hyakusoku H, Lu F, Hu Z, Jiang P et al (2007) Reconstruction of the face and neck scar contractures using staged transfer of expanded "Super-thin flaps". *Burns* 33(6): 760–63
- Gil T, Metanes I, Aman B, Taran A, Mayblum S, Izhak T et al (2008) Six tissue expansion sessions of the scalp for reconstruction of post-burn alopecia. *J Burn Care Res* 29(2): 390–4
- Ghalambor A (2007) A modified technique for application of tissue expanders for extremities in burn scars patients. *Pak J Med Sci* 23(4): 530–3
- Grevious M, Paulius K, Gottlieb L (2008) Burn scar contractures of the pediatric neck. *J Craniofac Surg* 19(4): 1010–5
- Gürlek A, Alaybeyoğlu N, Demir CY, Aydoğan H, Bilen B, Öztürk A (2004) Aesthetic reconstruction of large scalp defects by sequential tissue expansion without interval. *Aesthetic Plast Surg* 28(4): 245–50
- Hafezi F, Naghibzadeh B, Pegahmehar M, Nouhi A (2009) Use of overinflated tissue expanders in the surgical repair of head and neck scars. *J Plast Reconstr Aesthet Surg* 62(11): 413–20
- Haik J, Grabov-Nardini G, Goldan O, Tessone A, Regev E, Mendes D et al (2007) Expanded reverse abdominoplasty for reconstruction of burns in the epigastric region and the inframammary fold in female patients. *J Burn Care Res* 28(6): 849–53
- Hromadka M, Deschamps-Braly J, Sawan K, El Amm C (2010) Delayed development of toxic shock syndrome following abdominal tissue expansion in a pediatric reconstruction patient: case report. *Ann Plast Surg* 64(2): 254–7
- Hudson DA, Arasteh E (2001) Serial tissue expansion for reconstruction of burns of the head and neck *Burns* 27(5): 481–7
- Hudson DA, Grob M (2005) Optimising results with tissue expansion: 10 simple rules for successful tissue expander insertion. *Burns* 31(1): 1–4

## 'Unlike burns located in other areas of the body, scalp burns can result in significant burn-related alopecia'

### References

Hudson D, Lazarus D, Silfen R (2000) The use of tissue expansion in pediatric plastic surgery. *Ann Plast Surg* 45(6): 589–94

Jackson I (1987) Use of external reservoirs in tissue expansion. *Plast Reconstr Surg* 80(2): 266–73

Johnson P, Kernahan D, Bauer B (1988) Dermal and epidermal response to soft-tissue expansion in the pig. *Plast Reconstr Surg* 81(3): 390–7

Kimura N, Hasumi T, Satoh K (2001) Prefabricated thin flap using the transversalis fascia as a carrier. *Plast Reconstr Surg* 108(7): 1972–80

King W (1997) Editorial: A valuable international bridge to the rehabilitation of burn patients with facial disfigurement. *Burns* 23(2): v–vi

Knight K, McCann J, Vanderkolk C, Coe S, O'Brien B (1990) The redistribution of collagen in expanded pig skin. *Br J Plast Surg* 43(5): 565–70

Kovach S, Koger K, Klitzman B, Germann G, Levin L (2008) Advantages of minimally invasive, balloon-dissector-assisted tissue expander placement, a clinical and experimental study. *Ann Plast Surg* 60(1): 89–97

Lasheen AE, Saad K, Raslan M (2009) External tissue expansion in head and neck reconstruction. *J Plast Reconstr Aesthet Surg* 62(8): 251–54

LeDoux J, Meyer W, Blakeney P, et al (1998) Relationship between parental emotional states, family environment and the behavioural adjustment of pediatric burn survivors. *Burns* 24(5): 425–32

Leedy J, Janis J, Rohrich R (2005) Reconstruction of acquired scalp defects: an algorithmic approach. *Plast Reconstr Surg* 116(4): 54–72

tissues increases and new blood vessels form close to the capsule (Azzolini and Riberti, 1991).

### CIRCULATION

Min et al (1987) used a pig model to demonstrate that expansion of island buttock flaps has no apparent negative effect on the circulation of the flaps. On the contrary, they observed an increase in tortuosity and in the size of vessels supplying the flaps.

The experimental research of Leighton et al (1988) demonstrated that controlled expansion in a pig model was able to induce an increase in capillary density and flow within a buttock flap. The increase in blood flow within the capillaries was found to be similar to that of the 'delay phenomenon' through the realignment of vessels, the closing of cutaneous arteriovenous shunts, neoangiogenesis, and the depletion of neurohumoral vasoactive substances activated by surgical trauma. Delay phenomenon is a process whereby the flap is elevated and kept on its original bed, thus retaining some of its blood supply and causing an increase in capillary density and flow. This is in addition to reorganisation of the blood vessels, which improves flap perfusion and prolongs ischaemic endurance (Pang et al, 1986), making it more beneficial than non-expanded tissues and synthetic replacements when the risk of infection is exponentially higher.

Similarly, it has been shown that in a pre-expanded radial forearm flap, the circulation extended into wider areas of the flap, as shown by cutaneous oxygen tension measurements (Masser and Michael, 1990). Electron microscopy also revealed longer and thicker elastic fibres and active fibroblasts with an abundance of rough endoplasmic reticulum when compared with normal specimens (Diley et al, 1983).

In a study on rabbits, Erçöçen et al (1998) demonstrated a decrease in the lymphatic flow in the expanded tissues. However, the authors showed that the mere insertion of the expander itself resulted in this decreased lymphatic flow as there was no difference in lymphatic flow between expanded and non-expanded (sham-operated) tissues.

The authors concluded that the tissue expander itself reduces the lymphatic flow regardless of expansion and that it interferes with the formation of new lymphatic vessels through its foreign body effect, consequently causing lymphostasis. They did not notice any formation of lymphatic vessels in the capsule which formed around the tissue expander (Erçöçen et al, 1998).

Thus, lymphatic drainage is not improved in expanded tissues but, nevertheless, the tissues are able to withstand higher stresses (including seromas and lymph accumulation) than other alternatives, due to the proven improved blood supply during expansion.

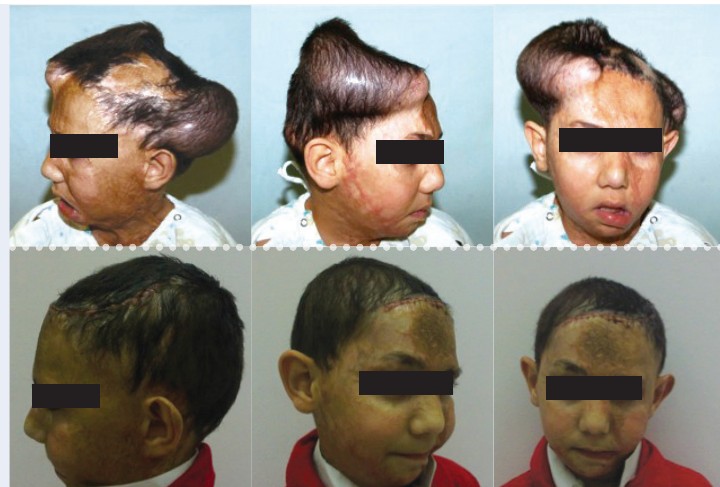### SCALP

Unlike burns located in other areas of the body, scalp burns can result in significant burn-related alopecia (McCauley, 2005). The hair is the most visible feature of the scalp, and it is an inseparable element of a person's external appearance. A lack of hair is a major aesthetic and emotional problem for many. In some cultures hair-bearing areas of the face and head are regarded as signs of manhood and, therefore, burns occurring in that area of the body can be viewed as a deformity (Gurlek et al, 2004; Leedy et al, 2005; McCauley, 2005; Nazerani and Motamedi, 2008).

Patients with burns and defects in hair-bearing areas, the paucity of hair-bearing skin and donor-site problems mean that this is a complicated issue (McCauley, 2005). Deep burns of the scalp responsible for alopecia posed a significant surgical challenge until tissue expansion began to be used in this area in the 1980s (Nazerani and Motamedi, 2008).

The conventional reconstructive methods used before the introduction of tissue expansion, like rotational scalp flaps, serial excision, microvascular flap transfer and free hair transplantation have many drawbacks, such as lengthy hospital stays, flap necrosis and the inability to cover major scalp defects (Zaki, 1989).

Tissue expansion is the treatment of choice for extensive problems,



*Figures 1-3: A six-year-old boy eight weeks after tissue expansion carried out for burn scar alopecia.*

*Figures 4-6: Two weeks after removal of the expanders and rotation of the flap to cover the excised burn scar.*

like burns of the scalp (Figures 1–6), because it addresses issues such as the inextensibility of the scalp, the convex geometry of the skull, and the non-replaceable hair-bearing area (Zaki, 1989). Another reason for considering tissue expansion as the technique of choice for post-burn alopecia reconstruction is the fact that it is the only procedure that allows the development of normal hair-bearing tissue to cover the areas of alopecia. It can cover an area of scalp alopecia of more than 50cm<sup>2</sup> with the use of only one expander (Argenta and Marks, 2006; Voulliaume et al, 2007), and with skin of the same color and hair bearing properties as the tissue lost to the defect (Gil et al, 2008).

The use of tissue expanders in plastic and reconstructive surgery is so well established for post-burn alopecia that it is also being used for other applications like androgenetic alopecia, traumatic alopecia, male pattern baldness, and congenital nevi (Maves and Lusk, 1987; El-Saadi and Nasir, 2008). Furthermore, it should always be indicated for the repair of severe functional and/or aesthetic injuries, although restricted to patients with healthy skin amenable to regular expansion and who are psychologically stable (Leedy et al, 2005). Cost benefit analysis and morbidity rates should always be performed and compared with other procedures (Leedy et al, 2005). Finally, consideration must be given to certain difficulties, such as limited donor site, involvement of several areas, patients who are emotionally distraught, the need for repeated

surgical procedures or the use of several expanders and long-term treatment or follow-up (Filho et al, 2007).

Subgaleal expansion shows typical biphasic progress (pain followed by loosening) (Voulliaume et al, 2007). An initial period of uncomfortable resistance is followed after few weeks, by scalp loosening and destruction of the barrier. Continuous and rapid increase of skin expansion then takes place (Voulliaume et al, 2007).

Prakash et al (2006), inspired by Edmond and Padilla (1994) before them, raised the issue of supragaleal expansion in a study conducted on 13 patients. They concluded that expanders can be placed in the supragaleal plane instead of the subgaleal plane, excluding the tough galeal layer (Prakash et al, 2006). However, Prakash et al's findings were debated by others (Ramos, 2007). For example, Ramos believes that 'galeal tissue is important to protect the integrity of the hair follicles, preserving their circulation during the procedure and the expansion'. In the same correspondence he mentions that the excessive bleeding that occurs in a non-vascular plane, such as the subgaleal one, may lead to more reactive tissue around the prosthesis. Moreover, this will lead to the cauterisation of vessels, causing injury to the hair follicles and local alopecias (Ramos, 2007).

To summarise, tissue expansion techniques have become safe and successful in treating post-burn alopecia of the scalp (Zuker, 1987; Buhner et al, 1988; ). Although the technique has some disadvantages, such as the need to

## References

- Lee Y, Gil MS, Hong JJ (2000) Histomorphologic changes of hair follicles in human expanded scalp. *Plast Reconstr Surg* 105(7): 2361–5
- Leighton W, Russell R, Feller A, Eriksson E, Mathur A, Zook E (1988) Experimental pretransfer expansion of free-flap donor sites. II: Physiology, histology, and clinical correlation. *Plast Reconstr Surg* 82(1): 76–87
- Levin S, Aponte R, Germann G (1997) Endoscopic tissue expansion of the upper extremity. *Op Techniq Plast Reconstr Surg* 4(1): 24–30
- LoGiudice J, Gosain AK (2003) Pediatric tissue expansion: indications and complications. *J Craniofac Surg* 14: 866–72
- Long R, Cope O (1961) Emotional problems of burned children. *New Engl J Med* 264: 1121–27
- Loss M, Infanger M, Kunzi W et al (2002) The burned female breast: a report on four cases. *Burns* 28(6): 601–5
- Lu F, Gao J H, Ogawa R, Hykusoku H (2006) Preexpanded distant 'super-thin' intercostal perforator flaps for facial reconstruction without the need of microsurgery. *J Plast Reconstr Aesthet Surg* 59(11): 1203–8
- MacLennan S, Wellsc M, Neale H (2000) Reconstruction of the burned breast. *Clin Plast Surg* 27(1): 113–9
- Mackinnon S, Gruss J (1985) Soft tissue expanders in upper limb surgery. *J Hand Surg Am* 10(5): 749–54
- Manders EK, Schenden MJ, Furrey JA, Hetzler PT, Davis TS, Graham WP (1984) Soft-tissue expansion: concepts and complications. *Plast Reconstr Surg* 74(4): 493–507

## References

- Margulis A, Agam K, Ickson M, Dotan L, Yanko-Arzi R, Neuman R (2007) The expanded supraclavicular flap, prefabricated with thoracoacromial vessels, for reconstruction of postburn anterior cervical contractures. *Plast Reconstr Surg* 119(7): 2072–7
- Masser MR, Michael R (1990) The pre-expanded radial free flap. *Plast Reconstr Surg* 86(2): 295–301
- Matev I (1970) Thumb reconstruction after amputation at the metacarpophalangeal joint. *J Bone Joint Surg* 52: 957–965.
- Maves MD, Lusk RP (1987) Tissue expansion in the treatment of giant congenital melanocytic nevi. *Arch Otolaryngol Head Neck Surg* 113(9): 987–91
- McCauley R (2005) Hair restoration: State of the art. *Semin Plast Surg* 19(2): 143–152
- Min Z, Olin T, Svedman P (1987) Viability and vascularization of an expanded buttock island flap in the pig. *Ann Plast Surg* 19(5): 409–13.
- Motamed S, Kalantar Hormozi A, Marzban S (2003) Expanded occipito-cervico-pectoral flap for reconstruction of burned cervical contracture. *Burns* 29(8): 842–4
- Motamed S, Niazi F, Atarian S, Motamed A (2008) Post-burn head and neck reconstruction using tissue expanders. *Burns* 34(6): 878–84
- Nakamoto H, Herson M, Cunha M, Ferreira M, Milcheski D, Sturtz G, et al (2001) Expansores teciduais em tratamento de sequelas de queimaduras. *Rev Bras Queimaduras* 1(1): 21–24
- Nazerani S, Motamedi MHK (2008) Reconstruction of hair-bearing areas of the head and face in patients with burns. *Eplasty* 8: 41
- Neale H, High R, Billmire D, Carey J, Smith D, Warden G (1988) Complications of controlled tissue expansion in the paediatric burn patient. *Plast Reconstr Surg* 82(5): 840–8
- Neale H, Kurtzman L, Goh K, Billmire D, Yakuboff K, Warden G (1993) Tissue expanders in the lower face and anterior neck in pediatric burn patients: limitations and pitfalls. *Plast Reconstr Surg* 91(4): 624–31
- perform two operations, frequent injection of fluids, transient but definite discomfort experienced with expansion and contour changes during the latter stages that may limit the patient's social interactions, and consequent emotional disturbances, several advantages have been proven. These include faster closure, fewer operations and decreased total length of hospitalisation (Zuker, 1987; Buhrer et al, 1998).
- TRUNK**
- The trunk is considered an ideal place for harvesting tissue (expanded or not) due to its large area and its proximity to other body surfaces. It is also the area least affected by burns, partly because of the protection offered by clothes (Tempest and Atkins, 1958). Nevertheless, reports of burns affecting the majority of the trunk surface area have been described in the literature and methods of reconstructing the post-burn sequelae have been proposed, such as the use of tissue expanders placed in various areas of the trunk, or the sequential excision of burn scars.
- BREAST**
- In 1980, Bishop et al addressed burns to the female breast by using expanded tissue above the latissimus dorsi to reconstruct defects with a musculocutaneous flap. This resulted in a better aesthetic outcome and a shorter hospital stay. Bishop et al (1980) also concluded that the use of the latissimus dorsi flap without tissue expansion is a useful way of reconstructing circular burns of the whole trunk. This technique was questioned by MacLennan et al in 2000, when they argued that primary closure of the donor site in these cases could be problematic and promoted the use of tissue expansion over the donor areas before reconstruction (Bishop et al, 1980; MacLennan et al, 2000).
- On the other hand, Argenta in 1983 placed expanders under the pectoralis muscle in patients with burn injuries that had caused a malformation of the breast, a method which was also utilised by MacLennan et al for the reconstruction of breast deformities (Argenta et al, 1983a; MacLennan et al, 2000).
- Furthermore, in 1984, Radovan concluded that breast reconstruction is an area in which the use of tissue expanders has been of greatest benefit. The use of tissue expanders in the reconstruction of breast deformities has been studied by several surgeons such as Loss et al (2002), Still et al (1998) and Pitanguy et al (2002), who used conventional techniques with serial tissue expansion. It was not until the early 2000s that new techniques and modifications for the reconstruction of post-burn sequelae of the chest area were introduced.
- Although expanders have been extensively used for the reconstruction of breast deformities, they have also been placed for reconstruction of epigastric, abdominal and back scars (Motamed et al, 2003; Haik et al, 2007). In 2003 Motamed et al described the use of expanded occipito-cervico-pectoral flaps for the reconstruction of severe burn scars to the neck, shoulder and back in a patient whose chest area was not burned (Motamed et al, 2003). This study was supplemented by several others who used tissue expansion to create flaps covering local defects, sometimes with the overexpansion technique and at other times using multiple expanders. All came to the conclusion that it is easier to expand tissue in the abdomen than in the back (Haik et al, 2007).
- For the reconstruction of burns in the epigastric area, which affect the inframammary fold, a 'reverse abdominoplasty' technique was used by Haik et al (2007). This technique encompasses the expansion of the lower abdominal skin, locally advancing it to the epigastrium to cover the scarred area with tissue of similar characteristics (Haik et al, 2007). As mentioned earlier, several techniques have been used to harvest tissue from the trunk for the reconstruction of the face and neck areas in addition to the extremities. These include the prefabricated thin flap using the transversalis fascia as a carrier, as described by Kimura et al (2001) and the pre-expanded distant 'super-thin' intercostal perforator flaps for facial reconstruction that does not require microsurgery, as described by Lu et al (2006).
- EXTREMITIES**
- Unlike in other areas of the body, tissue expansion in the extremities (Figures 7–13) has been used for the treatment of functional, rather than aesthetic, purposes (Ghalambor, 2007).
- The most common indication for tissue expansion in the extremities is the removal of disfiguring and function-limiting scar

tissue after surgery, trauma, burns, tattoos and giant nevi (Van Beek and Adson, 1987). Whether or not the complications of tissue expansion in burn patients are higher in the extremities than in other body areas is still controversial (Argenta, 1984; Mackinnon and Gruss, 1985; Jackson, 1987). Different authors describe different rates of burn complications in the extremities and other parts of the body. Maybe this is due to the heterogeneity of the mechanism of injury, the percentage of injury and other factors. This remains unproven.

Some authors concluded that complications were more common in the lower extremities (40%–60%), compared with the upper extremities (10%–45%) (Argenta, 1984; Mackinnon, 1985; Jackson, 1987). On the other hand, in 2007 Filho et al stated that the rate of complications with tissue expansion for treatment of burn sequelae ranged in the literature from 7.3% to 24.5%, with the most frequent locations being the head and neck followed by lower limbs (Van Beek and Adson, 1987; Almeida, 2001; Nakamoto et al, 2001; Pitanguy, 2002).

Absolute complications necessitating termination of the expansion process range from 12.0% to 85.3% and relative ones between 14.6% and 32.0% (Pitanguy, 2002).

Higher rates of complications in the extremities are attributed to the terminal nature of the vascular and lymphatic supply, which does not tolerate compression or undermining (Mackinnon and Gruss, 1985). A typical complication is nerve entrapment, whereby the tissue expander decreases the blood supply to the underlying tissues or even cuts it off (Bauer et al, 1990). Thus the need for proper patient selection becomes important (Chun and Rohrich, 1998).

In the lower limb, as previously mentioned, more complications are seen with tissue expansion (Argenta, 1984; Mackinnon and Gruss, 1985; Jackson, 1987). Expansion is better tolerated in the thighs than below the knee and the foot. This might be due to the fact that the vascularity in the thigh is higher in contrast to the leg (Mackinnon and Gruss, 1985). As mentioned before, crush injuries below the knee or burns involving greater than 50% of the extremity are also associated with expansion failure (Levin et al, 1997). With good patient selection and by applying a slower expansion rate,

tissue expansion in the extremities can be considered a safe and effective method for the reconstruction of defects and contractures caused by post-burn sequelae.

### PAEDIATRICS

Although tissue expansion in the paediatric patient is derived from the same basis as in adults, some differences in the operative procedure, complications, psychological effect and other aspects make expansion in a paediatric burn patient more difficult (Friedman et al, 1996; Hudson et al, 2000).

It is also important to note that contractures caused by burns might result in skeletal deformities in a growing body (e.g. distorting facial features in repose and during animation, and altering the growth and development of the mandible and spine) and may also alter speech and normal functional development (Hudson et al, 2000).

Neale et al's 1993 study, along with a previous study conducted by the same author (Neale et al, 1988), conclude that the rate of complications when using tissue expanders was highest in the neck. The authors also concluded that tissue expansion post-burn injury in the paediatric age group resulted in the least amount of contractures and donor site morbidity but, nevertheless, it advised that alternative methods (direct excision and non-expanded flaps) might achieve the same results (Neale et al, 1993; Neale et al, 1988).

Expansion techniques have also been used in the reconstruction of post-burn scalp alopecia in paediatric patients (Buhrer et al, 1988; Silfen et al, 2000; Oh et al, 2007). In the past, the process of serial excisions and flap use was tedious and required several operations for the removal of a small (15% of the hair bearing scalp alopecia) defect with a long hospital stay of around 13 days and an overall process duration of two years.

Tissue expansion has been shown to reduce hospital stays to eight days and to decrease the length of the process and the number of operations compared with serial excision techniques. The technique could also be used for larger defects (Buhrer et al, 1988). Buhrer et al went further to modify the use of the expanders by increasing their size, hyperexpanding them and using multiple expanders at once (Buhrer et al, 1988). Several studies have stressed the fact that the major difference between the adult

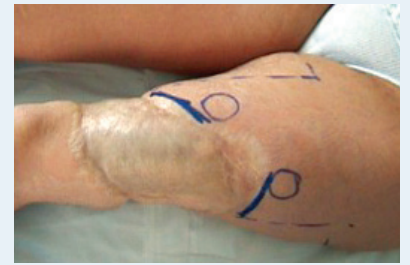


Figure 7: Healed thigh wound covered by split thickness skin graft following trauma sustained in childhood. Plans for placement of two expanders (laterally and medially) are made.

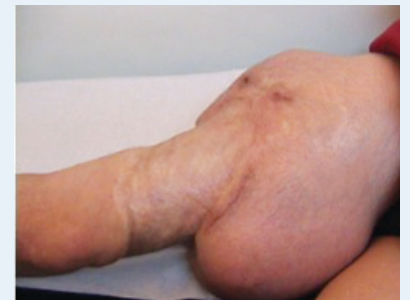

Figure 8: Tissue expansion near completion.

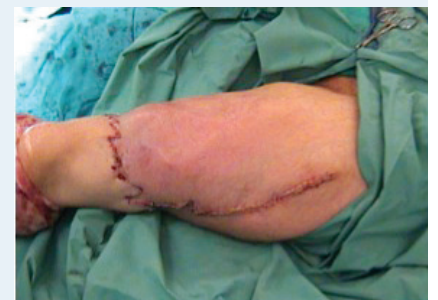

Figure 9: Tissue expansion allowed scar revision with complete excision of the skin graft.

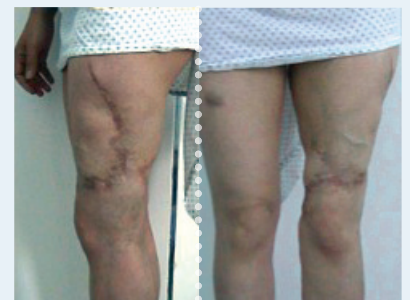


Figure 10: Final result at one month post-operatively. Further contour correction of the left thigh was subsequently achieved with autologous fat injection.



## References

- Netscher D, Davino N, Armenta A (2000) Abdominal tissue expansion aids in placement of the Baclofen pump and other implantation devices. *Plast Reconstr Surg* 106(6): 1437–1439
- Pallua N, Demir E (2008) Postburn head and neck reconstruction in children with the fasciocutaneous supraclavicular artery island flap. *Ann Plast Surg* 60(3): 276–82
- Pallua N, Von Heimburg D (2005) Pre-expanded ultra-thin supraclavicular flaps for (full-) face reconstruction with reduced donor-site morbidity and without the need for microsurgery. *Plast Reconstr Surg* 115(7): 1837–44
- Pang C, Forrest C, Neligan P, Lindsay W (1986) Augmentation of blood flow in delayed random skin flaps in the pig: Effect of length of delay period and angiogenesis. *Plast Reconstr Surg* 78(1): 68–74
- Pitangy I, Gontijo de Amorim N, Radwanski H, Lintz J (2002). Repeated expansion in burn sequela. *Burns* 28(5): 494–99
- Petres J, Muller RPA (1987) Treatment of congenital pigmented nevi by dermabrasion. In: Happle R, Grosshans E (eds). *Pediatric Dermatology* Springer-Verlag, Berlin: 135
- Prakash V, Tandon R, Mantri R (2006) Supragaleal placement of tissue expander for post-burn alopecia. *J Plast Reconstr Aesthet Surg* 59: 1102–04
- Pribaz J, Fine N, Orgill D (1999) Flap prefabrication in the head and neck: a 10-year experience. *Plast Reconstr Surg* 103(3): 808–20
- Quaba A (1988) Reconstruction of a post-traumatic ear defect using tissue expansion: 30 years after Neumann. *Plast Reconstr Surg* 82(3): 521–24
- Ramos RR (2007) Tissue expanders in post-burn alopecia: supragaleal or subgaleal placement? *J Plast Reconstr Aesthet Surg* 60(8): 968
- Radovan C (1982) Breast reconstruction after mastectomy using a temporary expander. *Plast Reconstr Surg* 69(2): 195–208
- Radovan C (1984) Tissue expansion in soft-tissue reconstruction. *Plast Reconstr Surg* 74(4): 482–92
- Oh S, Jung Y, Lee J, Seo D, Koh J, Kim Y (2007) Tissue expansion technique for the correction of the burn alopecia. *Burns* 33(Suppl 1): S75
- Silfen R, Hudson D, Soldin M, Skoll P (2000) Tissue expansion for frontal hairline restoration in severe alopecia in a child. *Burns* 26: 294–97
- Sniezek J, Sabri A, Burkey B, David B (2000) Reconstruction after burns of the face and neck. *Curr Opin Otolaryngol Head Neck Surg* 8: 277–81
- Still J, Craft-Coffman B, Law E (1998) Use of pedicled flaps and tissue expanders to reconstruct burn scars of the anterior abdomen and chest wall. *Ann Plast Surg* 40: 226–28

and the paediatric burn population is the psychosocial changes a person experiences (Long and Cope, 1961; Neale et al, 1993; Long and King, 1997; LeDoux et al, 1998; Silfen et al, 2000).

In 1993, Neale et al stated that even a modest improvement of facial burn scarring made a tremendous psychological difference to children who are forming their body images (Neale, 1988). Silfen et al added in 2000 that repeated hospitalisation is traumatic for every child (Silfen et al, 2000). Others also attested to the deleterious psychological effects that burns have on children (Long and Cope, 1961; LeDoux et al, 1998). It has also been reported that psychological and psychosocial adjustment after a burn is not necessarily directly related to the severity of injury, but to its location, and that 10–40% of burnt patients experience long-term psychological and psychosocial problems (Long and Cope, 1961; LeDoux et al, 1998). This is especially true when the burned areas are exposed (King, 1997; Robert et al, 1998).

In addition to the psychological side effects, and like any other process in the treatment of a paediatric patient, it is also important to take into consideration the commitment of the family and how this might affect patient compliance. Compliance is a crucial factor, especially in tissue expansion, where several visits would be needed for the inflation of the expander and post-operative flap follow-up (LeDoux et al, 1998).

As for the effect of age on the complication rate in tissue expansion, Gibstein and his colleagues (1997) found in a series of 105 patients that children aged between one and 12 years were at higher risk of developing expander-related complications than infants and adolescents because of a higher risk of disrupting or deflating their expanders. Another series looking at children undergoing tissue expansion between the ages of eight months and 15 years found that children under the age of seven were at higher risk of complications (Friedman et al, 1996).

Thus, when considering paediatric tissue expansion, there are several issues that are different from the adult procedure (Long and Cope, 1961; King, 1997; Zeitlin, 1997; LeDoux et al, 1998; Robert et al, 1998). Firstly, anxiety is higher in children (Long and Cope, 1961; LeDoux et al, 1998).

Secondly, the compliance of the child is determined by the commitment of his or her caregivers (LeDoux et al, 1998). Thirdly, the need for patient and family education is paramount, and the involvement of child life specialists may be beneficial (LeDoux et al, 1998). Finally, the disfiguring process of tissue expansion might have the potential to cause short- or long-term psychological sequelae (LeDoux et al, 1998).

## FACE AND NECK

It is not surprising that burns to the face and neck, regardless of their size and location, always have worse physical and psychological sequelae than in any other area of the body (Argenta et al, 1983b; Neale, 1993; Chun and Rohrich, 1998; Grevious et al, 2008; Motamed et al, 2008).

Physical sequelae can be classified into functional and aesthetic (Gil et al, 2008). Functional sequelae arise from the contractures and include a limitation in the range of motion of the neck, kyphoscoliosis, airway problems, oral incontinence, drooling, inability to phonate properly, ectropion, dental imbalance, and the inability to express emotions adequately (Gil et al, 2008).

Aesthetic sequelae include loss of facial hair, bony and cartilaginous deformation, loss of the aesthetic units (the face is classified into various aesthetic units), in addition to the creation of asymmetry (Gil et al, 2008).

The aforementioned sequelae of burns tend to overshadow the less prominent psychological effects that should not be ignored in the evaluation of a patient with a face and neck burn (Gil et al, 2008).

Although psychological changes occur in every patient with a burn injury, studies have shown that these are greater when the injury occurs early in life, and in an exposed area that is crucial to daily life activities and social interactions (Gil et al, 2008).

Subsequently, the management of burn scars in the face and neck are the most challenging for a plastic surgeon, partly because of the causes mentioned above but also, for example, because the lack of tissues available for reconstruction might make it a challenging process (Nazerani and Motamedi, 2008).

Also, in some cultures (such as those

from the Middle East), hair on the face is considered a sign of manhood (Nazerani and Motamedi, 2008).

Reconstruction is very difficult because of the unique type, thickness and orientation of the facial hair (Nazerani and Motamedi, 2008). To make the picture more complicated, the surgeon may find him or herself excising normal (though precious) tissues in order to reconstruct the involved areas as complete aesthetic units (Sniezek et al, 2000). Thus it is imperative that the surgeon takes these factors into account when planning treatment in order to manage the expectations of the patient and optimise the outcome (Sniezek et al, 2000).

Certain general guidelines should be followed when using tissue expansion in reconstructing the face and neck area to avoid complications (Sniezek et al, 2000). For example, avoiding vertical scars in the neck area will prevent linear contractures and maintain a better range of motion. Advantages of tissue expansion over split/full thickness skin grafts in the neck/face area include (Sniezek et al, 2000):

- ▶ Reconstruction with tissues of similar consistency, colour and thickness
- ▶ Tissue expansion tends to thin the tissue that needs to be transferred to the neck or face, making it physiologically similar to the recipient skin
- ▶ Tissue expansion results in reorganisation of the skin components, decreasing the risk of contraction of the transferred tissue (being a flap or a skin graft), resulting in a better outcome
- ▶ When expanding scalp tissue and transferring it to reconstruct the hair-bearing areas of the face, expansion would result in a decrease in the density of the hair follicles rendering it closer to the facial hair pattern.

#### COMMON QUESTIONS

##### What is the optimal timing of tissue expansion for reconstructing face and neck burns?

Sniezek et al (2000) suggested that 'immediate surgery is indicated for debridement of acute chondritis, covering of critical structures that become exposed (i.e. cornea) or when the scar limits function and is not responsive to conservative measures.' Otherwise, all other reconstructive surgeries should be delayed until wound healing is complete and scars have matured.

NEW

## 3M™ Tegaderm™ Superabsorber Dressing



Locks in  
exudate  
unlocks  
savings



To speak to a  
customer services  
representative call  
01509 611611



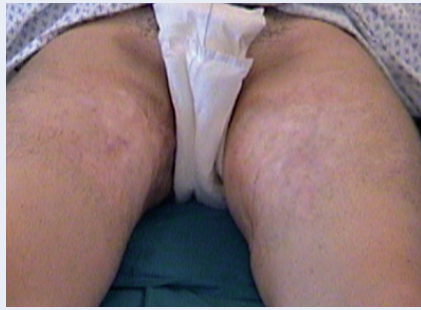

Figure 11: Burn scars on both upper medial area of thighs.

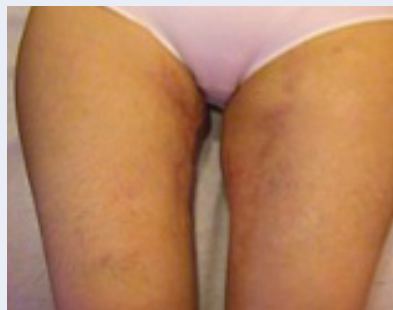

Figure 13: Final result four months postoperatively.

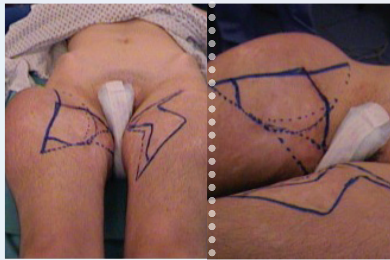


Figure 12: Scar revision of the right thigh planned following expansion. of the lateral thigh. Skin expansion was not necessary for revision of the left medial thigh scar.

## References

Takushima A, Harii K, Asato H (2002) Expanded latissimus dorsi free flap for the treatment of extensive post-burn neck contracture. *J Reconstr Microsurg* 18(5): 373–77

Tempest MN, Atkins JB (1958) The Influence of Clothing on the Pattern and Severity of Burns Studied in some Recent Colliery Fire-Damp Ignitions, *Br J Ind Med* 15(3): 147–157

Thomson H (1973) The fate of pseudosheath pocket around silicone implants. *Plast Reconstr Surg* 51(6): 667–71

Van Beek A, Adson M (1987) Tissue expansion in the upper extremity. *Clin Plast Surg* 14: 535–42

Van Rappard J, Sonneveld J, Borghouts J (1988) Histologic changes in soft tissues due to tissue expansion. *Facial Plast Surg* 5(4): 280–6

Voulliaume D, Chichery A, Chekaroua K (2007) Tissue expansion in surgical treatment of burn scars of the scalp. *Ann Chir Plast Esthet* 52(6): 590–9

Zaki M (1989) The use of tissue expansion for reconstruction of post-burn alopecia. *Annals of the MBC* Available at: [http://www.medbc.com/annals/review/vol\\_2/num\\_2/text/vol2n2p95.htm](http://www.medbc.com/annals/review/vol_2/num_2/text/vol2n2p95.htm) (accessed 10 February, 2012)

Zeitlin R (1997) Long-term psychological sequelae of pediatric burns. *Burns* 23: 467–72

Zuker R (1987) The use of tissue expansion in pediatric scalp burn reconstruction. *J Burn Care Rehabil* 8(2): 103–106

## What is the optimal shape of the expander to be used? How can we estimate the size to be used and the position of insertion?

It is now clear beyond any doubt that the rectangular shaped expander gives the maximum volume of expansion and the maximum amount of tissue to be transferred. However, in the head and neck areas, tissue loss is usually irregular and the topography of the area to be expanded may be convex/concave (Sniezek et al, 2000). In these areas a circular or semi-lunar expander might be preferred (Sniezek et al, 2000).

Jackson et al (1987) argue that the placement of the inflation port externally resulted in lesser complications (since less dissection was needed) and easier expansion, since it can be performed by any caregiver. Others suggested that the placement of an external port led to a higher rate of infections related to the expander (Hromadka et al, 2010).

On the other hand, Lasheen et al suggested the use of an external tissue expander in head and neck reconstruction using negative rather than positive pressure to induce the expansion process and argued that this avoided the complications found in internal tissue expansion (Lasheen et al, 2009).

Hudson and Arasten (2001) reported that serial expansion was associated with a high rate of complications and that the expansion was slow and little advancement was achieved each time. On the other hand, advocates of the over-expansion technique argued that over-inflation (especially of a small expander) yielded

better results (Hafezi et al, 2009). They also argued that using a small expander would be better than over-inflating a larger one due to the need for less dissection during the placement, and a resulting reduction in widening of the scar. This method yields more excess skin compared with the use of a larger prosthesis (Hafezi et al, 2009).

In order to achieve skin quality that is as close as possible to the skin to be replaced in colour, thickness and consistency, tissue should be harvested from adjacent sites, which lie mainly in the supraclavicular area and have the same colour and texture (Pallua and Von Heimburg, 2005; Margulis et al, 2007; Pallua and Demir, 2008).

But in some cases, the burn involves the entire head and neck area, thus the use of expanded tissue from other sites (with certain modifications) needs to be considered (Birgfeld and Low, 2006; Gao et al, 2007).

This tissue can be transferred as an island flap (Pallua and Demir, 2008), free flap (Takushima et al, 2002; Birgfeld and Low, 2006), or as an expanded full thickness skin graft. The tissues can also be prefabricated to reconstruct complex structures, such as the nose, ear or mouth (Pribaz et al, 1999). This involves placing tissue under the flap before transferring it to the recipient site. An example would be the placement of a cartilage graft under the flap before transferring it to the nose.

## CONCLUSION

It is clear that tissue expansion techniques have been instrumental in the development of reconstructive procedures.

They have been particularly successful in treating post-burn alopecia of the scalp, since they can overcome the difficulties posed by the inflexible nature of the scalp, the convex shape of the skull and the non-replaceable hair-bearing area.

In fact, tissue expansion allows for quicker closure and fewer operations than alternative methods for treating post-burn alopecia.

The second part of this review will detail the different expansion techniques, as well as looking at the complications and side-effects involved. **WUK**