

SURGICAL OPTIONS IN THE MANAGEMENT OF INTRANSIGENT LEG ULCERS

KEY WORDS

- ▶▶ Bypass
- ▶▶ Compression bandage
- ▶▶ Duplex
- ▶▶ Ulcer.

Chronic leg ulcers can be defined as a breach in the epithelial integrity of the skin which occurs between the ankle and the knee for over six weeks. Although a large proportion (comprising arterial, venous, pressure and diabetic ulcers) can be treated conservatively, some ulcers would benefit from early surgical input and intervention. This article provides guidance on when such patients should be referred for surgical opinion and what surgical options are available. Finally, amputation and prosthetic options available will be considered.

An estimated 1% or more of the British population suffers with debilitating chronic leg ulcers (Sarkar and Ballantyne, 2000). These patients often suffer with chronic pain, recurrent wound infections, decreased mobility, impaired work capacity, negative body image, reduced health-related quality of life, and an increased risk of amputations. A significant number of these patients are managed in the community over a protracted course by district nurses, tissue viability nurses, podiatrist and general practitioners with varied expertise.

With the unprecedented rise in the aging population, the prevalence of leg ulcers has risen to a point where it has become a significant economic burden, consuming a large proportion of primary care resources. Therefore, it has become imperative to study the aetiology of this disease and review current evidence surrounding the management of chronic leg ulcers.

Thus, an understanding of the aetiology of ulcers is needed to help guide their treatment and management. In 460 BC, Hippocrates, who himself had an ulcer, made the first reference to dependency-related venous dysfunction as a cause of leg ulceration and his recommendations of using compression bandages to drive out 'evil humours' has, to date, withstood the test of time. While approximately 75% of all ulcers are due to venous insufficiency, approximately 20% are due to arterial disease and a smaller proportion are due to vasculitides, diabetes, pressure, dermatitis,

pyoderma gangrenosum, infection and malignancy (SIGN, 2010). A careful history and examination will unravel the mystery of the underlying cause and specialised investigations can be used to confirm this. Although the majority of venous ulcers can be managed in the community, in the authors' clinical experience most other types of ulcers need specialist intervention.

This article highlights the features that should trigger specialist referral and discusses the surgical options available for the treatment of refractory leg ulcers.

CLINICAL ASSESSMENT

Assessing the patient

Venous ulcers

The majority of chronic leg ulcers occur due to chronic venous hypertension resulting from incompetence of the valves in the deep or superficial system (Grey et al, 2006). Therefore, the initial assessment should cover the past history of:

- ▶▶ Deep venous thrombosis
- ▶▶ Varicose veins
- ▶▶ Venous surgery
- ▶▶ Sclerotherapy
- ▶▶ Thrombophlebitis
- ▶▶ Leg fractures
- ▶▶ Infections
- ▶▶ Pregnancy.

Arterial ulcers

Approximately 22% of patients with chronic leg ulcers have underlying arterial disease (SIGN, 2010). The majority of arterial ulcers occur as a result of atherosclerosis. However, a smaller proportion occur as a result of thrombotic conditions, such as

TANIA DE SILVA

Registrar in General and Vascular Surgery, Chesterfield Royal Hospital

STUART ENOCH

Speciality Registrar in Plastic Surgery, University Hospitals of Manchester and Programme Director, Doctors Academy

diabetes, vasculitis, thrombangitis, sickle cell anaemia and thalassaemia (Grey et al, 2006). A history of intermittent claudication, rest pain, cardiovascular and cerebrovascular disease should be obtained. Also, modifiable risk factors such as diabetes, hypertension, hyperlipidaemia and smoking.

Rheumatoid arthritis and systemic vasculitides

These account for 9% of all chronic leg ulcers (SIGN, 2010). Systemic evidence of rheumatoid arthritis and splinter haemorrhages should be sought in these patients. Ulcers relating to systemic vasculitis will usually be multiple, deep, necrotic and have an atypical distribution. A differential diagnosis if pyoderma gangrenosum and an ulcer is related to Felty's syndrome should also be considered.

Diabetes

Five per cent of patients with diabetes develop arterial, venous, neuropathic or mixed ulcers (SIGN, 2010).

As well as assessing the aetiology of the ulcer, it is also important to ascertain information regarding the patient's comorbidities and general physiological status, as this influences the management of the ulcer, suitability for surgery and prognosis. In particular, factors such as obesity, malnutrition, intravenous drug use, steroid use and coexisting medical conditions, which may contribute towards delayed healing, should be assessed. Exploring the impact of the ulcer on the patient's mobility, quality of life and their expectations from treatment is vital for successful management.

Assessing the leg

Both legs should be assessed for venous and arterial disease. Signs of venous disease include:

- ▶▶ Varicose veins
- ▶▶ Venous dermatitis
- ▶▶ Haemosiderin pigmentation
- ▶▶ Pitting oedema
- ▶▶ Lipodermatosclerosis
- ▶▶ Atrophic blanche.

If these signs are present, a venous duplex scan should be requested to assess the patency of the deep and superficial systems and competence of their valves. It is also important to assess for arterial supply before the application of compression therapy, which is the standard treatment for venous

ulcers. Signs of arterial disease include:

- ▶▶ Pulseless: palpate the aorta and all lower limb pulses
- ▶▶ Pain
- ▶▶ Pale or dusky skin
- ▶▶ Atrophic shiny skin
- ▶▶ Loss of hair
- ▶▶ Cold peripheries
- ▶▶ Paraesthesia
- ▶▶ Calf/thigh muscle wasting
- ▶▶ Capillary refill time of four to five seconds.

The ankle brachial pressure index (ABPI) should be measured in both limbs using a hand-held Doppler. Palpation of pulses alone cannot exclude peripheral arterial disease and ankle mobility and calf pump function should also be assessed.

Table 1 outlines signs to note when assessing the ulcer.

INVESTIGATIONS

Different tests are needed depending on the clinical setting. The following tests can be undertaken in the community. They are performed to establish the cause of the ulcer and assess for complications. More specialist investigations are used in the hospital setting to guide management.

Blood tests

Full blood count (FBC) to assess hyper viscosity and fasting blood glucose to check for diabetes.

Bacterial swabs

Swabs should be taken only if there are signs of infection, such as cellulitis, increased pain, pyrexia, rapid extension, malodour or ulceration. As most venous ulcers are contaminated with colonisers, it is good practice to wash the wound and remove slough and necrotic skin containing surface contaminants, before swabbing viable tissue (Bowler and Davie, 1999).

Biopsy

Malignant leg ulcers and chronic ulcers that become malignant are uncommon, however, malignancy should always be considered as a possibility when ulcers are failing to heal after 12 weeks of active treatment, or if the appearance of the ulcer is atypical (Figure 1).

Patch testing

Particularly in patients with pre-existing eczema and dermatitis. Studies have now

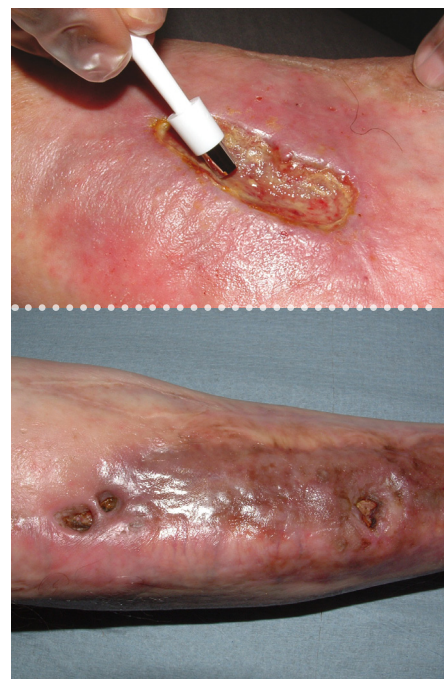




Figure 1: Although malignant leg ulcers are uncommon, malignancy should be ruled out when ulcers fail to heal after 12 weeks of treatment.

Figure 2: Non-healing wounds over shin with underlying osteomyelitis from previous trauma.

References

- Beard JD (2000) ABC of arterial and venous disease; Chronic lower limb ischaemia. *Br Med J*: 320: 854
- Bello M, Scriven M, Hartshone T, et al (1999) Role of superficial venous surgery in the treatment of venous ulceration. *Br J Surg* 86(6): 755–59
- Blair S, Wright D, Backhouse C, et al (1988) Sustained compression and healing of chronic venous ulcers. *Br Med J* 297(6657): 1159–61
- Bowler, P and Davies B (1999) The microbiology of infected and non infected leg ulcers. *Int J Derm* 38: 573–78
- Carek PJ, Dickerson LM, Slack J (2001) Diagnosis and management of osteomyelitis. *Am Fam Physician* 63(12): 2413–21
- Clifford R (2009) *Wheelless' Textbook of Orthopaedics*. Available at: <http://www.wheellessonline.com> (accessed 1 March, 2012)

Table 1
Clinical features of venous, arterial and neuropathic ulcers

	<i>Venous ulcers</i>	<i>Arterial ulcers</i>	<i>Neuropathic ulcers</i>
<i>Location</i>	<i>Between the malleolus and lower calf (gaiter area). Majority of venous ulcers are located over the medial malleolus</i>	<i>Frequently occur distally over bony prominences and on the dorsum of the foot</i>	<i>Sites of pressure (metatarsal heads, heels and toes)</i>
<i>Appearance</i>	<i>Shallow, irregular sloping edges. Margins can either be flat or with slight elevation. They can be small or nearly encircle the ankle</i>	<i>Round, punched-out appearance with sharply demarcated borders</i>	<i>Often there is surrounding callus. Sometimes there may be sinus tract formation. Prolonged bacterial infection may lead to osteomyelitis</i>
<i>Ulcer base</i>	<i>Shallow, irregular sloping edges. Margins can either be flat or with slight elevation. They can be small or nearly encircling the ankle</i>	<i>Round, punched-out appearance with sharply demarcated borders</i>	<i>Often there is surrounding callus. Sometimes there may be sinus tract formation. Prolonged bacterial infection may lead to osteomyelitis</i>
<i>Capillary refill time</i>	<i>Normal less than two seconds</i>	<i>Prolonged over 3–5 seconds</i>	<i>Normal in absence of associated arterial disease</i>
<i>ABPI</i>	<i>Normal: 0.9 or higher</i>	<i>If ABPI is 0.8 or less refer for further assessment of arterial disease. Refer urgently if 0.5 or less</i>	<i>Normal if arterial disease not present</i>
<i>Images</i>			

Note: Take serial measurement of the surface area as a reliable index of healing. Appropriate techniques include photography, tracing of the margins and measuring the two maximum perpendicular axes. The depth can be measured using probes and described in terms of tissue involved at the ulcer base

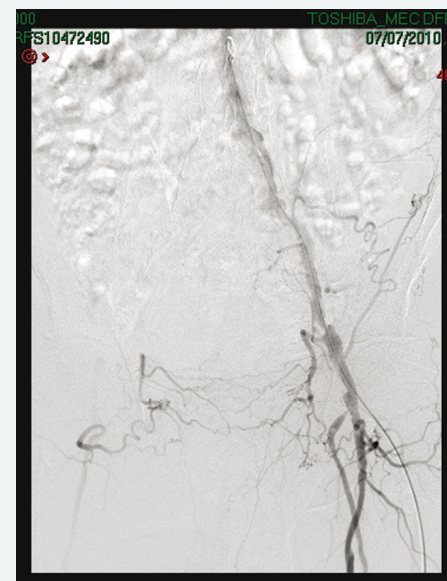
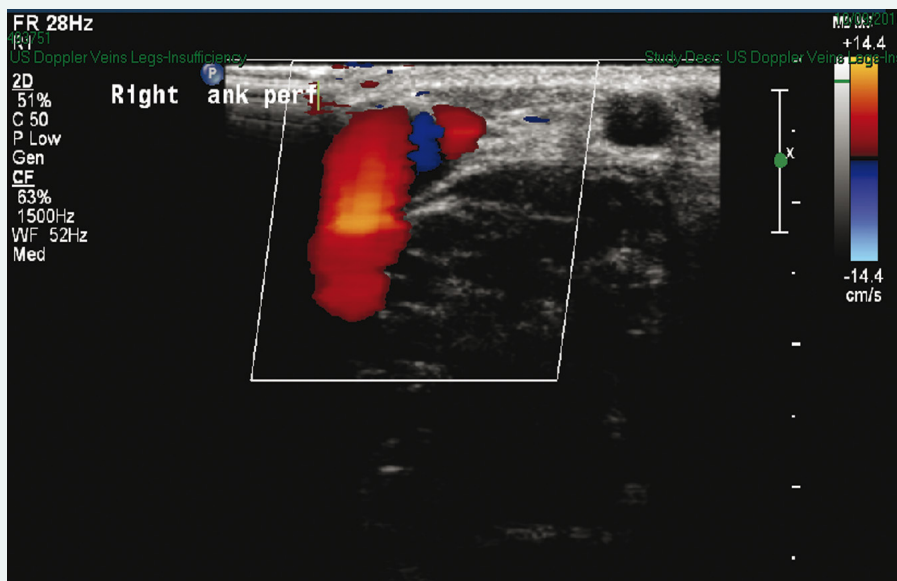


Figure 3: A duplex ultrasonography shows the superficial and deep venous systems, with the colour-coded flow mode enabling blood flow detection.

Figure 4: A clear image of the arterial tree is produced through DSA.

KEY POINTS

- ▶▶ The prevalence of leg ulcers has risen to a point where it has become a significant economic burden.
- ▶▶ The underlying aetiology of an ulcer can be confirmed by specialist investigations such as venous duplex, arterial Doppler ABPI and punch biopsies.
- ▶▶ The majority of venous ulcers can be treated successfully in the community with the use of appropriate dressings and compression bandages.

shown that more than 50% of patients with chronic ulcers develop allergies or sensitivities to lanolin, antiseptics, antibiotics, preservatives, emulsifiers, resin, latex and bandages, due to their prolonged use.

Continuous wave Doppler and ABPI

An ABPI of 1 is normal. An ABPI of 0.5–0.8 suggests moderate arterial disease, warranting routine referral for further investigations. Urgent referrals should be made for patients with an ABPI of 0.5 or less, as this indicates severe arterial disease. Care must be taken when interpreting the ABPI of patients with diabetes and arteriosclerosis, as it may be falsely elevated due to calcification.

X-rays

X-ray deep infected ulcers to look for evidence of osteomyelitis (Figure 2), such as localised soft tissue swelling, areas of bone destruction, periosteal elevation seen as a longitudinal lucency or ovoid lucencies with sclerotic edges (Khan, 2011). The presence of such findings warrants treatment to drain any collections of pus, debride diseased bone and provide intravenous antibiotics. (Carek et al, 2001).

Chronic venous leg ulceration

As discussed previously, chronic venous leg ulceration may be due to venous obstruction, valvular disease or both. The

following investigations may be useful in the specialist setting for establishing the aetiology of chronic leg ulcers, selecting suitable patients for percutaneous or surgical procedures and in assessing the outcome following interventions.

Duplex ultrasonography

This is performed to map the superficial and deep venous systems, to exclude obstruction and identify superficial venous reflux, suitability for surgery or endovascular intervention. The colour-coded flow mode enables detection of blood flow, direction of flow, flow pattern and the presence of any occlusion by a deep venous thrombosis (Figure 3).

Venography

This has been largely superseded by the non-invasive colour flow duplex ultrasound scan and its use has been limited to the assessment of certain deep venous thromboses, congenital venous abnormalities, incompetent perforating veins and lower limb oedema of unknown origin.

Peripheral arterial Doppler ultrasound

This is the initial investigation in patients presenting with intermittent claudication and in the surveillance of arterial grafts and aneurysms. It can be used to visualise the arterial system from the common femoral down to the distal run off vessels. A significant disadvantage, however, is the

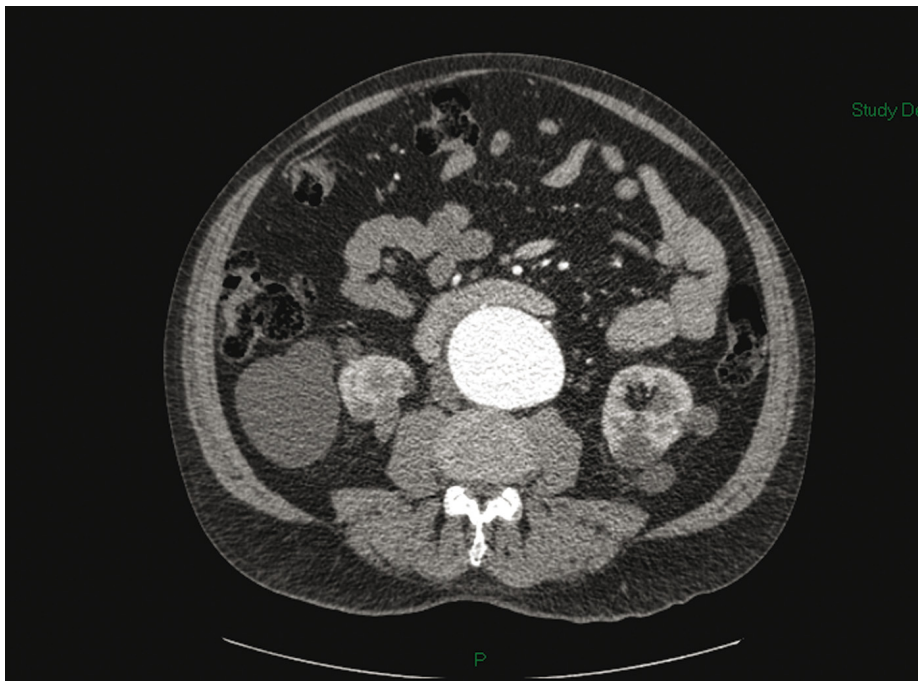


Figure 5: A computer tomography (CT) angiography is a quick and non-invasive test that can be used to reconstruct three-dimensional images of the peripheral vessels.

difficulty in delineating the length of an occlusion in the presence of calcification.

Digital subtraction angiography (DSA)

This is the investigation of choice in patients presenting with peripheral vascular disease. It involves taking digital images prior and subsequent to the administration of intra-arterial iodinated contrast and the subtraction of the background image to produce a clear image of the arterial tree. It is an invasive procedure which is disadvantaged by the risks of using nephrotoxic contrast, groin haematoma formation, false aneurysm and dissection. As there is also the potential for intervention, it is reserved for patients in whom revascularisation is indicated (*Figure 4*).

Magnetic resonance angiography

This test provides a non-invasive and non-nephrotoxic method of producing three-dimensional images of the aorta and peripheral arteries. It is widely available in the UK and has shown excellent correlation with DSA when assessing aortic, iliac and common femoral disease but variable accuracy in assessing occlusions below knee level (accuracy is approximately 91%) (Khan and McCall, 2004).

Computer tomography (CT) angiography

This is quick, non-invasive and is the investigation of choice in assessing the

aorta with its renal and mesenteric branches. It can also be used to reconstruct three-dimensional images of peripheral vessels, assess stenoses and flow through calcified vessels, which is comparable to DSA. The disadvantages include the high dose of ionising radiation and the use of nephrotoxic contrast (*Figure 5*).

Table 2 outlines the criteria for specialist referral.

TREATMENT OF CHRONIC LEG ULCERS

Treatment of venous ulcers in the community involves the following interventions.

Cleansing

The ulcer should be washed with tap water or normal saline to remove surface contaminants.

Debridement

Necrotic and sloughy material within the margins of the ulcer provide the perfect environment for bacterial proliferation. Therefore, this tissue should be debrided, either by mechanical methods, such as sharp debridement and Versajet® hydrosurgery (Smith and Nephew); chemical agents, such as manuka honey; or with biological agents, including larval therapy.

References

- Gohel M, Barwell J, Taylor M, et al (2007) Long term results of compression therapy alone versus compression plus surgery in chronic venous ulceration (ESCHAR) randomised controlled trial. *Br Med J* 355: 83–87
- Grey EJ, Harding KG, Enoch S (2006) ABC of wound healing: venous and arterial leg ulcers. *Br Med J* 332 (7537): 347–50
- Henry M, Henry I (2004) Percutaneous peripheral artherectomy using rotablator. In: Hauser RR, Henry M (eds). *Textbook of Peripheral Vascular Interventions*. Martin Dunitz, London
- Humphreys ML, Stewart AH, Gohel MS, et al (2007) Management of mixed arterial and venous leg ulcers. *Br J Surg* 94(9):1104–07

Recent randomised control studies have reported that manuka honey causes a greater reduction in the size of the wound and larval therapy produces a significantly faster debridement when compared with hydrogel (SIGN, 2010). However, there is no evidence for the use of honey as an antiseptic or wound treatment and, therefore, this is not recommended for routine treatment of patients with chronic venous ulcers.

Dressings

The type of dressing depends on the condition of the ulcer. Simple non-adherent dressings are recommended for shallow non-exudating ulcers (Palfreyman et al, 2006). Absorbent foam and alginate dressings are used for exudating ulcers, while hydrocolloids are reserved for ulcers that are sloughy and offensive smelling. Hyaluronic acid dressings can be used for ulcers which are sloughy and necrotic (Sarkar and Ballantyne, 2000). The current guidance is to use water-based emollients to protect the surrounding skin and to avoid allergens such as wool, alcohol, neomycin and gentamicin (SIGN, 2010).

Topical negative pressure wound therapy (TNPWT)

Although there is some evidence to suggest that the application of TNPWT speeds the time of recovery by decreasing the size of the ulcer bed in preparation for a split skin graft, it has no long-term advantage in preventing recurrences (SIGN, 2010).

Compression bandaging (CB)

CB remains the mainstay for the management of venous ulcers. A four-layer graduated compression bandage should be applied, with pressure at the ankle of 40mmHg and 17mmHg at the

calf (Blair et al, 1988). Patients should be reviewed with regards to complications such as skin necrosis within 24–48 hours of the initial application. Specialist advice should be sought before the application of compression on patients with diabetes and those with an ABPI of less than 0.8. Once the ulcer has healed, patients should be advised to wear elastic stockings to reduce the risk of recurrence. Adequate advice regarding the importance of compression in preventing recurrence is important to improve patient compliance. CB heals approximately 66% of venous ulcers within 12 weeks and 89% within 24 weeks (Blair et al, 1988).

Antibiotics

Venous ulcers contain more complex polymicrobial aerobic and anaerobic organisms, such as *Staphylococcus aureus*, *Pseudomonas aeruginosa* and beta haemolytic streptococci (Grey et al, 2006). However, the ulcer should be swabbed and antibiotics should be started only in the presence of clinical signs of infection, such as increasing pain, enlarging ulcer, cellulitis and pyrexia. In the author's clinical experience, oral flucloxacillin can be prescribed empirically, but this should be reviewed after three days in light of the culture results.

Pharmacological agents

The unlicensed use of pentoxifylline should be considered in patients with non-healing venous leg ulcers, as there is class 1 evidence to suggest that its use with compression bandages improved healing rates by 21% and by 23% where compression was not possible (SIGN, 2010). Although aspirin, mesoglycan and zinc have healing properties, there is inadequate evidence to recommend their routine use for non-healing ulcers.

References

Jones JE, Nelson EA (2007) Skin grafting for venous ulcers. *Cochrane Database Syst Rev* 18(2):CD001737.

Khan N, McCall J (2004) Imaging in vascular disease. *Surgery* 22(10): 268–71

Khan NA (2011) *Acute Pyogenic Osteomyelitis Imaging*. Medscape. Available at: <http://emedicine.medscape.com/article/393120-overview#a19> (accessed 1 March, 2012)

Norgren L, Hiatt WR, Dormandy JA, et al (2007) Inter-society consensus in the management of peripheral arterial disease (TASCII) *J Vasc Surg* 45(1 Suppl): S5A–57A

Table 2
Criteria for specialist referral

Patients who have the following features should be referred to the appropriate specialist at an early stage of management

- ▶▶ *Suspicion of malignancy*
- ▶▶ *Peripheral arterial disease (ABPI of less than 0.8, urgently if less than 0.5)*
- ▶▶ *Diabetes mellitus*
- ▶▶ *Rheumatoid arthritis/vasculitis*
- ▶▶ *Atypical distribution of ulcers*
- ▶▶ *Suspected contact dermatitis or dermatitis resistant to topical steroids should be referred to a dermatologist*

SURGICAL OPTIONS FOR CHRONIC VENOUS ULCERS

Superficial vein surgery

Although varicose vein surgery does not improve ulcer healing, there is good evidence from the ESCHAR trial to show that surgery reduces ulcer recurrence to less than 10% and increases ulcer free time (Gohel et al, 2007). Therefore varicose vein surgery is widely offered to suitable candidates, particularly if they have suffered with a venous ulcer (Bello et al, 1999).

If surgery is delayed in these patients, the superficial and perforator incompetence will progress and they will no longer be suitable for surgical treatment, highlighting the importance of prompt referral to a vascular surgeon.

The procedure offered is dependent on the level of incompetence. The most common cause of long saphenous vein varicosities is sapheno femoral junction incompetence. These patients will often benefit from a high tie of the sapheno-femoral junction, stripping of the long saphenous vein and multiple stab avulsions of the lower leg varicose veins.

If the varicose veins are in the short saphenous distribution and the duplex venous ultrasound confirms incompetence at the sapheno-popliteal junction, ligation of sapheno-popliteal junction and stripping of short saphenous vein, may be beneficial. Apart from the standard open surgery, minimally invasive procedures such as endovenous laser ablation, radiofrequency ablation and foam sclerotherapy can also be used. However, their efficacy in improving ulcer healing and preventing long-term recurrence is still unclear.

Shave excisions and split thickness skin grafting

Where other treatments have been unsuccessful, shave excision of the nonhealing ulcer and covering the wound with a meshed split thickness skin graft has proven to be promising (Jones and Nelson, 2007). It is particularly useful in patients with lipodermatosclerosis and dystrophic calcification within the ulcer (Schmeller and Gaber, 2000).

Pinch Skin grafts

Pinch skin grafting is a technique which

involves the transfer of small amounts of healthy skin (i.e. from the inner thigh) to cover the non-healing ulcer. It is a relatively simple technique which can be performed in the primary care setting as it does not require a general anaesthetic (Steele, 1985). Moreover, patients soon benefit from decreased pain, improved ulcer healing, reduced rates of recurrence and improved quality of life, as it avoids the need for frequent dressing changes. Pinch skin grafts are predominantly indicated in elderly patients or those with multiple medical problems, taking medications such as steroids which impair healing and in those who do not wish to undergo more aggressive surgical intervention.

TREATMENT OF ARTERIAL ULCERS IN THE COMMUNITY

Addressing modifiable risk factors

Addressing modifiable risk factors is the foundation for the management of patients with arterial ulcers, in the community. This involves:

- ▶▶ Encouraging smoking cessation
- ▶▶ Correcting hypertension with antihypertensives
- ▶▶ Prescribing aspirin
- ▶▶ Correcting hyperlipidaemia by prescribing statins
- ▶▶ Tight control of blood sugar levels in people with diabetes
- ▶▶ Encouraging regular graded exercise within limits of pain and tolerance, to promote development of a collateral circulation.

General advice also includes keeping legs warm, sleeping with the 'head end' of the bed raised to promote a gravity dependent blood flow, and protecting the feet.

Opioid analgesia may be necessary to control the pain and systemic antibiotics should be prescribed if there is any evidence of infection. Peripheral vasoconstrictors such as beta blockers should be avoided in this patient group. Unlike in venous ulceration, debridement is contraindicated as it risks enlarging the ulcer and further ischaemia. The type of dressing applied is dependent on the state of the ulcer. Although the above measures are beneficial, if an ulcer is thought to be due to underlying arterial occlusion, the patient should be urgently referred to a vascular surgeon for further investigation and revascularisation to salvage the limb.

References

Palfreyman SJ, Nelson EA, Lochiel R, Michaels JA (2006) Dressings for healing venous leg ulcers. *Cochrane* 19(3): CD001103

Sarkar PK, Ballantyne S (2000) Management of leg ulcers. *Postgrad Med J* 76: 674–82

Schmeller W, Gaber Y (2000) Surgical removal of ulcer and lipodermatosclerosis followed by split skin grafting (shave therapy) yields good long term results in non healing venous leg ulcers. *Acta Derm Venereol* 80: 267–71

INDICATIONS AND OPTIONS FOR THE TREATMENT OF ARTERIAL ULCERS

Angioplasty

In the presence of critical leg ischaemia, angiography is useful for mapping the arteries of the lower limb and assessing the suitability for percutaneous intervention by means of balloon angioplasty. This is only indicated in stenoses or short occlusions of the iliac and superficial femoral vessels, with one-year patency rates of 90% and 80%, respectively (Beard, 2000). Small endoluminal metal stents can be deployed to push the atheroma against the vessel wall, thereby improving its patency. However, the use of stents is limited to the area of residual stenosis or dissection following angioplasty and in longer occlusions in proximal vessels. Stents are not routinely used in distal stenoses due to high rates of reocclusion.

Endarterectomy

Endarterectomy is the surgical removal of atherosclerotic plaque from the inner wall of a blood vessel. The procedure can be used to open the lumen of smaller vessels more effectively than angioplasty and can reduce the incidence of short term re-stenosis (Henry and Henry, 2004). However, the long-term results and the efficacy of this modality of treatment compared with angioplasty, stents, bypass and laser therapy is yet to be determined.

Bypass

Medically suitable patients whose disease pattern is inappropriate for angioplasty should be considered for surgical bypass. The type of procedure offered depends on the general medical condition of the patient, the anatomical distribution and extent of the vascular disease. The fundamental principle in achieving a successful revascularisation is to ensure patency of the 'inflow' artery and more importantly the patency of the 'outflow' vessel used for the distal anastomosis.

Extra anatomical procedures carry lower rates of graft patency (Beard, 2000). Medically fit patients with proximal disease may benefit from an aortobifemoral bypass for bilateral disease, whereas a fem-fem crossover or an axillobifemoral bypass may be offered to patients who are not as fit but who have unilateral or bilateral disease, respectively. Surgical options for patients with distal disease include fem-popliteal

or fem-distal bypasses. However, results from bypass of smaller distal vessels are fairly dismal. Autologous vein grafts are found to have a higher five year patency rate (74–76%) when compared with polytetrafluoroethylene grafts (39–52%) (Norgren et al, 2007). Graft surveillance is advocated in patients with venous grafts to detect and treat stenosis.

PLASTIC SURGERY FOR CHRONIC LEG ULCERS

Once the underlying cause for the ulcer is addressed, advice should be sought from plastic surgeons with regards to wound coverage if the ulcer persists. General principles involve debridement of the wound to convert the ulcer into an acute wound, thereby removing overlying biofilm and encouraging the release of cytokines involved in wound healing.

Working up the reconstructive ladder, in addition to the techniques of pinch skin grafts and split skin grafts previously described, pedicle and free flaps may also be considered, particularly if the wound bed is not suitable for grafting or if the ulcer has exposed underlying bone or tendon. Patients with recurrent ulcers due to deep venous insufficiency will benefit from excision of liposclerotic tissue and reconstruction with a free flap (Schmeller and Gaber, 2000). Various free tissue flaps such as fasciocutaneous flaps, muscle flaps with skin grafts and omental flaps with skin grafts have been successfully used to provide long term cure of chronic leg ulcers (Weinzweig, 1999).

Amputation and prosthesis

Amputation is the last resort in patients with non-salvageable limb. The level of amputation is determined by the extent of infection, blood supply and the patient's pre-morbid level of mobility. The knee joint should be preserved wherever possible to maintain mobility and aid fitting of prostheses.

Minor amputations range from toe amputations, ray amputations, transmetatarsal amputations and Syme's amputations to Chopart amputations (disarticulation at midtarsal joint). Toe and ray amputations are associated with only a moderate loss of function and the wounds may be left open in the presence of infection. Shoe orthotics and rocker soles can be used to maintain normal gait.

References

SIGN (2010) *Management of Chronic Venous Leg Ulcers*. Available at: <http://www.sign.ac.uk/guidelines/fulltext/120/references.html> (accessed 1 March, 2012)

Steele K (1985) Pinch grafting for chronic venous leg ulcers in general practice. *J R Coll Gen Pract* 35(281): 574–75

Weinzweig J (1999) Leg ulcers. In: *Plastic Surgery Secrets*. Mosby, Oxford: 362–63

Even with a forefoot amputation, walking may still be fairly straightforward with the use of toe filler and arch support. A Syme's amputation is an ankle-level disarticulation which is most commonly performed for infection in the presence of a patent posterior tibial artery (Clifford, 2009). It is essential that these patients receive a specially designed prosthesis to relieve weight bearing and minimise wound breakdown.

Major amputations include above and below knee amputations. Below knee amputations (BKA) are preferred for the fitting of prostheses. The two main techniques for BKA include:

- ▶▶ The Burgess technique, where the tibia is cut 12–15cm below the knee joint and a posterior myocutaneous flap is brought forward to cover the bone
- ▶▶ The Kingsley Robinson technique is similar to the above where the calf muscle flaps are brought forward to provide coverage of bony surfaces. However, the skin flaps are slanted in relation to the muscle (Clifford, 2009).

Once the oedema resolves, a prosthetic limb can be fitted and patients often need six to 12 months of rehabilitation prior to achieving their full potential.

DISCUSSION

Chronic leg ulcers are those that do not heal within six weeks. The majority of leg ulcers can be managed in the community by GPs and tissue viability and district nurses. A thorough history and examination is useful in ascertaining the possible aetiology of the ulcer prior to commencing treatment, especially as the compression bandaging, which is the mainstay of treatment in venous ulcers, is contraindicated in the presence of arterial ulcers. The underlying aetiology can be confirmed by specialist investigations such as venous duplex, arterial Doppler ABPI and punch biopsies.

The majority of venous ulcers can be treated successfully in the community with the use of appropriate dressings and compression bandages. There is evidence to suggest that the recurrence of these ulcers is significantly reduced by surgically correcting the causal superficial venous incompetence and, therefore, appropriate candidates would

benefit from surgical referral.

Ulcers thought to be arterial in origin should be promptly referred to a vascular surgeon as ulceration indicates critical limb ischaemia, particularly if the ABPI is less than 0.5. Limb salvaging surgical intervention is also offered to patients with rest pain, worsening claudication and wet gangrene.

While angioplasty and endarterectomy can be used to treat short segments of proximal stenosis, bypass procedures with venous or prosthetic grafts can be offered to patients in whom these measures are not suited or have failed.

About 15% of chronic leg ulcers are a mix of arterial and venous and pose a significant challenge to clinicians. In this instance, if the patient's ABPI is more than 0.8, a multilayer compression bandage can still be used. If the ABPI is 0.5–0.8, these patients may be managed initially with supervised modified compression followed by revascularisation (only if the ulcer does not heal). In patients with ABPI of less than 0.5, revascularisation should be performed prior to compression (Humphrys et al, 2007).

A small proportion of ulcers that occur in atypical distribution, recur or are suspected of malignancy, also warrant specialist referral. If the ulcer is extensive or not healing despite treatment of the underlying cause, advice should be sought from plastic surgeons. Wound coverage techniques ranging from pinch grafts, split skin grafts, to pedicle flaps and free flaps, can have promising results. Amputation is the last resort in these patients and is limited to those with wet gangrene, extensive tissue loss, unreconstructible peripheral vascular disease and intractable ischaemia-related pain.

CONCLUSION

Chronic leg ulcers and their sequelae represent a complex clinical and social problem which is best treated by a multidisciplinary team consisting of GPs, district nurses, tissue viability nurses, dermatologist, vascular surgeons and plastic surgeons.

With the management options outlined above, patients can be helped to better live with this debilitating condition. **WUK**