

# The use of Promogran Prisma<sup>®</sup> to treat complex wounds and avoid skin grafting and tissue flap repair

Jane Pragnell and Sue Nicolson are Nurse Specialists in Plastic Surgery at the Royal Victoria Infirmary, Newcastle-upon-Tyne

With complex plastic surgery wounds the goal of management is often a reduction in wound size and promotion of sufficient granulation tissue to facilitate surgical closure with grafting. In both of the following case studies the wounds responded to treatment with Promogran Prisma<sup>®</sup> (Systagenix), which negated the need for grafting and helped the wounds proceed to complete healing within a time-frame agreed by both clinicians and patient.

In the management of any complex wound, it is important to understand the biochemical processes that promote tissue regeneration. Gibson et al (2009) describe a 'vicious circle' of delayed wound healing, where the hostile environment of stalled wounds is characterised by persistent degradation of the extracellular matrix and growth factors, increased inflammatory response, and high levels of proteases.

Promogran Prisma is a topical wound treatment containing collagen, oxidised-regenerated cellulose (ORC) and 1% silver-ORC. It is a protease-modulating matrix that has the potential to alter the wound environment by reducing the protease activity in the wound and thus stimulate healing.

The collagen content provides a biodegradable scaffold for cellular invasion and capillary growth (Cullen, 2006). All these features combine to create an environment that promotes granulation tissue formation, epithelialisation and optimal wound healing, offering improved outcomes for patients with hard-to-heal wounds (Cullen, 2010).

The silver content of Promogran Prisma also means that it has the potential to impede bacterial growth, reducing the risk of infection.

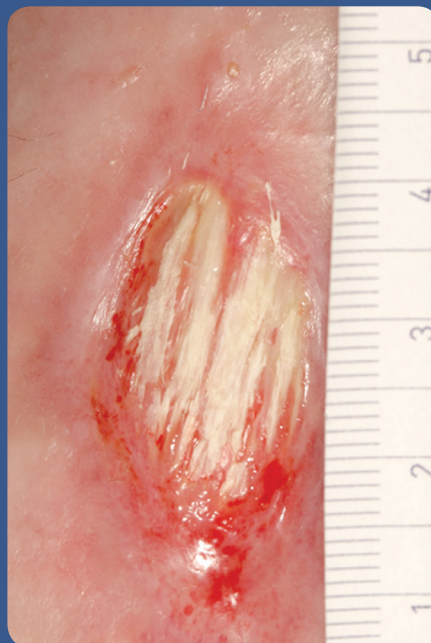


Figure 1. Wound showing exposed tendon.

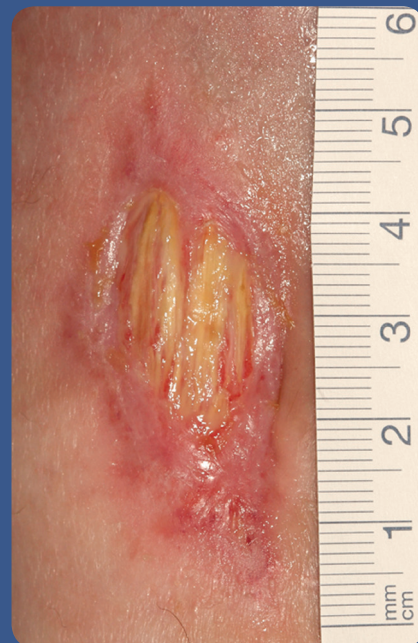

Figure 2. Granulation tissue had increased.

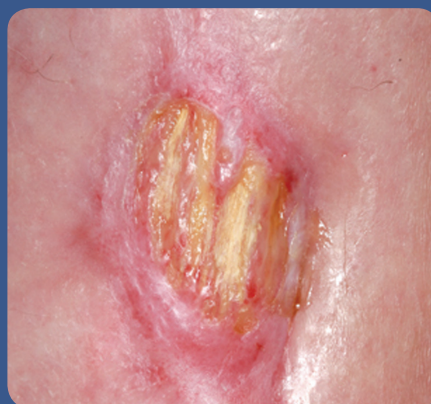

Figure 3. Continued reduction in wound size.

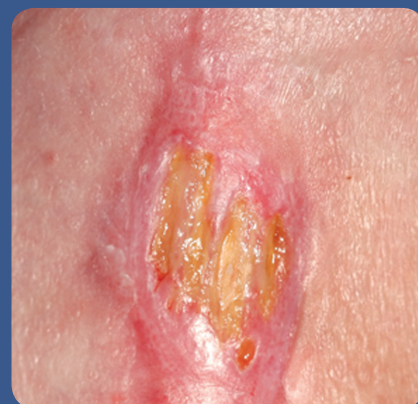

Figure 4. Wound remained infection-free.

## Case reports

This article presents two case reports where Promogran Prisma has been used to stimulate healing, promote granulation tissue formation and avoid the need for skin grafting or tissue flap reconstruction.

### Case report one

This 44-year-old male patient with a history of rheumatoid arthritis was referred from the district general hospital to the chronic wound care clinic for negative pressure wound therapy (NPWT) treatment of a non-healing wound on the dorsum of his left foot.

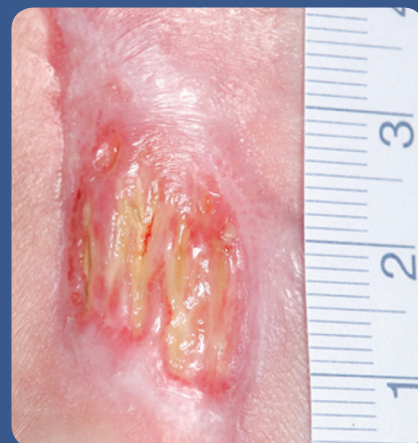

Figure 5. Wound at discharge.

The patient, who had experienced rheumatoid arthritis for 20 years, was initially admitted to the orthopaedic unit of the hospital following an episode of septic arthritis involving his left elbow, right foot and left knee. The infection spread to his tissues and resulted in a right above-knee amputation and a four-day intensive care stay.

Following the amputation, the wound care regimen for management of the left foot dorsal wound included Mepitel® (Mölnlycke Health Care) and Tegaderm® (3M). The patient was seen by a consultant plastic surgeon who decided to continue healing by secondary intention. The plan was that if the wound did not improve, it would be necessary to perform a tissue flap to provide robust tendon and skin cover.

On initial assessment at the nurse-led chronic wound clinic the wound measured 3.5 x 1.8cm, with 95% exposed tendon and only 5% granulation tissue. The wound did not appear infected and the level of exudate was minimal (Figure 1).

After careful discussion with the patient it was decided that the use of NPWT would not be practical. After the relatively recent amputation, he was mobilising independently with the use of a wheelchair; but he was keen to speed up his appointments for a prosthesis at the limb-fitting centre. He felt the NPWT system would be difficult to manage at the same time as attending clinic appointments and trying the new prosthesis.

The wound exhibited exposed tendon, which is at risk of desiccation and loss of viability if left untreated (Bucholz et al, 2006). In view of the exposed tendon and the anatomical site, it was felt that a collagen dressing would stimulate cell growth and cell infiltration into the wound area. Promogran Prisma was chosen to provide a matrix and prevent

the development of local infection. The wound was dressed twice-weekly with Promogran Prisma and an adhesive foam secondary dressing. The patient wore a trainer type shoe, which did not cause pressure on the wound.

When the wound was reassessed and photographed 14 days later, it had reduced substantially in size, measuring 2.3 x 1.3cm. There was also a reduction in the amount of exposed tendon (90%) and an increase in the amount of granulation tissue present (10%) (Figure 2).

Treatment continued with a thrice-weekly application of Promogran Prisma. Mepilex® Border (Mölnlycke Health Care) was also used to avoid desiccation of the tendon. Figure 3 demonstrates continued reduction in wound size and progress towards healing over a 10-week period.

The patient was reviewed by the consultant and referred to the vascular department for assessment of his blood supply, which can affect the subsequent healing of the wound. The duplex scan showed good pulsatile flow above the ankle and reduced velocity below the ankle. After 10 weeks of treatment, the wound remained infection-free and was progressing well (1.5 x 1.5cm) (Figures 4 and 5).

In order to protect the small amount of remaining exposed tendon from drying out and rupturing, the decision was taken at this stage to change the dressing regimen to a hydrocolloid (DuoDERM® Extra Thin; ConvaTec). However, as Promogran Prisma is biodegradable, removal was not necessary, helping to protect the tendon from further trauma.

At this stage, the patient was able to manage the dressings himself, which allowed him to undergo rehabilitation and limb-fitting. Following discharge he was provided with contact details for the specialist nurses if he needed advice or further appointments.

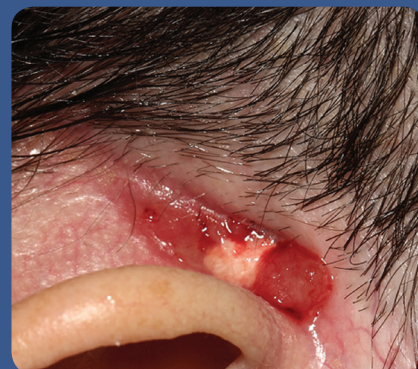

Figure 6. Wound extended to muscle and periosteum.

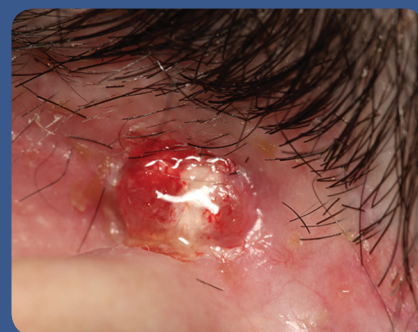

Figure 7. Development of healthy epithelialisation.

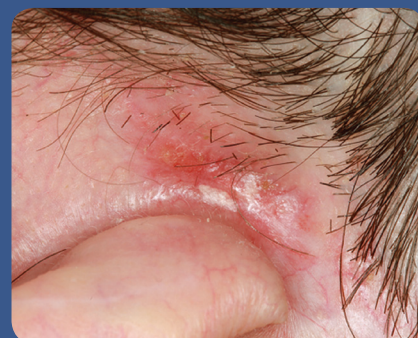

Figure 8. The wound progressing to healing.

### Conclusion

Using Promogran Prisma achieved the planned objective of a reduction in wound size and the formation of substantial granulation tissue to cover the exposed tendon. This approach avoided the need for surgery and skin grafting. Final healing was achieved using DuoDERM Extra Thin.

The patient was wearing his prosthesis when he attended his penultimate chronic wound clinic appointment.

He had continued with his regular appointments at the limb-fitting centre and maintained his independence with his personal care and activities of daily living. He reported feeling pleased with the outcome.

Although it is not possible to make detailed claims about financial savings, the cost of a plastic surgery bed is £475 per day and the anticipated stay would have been a minimum of five days, with surgical costs of several thousands of pounds. This is before considering any complications that may have arisen as a result of a prolonged hospital stay.

#### Case report two

A 57-year-old female was assessed in the chronic wound clinic for management of a postoperative occipitoparietal defect following Mohs micrographic surgery (MMS). The surgery was performed to obtain a biopsy from a lesion behind the patient's right ear, which had been present for the past 20 years.

The postoperative wound extended to muscle and periosteum and measured 10 x 5mm (Figure 6).

Previous treatment had included the use of Xelma® (Mölnlycke Health Care), an extracellular matrix protein recommended for hard-to-heal wounds. The plan of treatment was to reduce the size of the wound with a view to future skin grafting or the use of a tissue flap.

Over a three-week period, the wound became infected but failed to progress with the use of soft silicone and silver alginate dressings. It was decided to try Promogran Prisma with a soft silicone (Mepilex; Mölnlycke Health Care) and an elasticated viscose bandage (Tubifast®; Mölnlycke Health Care) to secure the dressing. Three weeks later, the wound had reduced in size to 7 x 6mm. For the following six weeks, Prontosan® (B. Braun) soaks were used before dressing

applications to reduce the bacterial burden and gently cleanse the wound. Promogran Prisma was continued as the primary dressing and topical steroid treatment was used intermittently to manage areas of overgranulation, as per the authors' local protocol.

Figure 7 illustrates the development of healthy epithelialisation and coverage of the exposed tendon, while Figure 8 demonstrates the continued progress of the wound using this treatment regimen.

Regular shaving of the hair surrounding the wound was necessary to prevent hair growth contaminating the wound. The wound progressively healed by contraction, avoiding the need for surgery. The patient also wore glasses and to avoid pressure damage, the arms of the glasses were padded so that they did not rest on the wound.

#### Conclusion

The patient presented with a wound in a difficult anatomical location and the use of Promogran Prisma facilitated wound closure avoiding the need for skin grafting and further surgery.

#### Summary

Managing wounds in difficult anatomical locations with exposed bone and/or tendon presents clinicians and patients with a number of challenges. The role of ORC and collagen in tissue repair and the evidence base for Promogran Prisma is well described (Lazaro-Martinez, 2008; Cullen et al, 2010).

The case reports presented in this article further illustrate the potential for this treatment to stimulate granulation tissue formation and wound contraction. **WUK**

#### References

Buchholz RW, Heckman JD, Court-Brown CM (2006) *Fractures in Adults*. Lippincott, Williams & Wilkins, Philadelphia, PA

#### Key points

- ▶▶ It is important to understand the biochemical processes that promote tissue regeneration.
- ▶▶ The goal of complex wound management is reduction in wound size and promotion of sufficient granulation tissue to facilitate surgical closure or skin grafting.
- ▶▶ Managing wounds in difficult locations with exposed bone and/or tendon presents a number of challenges.
- ▶▶ These case reports clearly illustrate the potential for this treatment to stimulate granulation tissue formation and wound contraction.

Lázaro-Martínez JL, García-Morales E, Benoit-Montesinos JV, Martínez-de-Jesús FR, Aragón-Sánchez FJ (2007) Randomized comparative trial of a collagen/oxidized regenerated cellulose dressing in the treatment of neuropathic diabetic foot ulcers. *Cir Esp* 82(1): 27–31

Cullen B, Boyle C, Rennison T, Webb Y, Gregory S (2006) *ORC/Collagen Matrix Containing Silver Controls Bacterial Bioburden while Retaining Dermal Cell Viability*. Poster presented at EWMA, Prague, 2006

Cullen B, Ivins N (2010) *Promogran and Promogran Prisma Made Easy*. Wounds International. Available online at: [www.woundsinternational.com/article.php?articleid=8836&page=7](http://www.woundsinternational.com/article.php?articleid=8836&page=7) [accessed 17, October, 2011]

Gibson D, Cullen B, Legerstee R, Harding KG, Schultz G (2009) *MMPs Made Easy*. Wounds International. Available online at: [www.woundsinternational.com/article.php?issueid=1&contentid=123&articleid=21](http://www.woundsinternational.com/article.php?issueid=1&contentid=123&articleid=21) [accessed 17, October, 2011]