

3M™ Tegaderm™ HP Foam Adhesive dressing: a case report series

Bianchi et al (2011) suggested that foam dressings appear to have similar clinical outcomes, indicating that clinicians make decisions to choose one particular dressing over another for a variety of reasons, such as wear time and specific user features. This paper describes a case report series that observed the performance of an adhesive foam dressing to absorb wound exudate, promote healing, remain *in situ* and avoid skin stripping on removal.

David Gray, Pam Cooper, Fiona Russell, Sandra Stringfellow

KEY WORDS

Tegaderm™ HP Foam Adhesive
Skin stripping
Peri wound trauma
Wound healing
Exudate management

Foam dressings have been described as the most commonly used wound dressing (Bianchi et al, 2011), due to their versatility and variety of presentations. A wide range of foam dressings exists: adhesive, non-adhesive, with or without silicone and with or without silver. Bianchi et al (2011) reviewed the literature relating to foams without additives such as silver and found that there was little

difference in the clinical outcomes observed. However, in the authors' opinion, it should be recognised that there may be measurable clinical differences between different foam dressings. The study to identify this has yet to be conducted. Bianchi et al (2011) also concluded that given the lack of evidence to guide the use of foam dressings, clinicians may be using other more practical parameters,

This paper presents the results of an evaluation where an adhesive-backed dressing was selected due to the regular referral of patients with fragile periwound skin at risk of skin stripping.

such as dressing retention and patient comfort. If, indeed, this is the case, practitioners need to conduct their own 'hands-on' evaluations to establish if the features of the dressing meet the needs of their patient groups

This paper presents the results of an evaluation where an adhesive-backed dressing was selected due to the regular referral of patients with fragile periwound skin at risk of skin stripping.

The adhesive foam product used was 3M™ Tegaderm™ HP Foam Adhesive dressing (3M™ Health Care), which has a spoke delivery system (paper framework that looks like wheel spokes which come off in sections, facilitating application) to facilitate easy application. This multilayer dressing has an absorbent foam contact layer overlaid with a high capacity absorbent layer which is, in turn, covered by a moisture control layer to facilitate the evaporation of moisture from the wound. There is a further layer of adhesive film which works in tandem with the spoke delivery system to ensure that the dressing conforms to the wound. Included in the latest version of this dressing is a moisture responsive layer that becomes activated by liquid exudate in the pad, boosting the breathability and fluid-handling properties of the dressing. This dressing has previously been evaluated in both clinical and laboratory studies. Brown-Etris et al (2011) considered the ease of removal in 116 dressing changes. In 76% of the cases, the product was rated as good or very good. There was no observation of skin stripping. A further study by Brown-Etris et al (2011) presented the cases of three of the patients from the nine recruited. These demonstrate the ability of the dressing to conform to challenging anatomical locations such as the elbow and heel. Holm et al (2011) studied the breathability and fluid-

David Gray is Clinical Nurse Specialist, Department of Tissue Viability, NHS Grampian and Visiting Professor, Tissue Viability Practice Development Unit, Faculty of Health, Birmingham City University; Pam Cooper, Fiona Russell and Sandra Stringfellow are all Clinical Nurse Specialist, Department of Tissue Viability, NHS Grampian, Aberdeen

handling properties of the dressing in a group of healthy volunteers using wound models. These volunteer studies showed the Tegaderm HP Foam Adhesive dressing's theoretical wear time and performance. However, given the variability of wounds in clinical practice, it is important to validate the findings of this study. Carlson et al (2011) looked at the dressing in relation to the costs associated with foam dressings. Data from healthy volunteers and wound models were used to provide wear time data which were presented in the form of a health economic model. Under these conditions, the authors found that significant savings could potentially be made in comparison to other adhesive foam dressings.

Methodology

Over an eight-week period, patients referred to the department of tissue viability were considered for treatment with Tegaderm HP Foam Adhesive, under normal circumstances a silicone-backed adhesive foam dressing would have been used. The outcomes were assessed by a nurse specialist who was familiar with the performance of the adhesive dressings normally prescribed.

Assessment related to five key areas:

- ▶ Fluid-handling properties
- ▶ Dressing adherence
- ▶ Wound healing
- ▶ Skin stripping
- ▶ Achievement of the treatment objective.

Results

Fifteen patients were recruited (Table 1, Figure 1). The treatment objectives were met in all but one case. In case 13, the patient developed a soft tissue infection requiring a daily dressing, so was moved on to a topical antiseptic and non-adhesive dressing.

In all other cases the dressings lasted for the prescribed time, i.e. three or seven days depending on the management plan in place. No episodes of leakage or dressings falling off were reported, or, more importantly, skin stripping.

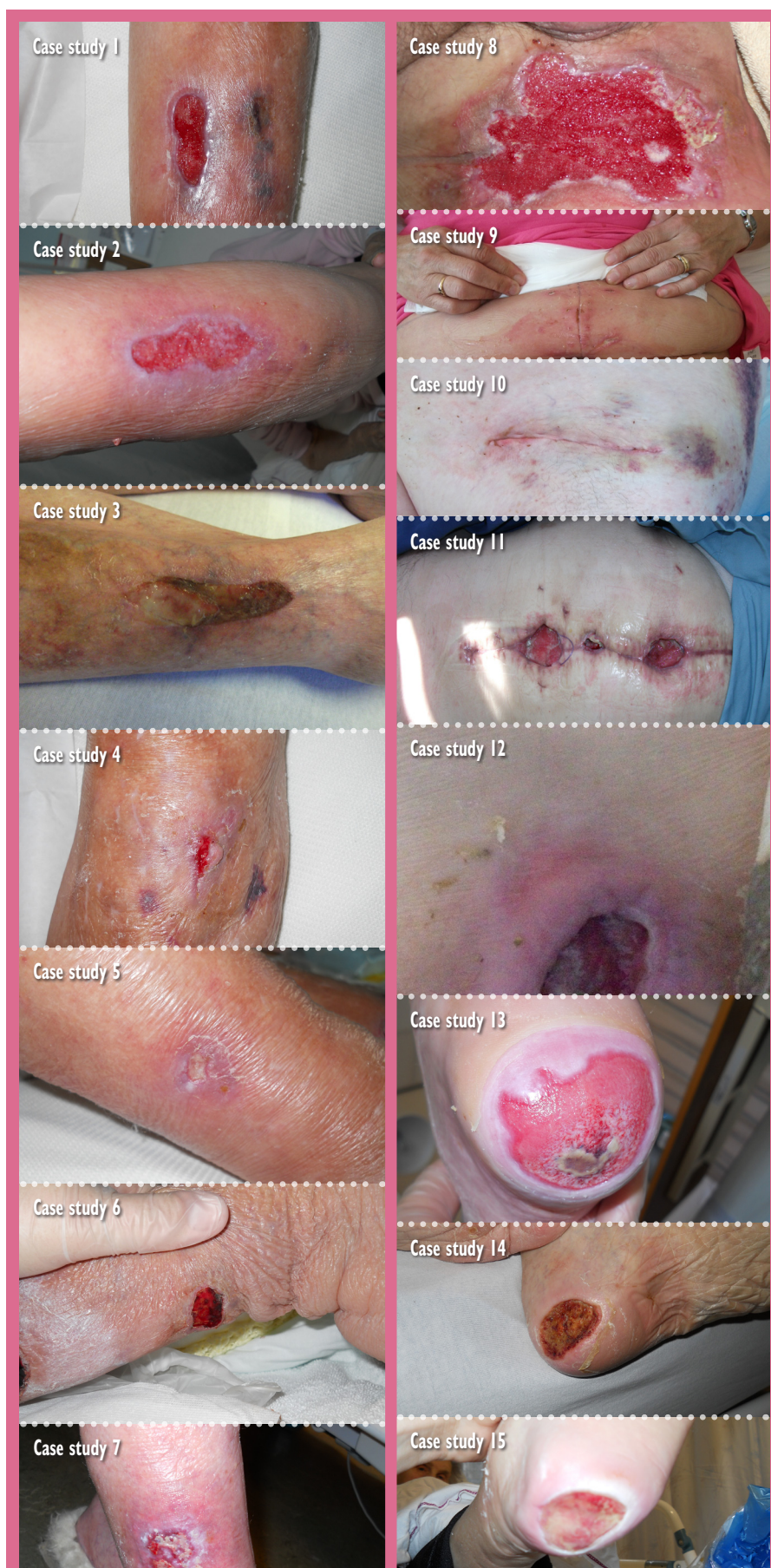

Figure 1. Cases series before treatment with Tegaderm HP Foam.

Table 1

Details of the 15 patients recruited for the evaluation

Case number	Wound type	Wound location	Periwound skin	Treatment objective	Level of exudate	Objective achieved yes/no
1	Trauma	Pretibial	Fragile	Healing	Low	Yes
2	Trauma	Calf	Fragile	Healing	Medium	Yes
3	Trauma	Tibia	Fragile	Healing	Low	Yes
4	Trauma	Tibia	Fragile	Healing	Low	Yes
5	Trauma	Tibia	Fragile	Healing	Medium	Yes
6	Trauma	Calf	Fragile	Healing	Medium	Yes
7	Trauma	Calf	Fragile	Anti-infection	Medium	Yes
8	Surgical	Groin	Healthy	Healing	Low	Yes
9	Surgical	Abdomen	Healthy	Healing	High	Yes
10	Surgical	Under arm	Healthy	Healing	Medium	Yes
11	Surgical	Abdomen	Healthy	Healing	High	Yes
12	Pressure ulcer	Sacrum	Red	Anti-infection	High	Yes
13	Pressure ulcer	Heel	Healthy	Healing	Medium	No
14	Pressure ulcer	Heel	Healthy	Healing	Low	Yes
15	Pressure ulcer	Heel	Healthy	Healing	Medium	Yes

NB: No skin stripping occurred in any of the cases. Effective fluid-handling properties and secure dressing adherence were achieved in all cases

Discussion

Apart from cases 7, 9 and 11, all the wounds assessed were categorised as having low to medium levels of exudate. The local infection present in case 7 resulted in a high level of exudate. The two abdominal wounds (cases 9 and 11), which also had high levels of exudate, were both treated with negative pressure wound therapy (NPWT) before Tegaderm HP Foam Adhesive was applied. In both of these cases, the dressings were changed every three days, which effectively managed the high level of exudate present and at a substantial cost-saving compared to NPWT. The lower limb wounds in cases 1–6 were managed with a low level compression system using toe-to-knee Tubifast®

Of concern with any adhesive dressing is that it may lose its adhesion and expose the wound bed, or allow fluid to leak from the wound. In this case series it was found that the dressing adhered securely to the periwound and showed no signs of falling off.

(Mölnlycke Health Care)/Comfifast® toe-to-knee orthopaedic padding and a further layer of toe-to-knee Tubifast/Comfifast, or similar. This method reduces soft pitting lower limb oedema, preventing the oedema from

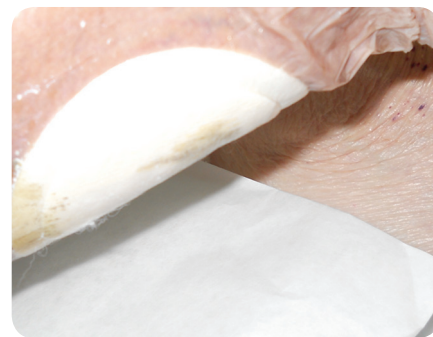

Figure 2. Case 6: dressing in situ with exudate being contained.

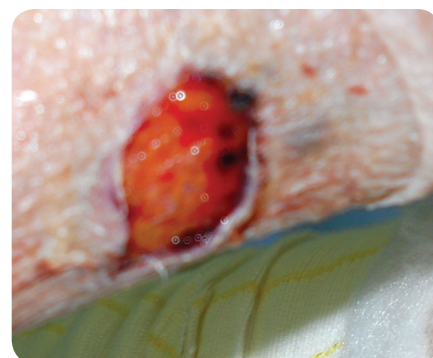


Figure 3. Case 6: wound beneath the dressing.



Figure 4. Case 9: Dressing can be seen to be flexible.

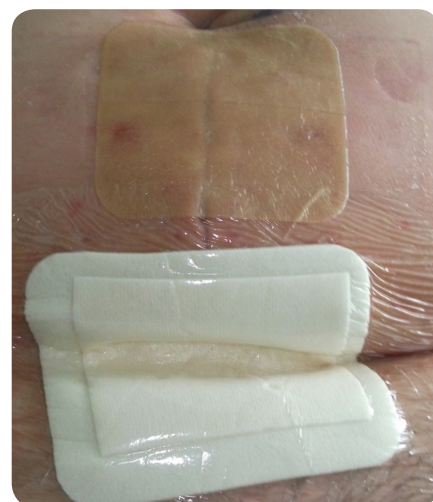

Figure 5. Case 9: Dressing has conformed to the folds of the skin.

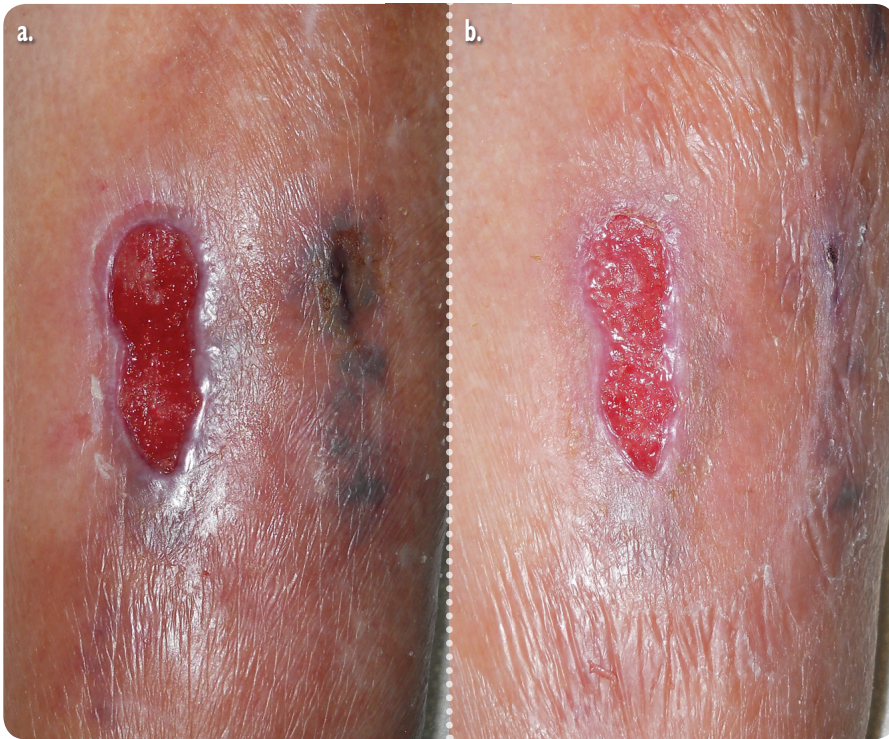


Figure 6a. Case 1: Lower limb trauma wound before application of dressing. **Figure 6b.** After 10 days of treatment using Tegaderm HP Foam Adhesive, the vulnerable periwound area was healthy.

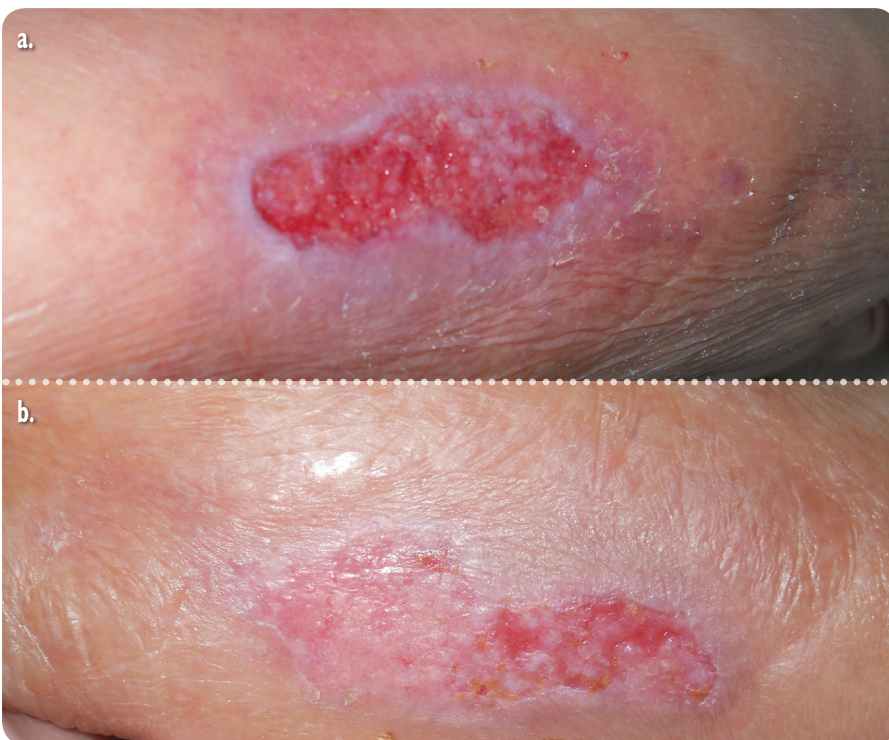


Figure 7A. Case 2: Lower limb trauma wound before application of dressing. **Figure 7b.** The same patient after 10 days of treatment using Tegaderm HP Foam Adhesive showing the vulnerable periwound area to be healthy.

escaping via the wound and swamping the dressing. In all cases, exudate was found to be contained within the dressing at dressing change (Figures 2 and 3).

Of concern with any adhesive dressing is that it may lose its adhesion and expose the wound bed, or allow fluid to leak from the wound. In this case series it was found that the

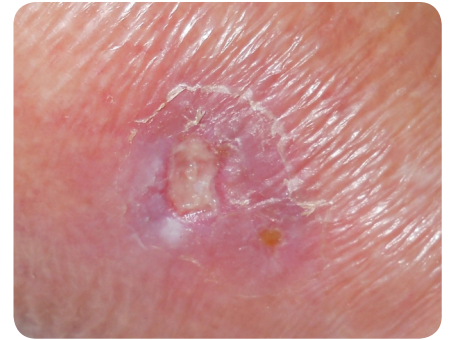


Figure 8. Case 5: vulnerable skin.

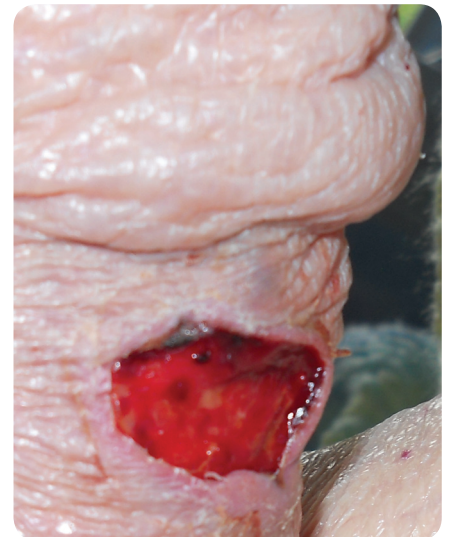


Figure 9. Case 6: vulnerable skin.

dressing adhered securely to the periwound and showed no signs of falling off. Figure 4 shows the dressing's flexibility, while in Figure 5 the dressing can be seen to have conformed to the folds of the skin (case 9). In cases 13–15 the dressing adhered to the heel, but also allowed the patient to wear footwear and mobilise, as the dressing profile was acceptable and not too bulky.

The patients in cases 1–7 were all acutely ill elderly patients with multiple comorbidities. However, through effective management of both exudate and limb oedema healing was achieved — the overall treatment objective (Figures 6 and 7). Case 13 was the only patient for whom the treatment objectives were not met, as the patient developed an infection.

Use of silicone adhesive dressings is often viewed as an essential aspect of caring for patients with vulnerable



Figure 10. Case 1: Dressing mid-removal showing no signs of skin trauma.

periwound skin (Jones and Morris, 2011). Previous experience with adhesive film dressings has led the authors to feel that such dressings could increase the risk of periwound trauma and skin stripping. However, in another study (Gray et al, 2011) using film-backed adhesive dressings, the authors found that they managed skin tears effectively and thus it was agreed that use of such dressings should be re-visited. Figures 8 and 9 show examples of patients with vulnerable skin. Figures 6b and 7b show the wounds immediately after dressing removal with no signs of periwound trauma or skin damage. Figure 10 shows the dressing mid-removal, with no evidence of skin damage.

The treatment objectives of all patients with vulnerable skin were met using Tegaderm HP Foam Adhesive during this case series.

Conclusion

This case report series enabled the authors to contribute to the understanding of how these dressings

perform in clinical practice. The cases presented in this paper show that Tegaderm HP Foam Adhesive is an atraumatic dressing that effectively manages wounds with low to high levels of exudate in patients with vulnerable skin and avoids further trauma on dressing removal. In this regard it seems to compare favourably with the silicone foam dressings usually used in the trust. It is the responsibility of all practitioners to ensure that the products they select are appropriate for the patient group being treated.

Results from this case series support the benefits associated with the use of Tegaderm HP Foam Adhesive dressing, as indicated by the fluid-handling and wear time results found in volunteer studies published previously. **WUK**

References

- Bianchi J, Gray D, Timmons J, Meaume S (2011) Do all foam dressings have the same efficacy in the treatment of chronic wounds? *Wounds UK* 7(1): 62–7
- Brown-Etris (2011) Poster presentation.

Key points

- ▶▶ A wide range of foam dressings exists: adhesive, non-adhesive, with or without silicone and with or without silver.
- ▶▶ Tegaderm HP Foam Adhesive is an atraumatic dressing that effectively manages wounds from low to high exudate in patients with vulnerable skin, and avoids further wound trauma on dressing removal.
- ▶▶ This case series found that the dressing adhered securely to the periwound and showed no signs of falling off.

SAWC, April 14–17th 2011, Gaylord Texan Hotel and Convention Center, Dallas, Texas

Carlson (2011) Poster presentation. SAWC, April 14–17th 2011, Gaylord Texan Hotel and Convention Center, Dallas, Texas

Gray D, Stringfellow S, Cooper P, et al (2011) Pilot RCT of two dressing regimens for the management of skin tears. *Wounds UK* 7(2) 26–31

Holm (2011) Poster presentation. SAWC, April 14–17th 2011, Gaylord Texan Hotel and Convention Center, Dallas, Texas

Jones M, Morris C (2011) *The Assessment and Management of Skin Tears*. MA Healthcare, London: 8

To access **free**
international wound care education visit
Wounds International...

online at: www.woundsinternational.com