

Recurrent ulcers in a patient with post-thrombotic syndrome

Pereira Albino is Vascular Surgeon of the H. Lusíadas-HPP, Lisbon, Portugal and invited Professor of Surgery of the FCM, New University of Lisbon; Nuno Meireles is Vascular Surgeon of the H. Lusíadas-HPP, Lisbon, Portugal; José Alves, Eliana Rosa, Margarida Lino, Andreia Porfírio, Nadia Cardoso, Rosa Santos and Fernando Barros are Nurses, Ambulatory Department, H. Lusíadas-HPP, Lisbon, Portugal

Leg ulcers can be a challenge to heal, especially when the underlying problem is caused by post-thrombotic syndrome (PTS). PTS is present in 5–10% of cases of venous hypertension and treatment is complex with many possible medical and surgical options (Saedon and Stansby, 2010; Kahn, 2011).

PTS is the occlusion of the deep vascular system with weakened revascularisation, associated with moderate insufficiency of the popliteal vein and insufficiency of the leg's perforating veins (Hencke, 2010). The superficial venous system usually appears without reflux, becoming insufficient only in the later phase of the disease (Eklof, 2004; Perrin, 2005; Albino, 2008).

A Cochrane review described PTS as a long-term complication of deep vein thrombosis (DVT), characterised by chronic complaints, swelling, and skin changes in the affected limb. One in three people with DVT develop post-thrombotic complications within five years (Kolbach, 2003). Due to its prevalence (20–50% of patients develop PTS within one to two years of symptomatic DVT) and chronicity, PTS is costly to society and is a cause of substantial patient morbidity (Kahn, 2004; Vasquez, 2010).

Case report

A professional waiter (male, 32 years old) had an occupational accident in 2004 resulting in a bone fracture to the left leg. After surgery, DVT of the popliteal femoral developed. This was conventionally treated with elastic compression stockings to prevent fluid from pooling in the ankle (oedema),

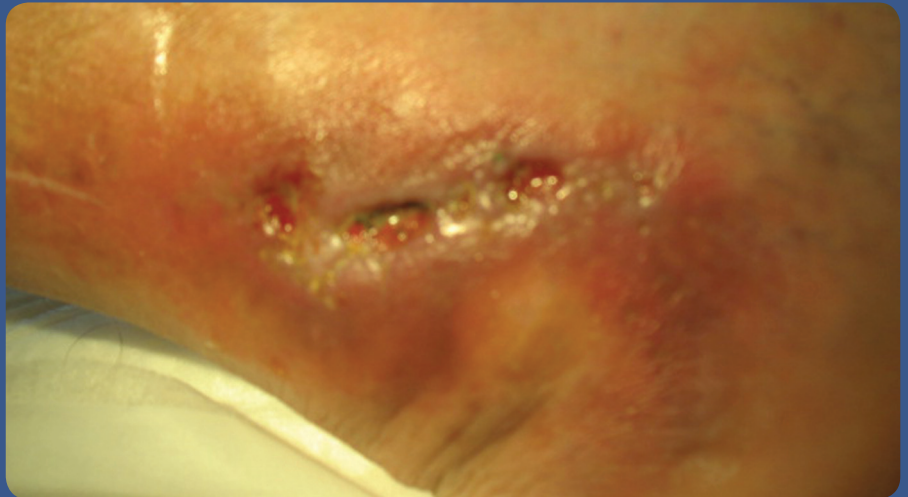


Figure 1. Infected ulcers at first review on 21/05/2010.

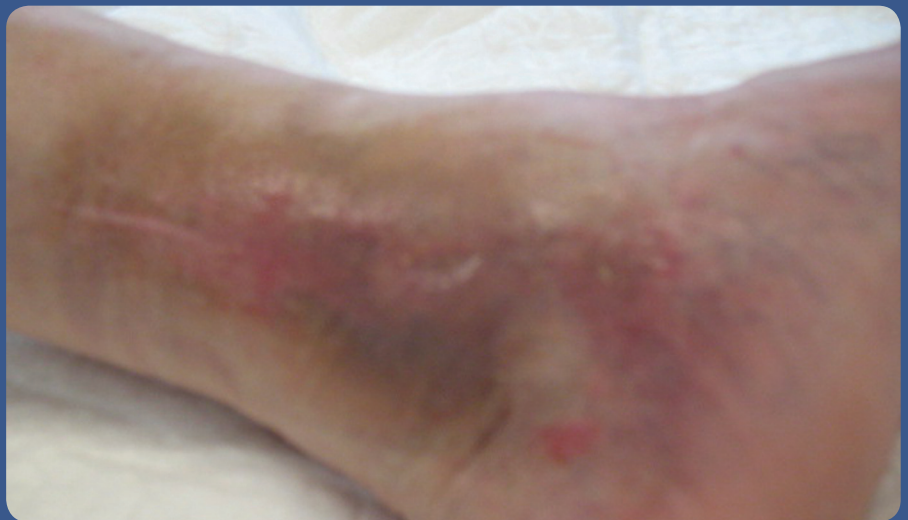

Figure 2. Healed ulcers on 07/07/2010 after four weeks of honey treatment.

and low molecular weight heparin (Musani, 2010; Roche-Nagle, 2010). The aetiological study did not show up the condition of thrombophilia.

Up until 2008 the patient had no significant symptoms and only intermittently used elastic compression stockings. However, after a minor accident (hitting his leg on a chair), he started having recurrent malleolar ulcers.

The patient was treated with inadequate compression and many other dressings at a clinic in Lisbon. Silver-based (Aquacel® Ag, ConvaTec) and hydrocolloid dressings were used, combined with pentoxifylline (for intermittent claudication) and micronised diosmin (Daflon). However, the ulcer remained unhealed for about eight months.

The clinical situation was aggravated in

January 2010, with the ulcer increasing in size and the patient was admitted for detachment of perforating veins, but this did not result in wound healing.

In June 2010, the patient again presented at the authors' hospital with infected, painful and inflammatory ulcers in the lower third of his left leg (Figure 1). During 2010, the patient was only able to work intermittently due to the pain. A duplex ultrasonography study confirmed a diagnosis of PTS (Perrin, 2005).

Treatment

Negative pressure wound therapy (NPWT) and deep venous surgery were considered as treatment options by the authors. However, it was felt that NPWT would result in the patient being bedridden, and, surgery, being invasive should be the last option. Thus, the authors decided to start treatment with honey-based dressings (L-Mesitran Border; Triticum), together with a two-layer compression bandage system (Saphenamed, Hartmann). The honey-based dressings were applied three times a week in the clinic.

Results

This treatment regimen immediately improved the inflammatory state of the ulcers, and also reduced the pain. The ulcers debrided rapidly, significantly improving the patient's quality of life. They healed completely after only four weeks of treatment (Figure 2).

Twelve honey dressings were used during the treatment period at a cost of around 80 euros, and no adverse events were reported.

Discussion

Therapeutic options for PTS are extremely limited and results are often disappointing (Pirard et al, 2008). Thus, prevention, recognition of clinical signs or complications, and early treatment

remain key to reducing its morbidity (Pirard et al, 2008).

In this case, the patient's quality of life was severely compromised due to recurring leg ulceration which prevented him from working. After various unsuccessful treatment regimens, it was decided to introduce a honey-based dressing before resorting to surgery.

Honey has been found to result in successful outcomes for many wound types (Jull, 2008; Gottrup, 2009). The mode of action is contributed to low pH, the capability to produce hydrogen peroxide and the osmotic action (Molan, 2006). The honey dressing used in this case has previously been compared to silver dressings (Du Toit and Page, 2009). Du Toit and Page (2009) examined the cell morphological effects of two key cellular components of wound healing, keratinocytes and fibroblasts, when in contact with honey and silver-impregnated dressings. They concluded that the honey-impregnated dressings had the potential to promote new tissue regeneration or healing. In this case, the regeneration of the tissue was evident and completed in six weeks' time.

Conclusion

In this case, the honey-based dressing had significant therapeutic advantages over other previously used dressings. The recurring ulcer was successfully healed in six weeks, without any adverse events occurring and with minimal material costs. Honey dressings are a non-invasive and cost-efficient alternative therapy compared to standard treatment methods, or surgical intervention for leg ulcerations, where PTS is the underlying pathology. **WUK**

References

Albino JP (2008) Chronic venous disorders and chronic venous diseases: concepts and evaluation. *Rev Port Cir Cardiorac Vasc* 15(1): 51–6

DuToit DF, Page B (2009) An in vitro evaluation of the cell toxicity of honey and silver dressings. *J Wound Care* 18(9): 383–9

Eklof B, Rutherford RB, Bergan JJ, et al (2004) Revision of the CEAP classification for chronic venous disorders: consensus statement. *J Vasc Surg* 40(6): 1248–52

Henke P (2010) Prevention and treatment of the postthrombotic syndrome. *J Vasc Surg*. Jul 31 [Epub ahead of print]

Jull AB, Rodgers A, Walker N (2008) Honey as a topical treatment for wounds. *Cochrane Database Syst Rev*. (4):CD005083

Kahn SR (2011) The post thrombotic syndrome. *Thromb Res* 127 Suppl3: S89–92

Gottrup F, Jorgensen B, Karlsmark T (2009) News in wound healing and management. *Curr Opin Support Palliat Care* 3(4): 300–4

Kahn SR, Ginsberg JS (2004) Relationship between deep venous thrombosis and the postthrombotic syndrome. *Arch Intern Med* 164: 17–26

Kolbach DN, Sandbrink MWC, Prins MH, Neumann MHAM (2003) Compression therapy for treating stage I and II (Widmer) post-thrombotic syndrome. *Cochrane Database of Systematic Reviews* 2003, Issue 4. Art. No.: CD004177. DOI: 10.1002/14651858.CD004177

Molan PC (2006) The evidence supporting the use of honey as a wound dressing. *Int J Low Extrem Wounds* 5(1): 40–54

Musani MH, Matta F, Yaekoub AY, Liang J, Hull RD, Stein PD (2010) Venous compression for prevention of postthrombotic syndrome: a meta-analysis. *Am J Med* 123(8): 735–40

Perrin M (2005) Revision of the CEAP classification for venous disorders: consensus statement. *J Mal Vasc* 30(2): 103–6

Pirard D, Bellens B, Vereecken P (2008) The post-thrombotic syndrome — a condition to prevent. *Dermatol Online J* 14(3): 13

Roche-Nagle G, Ward F, Barry M (2010) Current prescribing patterns of elastic compression stockings post-deep venous thrombosis. *Phlebology* 25(2): 72–8

Saedon M, Stansby G (2010) Post-thrombotic syndrome: prevention is better than cure. *Phlebology* 25 Suppl 1: 14–9

Vazquez SR, Kahn SR (2010) Postthrombotic syndrome. *Circulation* 121(8): e217–e219