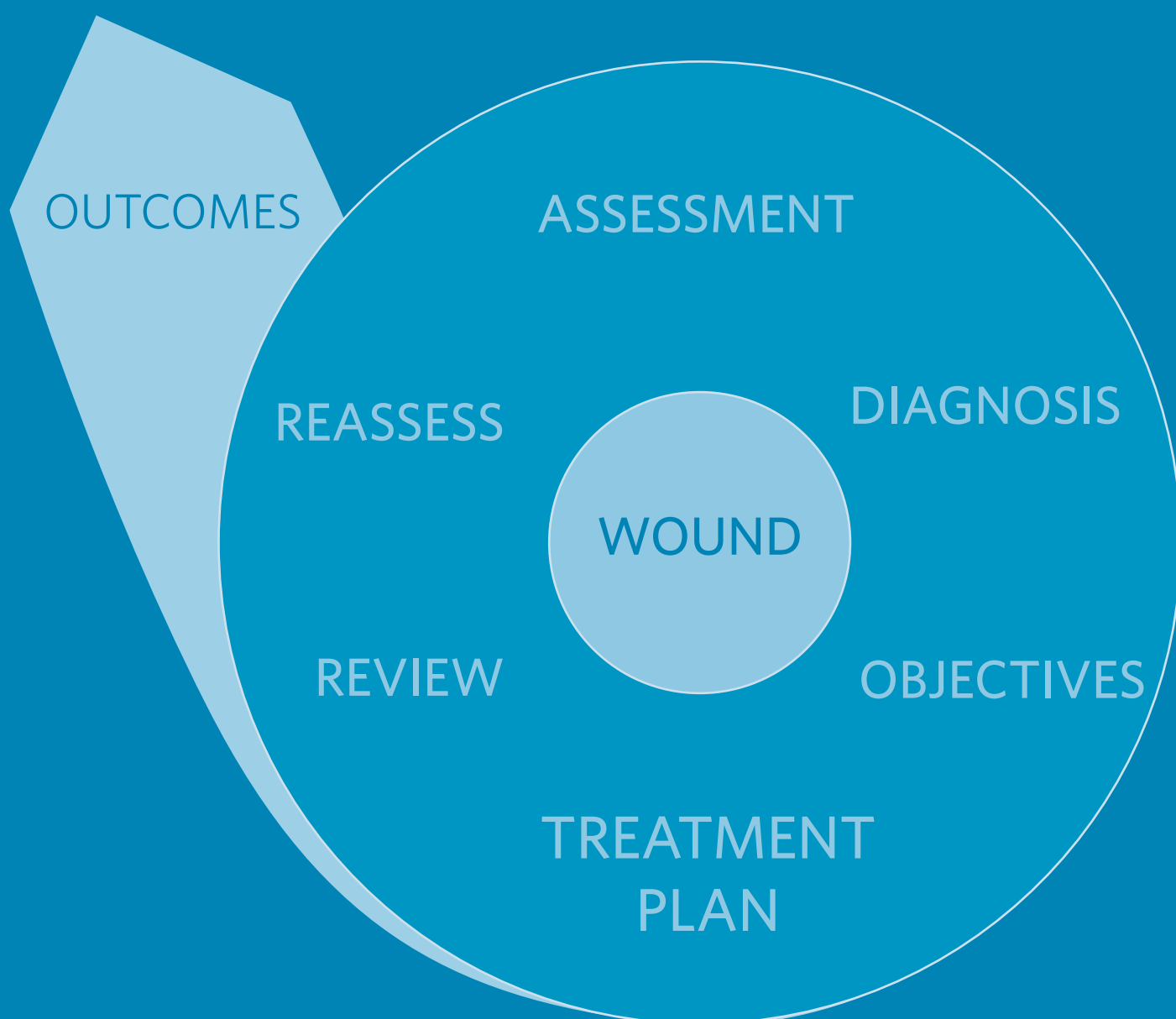


Larval debridement therapy: diabetic foot ulcer management



PUBLISHED BY:

Wounds UK
Enterprise House
1-2 Hatfields
London SE1 9PG, UK
Tel: + 44 (0)20 7627 1510
Fax: +44 (0)20 7627 1570
www.wounds-uk.com

Wounds UK

© **Wounds UK 2014**

This document has been developed by Wounds UK and supported by BioMonde.



The views expressed are those of the authors and do not necessarily reflect those of BioMonde.

How to cite this document:

Stang D, Jordan O'Brien J, Ricci E, Chadwick P. *Larval debridement therapy: diabetic foot ulcer management*. London: Wounds UK, 2014 10(2). Supplement. Available to download from: www.wounds-uk.com

The role of larval debridement therapy in diabetic foot ulcer management

Authors:

Duncan Stang, Advanced Specialist Diabetes Podiatrist and Diabetes Foot Coordinator for Scotland

Julie Jordan O'Brien, Tissue Viability CNS, Beaumont Hospital, Dublin, Ireland

“Many times wound healing is delayed as a result of late initiation of suitable debridement — all methods of debridement, and especially larval therapy, should be considered at the initial assessment”

INTRODUCTION

Larval therapy is well established as a highly-selective method of both debriding and treating diabetic foot ulcers (DFUs) and has been recognised as a potential adjunct to conventional therapy (Edwards and Stapley, 2010; Tian et al, 2013; Waniczek et al, 2013). Often, in the past, larval therapy has been used as a last resort (Evans, 1997); evidence now demonstrate that this method is safe, efficient and cost-effective (Bennett et al, 2013; Sherman, 2014).

THE ROLE OF DEBRIDEMENT IN DIABETIC FOOT ULCERS

DFUs are complex and often difficult to treat due to multifactorial problems such as poor glycaemic control, neuropathy, loss of adipose tissue, arterial insufficiency and multiple infections. Many patients with a DFU have multiple comorbidities, including cardiovascular and renal disease, increasing their risk of death if they undergo surgery (Waniczek et al, 2013).

Managing these wounds requires an understanding of pathophysiology and a multidisciplinary approach involving a comprehensive patient assessment and diagnosis, development and application of a plan of care, and ongoing evaluation and reassessment. Clinicians must address the underlying disease processes, ensuring an adequate blood supply, pressure offloading and managing the local wound environment through effective debridement and prevention of infection. Faster healing times and better outcomes can be achieved where care is delivered by a multidisciplinary foot team (MDFT) offering optimal care (Wu et al, 2007).

Many complex wounds require more than one method of debridement, not just throughout the course of treatment, but during any treatment episode. Sharp debridement is widely used by appropriately trained podiatrists and tissue viability nurses, and is considered to be the ‘gold standard’ method of debridement to facilitate the removal of all necrotic and non-viable tissue, including bone, and surrounding callus to promote the formation of healthy granular tissue and stimulate wound healing (Wounds International, 2013). This form of debridement can only be carried out by a clinician with the appropriate knowledge, skills and experience (FDUK, 2014).

Clinicians treating the wound must not limit the method of debridement to their current skill level, equipment available to them or the ability to order certain products/therapies, but must select a suitable debridement method based on assessment, even if that means onward referral. If a member of the MDFT cannot be reached immediately, to avoid any delay in treatment, alternative simpler methods of debridement can be used as an interim measure. This allows for a combination of debridement methods, for example larval therapy and sharp debridement, to be considered to achieve the treatment goals (Wounds UK, 2013).

THE ROLE OF LARVAL DEBRIDEMENT THERAPY

The primary action of larval therapy is to debride the wound (Pritchard and Nigam, 2013). Larvae of the greenbottle fly *Lucilia sericata* are used to remove slough and dead or devitalised tissue from the wound bed, leaving healthy granulation tissue (Telford et al, 2010). There is also some evidence to suggest that deep tissue debridement is possible, which may lead to more rapid removal of debris compared to many other non-surgical treatments (Sherman, 2014).

As more evidence is published, there is increased understanding of how larvae not only selectively remove dead or devitalised tissue, but can promote other activities that contribute to wound healing (Nigam, 2013; Pritchard and Nigam, 2013; Sherman, 2014). Laboratory studies have shown that larval secretions/excretions contain antimicrobial substances that kill bacteria as well as chemicals that promote tissue regeneration and restore normal wound healing processes (Cazander et al, 2013; Nigam 2013; Sherman, 2014).

"Larval therapy increases healing rates, number of antibiotic-free days, and decreases amputation rates when compared to other conventional therapies"

The ability of larvae to combat wound infections has been widely reported (Nigam, 2013). This may be simply due to rapid debridement or ingestion and subsequent destruction of wound pathogens as larvae feed (Mumcuoglu et al, 2001; Daeschlein et al, 2007). A peptide, isolated from larval secretions/excretions, has been shown to be potently active against several bacteria including *S. pyogenes* and *S. pneumoniae* (Andersen et al, 2010; Cerovsky and Bem 2014). In addition, there has been a growing interest in larval therapy in recent years due to the emergence of antibiotic resistant strains of bacteria, for example methicillin-resistant *Staphylococcus aureus* (MRSA) (Sherman, 2014). Larvae may also have a role in biofilm disruption and preventing formation (Nigam, 2013).

EVIDENCE FOR LARVAL THERAPY

The evidence of the use of larval therapy in wound debridement is limited (Edwards and Stapley, 2010), although expanding laboratory and clinical evidence has demonstrated improved healing rates in patients with DFUs (Tian et al, 2013), and potential to decrease the risk of major amputations (Gottrup and Jorgensen, 2011).

Wound healing rates

In a meta-analysis of DFUs by Tian et al (2013), four studies demonstrated a statistical significance in the healing rates between larval therapy and conventional therapy. In a retrospective case control study in 18 patients with DFUs, 14 patients achieved debridement and healed quicker than the conventional group (Sherman, 2003). Armstrong et al (2005) also found time to healing was quicker using larval therapy. The collated differences in time to healing after intervention in these studies revealed a significant difference between the larvae and control groups ($rr=3.70$ 95% CI=5.76:-1.64, $P=0.0004$).

Amputation rates

Armstrong et al (2005) and Paul et al (2009) explored amputation rates in patients with DFUs and found a statistically significant reduction in amputation rates in the larval therapy groups. Gottrup and Jorgensen (2011) reported that there has been a 20% reduction in amputation rates in Denmark in the 15 years since the therapy was implemented. Although amputation rates have decreased, the numbers of minor amputations have not and larval therapy, when used effectively, could reduce infection and amputation rates and overall costs if implemented sooner rather than later (Tian et al, 2013).

Disinfection and antibiotic use

Armstrong et al (2005) and Paul et al (2009) examined the incidence of infection in the larval therapy and control groups. When both studies were combined the incidence of infection after the intervention revealed no significant difference between both groups. However, there was a statistical difference regarding the use of antibiotics, with fewer antibiotics prescribed in the larval group compared with the control group.

Overall the findings reveal that larval therapy not only increases the healing rates and number of antibiotic-free days, but also decreases the rates of amputation and time to healing when compared to other conventional therapies (Table 1).

MAKING THE CASE FOR LARVAL THERAPY

Larval therapy can be used as part of an integrated care plan involving effective pressure relief/offloading, infection control, revascularisation, glycaemic control and patient education (Waniczek et al, 2013). As well as providing a rapid and efficient method of debridement, larval therapy may have additional effects that disinfect the wound and promote healing at a cellular level (Pritchard and Nigam, 2013). With the rise in antibiotic-resistant bacteria, alternative antimicrobial approaches such as larval therapy may play a significant role in the future management of DFUs (Andersen et al, 2010; Margolin and Gialanella 2010). Importantly, it may help to reduce the number or extent of amputations (Gottrup and Jorgensen, 2011), increasing patient quality of life and potentially reducing overall treatment costs.

TABLE 1: EVIDENCE SUMMARY FOR USE OF LARVAL THERAPY IN THE MANAGEMENT OF DIABETIC FOOT ULCERS

Author	Title of paper	Type of study	Purpose	Outcome
Tian et al (2013) <i>J Wound Care</i> 22(9): 462-9	Maggot debridement therapy for the treatment of diabetic foot ulcers: a meta-analysis	Meta-analysis performed on the evidence of 4 studies	Efficacy of larval therapy compared to standard care for DFU	Larval therapy group significantly superior to control group in the percentage of DFUs to achieve full healing ($P=0.03$); amputation rate ($P=0.02$); time to healing ($P=0.0004$) and number of antibiotic-free days ($P=0.001$). However evidence is too weak to recommend as routine therapy.
Waniczek et al (2013) <i>Evid Based Complement Alternat Med</i> Article ID 243568	Adjunct methods of the standard diabetic foot ulceration therapy	Review	Summarise the adjunct methods of DFU therapy	Preclinical and clinical trials demonstrate larval therapy may reduce time of therapy, short-term morbidity, and risk of major amputation.
Zarchi and Jemec (2012) <i>Int Wound J</i> 9(5): 469-77	The efficacy of maggot debridement therapy: a review of comparative clinical trials	Systematic review of 3 RCTs and 5 non-RCTs	To assess the efficacy of maggot therapy for treating ulcers of various aetiologies including DFUs	Studies report larval therapy as being significantly more effective than hydrogel as a debriding agent. Quality of studies poor and difficult to conclude that larval therapy shortens healing time.
Marineau et al (2011) <i>Hawaii Med J</i> 70(6):121-4	Maggot debridement therapy in the treatment of complex diabetic wounds	Observational study	23 patients with multiple comorbidities with a DFU	17 or 23 patients had improvement in their wound or complete healing.
Edwards and Stapley (2010) <i>Cochrane Database</i> 20(1): CD003556	Debridement of diabetic foot ulcers	Systematic review	Assess the effects of debridement interventions on the healing of DFUs	Larval therapy resulted in a significantly greater reduction in wound area than hydrogel. More research is needed to evaluate different methods of debridement.
Wang et al (2010) <i>Orthopaedic Surg</i> ; 2(3): 201-6	Clinical research on the bio-debridement effect of maggot therapy for treatment of chronically infected lesions	Retrospective case-control study	Evaluate the bio-debridement effect of larval therapy for treating chronically infected lesions	All ulcers healed completely and time to healing was significantly shorter than conventional group, both for pressure ulcers ($P<0.05$) and DFUs ($P<0.05$).
Paul et al (2009) <i>Int Wound J</i> 6(1):29-46	Maggot debridement therapy with <i>Lucilla cuprina</i> : a comparison with conventional debridement in diabetic foot ulcers	Prospective case-control study	Compare efficacy of larval debridement therapy ($n=29$) to standard care for DFUs ($n=30$)	There was no significant difference in outcomes. Larval therapy may be considered for those at high-risk for surgery or for those who refuse surgery.
Tantawi et al (2007) <i>J Wound Care</i> 16(9): 379-83	Clinical and microbiological efficacy of MDT in the treatment of diabetic foot ulcers	Prospective case control trial	Assess efficacy of larval therapy in 10 patients with DFUs unresponsive to conventional treatment and surgical intervention	Complete debridement achieved in all ulcers (mean 1.9 weeks), with a significant reduction in ulcer size (90.2%) in a mean of 8.1 weeks. Full healing occurred in 84.6% of ulcers. There was a rapid reduction in bacterial load after first cycle of larvae to below 10(5) threshold.
Armstrong et al (2005) <i>J Am Podiatr Med Assoc</i> 95(3): 254-7	Maggot therapy in "lower-extremity hospice" wound care: fewer amputations and more antibiotic-free days	Prospective case-control study	Assess efficacy of larval therapy in non-ambulatory patients ($n=60$) with neuroischaemic DFUs and peripheral vascular disease compared to conventional treatment	No significant difference in proportion of patients healing between groups. Of the patients that healed, time to healing was significantly shorter. Patients in the control group were more likely to undergo amputation and there were significantly more antibiotic-free days during follow-up in the larval therapy group.
Sherman (2003) <i>Diabetes Care</i> 26(2): 446-51	Maggot therapy for treating diabetic foot ulcers unresponsive to conventional therapy	Retrospective case series	Assess efficacy of larval therapy for treating foot and leg ulcers in patients with diabetes ($n=18$)	After 5 weeks of therapy conventionally treated wounds had 33% necrotic tissue coverage. Complete debridement was achieved with larval therapy after 4 weeks.

Summary of potential benefits of larval therapy in DFUs

- Established method of debridement (Sherman, 2014)
- Secondary benefits may help to promote wound healing (Pritchard and Nigam, 2013)
- May improve healing rates, reduce amputation rates and antibiotic use (Tian et al, 2013)
- 50% reduction in wound area compared with hydrogel (Edwards and Stapley, 2010)
- May reduce short term morbidity (Armstrong et al, 2005)
- Safe and effective alternative to surgical debridement in high-risk patients (Paul et al, 2009)
- More selective than surgical debridement (Gottrup and Jorgensen, 2011)
- Can be used in conjunction with NPWT (Brin et al 2007)
- May decrease overall treatment costs (Bennett et al 2013)

A recent economic evaluation comparing available debridement interventions found larval therapy to be more cost-effective than comparator debridement therapies, including surgical, sharp, mechanical and autolytic debridement (Bennett et al, 2013).

Larval therapy can be performed easily and quickly by any qualified healthcare professional with appropriate training and support. Sherman (2014) argues that larval therapy has the potential to not only “plough the field” by removing dead tissue but also “sow the seed” by stimulating cell proliferation. He proposes that careful planning of future studies and by pooling resources the clinical impact of robust studies would be beneficial to all.

REFERENCES

- Andersen AS, Sandvang D, Schnorr KM et al (2010) A novel approach to the antimicrobial activity of maggot debridement therapy. *J Antimicrob Chemother* 65(8): 1646-54
- Armstrong DG, Salas P, Short B et al (2005) Maggot therapy in “lower extremity hospice” wound care: fewer amputations and more antibiotic-free days. *J Am Podiatr Med Assoc* 95(3): 254-7
- Bennett H, Sewell B, Anderson P et al (2013) Cost-effectiveness of interventions for chronic wound debridement: an evaluation in search of data. *Wounds UK* 9(4 Suppl): 3-11
- Brin YS, Mumcuoglu KY, Massarwe S et al (2007) Chronic foot ulcer management using maggot debridement and topical negative pressure therapy. *J Wound Care* 16(3): 111-3
- Cazander G, van der Veerdonk MC, Vandenbrouke-Grauls CM et al (2010) Maggot excretions inhibit biofilm formation on biomaterials. *Clin Orthop Relat Res* 468(10): 2789-96
- Cerovsky V, Bem R (2014) Lucifensins, the insect defensins of biomedical importance: The story behind maggot therapy *Pharmaceuticals (Basel)* 7(3): 251-64
- Daeschlein G, Mumcuoglu KY, Assadian O et al (2007) In vitro antibacterial activity of *Lucilia sericata* maggot secretions. *Skin Pharmacol Physiol* 20(2): 112-5
- Edwards J, Stapley S (2010) Debridement of diabetic foot ulcers. *Cochrane Database Syst Rev* 20(1): CD003556
- Evans H (1997) A treatment of last resort. *Nurs Times* 93(23): 62-5
- Foot in Diabetes UK (FDUK) on behalf of Society of Chiropractors and Podiatrists. *Principles of Debridement: the diabetic foot. Developing a scope of practice for podiatrists in the UK*. SB Communications.
- Gottrup F, Jorgensen B (2011) Maggot debridement: An alternative method for debridement. *J Plastic Surg* 11: 290-302
- Marineau ML, Herrington MT, Swenor KM, Eron LJ (2011) Maggot debridement therapy in the treatment of complex diabetic wounds. *Hawaii Med J* 70(6): 121-4
- Margolin L, Gialanella P (2010) Assessment of the antimicrobial properties of maggots. *Int Wound J* 7(3): 202-4
- Mumcuoglu KY, Miller J, Mumcuoglu M et al (2001) Destruction of bacteria in the digestive tract of the maggot of *Lucilia sericata* (Diptera: Calliphoridae). *J Med Entomol* 38(2): 161-3
- Nigam Y (2013) Evidence for larval debridement therapy in wound cleansing and healing. *Wounds UK* 9(4 Suppl): 12-6
- Paul AG, Ahmad NW, Lee HL et al (2009) Maggot debridement therapy with *Lucilia cuprina*: a comparison with conventional debridement in diabetic foot ulcers. *Int Wound J* 6(1): 39-46
- Pritchard DI, Nigam Y (2013) Maximising the secondary beneficial effects of larval debridement therapy. *J Wound Care* 22(11): 610-6
- Sherman RA (2003) Maggot therapy for treating diabetic foot ulcers unresponsive to conventional therapy. *Diabetes Care* 26(2): 446-51
- Sherman RA (2014) Mechanisms of maggot induced wound healing: What do we know, and where do we go from here? *Evid Based Complement Alternat Med* 592419. Epub
- Tantawi TI, Gohar YM, Kotb MM et al (2007) Clinical and microbiological efficacy of MDT in the treatment of diabetic foot ulcers. *J Wound Care* 16(9): 379-83
- Telford G, Brown AP, Seabra RA et al (2010) Degradation of eschar from venous leg ulcers using a recombinant chymotrypsin from *Lucilia sericata*. *Br J Dermatol* 163(3): 523-31
- Tian X, Liang XM, Song GM et al (2013) Maggot debridement therapy for the treatment of diabetic foot ulcers: a meta-analysis. *J Wound Care* 22(9): 462-9
- Wang SY, Wang JN, Lv DC et al (2010) Clinical research on the bio-debridement effect of maggot therapy for treatment of chronically infected lesions. *Orthopaedic Surg* 2(3): 201-6
- Waniczek D, Kozowicz A, Muc-Wiergon M et al (2013) Adjunct methods of the standard diabetic foot ulceration therapy. *Evid Based Complement Alternat Med* 243568 Epub
- Wounds UK (2013) *Effective debridement in a changing NHS: A UK consensus*. Wounds UK. Available at: www.wounds-uk.com
- Wounds International (2013) *Best Practice Guidelines: Wound Management in Diabetic Foot Ulcers*. Available at: www.woundsinternational.com
- Wu SC, Driver VR, Wrobel JS, Armstrong DG (2007) Foot ulcers in the diabetic patient, prevention and treatment. *Vasc Health Risk Manag* 3(1): 65-76
- Zarchi K, Jemec GB (2012) The efficacy of maggot debridement therapy — a review of comparative clinical trials. *Int Wound J* 9(5): 469-77

The use of larval debridement therapy in diabetic foot ulcer management

Authors:

Elaine Ricci, Clinical Specialist
Podiatrist — Diabetes and
Wound Care, Sunderland Royal
Hospital.

Paul Chadwick, Consultant
Podiatrist, Salford Royal
Foundation Trust

The development of a diabetic foot ulcer (DFU) is a major event and is a sign of progressive disease (Young et al, 2008). Recent evidence has demonstrated a five-year mortality rate of 45–50% in patients with a DFU, and indicates that the outlook is worse for patients who have undergone amputation, which has a two-year mortality rate of 50% (Kerr, 2012).

The National Institute for Health and Care Excellence (NICE) has established best practice guidance for the treatment of DFUs (NICE, 2004; 2011). This guidance states that any patient presenting with an ulcer must be assessed by a diabetes multidisciplinary foot team (MDFT) within the first 24 hours. This approach has been shown to lead to better outcomes for patients (All Party Parliamentary Group on Vascular Disease, 2014), resulting in a >50% reduction in amputations where hospitals have introduced a MDFT and promoted rapid access to them.

IMPORTANCE OF ASSESSMENT

Patients with active ulceration need to have a comprehensive assessment to include a full patient history, any medications, comorbidities and current diabetes status (e.g. glycaemic control). It should also take into consideration the history of the wound, previous DFUs/amputations, and any symptoms suggestive of neuropathy (i.e. loss of protective sensation) and poor arterial flow, requiring involvement of the vascular team.

Recording the size, depth (including any undermining or tunnelling), and location of the ulcer as well as the amount and type of devitalised tissue to be removed will help inform the treatment plan. The use of photography may be helpful to document progress of any interventions. The area around the wound should also be assessed for evidence of additional complications (e.g. erythema, maceration, gangrene), which may delay healing (Figure 1).

Recognising infection in patients with DFUs can be challenging, but is one of the most important steps in assessment. Early and aggressive treatment of even subtle signs of infection is important to prevent life-threatening complications (Wounds International, 2013). Clinically uninfected wounds should not be treated with systemic antibiotic therapy. However, virtually all infected DFUs do require antibiotic therapy (Lipsky et al, 2012).

CAUSES AND CONTRIBUTORY FACTORS OF DELAYED HEALING

In patients with diabetic foot problems, often a combination of factors cause the tissue to breakdown. All of the co-existing factors must be addressed when treating patients with DFUs. With optimal care, involving adequate offloading and good wound care, the majority of ulcers will heal within 12 weeks of treatment (Boulton et al, 1999). The expected healing rate is a reduction in wound size by more than 50% in four weeks. Failure to attain this healing trajectory despite optimal care can be used as a predictor of delayed healing (Sheehan et al, 2003).

Wound healing is a complex integrated process, and in diabetic patients there are many changes that occur in the biochemistry of the wound that predispose to delayed or stalled healing (Blakytyn and Jude, 2006). These include (Henderson, 2006; Wolcott et al, 2009; Kirketerp-Møller et al, 2011):

- elevated levels of proinflammatory cytokines
- elevated metalloproteinases
- elevated neutrophils
- impaired response to growth factors
- impaired neuroinflammatory signalling
- the influence of wound biofilm and senescent cells.

Recognition of non-healing demands careful reassessment of the wound to identify barriers to healing. The earlier the wound healing problems are detected, the better the outcomes for the patient (Vowden, 2011).

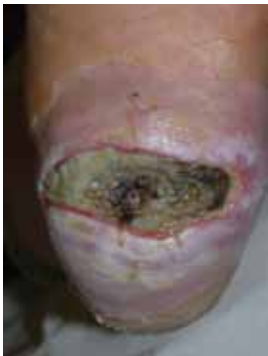

Figure 1: Debridement is indicated to remove slough and necrotic tissue in the wound bed. Such non-viable tissue can act as a nidus for infection. Larval therapy may be the preferred method where the wound is too painful for sharp debridement.

FOOT MANAGEMENT CONSIDERATIONS

DFUs heal more quickly and are often less complicated by infection when in a moist environment and adequately offloaded. However, this is often challenging due to the complexity of the wound and where it is located.

Foot wounds with significant tissue loss, such as trans-metatarsal amputations, tend to be very moist, usually from oedema and extrusion of tissue fluid through the wound bed due to the effects of gravity. The DFU is a polymicrobial, glucose-rich environment, so the addition of any extra moisture can encourage and promote infection. Dressing selection is therefore critical in maintaining a moist wound environment that optimally promotes healing, which is often a difficult balance to strike. In addition, many dressings are designed for non-foot areas of the body and may be difficult to apply between or over the toes or plantar surface, while forces such as peak plantar pressures and shearing forces can dislodge and damage dressings on the foot.

With any DFU, a critical issue is how to offload pressure from the wound. Identifying the optimal offloading device needs to be made on an individual patient basis. If the patient has a good fitness level this is relatively easy — the 'gold standard' treatment being the total contact cast or removable diabetic walker. If the patient is quite elderly or there is a loss of mobility, the addition of an offloading device can cause falls, or problems with knees, hips and lower back that can lead to poor patient concordance.

DEBRIDEMENT OF DIABETIC FOOT ULCERS

Debridement helps reduce the rate of infection and provides an ideal healing environment. Before initiating therapy, it is important to ask the following questions using a risk assessment process (Table 1). Where surgical debridement is not an option and rapid removal of devitalised tissue is required, larval therapy is a recognised option (Boulton, 2007).

TABLE 1: Questions to ask before initiating debridement	
Question	Why it should be asked?
Why debride?	It is important to understand the rationale for debridement
What am I trying to achieve?	Before starting therapy, define treatment aims and the exit strategy if treatment goals are reached. Review treatment aims at each dressing change (Figure 2).
Is it realistic to attempt to debride this wound?	You should consider whether the wound is capable of healing/is the patient at end-of-life?
Is it safe?	Safety is the most pressing issue in any decision to debride. The key safety issues for most patients relate to quality of arterial blood flow to the foot and the risk of damage to vitality or functionality of important structures. Other issues relate to infection risk, the pain caused by the debridement process and the patient's ability to receive anaesthesia.
Do I have the necessary skills?	Debridement should be performed by an experienced specialist in consultation with the specialist multidisciplinary team to avoid clinical risks (FDUK, 2014).
Is the environment appropriate in which debridement will be undertaken?	Wound debridement should be performed in a suitable environment under aseptic conditions using the Aseptic Non-Touch Technique (ANTT) to reduce the risk of healthcare-associated infections (Rowley and Clare, 2011).

“Before starting LDT it is crucial that a management plan is in place to maximise the long-term benefits of this therapy”

SELECTING LARVAL THERAPY FOR DIABETIC FOOT WOUNDS

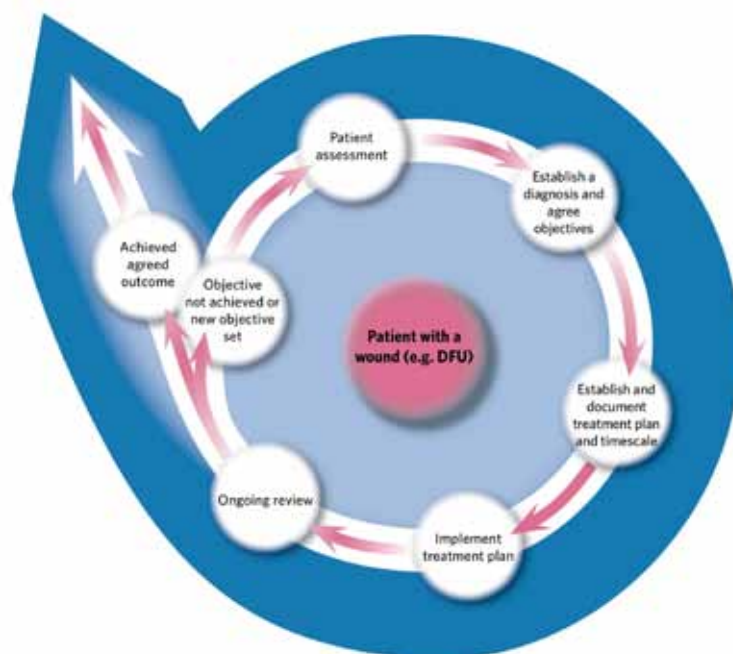
The decision to use larval therapy must be taken by a specialist practitioner with the appropriate skill, knowledge and experience. However, the application of larval therapy may be applied by any qualified healthcare practitioner who has reached an appropriate level of competency through training and who has adequate provision of clinical support (AWTVN, 2013). Potentially all patients with a neuropathic DFU are suitable candidates for larval therapy and it is indicated where there is an overall clinical decision for the rapid debridement of devitalised tissue that is delaying wound healing. Wounds most suited to larval therapy include moist, sloughy/necrotic wounds.

Prior to initiating therapy it is important to explain fully to patients the benefits and risks of using larval therapy and this should be supported by evidence-based information and the patient given the opportunity to ask questions prior to consent (Haycocks and Chadwick, 2008).

Key questions to be asked when deciding which debridement technique to use include:

- How rapid does debridement need to be?
- Is the patient in pain?
- Is the arterial blood supply compromised?
- Is the patient mobile and can pressure be offloaded from the wound site?
- Are there any precautions/contraindications (e.g. is the patient on anticoagulant therapy)?
- Does the patient consent to treatment?

Figure 2: A debridement pathway underlining the importance of assessment, documentation, ongoing evaluation and reassessment (from Gray et al, 2011).



The rationale for debridement using larval therapy should be documented in the patient's record and evaluated at each dressing change as part of an overall management plan (Figure 2).

HOW TO APPLY LARVAL DEBRIDEMENT THERAPY

The most commonly used mode of application for larval therapy is the BioBag. The larvae are sealed within a woven dressing pouch containing small pieces of foam that protect the larvae during the early stages of treatment. This method is well tolerated by patients and is easy to apply, allowing good visualisation of the wound bed.

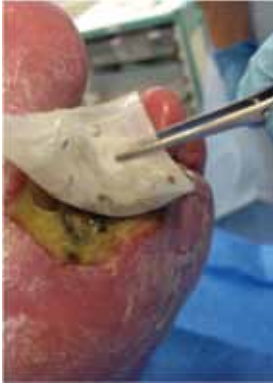

Figure 3: Larval therapy being applied to a sloughy wound after toe amputation.

Free range larvae can be applied directly to the wound and retained in a special dressing system for a maximum of 4 days. However, they can be very difficult to contain due to problems in applying the dressing to the foot/toe area and subsequent movement of the foot during walking.

Selection of an appropriate offloading device is fundamental to the initiation of LDT in patients with DFUs. Foot wounds that are easiest to treat are those that are on the dorsum and borders of the foot. Wounds on the plantar aspect in ambulant patients are most difficult, but not impossible to treat with larval therapy. Advice should be given about how to avoid applying pressure to plantar surface of the foot when walking, while the use of crutches may be considered to offload. Any offloading device needs to be removable to allow visual inspection of the wound. The use of padding (e.g. semi-compressed felt or hydrocolloid dressing) can be used to build up the surrounding area to create a trench, which will protect the larvae from vertical forces.

The effectiveness of the BioBag method and free-range application is similar; however, for complicated undermined cavity wound, free-range larvae may be preferable (Gottrup and Jorgensen, 2011).

Calculators and size guides are available from the manufacturers to determine the size of bag or number of larvae for the wound to be debrided.

PRACTICAL TIPS FOR APPLICATION

1. Use a single BioBag or combination of BioBag sizes, suitable for the wound size.
2. Irrigate the wound using saline to remove dressing residues and loose material.
3. Apply a skin barrier cream to protect the intact periwound skin.
4. Place the BioBag(s) onto the wound. Fold or double back to avoid contact with the periwound skin (Figure 3).
5. Ensure the larvae are moist by placing a moistened gauze swab over the BioBag.
6. Apply an absorbent outer dressing to manage wound exudate and maintain a non-occlusive environment for the larvae.
7. Secure all dressings by taping outer edges of the absorbent dressing or apply a light retention bandage.
8. Discuss avoidance of weight-bearing on plantar wounds.

Outer dressings should be checked or changed on daily. Each application of larvae can be left in place for up to 4 days before removal. All BioBags/larval dressings should be disposed of as clinical waste.

Although one application may be sufficient, if required, two or more treatments can be used consecutively or over a period of time to achieve a healthy, clean wound bed with evidence of granulation tissue. Exudate will be a red/brown colour due to breakdown of tissue and this should not be confused with bleeding. In addition, the wound treated with larval therapy does have a distinctive odour and it is important to explain this to the patient prior to application to alleviate any undue concern and premature termination of the therapy.

Most patients are unaware of the presence of larvae during treatment, although some, particularly those with a poor arterial blood supply, report that their wounds become more painful during larval debridement therapy. Treatment is still possible using appropriate analgesia as part of a pain management plan. Titration of analgesia is indicated if the patient has a painful wound prior to treatment. This may include the use of opioids or peripheral nerve blocks (Mumcuoglu et al, 2012).

PRECAUTIONS AND CONTRAINDICATIONS

Larvae should not be used in the following situations:

- Wounds that communicate with a body cavity or internal organ

- Wounds in close proximity to a large blood vessel
- If the patient has a coagulopathy where bleeding from the site could be problematic.
- Wounds with dry necrotic eschar/callus.

Caution is advised in those with highly exuding wounds and in patients with clotting issues, as larval therapy may increase the risk of bleeding.

WOUND MANAGEMENT POST-LARVAL THERAPY

The following treatment options may be considered after larval debridement therapy:

- Application of negative pressure wound therapy to continue to promote the formation of granulation tissue
- Use of topical antimicrobial products to reduce the reformation of a bacterial biofilm and prevent infection.
- Offloading.

This approach is designed to continue the healing progress and reduce, as far as possible, the factors that would stall healing. In addition, good moist wound healing, dependent on the state and/or stage of the wound, is important for good outcomes in these complex wounds.

REFERENCES

- All Party Parliamentary Group on Vascular Disease (2014) *Tackling Peripheral Arterial Disease more Effectively: Saving Limbs Saving Lives*. All Party Parliamentary Group. Available at: <http://bit.ly/1gxwA7D> (accessed 27.05.2014)
- All Wales Tissue Viability Nurse Forum (AWTVN) (2013) *All Wales Guidance on: Larval debridement therapy*. AWTVN Available from <http://www.welshwoundnetwork.org/en/resources>
- Blakytyn R, Jude E (2006) The molecular biology of chronic wounds and delayed healing in diabetes. *Diabet Med* 23(6): 594–608
- Boulton AJ (2007) Topical treatment for painful diabetic neuropathy? *Curr Diab Rep* 7(6): 407–8
- Boulton AJ, Meneses P, Ennis WJ (1999) Diabetic foot ulcers: a framework for prevention and care. *Wound Repair Regen* 7(1): 7–16
- Foot in Diabetes UK (FDUK) on behalf of Society of Chiropodists and Podiatrists (2014). *Principles of Debridement: the diabetic foot. Developing a scope of practice for podiatrists in the UK*. SB Communications.
- Gottrup F, Jorgensen B (2011) Maggot debridement: An alternative method for debridement. *J Plastic Surg* 11: 290–302.
- Gray D, Acton C, Chadwick P, et al (2011) Consensus guidance for the use of debridement techniques in the UK. *Wounds UK* 7(1): 77–84
- Haycocks S, Chadwick P (2008) Sharp debridement of diabetic foot ulcers and the importance of meaningful informed consent. *Wounds UK* 4(1): 51–56
- Henderson EA (2006) The potential effects of fibroblast senescence on wound healing and the chronic wound environment. *J Wound Care* 15(7): 315–8
- Kerr M (2012) *Foot Care for People with Diabetes: The Economic Case for Change*. NHS Diabetes. Available at: <http://bit.ly/1jCR9ho> (accessed 27.05.2014)
- Kirketerp-Møller K, Zulkowski K, James G (2011) Chronic wound colonisation, infection, and biofilms. In: *Biofilm Infections*. Springer, Germany: 11–24.
- Lipsky BA, Peters EJG, Berendt AR, et al (2012) Specific guidelines for the treatment of diabetic foot infections 2011. *Diabetes Metab Res Rev* 28: 234–5. doi: 10.1002/dmrr.2251
- Mumcuoglu M, Davidson E, Avidan A, Gilead L (2012) Pain related to maggot debridement therapy. *J Wound Care* 21(8): 400–5
- National Institute of Health and Care Excellence (2004) Type 2 diabetes: Prevention and management of foot problems. Clinical guideline CG10. Available at: <http://guidance.nice.org.uk/CG10> (accessed 27.05.2014)
- National Institute of Health and Care Excellence (2011) Diabetic foot problems: Inpatient management. Clinical guideline CG119: Available at: <http://guidance.nice.org.uk/CG119> (accessed 27.05.2014)
- Rowley S, Clare S (2011) ANTT: a standard approach to aseptic technique. *Nursing Times* 107(36): 12–14
- Sheehan P, Jones P, Caselli A, et al (2003) Percent change in wound area of diabetic foot ulcers over a 4-week period is a robust predictor of complete healing in a 12-week prospective trial. *Diabetes Care* 26(6): 1879–82
- Vowden P (2011) Hard to heal wounds Made Easy. *Wounds International* 2(4). Available from www.woundsinternational.com
- Wolcott RD, Kennedy J, Dowd S (2009) Regular debridement is the main tool for maintaining healthy wound bed in most chronic wounds. *J Wound Care* 18(2): 54–6
- Wounds International (2013) *Best practice guidelines: Wound management in diabetic foot ulcers*. Wounds International. Available from: www.woundsinternational.com
- Young MJ, McCardle JE, Randall LE, Barclay JI (2008) Improved survival of diabetic foot ulcer patients 1995–2008: Possible impact of aggressive cardiovascular risk management. *Diabetes Care* 31(11): 2143–7

CASE STUDIES

USING LARVAL THERAPY AS A DIAGNOSTIC INDICATOR OF HEALING

Elaine Ricci

CASE 1

Larval debridement therapy is often advocated as a last resort treatment when conservative means for wound bed preparation prove unsuccessful or when surgery is not feasible owing to comorbidities or other considerations.

In the following case, larval therapy was used in conjunction with good clinical assessment to indicate potential to heal. The patient had diabetes, severe peripheral arterial disease affecting the distal run-off vessels. There were no surgical options available to improve the blood flow to the foot. Following emergency surgery to remove infected tissue the foot was left with a large sloughy wound that was not healing. The decision was taken to debride utilising larval therapy (Figure 1).

Two applications of larvae were prescribed, which removed the sloughy tissue in the wound bed, but failed to stimulate production of granulation tissue. At the end of larval therapy, the wound became very sloughy within days (Figure 2). This indicated that the foot was incapable of mounting a healing response. Within a week the foot deteriorated further. The professional consensus of the multidisciplinary foot team was that the foot was no longer viable and a below-knee amputation was performed.

CASE 2

In a similar case, this patient with diabetes was not suitable for arterial reconstructive surgery. The wound had been static for 8 weeks following debridement surgery for infection. Again larval therapy was the treatment of choice due to the delicate nature of the tissue — the blood supply to the foot was very precarious and sharp/surgical debridement in theatre would have put at risk the vitality of the limb and the patient's health (Figure 3).

After two applications of larval therapy, the wound was slough free and there was evidence of granulation tissue (Figures 4 and 5). The wound went on to heal uneventfully (Figure 6).

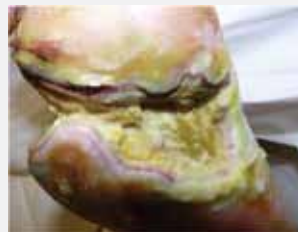

Figure 1: Appearance of foot just prior to the first application of larvae.

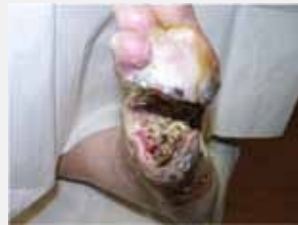

Figure 2: The wound after the second application of larvae.

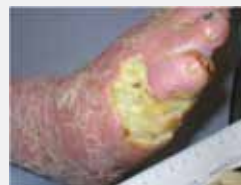

Figure 3: The foot prior to the application of larval therapy.

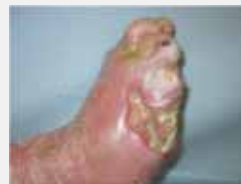

Figure 4: After the first application of larval therapy.

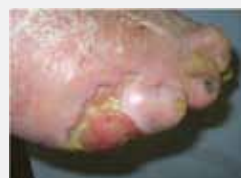

Figure 5: After the second application of larval therapy.

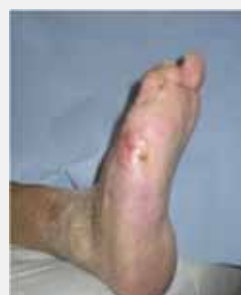

Figure 6: The wound went on to heal uneventfully.

"At each follow-up visit there was a reduction in wound size and volume"

USING LARVAL THERAPY TO STIMULATE WOUND HEALING

Elaine Ricci

CASE 3

A 69-year-old man presented to the diabetic foot clinic on 1 May 2012. He had been an inpatient after presenting to A&E three days previously with an infected neuropathic ulcer to his right first metatarsal head. He had a 17-year history of type 2 diabetes and had retinopathy and ischaemic heart disease.

On examination he also had peripheral sensory neuropathy. He had palpable foot pulses, although these were damped on doppler assessment. The previous day he had been to theatre and undergone debridement of this wound. The foot remained clinically infected. He was treated with intravenous flucloxacillin 2g four times daily and metronidazole 400mg twice daily. He was discharged after a hospital stay of 12 days and was given oral antibiotics. He had a negative pressure wound therapy (NPWT) device *in situ*.

The main challenges in treating this wound were the extent of the infection and the location. Despite the hospital discharge, the wound remained very deep and sloughy, probing to the joint capsule of the first metatarsal head. It was clear that the ligaments and tendons had been badly damaged by the infection. The wound was successively sharp debrided with a scalpel, which removed some, but not all, of the sloughy and devitalised tissue. The patient continued with NPWT for two weeks and this was discontinued due to a poor response.

His foot was offloaded initially with an Aircast removable walker, but unfortunately he was unable to tolerate this therapy due to severe knee and back pain. He was given a combination of 20mm semi-compressed felt padding, a fibreglass removable slipper cast and an OrthoWedge forefoot pressure-relieving sandal. Despite this, the wound remained static with poor quality granulation tissue.

On 23 May he underwent an initial single application of larval therapy to stimulate wound healing (Figure 1). This application of larvae improved the wound by desloughing, promoting granulation tissue and progressing the wound.

By 15 June it was clear that the improvements made following the first application of larvae were short-lived and the wound, although relatively free from slough, had become static, which was thought to be due to the presence of a biofilm.

The wound appearance over a period of 4 weeks is shown in Figure 2. At each follow up visit the wound was sharp debrided and various topical antimicrobial products used. Despite this, the wound remained static.

After a discussion, it was decided to reapply larvae to stimulate the healing process. A single application of larvae was given on 3 August 2012 (Figure 3) and the larvae were left in place for 4 days. When the larvae were removed they were much smaller in appearance than normal and some had died in the bag as there was insufficient food available to sustain them. Post-application the wound was dressed with antimicrobial dressings to maintain the wound bed.

Following this second application of larval therapy, the wound made remarkable progress towards healing (Figure 4). At each follow-up visit there was a reduction in wound size and volume. The wound healed (Figure 5) uneventfully 10 weeks following the second application of larvae.

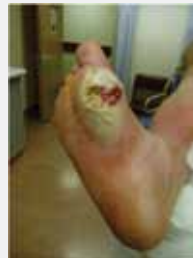

Figure 1: An initial single larval treatment was applied to the ulcer.

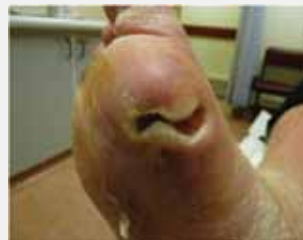

Figure 2: The wound developed a static appearance despite the application of larvae.

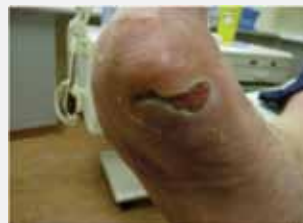

Figure 3: Characteristic wound appearance at the second larvae application. There was a translucent sloughy film coating the wound bed and pale, poor-quality granulation tissue. The wound edges are undermined.

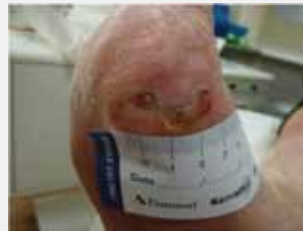

Figure 4: 22 days after the second application of larvae.

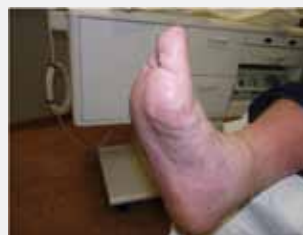

Figure 5: The wound had healed by 12 October — 10 weeks following the second application of larval therapy.

USING LARVAL THERAPY AFTER TOE AMPUTATION

Paul Chadwick

CASE 4

This 73-year-old gentleman had type 2 diabetes with no neurological deficit. He had severe distal vessel arterial disease and no pulses were palpable below the knee.

He developed an ulcer on his third toe, which became septic following a holiday taken against medical advice. This resulted in amputation of the 2nd and 3rd toes while abroad (Figure 1).

Once back in the UK, he had a formal forefoot amputation and angiography revealed unreconstructable peripheral arterial disease. The wound dehiscd and became sloughy (Figure 2).

The wound was very painful, preventing sharp debridement, and a below-knee amputation was considered. Larval therapy was applied to help save the limb (Figure 3). The wound responded well and 3 weeks after larval therapy and the application of a non-adherent dressing, the wound was healing well (Figure 4).

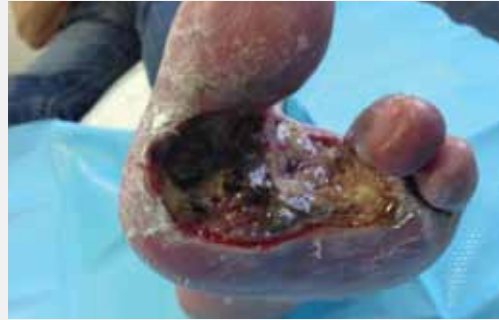

Figure 1: The wound prior to forefoot amputation.

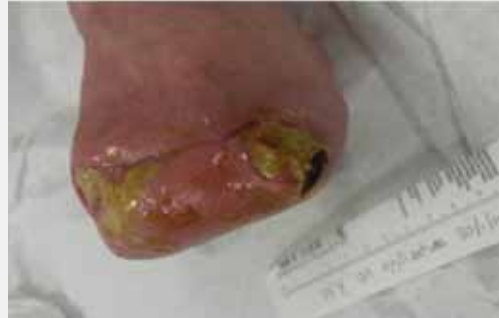

Figure 2: Post surgery the wound dehiscd and became sloughy.

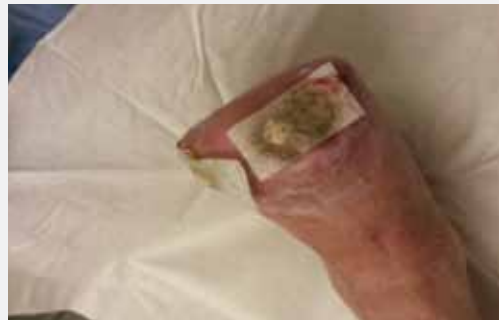

Figure 3: Larval therapy in situ prior to removal.

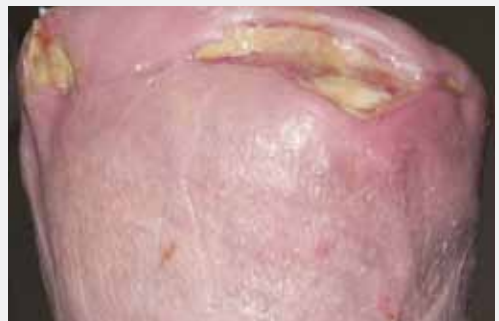

Figure 4: Three weeks post larval therapy and moist wound healing. The wound is in a healing trajectory.

