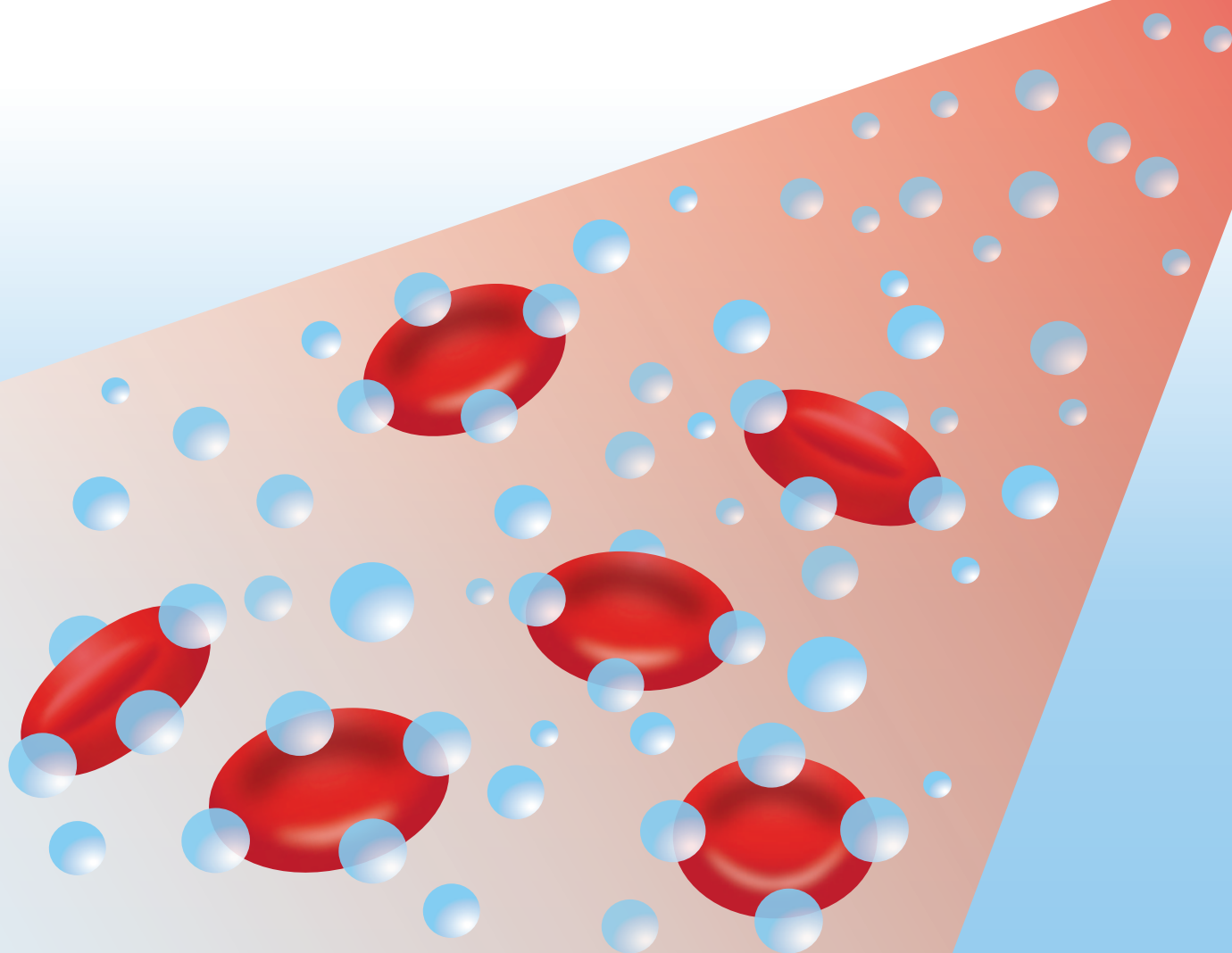


Oxygen wound therapy: The clinical and cost impact of using topical haemoglobin spray (Granulox[®])



PUBLISHED BY:

Wounds UK
1.01 Cargo Works
1-2 Hatfields
London SE1 9PG, UK
Tel: + 44 (0)20 3735 8244
Fax: + 44 (0)800 242 5031
www.wounds-uk.com

Wounds UK

© **Wounds UK 2017**

This document has been developed by Wounds UK and supported by an unrestricted educational grant from **infirst Healthcare Ltd.**



The views expressed are those of the authors and do not necessarily reflect those of **infirst Healthcare Ltd.**

How to cite this document:

Oxygen wound therapy: The clinical and cost impact of using topical haemoglobin spray (Granulox®). London: Wounds UK, 2017. Available to download from: www.wounds-uk.com

FOREWORD

Granulox® (infirst Healthcare Ltd, UK) is a topical sterile haemoglobin spray, which is designed to transport oxygen to slow-healing and non-healing wounds that have not responded to standard care, such as venous leg ulcers, arterial leg ulcers, mixed leg ulcers, diabetic foot ulcers, secondary healing of surgical wounds and pressure sores. Its mode of action is different from other oxygen therapies as it allows oxygen to diffuse through the normally impermeable exudate of the wound, and thus improves the oxygen supply to the wound bed. Granulox is an adjunct treatment to be used in combination with standard wound care. Granulox can also be used on sloughy and infected wounds.

It has been accepted wisdom for some time that oxygen is vital to wound healing. Hyperbaric oxygen therapy was first used in the field of wound care in the 1960s following the discovery that patients with burns who received treatment for carbon monoxide poisoning healed more quickly (Wada et al, 1965). More recently the role of topical oxygen therapy, without the need for full-body hyperbaric chambers, has come to the fore (Tawfick and Sultan, 2009).

Oxygen is required for normal cellular processes, and 97% of chronic, non-healing wounds have been shown to have low oxygen levels. Mild hypoxia (low oxygen) is a normal biological response following an injury. Along with a cascade of initial responses, injury causes oxygenated plasma to diffuse from the surrounding intact tissue to the hypoxic wound area, in order to aid healing (Bishop, 2008). Granulox assists in this process by improving the oxygen supply to the wound bed.

This supplement highlights the clinical and cost impact of using Granulox, through case studies, an example of best practice and an examination of the cost data. The real-life examples from clinics in the UK illustrate the role Granulox can play in reducing wound-related pain and slough, improving healing and reducing costs (Hunt, 2015).

Jacqui Fletcher, Independent Nurse Consultant

HOW TO USE GRANULOX

1. All wounds showing signs of delayed healing should be optimised using the principles of wound bed preparation (Dowsett and Newton, 2005) to decrease bacterial load, manage exudate levels and remove non-viable tissue.
2. As Granulox is sprayed, haemoglobin begins to bind to atmospheric oxygen, and the process of oxygen transportation to the wound commences (Figure 1).
3. Once saturated with oxygen, the haemoglobin becomes oxyhaemoglobin (HbO_2), which diffuses to the base of the wound (Figure 2: A), and increases the oxygen supply to the cells by diffusion (Figure 2: B).
4. The normal dressing regimen should be continued with a breathable/non-occlusive wound dressing (Figure 3). Granulox should be applied every time the dressing is changed, or at least every 3 days.

References

- Bishop A (2008) *J Wound Care* 17(9): 399-402
Dowsett C, Newton H (2005) *Wounds UK* 1(3): 58-70
Hunt S (2015) *Wounds UK* 11(4):90-5
Tawfick WA, Sultan S (2009) *Eur J Endovasc Surg* 38(1): 125-32
Wada J et al (1965) *Igakunoaymi (Japan)* 54-68

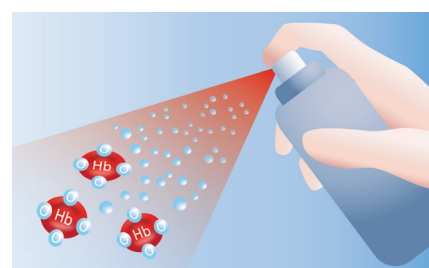


Figure 1

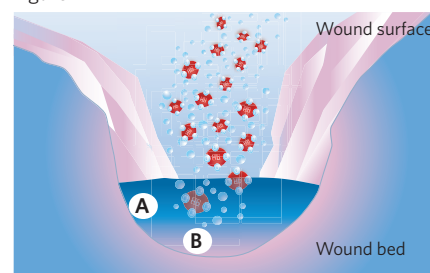


Figure 2

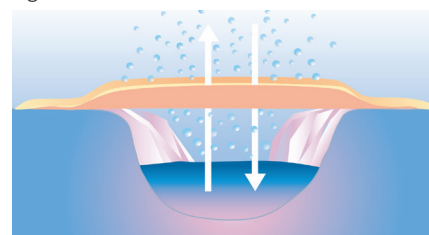


Figure 3

SIGNIFICANCE OF OXYGEN: TO LIFE, BIOFILMS AND WOUND HEALING

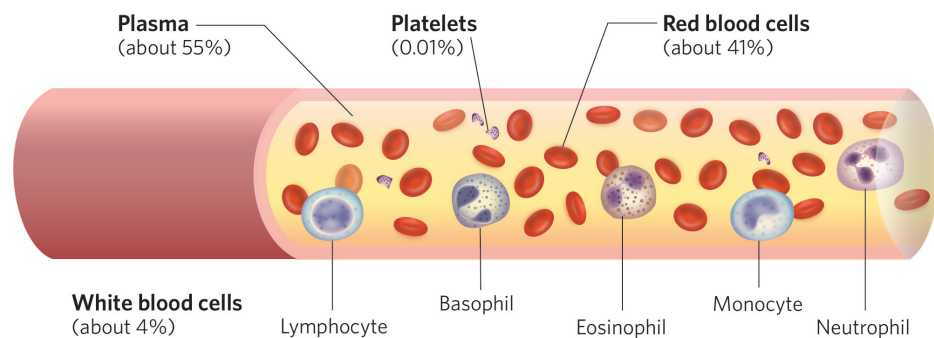
Author

Steven L Percival,
CEO, Centre of Excellence
in Biofilm Science and
Technologies (CEBST), UK

THE CARDIOVASCULAR SYSTEM IN SUMMARY

The human cardiovascular system comprises the heart, blood and blood vessels and functions to transport gases (mainly oxygen and carbon dioxide), nutrients and hormones around the body. In humans, the circulatory system normally exists as a closed system; however, nutrients and oxygen can diffuse across blood vessel walls and enter the interstitial fluid, a solution that bathes and surrounds tissue cells.

Figure 1: Composition of blood



Blood is composed of plasma, platelets, erythrocytes (red blood cells) and leukocytes (white blood cells) (Figure 1). Oxygen is transported in the blood by erythrocytes, which contain haemoglobin (Hb), an iron-containing metalloprotein. Oxygen binds to the haem group of Hb in the lungs, and forms oxyhaemoglobin (HbO_2) (Figure 2: A). As blood moves around the body, HbO_2 dissociates and releases oxygen molecules to tissues and cells. Cells use oxygen to generate adenosine triphosphate (ATP), an important energy source for normal cellular function, growth and regeneration.

The heart pumps oxygenated blood, high in HbO_2 , from the lungs to regions of the body low in oxygen or hypoxic. Once oxygen has been offloaded, oxygen-depleted blood (now high in carbon dioxide) returns to the lungs where it becomes oxygenated again and the cycle continues (Figure 2: B).

OXYGEN IN HIGH DEMAND IN WOUND HEALING

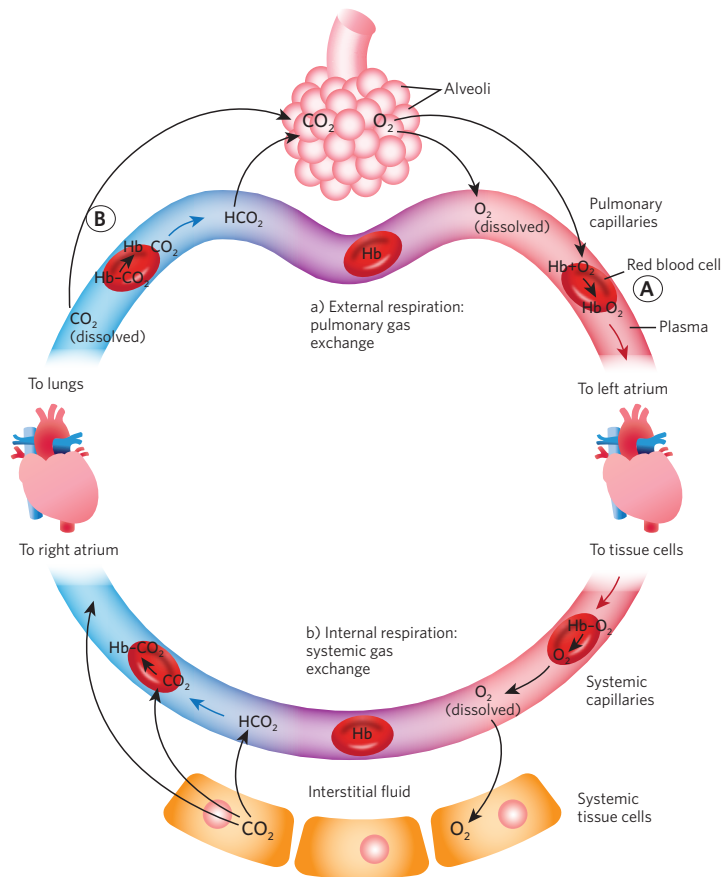
It is well-known that oxygen is vital to wound healing. Wound cells require oxygen for ATP generation, to maintain and increase many of the cellular processes necessary to wound healing, from the initial immune response, fibroplasia, angiogenesis, connective tissue reconstruction, epithelialisation and ultimate closure (Cianci and Hunt, 1993; Gottrup, 2004).

Wound hypoxia is caused by the amount of oxygen delivered to the wound being less than the amount needed, and studies have suggested that tissue oxygen partial pressure may be a good predictor of wound outcome (Bodily and Burgess, 1983). Many chronic wounds have poor blood perfusion, and oxygen requirements become higher the longer a wound remains open (Im and Hoopes, 2010; Schreml et al, 2010). Improving the oxygen supply to wounds is integral to encouraging wound healing.

CHRONIC WOUND MICROBIOLOGY AND BIOFILMS

All chronic wounds contain microorganisms, which reside within both the planktonic, free-floating state, and the sessile, attached state (Percival and Dowd, 2010; Attinger and Wolcott, 2012). Within the sessile state, microbes live within a biofilm community (Percival, 2017). The role biofilms play in increasing wound hypoxia is presently not known despite work in the dentistry field and other biofilm-related conditions. However, it is believed that biofilms increase tissue hypoxia (Kolpen et al, 2010).

Figure 2: Oxygen transport cycle (Tortora and Derrickson, 2014)



Of specific interest is the role anaerobic bacteria, which are found within biofilms, play in the deterioration of wounds delay in healing. Anaerobic bacteria, sometimes referred to as the 'silent villains' in wounds, are reported to impede the healing process (Wall et al, 2002), affecting cellular healing either in isolation or in synergies with other microbes (Stephens et al, 2003). Increased oxygen in the wound bed has the potential to inhibit the proliferation of strict anaerobic bacteria as they thrive in oxygen-depleted environments (Hunt et al, 1975; Gordillo et al, 2008).

Oxygen is believed to adjust the microbiology in a chronic wound (Percival and Dowd, 2010). Increased oxygen may lead to a reduction in the net pathogenic effect of the wound microbiota and improve wound healing. Additionally, the process of microbial phagocytosis by innate neutrophils requires high levels of oxygen (Jesaitis et al, 2003), a process that produces reactive oxygen species, which inhibit and destroy microorganisms.

RATIONALE FOR OXYGEN THERAPY IN WOUND HEALING

Administration of oxygen to the wound bed represents an important component of the wound management strategy. The role of oxygen in wound healing was first discovered when patients receiving hyperbaric oxygen therapy (HBOT) for carbon monoxide poisoning had burns that healed faster than those who did not receive HBOT (Wada et al, 1965). HBOT increases the amount of dissolved oxygen in the blood, which enhances healing by increasing angiogenesis (Gibson et al, 1997). However, not all patients can tolerate or have access to high-pressure oxygen chamber.

Localised topical oxygen therapy can provide a more accessible oxygen delivery system than HBOT. It has long been known that the skin is capable of gas exchange, and that oxygen can penetrate the skin. However, the thickness of the skin is a barrier to oxygen diffusion (epidermis <1.5 mm, dermis <3 mm, compared to the lungs <1 µm; Ladizinsky and Roe, 2010). Wound exudate also acts as a diffusion barrier and as a result, ensuring atmospheric oxygen reaches deep into a wound represents a significant challenge. To ensure high-concentration oxygen is delivered to hypoxic tissue to facilitate oxygen diffusion deep in the wound, the properties of haemoglobin for oxygen uptake and offloading can be used.

As discussed, haemoglobin is able to bind and offload oxygen into regions of low oxygen tension. The addition of haemoglobin into areas of low oxygen, i.e. hypoxic chronic wounds, can assist in adjusting oxygen levels and help to enhance wound healing.

Granulox is a haemoglobin topical spray and is an adjunct treatment to standard wound care. haemoglobin is sprayed from the canister on to the wound and binds to atmospheric oxygen to form HbO₂. HbO₂ diffuses to the wound base, increasing the oxygen supply to the wound cells through facilitated diffusion. The addition of haemoglobin can help to reduce hypoxia in wounds and may have an effect in biofilm reduction. See page 1 for more information on the mode of action of Granulox.

References

- Attinger C, Wolcott R (2012) *Adv Wound Care* 1(3): 127-32
- Bodily KC, Burgess EM (1983) *Am J Surg* 146(2): 280-2
- Cianci P, Hunt TK (1993) *Adjunctive hyperbaric oxygen therapy in the treatment of diabetic wounds of the foot*. In: Levin ME, O'Neal LW, Bowker JH (eds). *The Diabetic Foot*. 5th ed. St. Louis, MO, USA: Mosby Year Book; 1993:305-19
- Gibson JJ, Angeles AP, Hunt TK (1997) *Surg Forum* 48: 696-9
- Gordillo GM, Roy S, Khanna S et al (2008) *Clin Exp Pharmacol Physiol* 35(8):957-64
- Gottrup F (2004) *World J Surg* 28(3):312-5
- Hunt TK, Linsey M, Grisliis G et al (1975) *Ann Surg* 181(1): 35-9
- Im MJ, Hoopes JE (2010) *J Surg Res* 10(10): 459-64
- Kolpen M, Hansen CR, Bjarnsholt T et al (2010) *Thorax* 65(1): 57-62
- Jesaitis AJ, Franklin MJ, Berglund D et al (2003) *J Immunol* 171(8): 4329-39
- Ladizinsky D, Roe D (2010) *Wounds* 22(12): 294-300
- Percival SL, Dowd SE (2010) *The Microbiology of Wounds*. In: Percival SL, Cutting KF eds. *The Microbiology of Wounds*. CRC Press, Taylor & Francis Group LLC, New York
- Percival SL (2017) *Br J Surg* 104: e85-e94
- Schreml S, Szeimies RM, Prontl L et al (2010) *Br J Dermatol* 163(2): 257-68
- Stephens P, Wall I, Wilson M et al (2003) *Br J Dermatol* 148(3): 456-66
- Tortora GJ, Derrickson BH (2014) *The Respiratory System*. In: Tortora GJ, Derrickson BH (eds). *Principles of Anatomy and Physiology*. 14th ed. London, UK: John Wiley & Sons.
- Wall IB, Davies CE, Hill KE et al (2002) *Wound Repair Regen* 10(6): 346-53
- Wada J et al (1965) *Igakunoayumi (Japan)* 54-68

CASE SERIES USING GRANULOX ON A VARIETY OF ULCERS AT A GLASGOW CLINIC

Author

Celia Macaskill,
Dermatology Clinical
Nurse Specialist, Greater
Glasgow and Clyde,
Scotland

In a dermatology clinic in the Greater Glasgow and Clyde area, Granulox treatment was used on eight people on a range of slow or non-healing ulcers, e.g. leg ulcers, pressure ulcers, arterial ulcers, venous ulcers. Granulox was used on ulcers present for >3 months that had not responded to standard care, or on- and off-formulary dressings and treatments. One wound had been static for 1 month, and one pressure ulcer had been treated for 2 years without response. The groups were aged 19-90 years, and two patients had additional arterial problems, leading to a further ischaemia and reduced oxygen to the wounded area (Sen, 2009). Granulox was prescribed to be applied two to three times a week with each dressing change.

OUTCOMES

Among the group, Granulox was used on ulcer bases that were clean, non-malodorous and static. In most cases, granulated tissue developed from the base up and wound healing began to progress. For some patients, the wound reduced in size and re-epithelialised. Granulox was used on wounds that were sloughy, as it has been shown to remove 100% of slough in 4 weeks (Hunt, 2015). There was also a reduction in wound pain among the cohort, and Granulox appeared to promote and accelerate healing of slow-healing ulcers that had been present for many years. Cases 1 and 2 provide a detailed description of two individuals, and Box 1 provides an overview of the other six patients.

BOX 1: ADDITIONAL CASES IN SUMMARY

- 19-year-old man with spina bifida and a grade 3 pressure ulcer on the left flank present for a year. He had a superficial lesion approximately 8cm (length) x 3cm (width) caused by pressure and friction from clothes. Previous treatments had included silver and iodine dressings, and negative pressure wound therapy. Granulox therapy was commenced; the patient's mother irrigated the wound, administered Granulox and applied the secondary adhesive foam dressing. The wound healed within 2 months of starting Granulox.
- 90-year-old female with a non-healing grade 4 pressure ulcer on the heel for 3 years. The ulcer was 2cm (length) x 2cm (width), and previous treatments have included various dressings and off-loading devices. Granulox therapy was commenced and within 2 months the area had halved in size. After 3 months of use, the wound healed.
- 88-year-old woman with Parkinson's disease and a grade 4 pressure ulcer on her clavicle. The ulcer was 6cm (length) x 5cm (wide) x 0.5cm (deep), going down to muscle fascia. After 2 weeks of using Granulox, new skin had started to form at the wound edges and the wound depth reduced to 0.1cm. Unfortunately the patient died due to other health problems.
- 82-year-old blind woman with bilateral venous ulceration. The ulcers were superficial, but were over 12cm in length. She had fixed ankles and reduced mobility. This patient had a history of ulceration for over 10 years, which have shown signs of improvement, but have never completely healed. She was referred to the dermatology clinic by the district nurse when the level of exudate became a problem. She required daily or 3 times weekly visits depending on exudate levels and received compression therapy, but her fixed ankles limited its function. Granulox was initiated and the wound started to improve from a very wet ulcer to a healing base. Both wounds reduced in size and the number of clinical visits reduced as well, freeing up nursing time.
- A man of approximately 60 years of age had a small venous ulcer on outer aspect of malleolus left leg. He was obese and had longstanding venous issues. The patient felt his condition improved after using Granulox for 2 months: however, he received venous surgery and Granulox was discontinued.
- 60-year-old man with heavily exuding, ulcerated toes and recurrent wound infections. Granulox was initiated and the skin condition improved and exudate levels reduced. The patient was admitted to hospital with infection of the toes. At the time, Granulox was withdrawn as per the instructions for use at the time (Granulox is now indicated for use in infected wounds).

CASE 1: GRANULOX REDUCED PAIN IN MULTIPLE VENOUS LEG ULCERS

This female patient had a 3-year history of ulceration and presented with venous leg ulcers of the left leg. Prior to Granulox treatment, the previous regimen included wound irrigation, a gentle foam dressing and compression leg ulcer hosiery kit, as the patient could not tolerate bandaging. It had been difficult to find a dressing that was not painful and did not cause further deterioration of ulcers.

Figures 1 and 2 show the extent, size and depth of the wounds to the left leg. There was a moderate odour before the dressing was removed, and the patient reported that the pain was 6–7 out of 10 (1=no pain, 10=worst pain). Between dressing changes, pain was scored at 8 out of 10. Granulox was administered and the patient was advised to change the dressing twice a week and reapply Granulox at each dressing change. The patient had previously been susceptible to contact allergy to many other dressings, but Granulox elicited no irritation.

GRANULOX THERAPY

Two weeks after Granulox initiation, the wounds had a medium level of exudate and the tissue was 100% granulating in the wound on the outside of the leg (Figures 3 and 4). The level of pain on dressing change and between dressing changes had reduced to 2 out of 10. The surrounding skin had improved, and the clinician commented that the rapid pain reduction was remarkable. The patient was reviewed weekly and continued to apply Granulox and a breathable, soft foam dressing twice a week at home.

FINAL ASSESSMENT

Five months later, the ulcers had epithelialised (Figures 5 and 6), and there was no odour from the wound. The surrounding skin was normal, and the patient's comfort and pain level had improved. Granulox appeared to reduce the patient's pain and encourage wound healing. The patient's outlook and quality of life improved, and, as she was able to self-care, less nursing and clinical time was required.

CASE 2: GRANULOX ADMINISTERED TO A NON-HEALING ARTERIAL ULCER

This 67-year-old woman had an arterial ulcer on the right medial malleolus. She had previously had a stroke and had peripheral arterial disease, so was unsuitable for high compression therapy or surgery. The local health centre struggled for over a year to find a dressing regimen to manage the high level of exudate. When referred to the dermatology clinic, she had difficulty walking and was in a lot of pain due to exudate seeping down and causing skin maceration. The wound was 13.5cm (length) x 6.5cm (wide) x 0.2cm (deep) and static. It was 40% sloughy and 60% granulating, and there were no signs of infection. The surrounding skin was macerated and eczematous (Figure 7). The patient rated the pain on dressing change and between dressing changes at 6 out of 10.

GRANULOX THERAPY

Granulox therapy was considered as an adjunct treatment to compression therapy. At each appointment, the wound was irrigated, and Granulox and a foam dressing was applied. Over time, pain between dressing changes reduced dramatically from 8 to 1 out of 10, and the wound size and level of exudate reduced (Figures 8 and 9). The wound was reviewed by the nursing team once a week, and she applied Granulox, a foam dressing and compression stocking at home.

After 4 months of Granulox, the wound comprised 80% granulating tissue and 20% epithelialisation tissue, and the surrounding skin was less red. Dressing changes were reduced from daily to 3 times weekly.

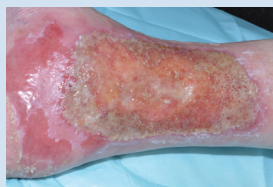

Figure 7: Initial assessment. December 2015

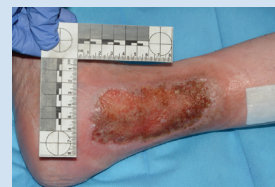

Figure 8: January 2016

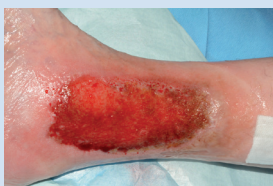

Figure 9: February 2016

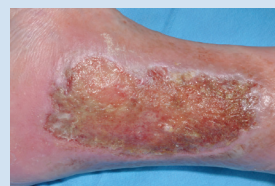
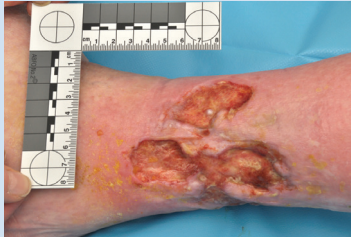
Figure 10: April 2016

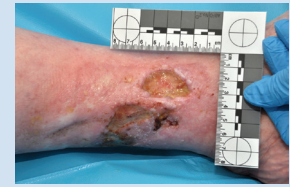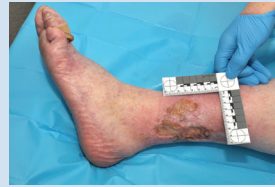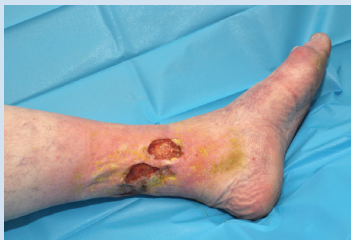After 5 months of use, the wound was 10cm (length) x 4.6cm (width) with islands of epithelialisation (Figure 10). By this stage, the patient was able to use a compression hosiery rather than bandaging.

FINAL COMMENTS

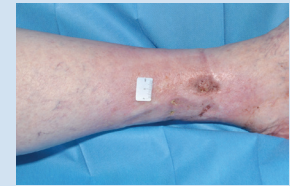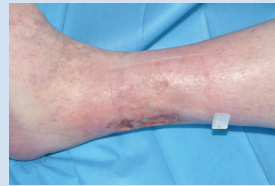Granulox reduced pain, exudate levels and dressing change frequency from daily to 3 times weekly. The edges of the wound started to epithelialise and the patient was able to continue self care at home and be more mobile.



Figures 1 & 2:
Leg ulcers on the left leg before Granulox use. November 2015



Figures 3 & 4: First assessment. December 2015



Figures 5 & 6: Final assessment. April 2016

DISCUSSION

The clinician and patients found Granulox easy to use. Granulox was found especially useful for those who could not tolerate full compression bandaging, even though it can be used with compression bandaging. If compression bandaging or a topical steroid was administered for periwound or stasis eczema, Granulox was usually administered two or three times a week at each dressing change. Granulox can also be used continuously in conjunction with antimicrobials in infected wounds.

Granulox was considered an appropriate treatment when pain was a problem (Arenbergerova et al, 2013; Bateman et al, 2015a; 2015b). One patient (Case 1) had a very painful ulcer, but was reluctant to take analgesia continuously, and it had been a challenge to find a suitable dressing that did not cause pain. As a retired nurse, the patient was keen to self care and applied Granulox and dressings with great dexterity, though the ulcers were in difficult-to-reach areas. Granulox provided an appropriate treatment due to its 'no touch' application. It also decreased the patient's level of pain, with almost immediate results after initial use.

References

- Arenbergerova M, Engels P, Gkalpakiotis S et al (2013) *EWMA Journal* 13(2): 1-7
- Bateman S (2015a) *Br J Community Nurs* 20(Suppl 9): S32-9
- Bateman S (2015b) *Br J Nurs* 24(12): S24-9
- Sen CK (2009) *Wound Repair Regen* 17(1):1-18

AN OVERVIEW OF A SMALL MEDICAL PRACTICE IN SCOTLAND MANAGING SLOW OR NON-HEALING WOUNDS

Author

Sue Sullivan and Tracy Lavery, Practice Nurses, Leslie Medical Practice, Leslie, Fife, Scotland

Leslie Medical Practice is a small practice in Glenrothes in Fife, East Central Scotland. In 2015, a new treatment pathway was established at the practice for non-healing wounds. Granulox is a haemoglobin spray comprised of highly purified haemoglobin and is a novel approach for increasing oxygen availability in the wound bed of non-healing wounds, such as diabetic foot ulcers, pressure ulcers, venous leg ulcers and surgical wounds. This article describes how the Leslie Medical Practice implemented Granulox in the treatment of non-healing wounds and reports on the positive clinical outcomes and patient experience.

SETTING THE SCENE

Leslie is a large village and parish of approximately 3,000 people, and is situated to the west of Glenrothes in Fife, East Central Scotland. Fife accounts for 6.9% of the total population of Scotland, and the prevalence of diabetes in Fife is around 21,000 or 5.8%, which is above the average in Scotland (NHS Scotland, 2016). The percentage of people in Fife with diabetes who have had a lower limb amputation is also above the Scottish average (NHS Scotland, 2016).

Leslie Medical Practice is a relatively small practice with around 6,500 patients and has 4 GPs, 2 nurses, 1 healthcare assistant and 7 admin staff. The practice covers Leslie, Glenrothes and the surrounding areas. There is no podiatry or diabetes service attached to the practice, so patients requiring secondary care are referred to a Central Hospital Service in Fife, which is at least half an hour's drive away and many have to rely on public transport or NHS ambulance services to get there. The practice nurses at the centre can also seek guidance from Tissue Viability Nurse services at Victoria Hospital, Kirkcaldy, Fife, if they require further advice about wounds.

BEST PRACTICE AT THE LESLIE MEDICAL PRACTICE

To provide care for patients closer to their home and in the community, the clinical staff at Leslie Medical Practice developed a new treatment plan incorporating Granulox in combination with standard wound care: any patient with a slow- or non-healing wound present for 4 weeks or more was commenced on Granulox, while continuing with the prescribed dressing regimen. Patients initiated on the Granulox treatment pathway had Granulox applied every third day in the clinic, as part of their usual dressing change. At each dressing change, the wound was cleaned, Granulox was administered, and the wound was covered with a semi-permeable dressing.

OUTCOMES FROM THE PRACTICE

In the clinic, seven people were eligible to start Granulox treatment, with leg ulcers present from 2–36 weeks (Table 1). One person did not want to start treatment. Pain at the start of treatment ranged from 1 to 7 out of 10, and all six patients who completed the treatment experienced a reduction in pain following the use of Granulox therapy.

At the start of treatment, slough levels ranged from 10% to 90%, and by the end, slough had disappeared from all wounds. This is inline with results seen by Hunt and Elg (2016), where patients were slough-free with Granulox after 4 weeks. The wound healed completely in 4 cases. For the two ulcers that had been present for the longest time, over 6 months, the wounds significantly decreased in size.

Table 1: Summary of patients treated with Granulox

Patient (relevant symptoms)	Ulcer present (weeks)	Slough (start)	Slough (finish)	Pain reduction	Wound reduction	Patient acceptability (out of 10)
1	5	90%	0%	yes	yes - wound closed	_
2 (poor vascularity)	2	10%	0%	yes	yes - wound closed	9
3 (diabetes, poor vascularity and a smoker)	36	10%	0%	yes	No	9
4	8	80%	0%	yes	yes - wound closed	_
5 (poor vascularity)	7	80%	0%	yes	yes - wound closed	9
6	35	70%	0%	yes	yes - wound closed	9

Box 1: Tips for use of Granulox in practice

- Inform patients of the red appearance of the product in advance of use
- Discuss the ingredients of Granulox and address any concerns
- Excess exudate levels can be managed alongside the use of Granulox treatment
- Take appropriate action to avoid staining of clothes and use an appropriate (breathable) secondary dressing to prevent strikethrough and leakage
- Cleanse the wound at each dressing change
- Reapply Granulox every 72 hours for optimum effect
- To prevent the nozzle from becoming blocked, consider rinsing the nozzle with warm water or saline directly after use
- Depending on wound size, one spray can is sufficient for approximately 30 applications
- Ideally Granulox should be stored in the fridge. If not possible, non-refrigerated products will last at least 6 weeks

COST IMPLICATIONS

The use of innovative products such as Granulox alongside robust patient and carer education and patient involvement in care are vital in ensuring that care is appropriate, consistent, beneficial and cost-effective (Bateman et al, 2015). Using Granulox at Leslie Medical Practice was more cost-effective than the previous regimen as fewer dressings and bandages, and thus less nursing time, were required.

In a retrospectively controlled community-based UK study on diabetic foot ulcers over a 28-week period, Granulox showed significant cost savings compared to standard care alone. In the cohort of 20 patients on Granulox and 20 patients on standard care, there was a £128 (4%) cost saving in dressings and £2442 (72%) cost saving in nursing time, based on actual costs at wound care phases (Granulox, 2016).

CONCLUSION

Granulox was used on wounds that had not progressed or healed for more than 4 weeks, and continues to be used on patients with wounds that have been present for 4 weeks or more. Granulox demonstrated positive and effective outcomes in wound closure, wound size reduction, pain and slough for non-healing ulcers.

References

- Bateman S (2015) *Wounds UK* 11 (4): 90-5
- Granulox (2016) Data to support the cost effectiveness of Granulox in a clinical setting. Infirst Healthcare Ltd
- Hunt TK, Zederfeldt B, Goldstick TK et al (1969) *Am J Surg* 118: 521-5
- Hunt S, Elg F (2016) *Diabet Foot Ankle* 7(7): 33101
- NHS Scotland (2016) *Scottish Diabetes Survey 2016*. NHS Scotland, Available at: <http://bit.ly/2wLd4Ce> (accessed 03.10.17).

COST IMPACT OF GRANULOX

Author

Chris Bojke,
Professor of Health
Economics, Academic
Unit of Health Economics,
University of Leeds, UK

Treatment of non-healing wounds is estimated to cost the NHS £5 billion a year; 78% of which is due to chronic wounds (15%) that do not resolve after a year (Guest et al, 2015). The majority of wound-related costs derive from three distinct but related factors: wound duration, dressing change frequency and associated complications, e.g. amputations (Lindholm and Searle, 2016). A therapy that addresses any or all of these factors has the potential to be cost-saving.

GRANULOX HAEMOGLOBIN SPRAY

Granulox is an adjunct to standard wound care practice, and facilitates the diffusion of oxygen from the atmosphere directly to a hypoxic wound bed. The cost impact of using Granulox as adjunct therapy in a UK setting was assessed using a study of chronic diabetic foot ulcers (DFUs; Hunt and Elg, 2016). Twenty patients with a DFU present for >12 weeks were treated with Granulox and followed for 28 weeks. The cohort was retrospectively controlled and compared with 20 patients from the previous year who had a DFU who received standard care only. There were no statistically significant differences between cohorts at baseline (e.g. age, gender, wound duration).

There was no recorded variation in application volume across wound size, so any dressing change is assumed to consume one application of Granulox, which is estimated to cost £4.17 (canister costs £125 for an average of 30 applications). Using micro-costing of resource use, the cost per dressing change for standard care is estimated at £57, the majority of which is attributable to nursing time. The cost per dressing change with Granulox is estimated at £61, the cost of standard care plus the cost of one application of Granulox.

COST EFFECTIVENESS

Healing rates from the study by Hunt and Elg (2016) were estimated using a log-logistic survival model, which extrapolated the observed rates to 52 weeks. Figure 1 shows the estimated healing rates for the initial wound if all 40 patients in the study received standard care compared to that expected with the same 40 patients receiving standard care plus Granulox. The analysis accounted for any variation in patient characteristics across cohorts. Table 1 shows the overall expected annual cost summary for the initial DFUs for standard care versus standard care plus Granulox therapy.

Figure 1: Modelled counterfactual healing rates for population in the DFU study by Hunt and Elg (2016)

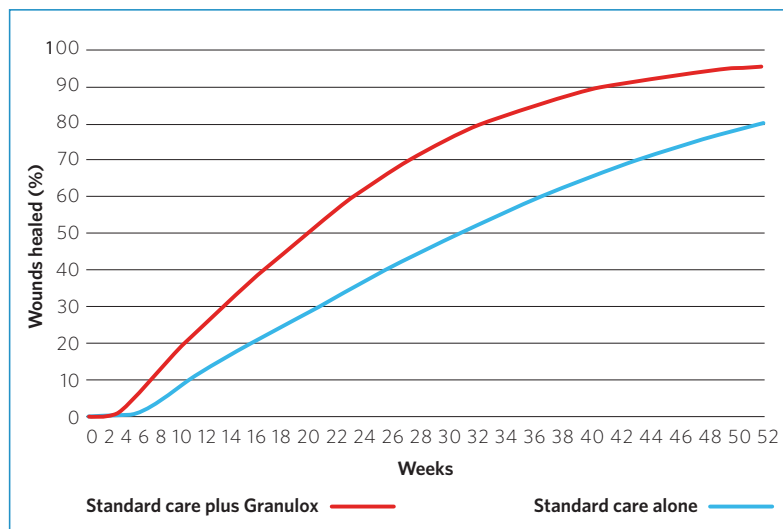


Table 1: Overall expected annual cost summary for DFUs.
 Calculated using data from Hunt and Elg (2016) applied to modelled counterfactual healing rates.

	Standard care	Standard care plus Granulox treatment
Cost per dressing change	£57	£61
Dressing change frequency	3.3	2
Healing time (weeks)	35	21
Dressing change (frequency x healing time)	115	42
Total cost per annum	£6,576	£2,550
Wounds healed (%)	80	96

From this analysis, it is estimated that the expected cost saving could be approximately £4,000 per patient. The cost-saving result is robust to both probabilistic and deterministic sensitivity analysis, for example:

- If we assume Granulox has no impact on healing rates, the impact of fewer dressing changes per week generates an expected cost-saving of £2,300.
- If we assume Granulox has no impact on dressing change frequency, the faster healing rate generates an expected cost-saving of £2,369.
- If we assume 25% product wastage, no-can sharing between patients, and the can is discarded when a wound heals, there is an expected cost-saving of £3,927.

CONCLUSION

Standard care plus Granulox has a higher cost per dressing change compared to standard care alone; however, the statistically significant improvement to healing rates and dressing change frequency leads to a cost offset that compensates the cost. Granulox could reduce total costs of initial DFU treatment by around 60% a year.

References

- Guest JF, Ayoub N, McIlwraith T et al (2015) *BMJ Open* 5: e009283
 Hunt SD, Elg F (2016) *Diabet Foot Ankle* 7: 33101
 Lindholm C, Searle R (2016) *Intern Wound J* 13: 5-15

