

‘Wound Preparation’ using a 2-in-1 cleansing and debridement tool

KEY WORDS

- ▶ Alprep® Pad
- ▶ Debridement
- ▶ Wound assessment
- ▶ ‘Wound Preparation’

Healthcare professionals involved in wound cleansing and debridement need a good understanding of wound bed preparation (WBP) and how to create an optimal environment for wound healing and assessment. WBP is a systematic approach to evaluate and remove barriers to healing and allow the wound healing process to progress normally (Schultz et al, 2003; Falanga, 2004). Barriers to healing may include wound aetiology, patient age and the presence of significant comorbidities, as well as wound size and depth, location of the wound, wound duration, and the presence of a heavy bioburden (Vowden, 2011). Alprep® Pad (Coloplast) is a 2-in-1 cleansing and debridement tool suitable for use in a wide variety of wounds where WBP is needed.

The elements of wound bed preparation (WBP) should be selected according to the results of a patient and wound assessment, such as the Triangle of Wound Assessment (Dowsett and von Hallern, 2017; *Figure 1*), a holistic framework that allows healthcare professionals to assess and manage all aspects of the wound, including the periwound skin. Periwound management has a significant impact on WBP and wound healing, yet it is often an overlooked area (LeBlanc et al, 2021). Considering this, it may be timely for terminology to change from WBP to ‘Wound Preparation’ (WP) to ensure that the wound edge and periwound skin are also suitably managed, especially as more generalist nurses become involved in wound care.

Wound assessment should identify and address underlying disease, nutritional status, mobility, wound characteristics, allergies/sensitivities, psychosocial factors, and concomitant drugs/therapies. This assessment should also consider the impact of all aspects of the patient’s health and wellbeing on the healing process.

CLEANSING AND DEBRIDEMENT

WP through cleansing and debridement is essential in wounds that contain slough, non-viable tissue, or biofilms as these act as a barrier to creating the right environment for wound healing and assessment. Cleansing has additional benefits, such as removal of excess exudate and wound dressing remnants,

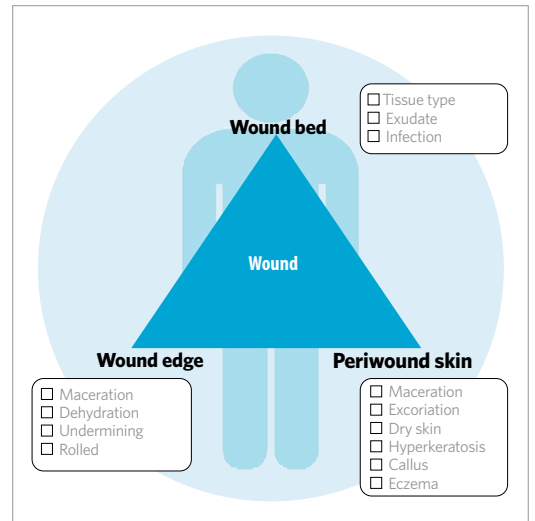


Figure 1. The Triangle of Wound Assessment (Dowsett and von Hallern, 2017)

thus improving visualisation of the wound bed and edges (Weir and Swanson, 2019). Debridement helps to reduce bioburden and manage infection risk in chronic wounds that are at high risk of developing infection or biofilms (Strohal et al, 2013; Percival and Suleman, 2015; Anghel et al, 2016). Debridement can also help to reduce potential pain associated with devitalised tissue, improve quality of life and healing outcomes (Gray et al, 2011; Strohal et al, 2013; Davies et al, 2015). For example, Wilcox et al (2013) investigated healing outcomes and debridement frequency in over 300,000

KEITH MOORE
Clinical Nurse Specialist Tissue Viability; Bridgewater Tissue Viability Team Lead, Hallwood Health Centre, Runcorn, UK

EMMA BAXTER
Tissue Viability Nurse, Hallwood Health Centre, Runcorn, UK

Definitions

Cleansing: Removal of surface contaminants, bacteria, and remnants of previous dressings from the wound surface and its surrounding skin (Rodeheaver and Ratliff, 2018).

Debridement: Removal of dead, non-viable/devitalised tissue, and infected or foreign material from the wound bed and surrounding skin (Wounds UK, 2013).

Table 1. Types of debridement (Leaper, 2002; Gray et al, 2005; Granick et al, 2006; Gray et al 2011)

Type	Description
Autolytic	<ul style="list-style-type: none"> • Process by which the body attempts to rehydrate, soften, and liquefy hard eschar and slough using moisture • Dressing choice will support moist wound healing.
Biological	<ul style="list-style-type: none"> • Larvae/maggots grown in a sterile environment are applied to the wound bed to remove necrotic and devitalised tissue • Extended competencies are not required.
Enzymatic	<ul style="list-style-type: none"> • Performed by the application of a prescribed topical agent that chemically liquefies necrotic tissue with enzymes • Extended competencies are not required.
Mechanical	<ul style="list-style-type: none"> • Traditional method involves gauze that dries and adheres to the top layer of the wound bed, which is 'pulled' away when the dressing is removed • Other forms include debridement pads, hydrosurgery or ultrasound • Extended competencies are not required.
Surgical/sharp	<ul style="list-style-type: none"> • Removal of dead or devitalised tissue using a scalpel, scissors and/or forceps to just above the viable tissue level • May be undertaken in conjunction with other therapies (e.g. autolysis) • Requires extra training and competency.

patients and concluded that, the diabetic foot ulcer, median time to heal for weekly or more frequent debridement was 21 days, compared with 64 and 76 days for 1-to-2 week or 2-week or more intervals between debridements, respectively.

There are many types of debridement, including autolytic, biological, enzymatic, mechanical, and surgical/sharp (see Table 1), with some requiring healthcare professionals to possess specific skills. For effective debridement, it is well recognised that healthcare professionals must be confident and knowledgeable about all methods available (Price and Young, 2013; Wounds UK, 2013) to be able to recognise the most appropriate technique for the patient and their wound (Vowden and Vowden, 2011). This can support them to accurately gauge the extent of a wound (Callaghan and Stephen-Haynes, 2012), facilitating accurate wound assessment and decision-making.

In clinical practice, often initial and ongoing responsibility for wound assessment and delivery of continuing care is carried out by generalist clinicians; however, capability level and local policy can influence their choice of debridement method (Price and Young, 2013). Using a debridement tool that allows all clinicians to perform optimal WP in an easy and controlled manner, without the need for

specialist, enhanced training could help to facilitate WP at every dressing change and assist with continuity of care.

INTRODUCING ALPREP® PAD

Alprep Pad is a new 2-in-1 cleansing and debridement tool (Figure 2). It is suitable for a wide variety of wounds, including non-infected wounds, infected wounds, or wounds with suspected biofilm. The tool is designed for improved absorption and can help to simplify cleansing and debridement for healthcare professionals to support optimal WP.

The pad has an ergonomic grip for ease of use and increased control, and the special triangular shape makes for comfortable handling. The unique packaging can be used to wet the pad with an irrigation solution of choice and, when finished, the case can be reused to hold the pad for appropriate disposal. A specially designed QR code can also be found on the retail box, allowing healthcare professionals to view the application video prior to use (Figure 3).

Alprep Pad presents two tools in one; the dark grey foam is for loosening and the light grey softer foam is for absorbing and capturing. The unique slits in the light grey foam are designed for increased absorption and aid efficient removal of



Figure 2. Alprep Pad, a new 2-in-1 cleansing and debridement tool



Figure 3. Specially designed QR code for Alprep Pad

non-viable tissue, slough, and skin scales, including hyperkeratotic scales, from the wound bed, wound edge and periwound skin. It also removes biofilms and microorganisms from the wound surface.

PRODUCT EVALUATION

In a recent product evaluation, the clinical use of Alprep Pad for the cleansing and debridement of wounds were evaluated to determine effectiveness and ease of use for healthcare professionals. The evaluation was carried out during a period of up to 21 days. The evaluation required the healthcare professional responsible for wound management to complete a wound assessment form, perform an evaluation of the debridement session at each wound dressing change, as well as a baseline questionnaire with patient and wound information, and a final evaluation questionnaire. A total of 46 patients with a total of 53 different wounds were evaluated in up to three debridement sessions per wound. All patients, except five, completed three debridement sessions; a total of 153 debridement sessions were performed.

Results following debridement with Alprep Pad showed an overall reduction of 31% in pain

level prior to each debridement session. No pain to minimal pain was reported during 78% of debridement sessions when using Alprep Pad. Compared to usual debridement tools, healthcare professionals reported that Alprep Pad caused much less or less pain in 43% ($n=66$). Patients (14%) were receiving analgesia for the purpose of the debridement procedure. In terms of effectiveness, up to 20% of debris/necrosis/slough was reportedly removed when using Alprep Pad in 50% ($n=76$) of debridement sessions, 20–50% in 27% ($n=41$); 50–80% in 9% ($n=14$), and >80% in 5% ($n=8$). Figure 4 shows the mean wound area (length x width) was 30.1cm² at the first debridement session and 19.9cm² at the last debridement session, which equates to an area reduction of 10.1cm² (34%) during the study duration. In most wounds, the main tissue types were granulating and sloughy tissue. Figure 5 shows the mean proportion of granulating tissue increased from 36.0% (visit 1) to 57.6% (visit 3), thus an increase of 60%. Simultaneously, the mean proportion of sloughy tissue decreased from 69.5% (visit 1) to 45.4% (visit 3), thus a reduction of 35%.

It was reported that debris/necrosis/slough was absorbed into the Alprep Pad in 84% ($n=129$) of

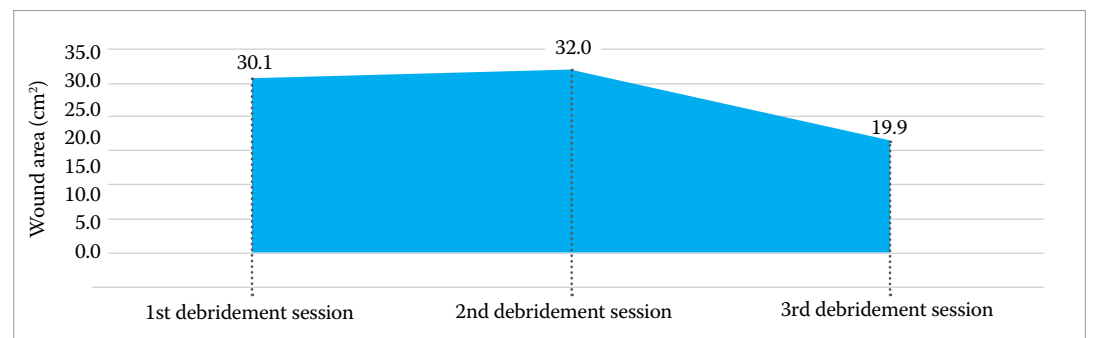


Figure 4. Mean wound area during the clinical evaluation using Alprep Pad

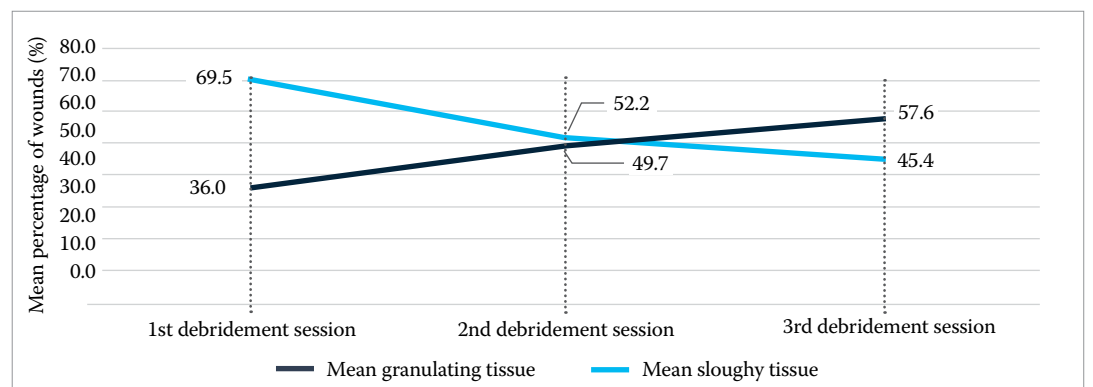


Figure 5. Mean proportion of tissue type during the clinical evaluation using Alprep Pad

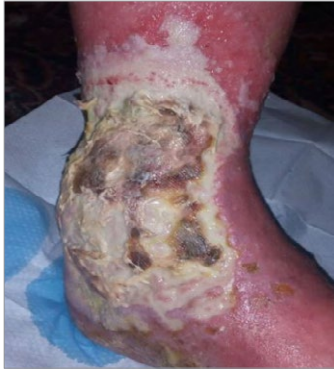

Figure 6. First debridement session

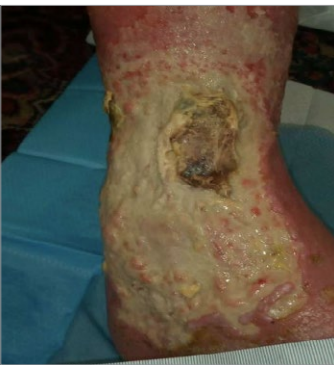

Figure 7. Second debridement session

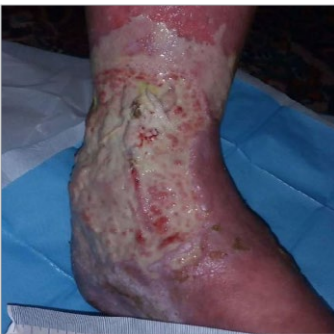

Figure 8. Third debridement session

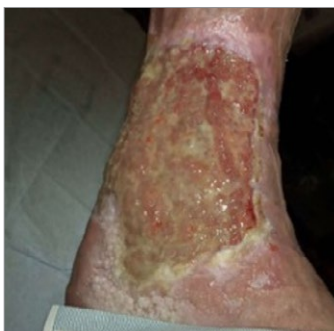

Figure 9. Progress after 1 month of treatment

the debridement sessions and there was a visible effect of cleansing and debriding with Alprep Pad within 1 minute of the procedure in 89% of cases ($n=136$). Additionally, healthcare professionals confirmed that in 87% ($n=124$) of debridement sessions Alprep Pad left newly formed granulation tissue completely (50%), or to some extent (37%), undamaged; the debridement tool was perceived as very gentle in most of the wound evaluations. All stated that they would use the product in the future and recommend to peers as a time-effective solution.

ALPREP PAD CASE REPORTS

Two detailed case reports from the clinical evaluation are presented below where we used Alprep Pad for cleansing and debridement of wounds requiring WP at the Bridgewater Community Healthcare NHS Foundation Trust.

Patient 1

A 79-year-old female presented with a 1-month-old venous leg ulcer of mixed aetiology on the left inner leg and forefoot. The wound on the inner leg measured 160mm (length) x 120mm (width), with no depth. It comprised 100% slough, with maceration visible at the wound edges and on the surrounding skin. The wound was showing signs of infection (oedema and malodour) and biofilm was suspected. Heavy purulent exudate was present, and the patient rated her wound pain at 9 out of 10 on a visual analogue scale (VAS; 1=no pain, 10=extreme pain).

Cleansing and debridement were carried out to disrupt suspected biofilm and to loosen and remove non-viable tissue; after debridement up to 20% was removed (Figure 6). The patient reported experiencing much less pain during debridement with Alprep Pad compared to their usual debridement method – a monofilament debridement pad. The time taken to cleanse and debride was also considerably less than with the usual method used on this type and size of wound.

Prior to the second debridement session, the wound measured 160mm (length) x 120mm (width) x 1mm (depth) and comprised 95% slough and 5% granulation tissue. Maceration was visible at the wound edges and skin scales were present on the surrounding skin. There was also moderate

purulent exudate production and malodour. The patient rated their wound pain at 7 out of 10 (VAS scale). Cleansing and debridement were required to remove slough; after debridement between 20–50% was removed (Figure 7). The patient commented that pain was still significantly less, and time spent cleansing and debriding had reduced.

Wound assessment prior to the third debridement session showed that ulcer size had reduced; the wound now measured: 150mm (length) x 110mm (width) x 1mm (depth). The patient rated wound pain at 6 out of 10 (VAS scale). The wound comprised 90% slough and 10% granulation tissue, with moderate purulent exudate present. The wound edge was normal with some maceration and skin scales were visible on the surrounding skin. Cleansing and debridement were needed to reduce slough further and, again, required less time than with the usual debridement solution used in this practice.

Figure 8 shows the wound after the third debridement session, where a further 20–50% of non-viable tissue and slough was removed. The patient was pleased with treatment and wound progress; Figure 9 shows the wound after 1 month of treatment, which included cleansing and debridement with Alprep Pad.

Patient 2

A 72-year-old male presented with a 3-month-old venous leg ulcer of mixed aetiology that had ulcerated previously. The wound measured 190mm (length) x 110mm (width) x 4mm (depth) and the patient rated their wound pain at 8 out of 10 on a VAS scale (1=no pain, 10=extreme pain). The wound bed comprised 80% slough and 20% granulation tissue, and the presence of oedema and malodour indicated infection. The wound edge was macerated, and skin scales were visible on the surrounding skin. The patient had previously endured other debridement pads but was unable to tolerate them. Treatment with Alprep Pad was agreed as his wife was also on the caseload and had coped well with the tool, despite having a low pain tolerance. After the first debridement session, between 20–50% of non-viable tissue and slough was removed (Figure 10). It took 4–7 minutes to complete and compared to the usual debridement method, Alprep Pad caused

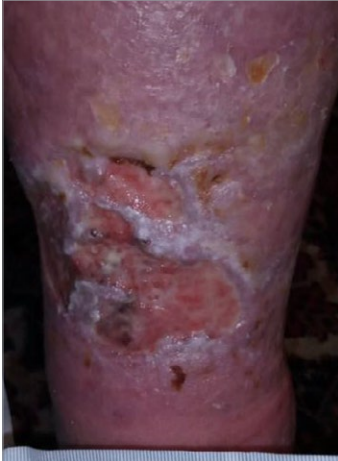

Figure 10. First debridement session

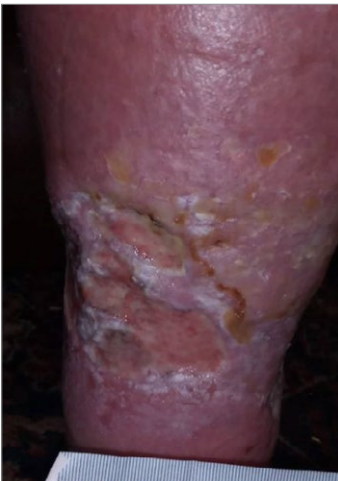

Figure 11. Second debridement session

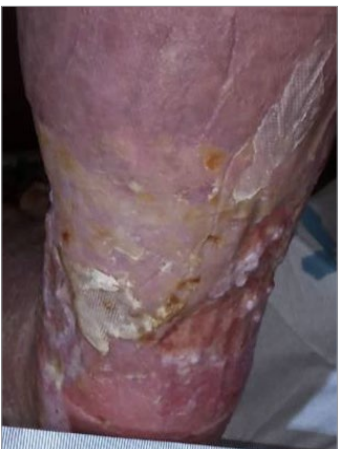

Figure 12. Third debridement session

less pain.

Prior to the second debridement session, the wound measured 185mm (length) x 110mm (width) x 4mm (depth) and comprised 80% slough and 20% granulation tissue. Maceration was visible at the wound edges and skin scales were present on the surrounding skin. There was also moderate clear exudate production and malodour. The patient was pleased with the reduction in his pain levels (7 out of 10 on a VAS scale) during debridement compared to the usual debridement method. Cleansing and debridement removed between 20–50% of non-viable tissue and slough after the second debridement session (Figure 11); emollients were removed before using Alprep Pad. Time spent debriding was much less compared to the usual method used on this type and size of wound. After the third debridement session, a further 20–50% of non-viable tissue and slough was removed (Figure 12) and the wound bed was much improved.

Summary

After the final debridement session for both patients, Alprep Pad was rated a 'very effective' cleansing and debridement tool. The product was gentle, very easy and convenient to use, and provided a time-effective solution. At every debridement session, one debridement pad was used; a visible effect could be seen within 1 minute and newly formed granulation tissue was left undamaged. Pain caused by Alprep Pad during all debridement sessions was rated moderate; the patients had received analgesia prior to use.

WP was easy to complete and assessment of the wound was facilitated after cleansing and debridement, and the product helped to reduce concerns about causing harm. Exudate and non-viable tissue were effectively absorbed and incorporated into the product. Based on these case studies, we would use Alprep Pad again, and would recommend the product to our peers.

CONCLUSION

Importantly, effective debridement can lead to improved patient care, faster wound healing, and increased capacity (Wounds UK, 2013). Alprep Pad has been designed to cleanse and debride the wound bed, wound edge and periwound skin in a wide range of wounds. The tool can help

to establish a healthy wound bed, aid removal of slough, non-viable tissue, biofilms, and skin scales, including hyperkeratotic scales, to support optimal WP. The triangular shape and ergonomic grip provides increased control and comfort to clinicians when handling the tool. Use of this new 2-in-1 debridement tool in practice may help to simplify WP for all clinicians.

WUK

REFERENCES

Anghel EL, DeFazio MV, Barker JC (2016) Current Concepts in Debridement: Science and Strategies. *Plast Reconstr Surg* 138(3 Suppl): 825–935

Callaghan R, Stephen-Haynes J (2012) Changing the Face of Debridement in Pressure Ulcers. Poster presentation. 15th Annual European Pressure Ulcer Advisory Panel Conference, Cardiff: 19–21 September

Davies CE, Woolfrey G, Hogg N et al (2015) Maggots as a wound debridement agent for chronic venous leg ulcers under graduated compression bandages: a randomised controlled trial. *Phlebology* 30(10):693–9

Dowsett C, von Hallern B (2017) The Triangle of Wound Assessment: a holistic framework from wound assessment to management goals and treatments. *Wounds International* 8(4):34–9

Falanga V (2004) Wound Bed Preparation in Practice. EWMA Position Document. London: Med. Ed. Partnership Ltd

Granick MS, Jacoby M, Noruthrum S, et al (2006) Clinical and economic impact of hydrosurgical debridement on chronic wounds. *Wounds* 18(2): 35–9

Gray D, White R, Cooper P, Kingsley A (2005) Applied wound management. in: wound healing: a systematic approach to advanced wound healing and management. *Wounds UK*, Aberdeen: 59–96

Gray D, Acton C, Chadwick P et al (2011) Consensus guidance for the use of debridement techniques in the UK. *Wounds UK* 7(1):77–84

Leaper D (2002) Sharp technique for wound debridement. *World Wide Wounds*. <http://www.worldwidewounds.com/2002/december/Leaper/Sharp-Debridement.html> (accessed 23.06.2021)

LeBlanc K, Beeckman D, Campbell K et al (2021) Best practice recommendations for prevention and management of periwound skin complications. *Wounds International*. www.woundsinternational.com (accessed 23.06.2021)

Percival SL, Suleman L (2015) Slough and biofilm: removal of barriers to wound healing by desloughing. *J Wound Care* 24(11):498,510

Price B, Young T (2013) Debridement consensus: recommendations for practice. *Wound Essentials* 8(1):71–76

Rodeheaver GT, Ratliff CR (2018) Wound cleansing, wound irrigation, wound disinfection. In: Krasner DL, van Rijswijk L (eds) *Chronic Wound Care: The Essentials e-Book*. HMP: Malvern, PA: 47–62

Schultz GS, Sibbald RG, Falanga V et al (2003) Wound bed preparation: a systematic approach to wound management. *Wound Repair Regen* 11:1–28

Strohler R, Dissemmond J, Jordan O'Brien J et al (2013) An updated overview and clarification of the principle role of debridement. *J Wound Care* 22: S1–S52

Vowden P (2011) Hard-to-heal wounds Made Easy. *Wounds International*. <https://www.woundsinternational.com/uploads/resources/8b209a588e74f81cc9dda6ed140a3c85.pdf> (accessed 23.06.2021)

Vowden P, Vowden K (2011) Debridement Made Easy. *Wounds UK* 7(4). <http://www.woundsuk.co.uk/madeeasy/debridement-made-easy> (accessed 23.06.2021)

Weir D, Swanson T (2019) Ten top tips: wound cleansing. *Wounds International* 10(4):8–11

Wilcox JR, Carter MJ, Covington S (2013) Frequency of Debridements and Time to Heal: A Retrospective Cohort Study of 312 744 Wounds. *JAMA Dermatology* 149(9):1050–8

Wounds UK (2013) Effective debridement in a changing NHS: a UK consensus. London: *Wounds UK*. www.wounds-uk.com (accessed 23.06.2021)