

Experiences of healthcare professionals using Prontosan® Debridement Pad

KEY WORDS

- ▶ Debridement
- ▶ Prontosan® Debridement Pad
- ▶ Wound bed preparation

Wound bed preparation (WBP) often incorporates debridement, which removes debris, slough and, importantly, biofilm from the wound bed, to facilitate healing. The Prontosan® Debridement Pad (B. Braun) is a microfibre mechanical debridement pad with a uniquely tapered design, facilitating access into awkward and hard-to-reach wounds. Fifty-six healthcare professionals (HCPs) from a range of settings reported their experience using the Prontosan Debridement Pad via a feedback questionnaire. During the response period, 111 responses were completed by these 56 HCPs. Over 90% of the questionnaires scored the pad as ‘good’ or ‘excellent’ for overall usability and debridement action. The majority of the questionnaire responses (87%) found accessing all areas of a wound ‘easy’ or ‘very easy’ when using the Prontosan Debridement Pad. Irrespective of wound type, over 95% of the responses completed by the HCPs perceived that patient comfort whilst using the pad was ‘as expected’ or ‘better than expected’. The unique tapered end of the Prontosan Debridement Pad was used in the majority of wounds (60%; n=46/77). Finally, results revealed that, in the HCPs’ opinion, the pad was preferred over other available debridement products in the UK.

It is well recognised that wound bed preparation (WBP) is required for the optimal treatment of chronic wounds (Harries et al, 2016). WBP involves the reduction of debris and bioburden from a wound bed via the removal of devitalised tissue, slough and exudate (Harries et al, 2016). Newer consensus terminology, such as ‘wound hygiene’, incorporates WBP principles and recommends early intervention strategies to promote wound healing (Murphy et al, 2020). It is widely acknowledged that over 90% of chronic wounds contain a biofilm and that all open wounds should be treated as containing biofilm (Attinger and Wolcott, 2012; Murphy et al, 2020). Devitalised tissue and slough are frequently present in chronic wounds and are associated with the presence of biofilm (Percival and Suleman, 2015). The impact of chronic wounds on the NHS, and in particular within the community setting, is well documented (Guest et al, 2017; 2020).

Consensus defines wound cleansing and debridement as separate treatment stages (Murphy et al, 2020). Cleansing of the wound bed aims to

loosen devitalised tissue, debris and biofilm, which is often performed as a soak or irrigation, and the use of surfactant-containing cleansers encouraged (Murphy et al, 2020). Debridement follows cleansing, facilitating the removal of non-viable tissue, biofilm, slough and exudate, which would otherwise impede healing (Steed et al, 1996; Williams et al, 2005; Ousey and McIntosh, 2010; Wolcott, 2015). For chronic wounds, more than one method of debridement may be required and debridement may be repeated over a number of weeks (Bentley et al, 2005). Debridement methods range from enzymatic and autolytic processes through to physical processes via mechanical or surgical debridement. However, it is only mechanical debridement that allows for physical debridement of chronic wounds without the need for specialist knowledge (Irving et al, 2018). Ultimately, mechanical debridement has the benefit of removing non-viable tissue quickly, hence it is often an attractive option for both the patient and the healthcare professional (HCP). Once the wound is debrided, the use of surfactant-containing gels

LUXMI DHOONMOON
Nurse Consultant Tissue
Viability, Central and
North West London NHS
Foundation Trust

continue WBP between dressing changes, while secondary dressings are selected depending on treatment objectives (Irving et al, 2018).

The Prontosan® Debridement Pad (B. Braun; ‘the pad’) is a mechanical debridement pad composed of soft and flexible microfibres (Figure 1). Each microfibre is approximately 1% of the diameter of a human hair and has a split fibre design that generates multiple strands per fibre. This novel design not only results in the pad containing many cleansing fibres per surface area, but also allows the pad to remove and retain particles of debris within the fibre structure, effectively trapping debris between its strands (Irving et al, 2018). The pad’s unique tapered design provides effective debridement even in awkward or hard-to-reach areas, e.g. inside wound cavities and around undermined wound edges. The larger, rounded, end of the pad is suitable for large wound surfaces, such as leg ulcers or lower limb hyperkeratotic plaques. As a result of the pad’s unique features, HCPs are reporting positive treatment outcomes in a variety of hard-to-heal wounds (Ovens and Irving, 2018).

AIM

The purpose of this feedback was to evaluate HCP experience of the Prontosan Debridement Pad in a day-to-day clinical setting.

MATERIALS AND METHODS

During 2018–2019, feedback questionnaires were provided to community and acute-based HCPs across a broad range of specialities, including leg ulcer clinic staff, podiatrists, practice nurses and TVNs in the NHS. The HCPs were asked

to complete the questionnaire after using the Prontosan Debridement Pad for wound debridement. Data provided by HCPs included wound size and condition, previous wound debridement, use of cleansing/soaks, technique and method of use of the pad during debridement. HCPs were asked to assess and record their perception of patient comfort during debridement using a 3-point scale (‘less comfortable than expected’, ‘as expected’ or ‘more comfortable than expected’). Comparison of the pad to other products was explored by asking them to compare their current experience with the pad against their experience using other debridement products on a 5-point score (‘much better’, ‘slightly better’, ‘about the same’, ‘slightly worse’, or ‘much worse’). Finally, a 5-point Likert scale (‘poor’, ‘average’, ‘good’, ‘very good’ or ‘excellent’) was used to assess HCP perception of the pad’s overall rating, debridement action, ease in accessing the wound and the ability to remove slough.

RESULTS

A total of 111 questionnaires representing 111 patients were completed by 56 HCPs. The average number of returned questionnaires per HCP was two, with the maximum being nine. Only one questionnaire was excluded due to the pad not being used on a patient. Questions that were unanswered or were recorded by the HCP as being not applicable were excluded from individual analysis.

Debridement with the pad

The overall rating of the pad, its ability to remove slough and debris, and its debridement action were rated as good, very good or excellent in the majority of questionnaires (92%, 88% and 92% respectively (Figures 2a-c). The pad’s ability to access all areas of the wound was reported as easy or very easy in 87% of responses (n=80/92; Figure 2d). The HCPs’ perception of patient comfort was reported as being ‘more comfortable than expected’ in 49% (n=50/103) of responses, ‘as expected’ in 47% of cases (n=48/103) and ‘less comfortable than expected’ in 4% (n=5/103) of cases (Figure 2e).

Impact of different wound types

The pad was used for debriding a variety of common wound types including fibrinous/sloughy and granulating wounds; moist and fibrinous/




Figure 1. Prontosan Debridement Pad (B. Braun)

sloughy wounds; dry and fibrinous wounds; and granulating wounds. These wounds comprised 80% of the total number of wounds included in the questionnaire. On average, across all common wound types, 90% of the pad's debridement action was rated as either 'good' or 'excellent' (Figure 3a). The pad appeared to perform equally well

regardless of wound type. The HCPs' perception of patient comfort was also scored positively by the majority of HCPs across a number of different wound types. Specifically, 95% of cases reported the patient's perceived comfort was either 'expected' (54%; n=48) or 'better than expected' (41%; n=36) (Figure 3b).

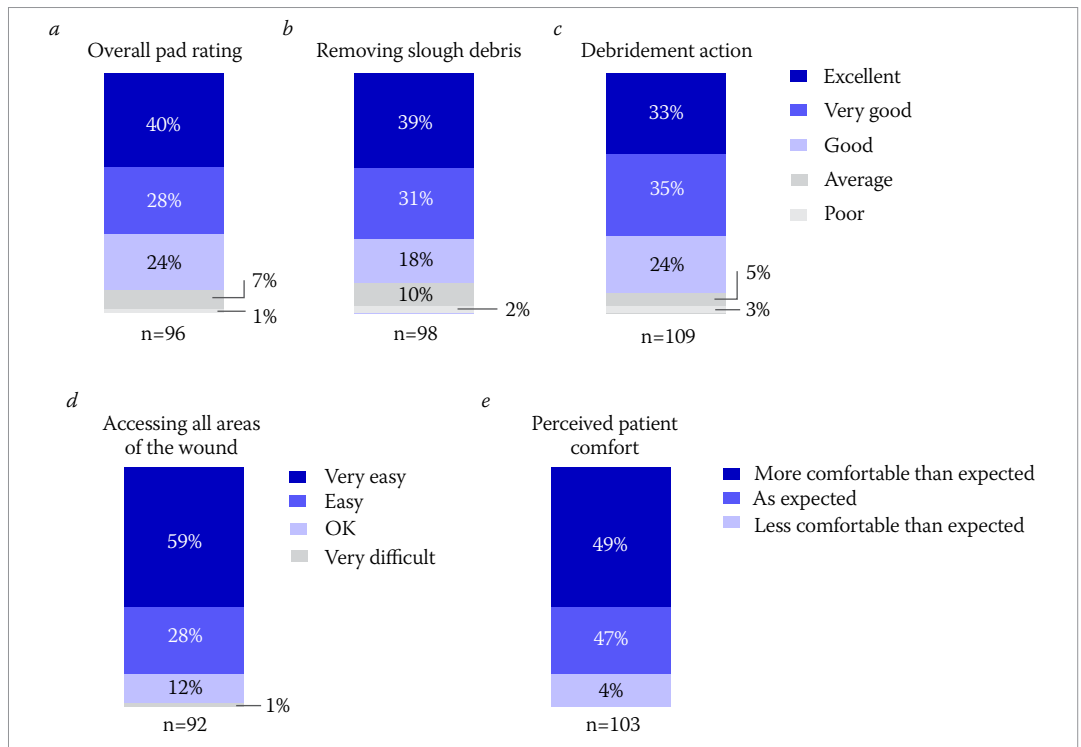


Figure 2. HCP opinion of Prontosan Debridement Pad on factors related to debridement

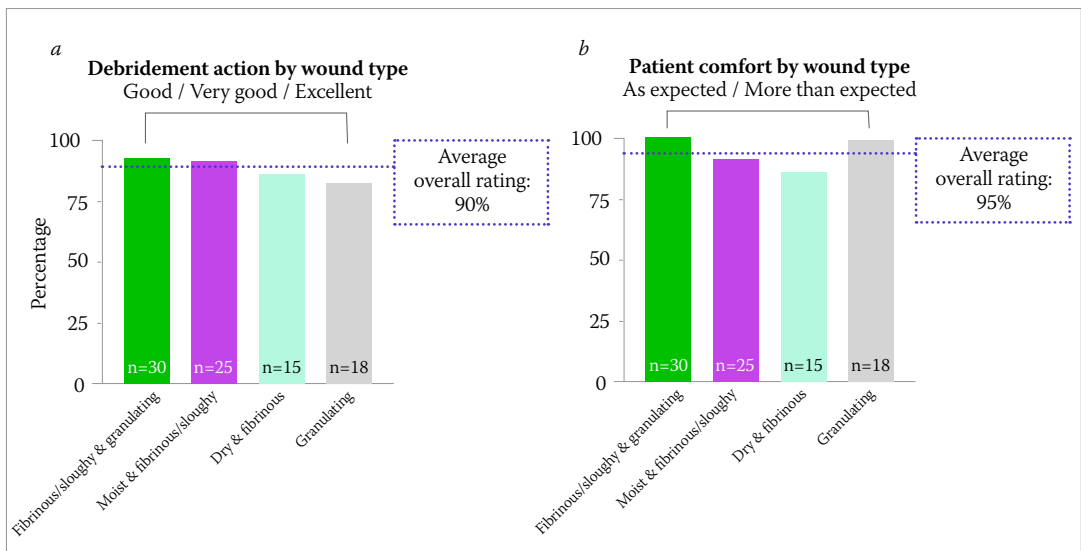


Figure 3. HCP perception of the (a) debridement action and (b) patient comfort of Prontosan Debridement Pad across a range of wound types

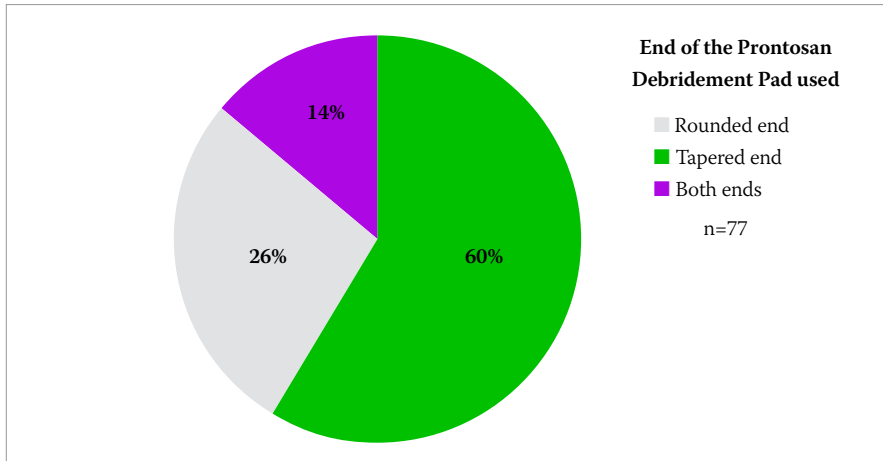


Figure 4. Ends of the Prontosan Debridement Pad used.

Use of tapered end of the pad

Overall, 77 questionnaires stated which end of the pad was used. In 60% of these cases, the HCP specified they had used the tapered end of the pad; in 26% of the cases, respondents stated they had used the rounded end; and in 14% of cases, the respondents stated they had used both ends (Figure 4).

The effect of pre-soaking

Wounds either had a pre-soak (n=69) or did not have a pre-soak (n=29) before debridement. For wounds that were pre-soaked, 66% had a soak time of between 5 and 10 minutes. The remaining 34% of wounds either did not specify a time or recorded

soak time as either 12 (n=2), 15 (n=3) or 20 (n=1) minutes in length.

When wounds received a pre-soak, the pad's ability to remove slough from the wound was scored higher than when the wound had not received a pre-soak. Among cases that had been pre-soaked, 94% of cases were scored as good or better (Figure 5a). In contrast, among cases where the wound had not been pre-soaked, only 72% were scored as good or better and there was a higher proportion of cases that scored average or poor (Figure 5b).

HCPs perception compared to previous mechanical debridement products

Of the 110 responses, 68 stated previous experience with other mechanical debridement products; 91% of responses rated the Prontosan Debridement Pad as 'better than' or 'about the same' as other available products (63% and 28%, respectively). Of these 68, 49 responses had used an alternative debridement pad: 29 (59%) stated that, in their opinion, the Prontosan Debridement Pad performed 'much or slightly better', 14 (29%) thought it performed 'about the same', 5 (10%) perceived it as 'slightly worse' and 1 (2%) clinician thought it was 'much worse'. Nineteen responses had previous experience with a cloth: 74% of these responses thought that the Prontosan Debridement Pad performed 'much or slightly better', and 26% thought the pad performed about the same as the cloth.

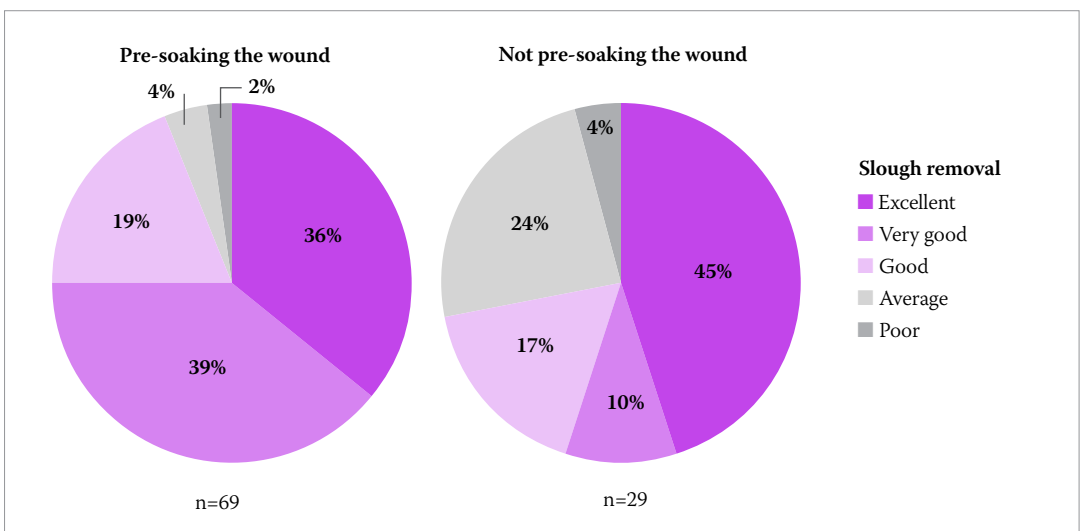


Figure 5. HCPs' opinion of pre-soaking and not pre-soaking on slough removal using Prontosan Debridement Pad.

The Prontosan Debridement Pad can be used on wounds that have been either pre-soaked with solution or not (Ovens and Irving, 2018). The HCPs' perception of the pad compared to other debridement products was not affected by whether the wound was pre-soaked or not. In total, 66% (n=43) of responses who pre-soaked the wound and 64% (n=14) of responses who did not pre-soak the wound rated the pad as 'much better' or 'slightly better' than previously used debridement products.

DISCUSSION

Debridement is an important step in WBP as the removal of wound debris, slough and biofilm are all linked to better healing outcomes (Milne, 2015). It is, therefore, important that any debridement product is not only effective but also easy to use by clinicians. The Prontosan Debridement Pad was well-received in this feedback as the majority of the completed questionnaires reported the pad was 'good' to 'excellent' for all parameters. This shows that it can effectively support WBP and, therefore, can support wound healing. Patient comfort is important to achieve good patient outcomes and wound healing, since any delay in debridement can lead to increased risk of infection and other complications of non-healing (Young, 2011). HCPs perceived that patients tolerated the pad's use well, with the majority (95%) of responses reporting an expected or better than expected comfort level.

At the time of writing, Prontosan Debridement Pad has a unique product design (NHS Drug Tariff, 2021) of a tapered shape, and the thinness of the pad facilitates access to deep wound cavities and undermined wound edges. Interestingly, clinicians have anecdotally reported that rolling and folding the pad helped to access the wound bed, particularly for deep cavities and the area between the toes. When the clinician reported which end of the pad was used to debride the wound, the pad's tapered end was used for 60% of cases (Figure 4). This could suggest that a substantial number of wounds may require a tapered shape or a thinner pad for effective debridement and slough removal.

Mechanical debridement is an option, if indicated, which can follow a cleansing procedure, such as a pre-soak. Pre-soaking improved the effectiveness of slough removal during debridement

(Murphy et al, 2020). In this feedback, it was reported that the majority of wounds that were pre-soaked were soaked for between 5 and 10 minutes (66%), this is in line with recommended contact times for sloughy wounds (Collier and Hofer, 2017). Based on this result, a pre-soak prior to mechanical debridement enhances the effectiveness of debridement, and is in line with current recommendations that debridement follows cleansing (Murphy et al, 2020).

In the questionnaires, HCPs reported a general preference for the Prontosan Debridement Pad to previous experiences with other mechanical debridement products. Comments included in the questionnaire about the Prontosan Debridement Pad included: *'having better than expected desloughing capability'*, *'being well tolerated by patients'* and *'providing a good level of debridement action over a short space of time'*.

CONCLUSION

As the Prontosan Debridement Pad is non-adherent and flexible, it allows for non-traumatic mechanical wound debridement. Based on the feedback from 56 HCPs across multiple wound care settings, this feedback revealed that the pad provided highly effective debridement across a range of wound types. Results also show how HCPs perceived the patient comfort as acceptable. It should be acknowledged that 'old-fashioned' gauze mechanical debridement exists outside of the UK. The mechanical debridement action of Prontosan Debridement Pad ensures removal of non-viable tissues only, with no risk of healthy tissue being removed simultaneously.

In this author's experience, where previously staff may have shied away from the process of debridement and leaving it to the specialist team only, it is very encouraging to see general staff using the Prontosan Debridement Pad with an objective to improve wound healing in patients with chronic wounds in the community. It can be used safely in the community and across all clinical settings, so that clinicians can confidently remove the devitalised tissue from the wound bed, leaving healthy tissue intact, without causing pain and trauma to the patient. *Box 1* presents a case study that shows that facilitating the fundamental elements of WBP – principally, cleansing and

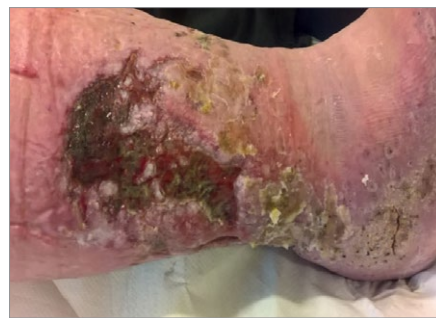Box 1. Case study: Wound bed preparation incorporating Prontosan Debridement Pad (Kramer et al, 2018; case study courtesy of Luxmi Dhoomood)

This lower limb ulcer had been present for 3 years and had been static for months. Due to the patient's pain levels, debridement was not always possible or successful. Exudate levels were causing frequent strikethrough and odour was a significant problem. Dressing changes were 2-3 times per week.

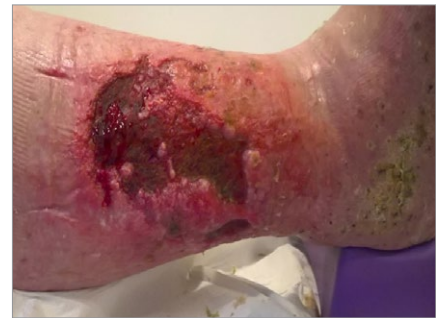Prontosan Solution was used in conjunction with the Prontosan Debridement Pad. The wound had two treatments with Prontosan Debridement Pad with significant improvement in the wound bed noted due to decreased devitalised tissue and slough.

Dressing changes were reduced to once per week. The patient's pain and odour issues improved, and the patient was more comfortable wearing their compression garments. The patient's mobility also benefited and they were able to increase their level of exercise, which had a positive effect on their overall health.

Debridement and effective wound bed preparation, which kickstarted wound healing, had a positive effect on the patient's general health and quality of life.



Wound pre-debridement with Prontosan Debridement Pad



Wound post-debridement with Prontosan Debridement Pad

debridement — can improve outcomes and have a positive effect upon patient wellbeing and quality of life (Kramer et al, 2018).

Prontosan Debridement Pad has been available in the UK since February 2018, and this feedback shows that the pad is an acceptable form of debridement among clinicians and can be incorporated into local WBP and anti-biofilm strategies. WUK

REFERENCES

Attinger C, Wolcott R (2012) Clinically addressing biofilm in chronic wounds. *Adv Wound Care* 1(3):127–32. <https://doi.org/10.1089/wound.2011.0333>.

Bentley J, Bishai P, Foster A et al (2005) Clinical competence in sharp debridement: an innovative course. *Br J Community Nurs* 10(3):S6–13. <https://doi.org/10.12968/bjcn.2005.10.Sup1.17624>

Collier M, Hofer P (2017) Taking wound cleansing seriously to minimise risk. *Wounds UK* 13:58–64 <https://bit.ly/303OWr7>

Guest JF, Ayoub N, McIlwraith T et al (2017) Health economic burden that different wound types impose on the UK's National Health Service. *Int Wound J* 14(2):322–30. <https://doi.org/10.1111/iwj.12603>

Guest JF, Fuller GW, Vowden P (2020) Cohort study evaluating the burden of wounds to the UK's National Health Service in 2017/2018: update from 2012/2013. *BMJ Open* 10(12):e045253. <https://doi.org/10.1136/bmjopen-2020-045253>

Harries RL, Bosanquet DC, Harding KC (2016) Wound bed preparation: TIME for an update. *Int Wound J* 13(S3): 8–14. <https://doi.org/10.1111/iwj.12662>

Irving S, Owens L, Collier M (2018) Prontosan Debridement Pad: made

easy. *Wounds International*, London. <https://bit.ly/2MEINjh>

Kramer A, Stryja J, Haeni T et al (2018) Remove barriers to healing: Focus on wound bed preparation. *Wounds International* 9(1):44–7. <https://bit.ly/3sPe7dr>

Milne J (2015) Wound-bed preparation: the importance of rapid and effective desloughing to promote healing. *Br J Nurs* 24 Suppl 20:S52–8. <https://doi.org/10.12968/bjon.2015.24.Sup20.S52>

Murphy, Atkin L, Swanson T et al (2020) Defying hard-to-heal wounds with an early antibiofilm intervention strategy: wound hygiene. *J Wound Care* 29(Sup3b):S1–S26. <https://doi.org/10.12968/jowc.2020.29.Sup3b.S1>

NHS Electronic Drug Tariff. Jan 2021

Ousey K, McIntosh C (2010) Understanding wound bed preparation and wound debridement. *Br J Community Nurs* 15(3):S22–6. <https://doi.org/10.12968/bjcn.2010.15.Sup12.S22>

Ovens L, Irving S (2018) Advances in wound cleansing: an integrated approach. *Wounds UK* 14(1):58–63. <https://bit.ly/3r8mMHx>

Percival SL, Suleman L (2015) Slough and biofilm: removal of barriers to wound healing by desloughing. *J Wound Care* 24(11):498–510. <https://doi.org/10.12968/jowc.2015.24.11.498>

Steed DL, Donohoe D, Webster MW et al (1996) Effect of extensive debridement and treatment on the healing of diabetic foot ulcers. Diabetic Ulcer Study Group. *J Am Coll Surg* 183(1):61–4

Williams D, Enoch S, Miller D et al (2005) Effect of sharp debridement using curette on recalcitrant nonhealing venous leg ulcers: a concurrently controlled, prospective cohort study. *Wound Repair Regen* 13(2):131–7. <https://doi.org/10.1111/j.1067-1927.2005.130203.x>

Wolcott R (2015) Economic aspects of biofilm-based wound care in diabetic foot ulcers. *J Wound Care* 24(5):189 <https://doi.org/10.12968/jowc.2015.24.5.189>

Young T (2011) Reviewing best practice in wound debridement. *Pract Nurs* 22(9):488–92

DECLARATION OF INTEREST:

Prontosan Debridement Pad were supplied free of charge by B. Braun. This article is sponsored by B. Braun.