

Advances in wound cleansing: an integrated approach

This article is based on a symposium held at the Wounds UK annual conference in Harrogate, UK, on 13th November 2017. The aim of the symposium was to provide practical information on how new principles in cleansing and debridement technology can help to improve wound bed preparation and resulting patient outcomes. The symposium consisted of presentations by two speakers: Liz Ovens (Independent Tissue Viability Specialist Nurse), who explained the importance of wound bed preparation in dealing with biofilms, and the role of debridement and topical irrigation and gel; and Sally Irving (Independent Tissue Viability Nurse Consultant) presented case studies using a novel soft debridement pad.

THE IMPORTANCE OF WOUND BED PREPARATION

In wound care, it is important to remember that 'preparation is the key to success'. Cleansing has been proven to affect outcomes, improving healing rates and saving the NHS money. Wound bed preparation (WBP) has been defined as management of the wound, in order to accelerate healing and facilitate the effectiveness of other therapeutic measures (Dowsett and Newton, 2005).

The TIMES principles (Wounds UK, 2017) provide a useful framework for the foundations of WBP in practice:

- ▶ **T** Tissue
- ▶ **I** Infection
- ▶ **M** Moisture balance
- ▶ **E** Edge of the wound/epithelial cell migration
- ▶ **S** Surrounding skin

As such, the components of a WBP regimen should be:

- ▶ Wound cleansing
- ▶ Debridement
- ▶ Management of infection and inflammation
- ▶ Measures to facilitate moist wound healing (Wounds UK, 2017).

Within the symposium, the focus was on cleansing and debridement, and how using

new technology to optimise the process could facilitate improved WBP and thus improve overall patient outcomes.

BIOFILM MANAGEMENT

One of the key objectives of WBP should be to manage biofilm, particularly in chronic wounds: a recent study demonstrated that up to 90% of chronic wounds have biofilm present (Malone et al, 2017) and are a major cause of pain, discomfort and poor healing of wounds for patients. The cycle of biofilm formation (*Figure 1*) means that free-floating bacteria multiply and quickly become attached to a suitable surface; if allowed to develop, they will become more firmly attached and become increasingly resistant to antibiotics, antiseptics and disinfectants. However, the initial attachment is reversible and the cycle needs to be disrupted as quickly as possible in order to prevent the biofilm cycle continuing and biofilm reforming (Wolcott et al, 2008).

While biofilm is made up of microscopic bacteria and is not visible to the eye, there are signs that can indicate biofilm may be present and should be suspected, such as a slimy wound surface, and a painful chronically infected wound. In such wounds, early intervention and effective initial WBP measures are key.

FOCUS ON CLEANSING

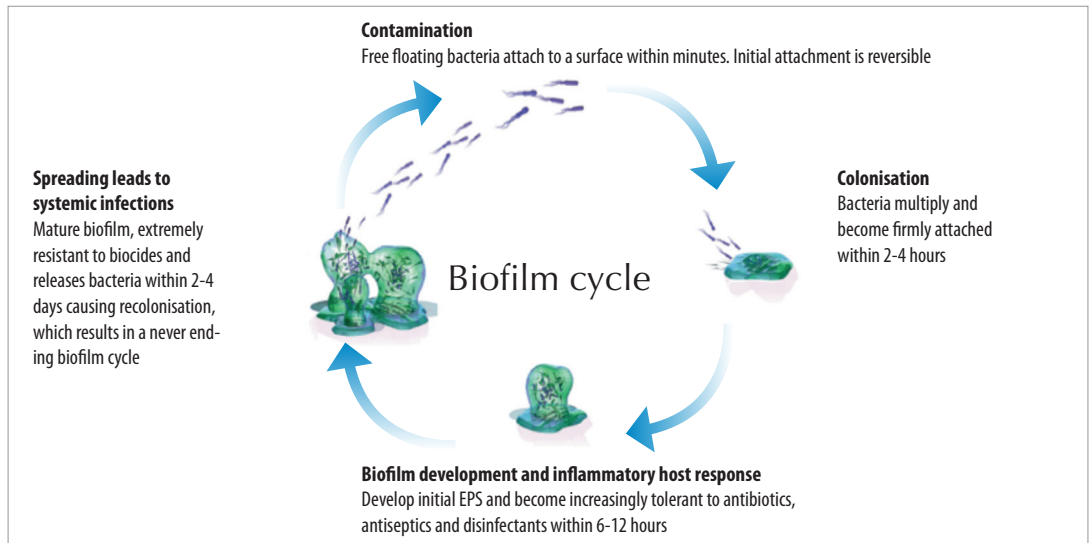
Cleansing should be the first step in any WBP regimen. The definition of wound cleansing is to: 'remove contaminants from surface including debris, slough, softened necrosis, microbes, remnants of previous dressing, from both the surface of the wound and its surrounding skin' (Wolcott and Fletcher, 2014).

Traditionally, water and saline have been used as cleansing agents, but it is now recognised that they may not actively promote healing of chronic wounds, particularly those where biofilm is present. Other solutions such as Povidone iodine and peroxide can be toxic, and a Cochrane review (2012) suggested that such solutions do little to

LIZ OVENS
*Independent Tissue Viability
Specialist Nurse*

SALLY IRVING
*Independent Tissue Viability
Nurse Consultant*

Figure 1. The biofilm cycle



Advantages	Prontosan®	Saline	Water	Antiseptic
Reduction in bioburden	✓	✗	✗	✓
Safe for long term use	✓	✓	✓	✗
No inhibition of granulation tissue	✓	✓	✓	✗
Clinical evidence in reduction of pain and odour	✓	✗	✗	✗
Can be used up to 8 weeks after opening – cost effective	✓	✗	N/A	✗
Clinical evidence in reduction of infection rates	✓	✗	✗	✓
Clinical evidence in improved healing times	✓	✗	✗	✗

control wound bacteria and may in fact interfere with host healing.

Polyhexamethylene biguanide (PHMB) is a broad spectrum antimicrobial that is effective against bacteria, viruses and fungi, which does not contribute to antimicrobial resistance. Prontosan cleanser (B Braun), contains PHMB combined with betaine, a surfactant, to lift microbes and suspend them in a solution to prevent wound recontamination. Working together, this combination has been found to provide a more effective wound cleansing solution compared to other options (Table 1).

Figure 2. The Prontosan Debridement Pad



FOCUS ON DEBRIDEMENT

Debridement is defined as ‘the process of removing necrotic or devitalized tissue, bacteria and cells that impede the healing process to reduce wound contamination and tissue destruction’ (Halim et al, 2012). The aim of debridement is to restore a viable wound base with a functional extracellular matrix. Chronic wounds are converted into acute wounds with the removal of the necrotic burden of senescent cells, the extracellular matrix, inflammatory enzymes and biofilms that contain bacterial colonies.

General methods for debridement include:

- » Surgical
- » Hydrosurgery
- » Sharp debridement
- » Autolytic
- » Enzymatic and biological methods
- » Ultrasound
- » Mechanical.

There are advantages and disadvantages to all of these methods depending on the clinical scenario.

The Prontosan Debridement Pad (B Braun) provides a new advance in mechanical debridement methods, combining microfibre

A WBP regimen incorporating cleansing and debridement in the most effective forms available is key to creating an optimal wound healing environment. In chronic or hard-to-heal wounds, biofilm is likely to be a factor, therefore should be considered in any WBP strategy. Reducing the amount of biofilm in a chronic wound may tip the balance in favour of healing; if biofilm is suspected of delaying healing of a chronic wound, it should be treated proactively by:

- Repeatedly breaking up and removing the biofilm — through vigorous/active cleansing and/or debridement
- Reducing biofilm reformation — by decreasing the number of bacteria left in the wound through the use of an antimicrobial dressing (e.g. Prontosan Gel X) left in place between each session of biofilm removal.

Prontosan Debridement Pad tips for use

- Moisten microfibre pad
- Apply gentle pressure
- Use sweeping or circular strokes

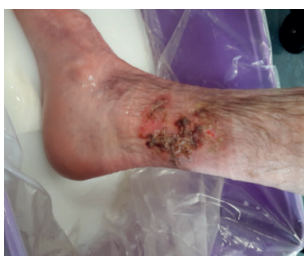

Figure 5. The wound at presentation

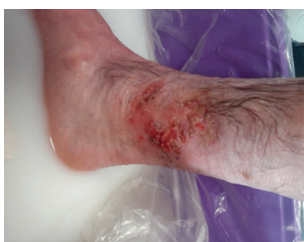

Figure 6. The wound after use of the Prontosan Debridement Pad




Figure 3. The traditional monofilament versus microfibre structure

technology with a unique teardrop shape to facilitate use in hard-to-reach areas and cavities (Figure 2).

Microfibrils are more effective at cleansing than traditional fibres, due to their size and structure: one microfibre is approximately 1/100th the diameter of a human hair, meaning that there are many more of them in the pad's surface area than in a traditional monofilament pad. Each microfibre has a split structure, producing several strands per fibre, which not only produces a greater 'lifting' effect but also allows the microfibre to retain particles of debris in the space between each strand — further increasing the surface area available for cleansing and removal of debris (Figure 3).

Additionally, microfibrils can use microscopic 'electrostatic forces' to bind to particles, further increasing their ability to lift and retain particles of slough and debris. In practical terms, this means that slough and debris will effectively be lifted from the wound bed, and removed and retained within the Prontosan Debridement Pad.

USING THE PROTOSAN DEBRIDEMENT PAD IN PRACTICE

Clinical evaluations were undertaken using the Prontosan Debridement Pad in practice. This involved 6 patients presenting to a leg ulcer clinic.

Patient 1

This was a 35-year-old male with pyoderma gangrenosum to the left lateral gaiter, following an injury sustained while playing football (Figure 5). The wound had been present for 10 months, being managed by practice nurses, with involvement from the Dermatology department. The patient was being managed with compression therapy, but found was self-conscious about the bandaging.

Several types of dressings and topical treatments had previously been used without success (various

steroid creams, alginate/hydrofibre dressings, wound contact layers, super-absorbents, iodine and silver dressings).

The patient found cleansing painful due to pyoderma, so the Prontosan Debridement Pad was suggested. The pad was immersed in a water/emollient solution and then used to gently cleanse and debride the wound, for approximately two minutes.

After the debridement pad was used (Figure 6), the debris and biofilm did not return. The patient was able to commence in compression hosiery and the wound was almost healed in a total of 6 weeks.

Patient 2

This was a 74-year-old male with a foot ulcer following a femoral artery bypass and full knee replacement, also with peripheral vascular disease. The foot ulcer had been caused by pressure from walking abnormally before the knee replacement. The wound had been present for 13 months in total, and the patient had been self-managing for 10 months. Previously the wound had been managed by practice nurses. Previous dressings used included foam dressings, alginate/hydrofibre, silicone wound contact layer, iodine and hydrogel.

The wound was very small, with dry skin around the wound edges, which needed to be removed (Figure 7). It was apparent that there was some undermining to the wound and that debridement may uncover a more significant problem. Use of forceps was unsuccessful, so sharp debridement was considered. However, the Prontosan Debridement Pad was found to be effective; the pad was folded in half to access the wound and moistened with saline, which debrided the wound effectively (Figure 8).

Patient 3

This was a 60-year-old male with bilateral venous

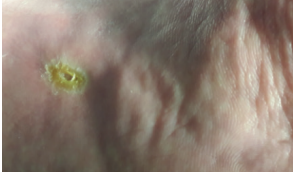

Figure 7. The wound on presentation

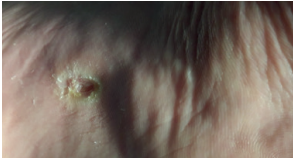


Figure 8. The wound after use of the Prontosan Debridement Pad

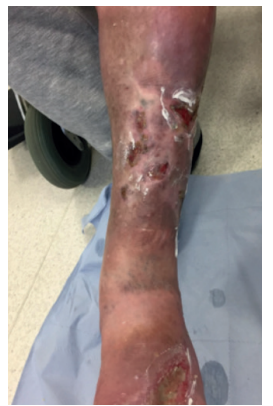
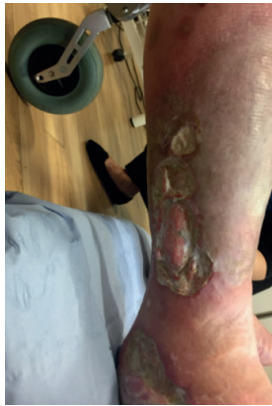
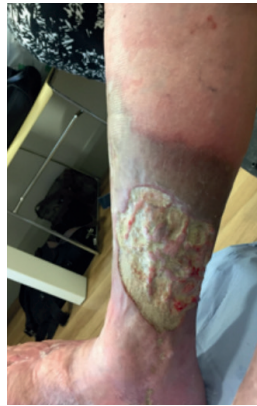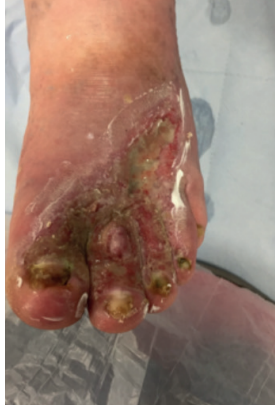Figure 9. The wounds on presentation

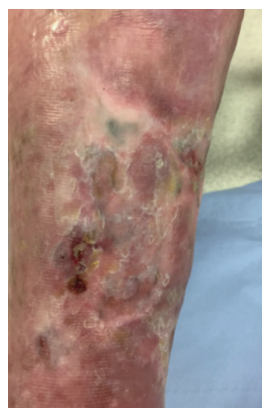
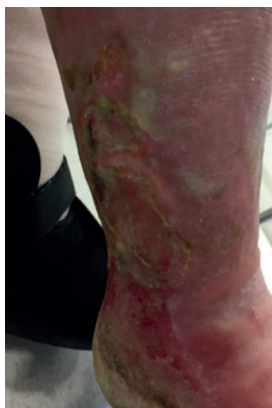
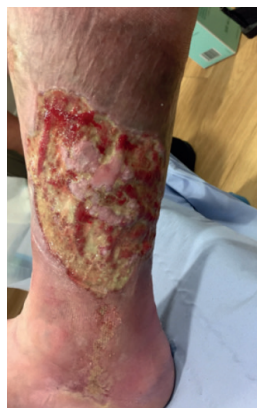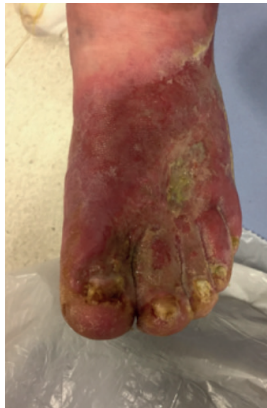Figure 10. The wounds after four weeks of treatment with the Prontosan Debridement Pad

leg ulcers (Figure 9), who also had osteoarthritis to the hip and psoriasis. These were long-standing wounds that affected the patient's quality of life; for instance, he slept in a recliner as he was unable to walk upstairs to bed. He also suffered from oedema of the feet, and psoriasis meant that he was unable to tolerate many products, due to the risk of adverse reaction. He was also unable to tolerate compression therapy. He had been visiting the Dermatology department regularly for 4 years and was also treated by practice nurses, with his wife changing dressings. Previous treatments used included foam dressings, alginates, wound contact layers, super-absorbents, silver hydrofibers/contact layers, iodine, steroid cream and flamazine. The current management plan consisted of retention bandaging with wound contact layers.

The Prontosan Debridement Pad was used weekly, folded in half to reach the area between the toes where necessary, with one pad being used on each leg. Tenacious slough was present, which meant that topical treatments would not be effective as they were unable to reach the wound bed.

After 4 weeks of weekly use of the pad, granulation tissue was forming on both legs, the quality of skin had improved and progress was made towards healing (Figure 10).

Patient 4

This was a 59-year-old male, with a wound to the lateral malleolus (Figure 11). The patient also had Type 1 diabetes mellitus, intermittent claudication, peripheral vascular disease, ischaemic heart disease, cognitive impairment and myocardial infarction. The wound had been present for 2 years, with 18 months of self-management and 6 months with practice nurses. Dressings previously used included iodine, honey, hydrogel, wound contact layers and foam dressings.

This was a small wound but was a hard-to-heal chronic wound that had failed to close. Use of the debridement pad cleared the slough and debris, allowing the dressings used to get through to the wound bed. This meant that treatment was more effective than it had been previously. The wound healed within 3 weeks (Figure 12).

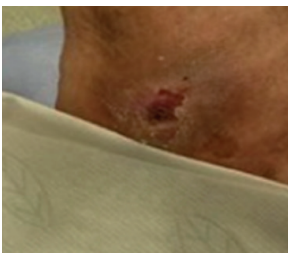

Figure 11. The wound on presentation

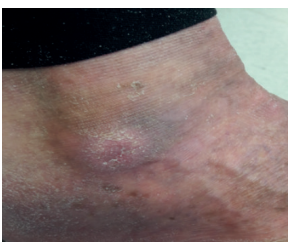


Figure 12. The wound after three weeks

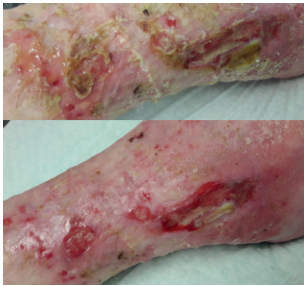


Figure 13. The wounds at presentation

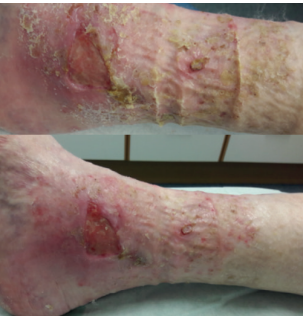

Figure 14. The wounds following use of the Prontosan Debridement Pad

Patient 5

This was an 80-year-old female with two venous leg ulcers, to the lateral and medial gaiter of the right leg (Figure 13). She also had hypertension, oesophageal varices with bleeding, myelofibrosis, and a history of basal cell carcinoma. The wound had been managed for 3 months by practice nurses in the leg ulcer clinic. Her management plan included reduced compression therapy, due to tolerance issues. Previous dressings used included hydrofibre, alginates and super-absorbents.

Previously, the wound had been regularly debrided using traditional debridement methods, which had not sufficiently debrided the wound. The Prontosan Debridement Pad was used (soaked in Prontosan solution) and there was an immediate improvement to the skin condition. The first wound continued to healing, with no slough or biofilm recurring, and no deterioration; the second wound improved, with reduced slough and improved skin condition (Figure 14).

Patient 6

This was a 70-year-old male, with a wound to the left leg lateral malleolus (Figure 15). He also had atrial fibrillation and had undergone a tracheostomy. The patient had been managed for 3 months by practice nurses in the leg ulcer clinic and was in compression bandaging. Dressings previously used included hydrofibre, alginates, hydrogels and super-absorbents. The wound had also been regularly debrided using traditional debridement methods. The patient was in optimum compression treatment, but the wound was still failing to heal.

The wound was small, but with a tough 'plug' of slough that was not clearing, so it was decided to use the Prontosan Debridement Pad. The pad was soaked and just used for around 30 seconds. This immediately cleared the slough and kickstarted healing, which allowed the dressings used to have a beneficial effect (Figure 16). The wound went on to heal within 3 weeks.

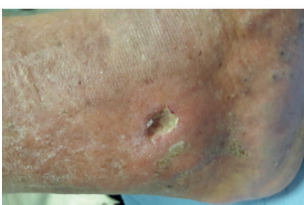

Figure 15. The wound at presentation

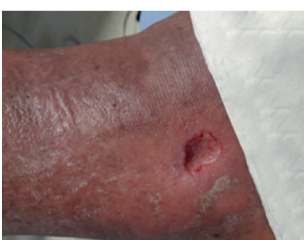

Figure 16. The wound following use of the Prontosan Debridement Pad

SUMMARY

The shape and the low profile of the Prontosan Debridement Pad meant that it was effective to use in all of the types of wounds observed in the case studies, including those in hard-to-reach areas. The edge-to-edge microfibrils on the pad ensured that the debridement pad was effective, including in wounds where traditional debridement methods had previously been unsuccessful.

In all cases, patient comfort was noted and patients were satisfied with the treatment. All patients were able to tolerate the product, including the patient with pyoderma. Good results were achieved in all cases, regardless of whether the pad was pre-soaked or not; effects were improved when the pad was pre-soaked, but using the product independently is an effective option where necessary.

The Prontosan Debridement Pad provides a new advance in mechanical debridement, with its novel mode of action able to clear slough and disrupt biofilms more effectively than traditional debridement methods. **WUK**

The symposium and report article were supported by B Braun.

REFERENCES

- Cochrane review (2012). *The Effects of Water Compared with Other Solutions for Wound Cleansing*. Available online at: http://www.cochrane.org/CD003861/WOUNDS_the-effects-of-water-compared-with-other-solutions-for-wound-cleansing (accessed 7.12.2017)
- Dowsett C, Newton H (2005) Wound bed preparation: TIME in practice. *Wounds UK* 1(3):58–70
- Halim AS, Khoo TL, Mat Saad AZ (2012) Wound bed preparation from a clinical perspective. *Indian J Plast Surgery* 45(92):193–202
- Malone M, Bjarnsholt T, McBain A et al (2017) The prevalence of biofilms in chronic wounds: a systemic review and meta-analysis of published data. *J Wound Care* 26 (1) 20–5
- Wolcott RD, Rhoads DD, Dowd SE (2008) Biofilms and chronic wound inflammation. *J Wound Care* 17(8):333–41
- Wolcott RD, Fletcher J (2014) The role of wound cleansing in the management of wounds. *Wounds International* 5(3):25–31
- Wounds UK (2017) Quick Guide: TIMES model of wound bed preparation. Available online at: <http://www.wounds-uk.com/quick-guides/quick-guide-times-model-of-wound-bed-preparation> (accessed 27.11.2017)