

CONSENSUS DOCUMENT

---

---

THE ROLE OF LARVAL  
DEBRIDEMENT THERAPY  
IN THE MANAGEMENT  
OF LOWER LIMB  
WOUNDS

---

**Published by:**

Wounds UK  
108 Cannon Street  
London EC4N 6EU, UK  
Tel: +44 (0)20 3735 8244  
www.wounds-uk.com

**Wounds** UK

© Wounds UK, 2020

This document has been developed by Wounds UK and supported by BioMonde.



The views expressed are those of the authors and do not necessarily reflect those of BioMonde.

**How to cite this document:**

Atkin L, Acton C, Edmonds M et al (2020) *The role of larval debridement therapy in the management of lower limb wounds*. London: Wounds UK. Available to download from: [www.wounds-uk.com](http://www.wounds-uk.com)

**Expert working group**

**Chair: Leanne Atkin**, Vascular Nurse Consultant, Mid Yorks NHS Trust and Lecturer Practitioner, University of Huddersfield, West Yorkshire, UK

**Claire Acton**, Head of Tissue Viability, Kent Community NHS Foundation Trust, Kent, UK

**Michael Edmonds**, Professor of Diabetic Foot Medicine, King's College London; Consultant Physician, King's College Hospital, London, UK

**Sian Fumarola**, Clinical Specialist, NHS Supply Chain; Senior Clinical Nurse Specialist, Tissue Viability and Continence, University Hospitals of North Midlands NHS Trust, Staffordshire, UK

**Jemell Geraghty**, Nurse Consultant for Tissue Viability, Camden Health Improvement Practice London, Turning Point; HCA Hospitals (Princess Grace) London; Visiting Clinical Teacher, King's College, Florence Nightingale Faculty of Nursing, Midwifery and Palliative Care, London, UK

**Caroline McIntosh**, Established Professor of Podiatric Medicine, National University of Ireland Galway; Diabetes Specialist Podiatrist, University College Hospital Galway, Galway, Ireland

**Duncan Stang**, Podiatrist; National Diabetes Foot Coordinator for Scotland, UK

**Review panel**

**Jeannie Donnelly**, Lead Nurse Tissue Viability, Belfast Health and Social Care Trust, Belfast, Northern Ireland

**Georgina Gethin**, Head of the School of Nursing and Midwifery and the Alliance for Innovation and Research in Wounds, Áras Moyola, National University of Ireland, Galway, Ireland

**Angela Rodgers**, Paediatric Tissue Viability Nurse, Royal Hospital for Children, Glasgow, UK

**Ruth Ropper**, Lead Nurse Tissue Viability, NHS Lothian, Scotland, UK

# Foreword

---

The lower limb is the most common site for wounds (Guest et al, 2015) and, with almost half being considered 'chronic' or complex (Guest et al, 2017), it is essential that timely, appropriate treatment is provided to increase the chances of healing, improve patient quality of life and reduce pressure on healthcare services. There is currently a lack of wound differentiation, marked variation in care and underuse of evidence-based interventions in practice (Guest et al, 2015; Gray et al, 2018). Making a clear diagnosis and integrating wound care into the management of underlying comorbidities will address these issues. As patients are often treated across several healthcare settings, success will depend on multidisciplinary care in conjunction with clear treatment and referral pathways.

Debridement is considered beneficial in wound management as it addresses the cause of inflammation, optimises the condition of the wound bed, reduces the risk of infection and reveals the extent of tissue damage, enabling accurate wound assessment (Gray et al, 2010; All Wales Tissue Viability Nurse Forum, 2013; Strohal et al, 2013; Davies et al, 2015). In the UK, debridement often takes 3 months, by which time a wound is considered hard-to-heal (Wounds UK, 2016). Two previous debridement consensus statements support the use of larval debridement therapy (LDT) as a first-line option when speed, selectivity and bioburden are driving care decisions (Gray et al, 2010; Strohal et al, 2013). Literature and expert experience support the use of LDT as a rapid, selective, non-invasive treatment option for lower leg wounds, as a 'stand-alone' treatment or in conjunction with sharp debridement; however, this form of therapy is currently underused in practice despite being included on most formularies.

A panel of UK experts met in August 2019 to review the role of LDT in the management of lower limb wounds. They discussed the current treatment landscape, the benefits of LDT, possible barriers to its use, patient assessment and selection, and associated practical considerations. From their discussion, a treatment pathway has been devised that can be used by all members of the multidisciplinary team to inform the appropriate selection of LDT during clinical decision-making.

## **PURPOSE OF THIS DOCUMENT**

This document provides information and recommendations to support healthcare practitioners in the safe and effective prescription and delivery of LDT in practice, based on expert consensus. It focuses on lower limb wounds. The term 'lower limb' refers to any anatomical location below the knee, with wounds below the malleolus being sub-classified as foot wounds.

## **THE EVIDENCE: EMPIRICAL VERSUS CLINICAL PRACTICE**

At present there are no national guidelines on the use of LDT. There is currently a lack of empirical evidence, resulting from large blinded randomised controlled trials (RCTs), as it is difficult to blind patients to the use of larvae and there can be difficulties recruiting sufficient numbers of patients to generate statistically meaningful results (Dumville et al, 2009). Despite this, a large body of literature and anecdotal evidence from clinical practice support the use and benefits of LDT. This expert consensus serves to bridge the gap between empirical evidence and practice-based knowledge and experience.

# A challenging wound treatment landscape

## Box 1: Core tissue viability skills/competencies (White, 2008; HSE, 2018; Atkin et al, 2019)

- Competence in holistic assessment
- The ability to identify barriers (pathophysiology and risk factors) to healing
- Competence in acute and chronic wound care and related infection control
- The ability to assess and manage pain
- The ability to implement preventative measures, including pressure-redistribution equipment, to reduce the risk of skin and soft tissue injury
- Skin protection, especially for patients 'at risk' from trauma, maceration and periwound excoriation
- Knowledge of dermatological conditions that are common in older people
- Knowledge of vascular and circulatory anatomy and physiology
- The ability to assess the patient's suitability for compression
- The ability to promote the psychosocial wellbeing and health of patients living with a wound
- Appropriate referral to a complex wound clinic or multidisciplinary team as appropriate.

Wound care confers a considerable and growing burden on patients and the UK healthcare system. Wound management costs the NHS £4.5–5.1 billion a year, the majority of which is spent on hard-to-heal wounds (Guest et al, 2015). This expenditure does not include costs to the patient, such as the impact of wounds on productivity, activities of daily living and quality of life.

Wounds are common in clinical practice: 1.2–2.3% of individuals have an active leg ulcer; 2% of diabetes patients experience a new foot ulcer each year; and over 1,300 new pressure ulcers are reported each month (Mudge et al, 2014; Kerr, 2017; NHS Improvement, 2019). The overall prevalence of wounds in the UK is rising by 11.3% each year, with population ageing and increased multimorbidity contributing to impaired healing in many individuals (Guest et al, 2017). Around 30% of wounds currently lack a differential diagnosis and there is a lack of continuity and consistency in evidence-based wound care in practice (Guest et al, 2015; Gray et al, 2018). Ensuring patients receive a diagnosis and evidence-based treatment will improve outcomes. Patients should be offered access to the same care regardless of their background and diagnosis, yet greater recognition of complications associated with diabetes has resulted in the provision of more services and clearer referral pathways for these patients. A multidisciplinary team approach to care is ideal but is not always possible or implemented in practice (Guest et al, 2015). The Royal College of Nursing (2017) has highlighted that there are currently not enough registered general nurses in the UK to provide patients with optimal levels of care and that there has been a dilution of skill mix since 2010 — and this includes nurses with tissue viability training. Local service commissioning, prescribing budgets and difficulties filling specialist posts add to variations in care provision and multidisciplinary working across healthcare settings and regions.

The NHS England National Wound Care Strategy Programme is working to eliminate variations in clinical practice, and provide patients with the right care at the right time, delivered by practitioners with the appropriate skills and education (Atkin, 2019). Self-recognition of limitations in tissue viability skills and competency will ensure patients are referred in a timely and appropriate manner (Gray et al, 2018). Tissue viability nurses and other specialist nurses have a key role to play in supporting the optimal management of patients with complex or hard-to-heal wounds. In the medium- to long-term, increasing the number of community and primary care practitioners with core tissue viability skills (Box 1), will improve the treatment patients initially receive and reduce the number of patients with hard-to-heal wounds referred to the tissue viability service at a later date.

## SUCCESS REQUIRES A MULTIDISCIPLINARY TEAM APPROACH

Patient wound care programmes can span multiple care settings, making treatment complex. All patients with hard-to-heal wounds should be managed by appropriate members of the multidisciplinary team (Atkin, 2019). Practitioners are encouraged to foster relationships outside their own discipline to share information and learning, and to support multidisciplinary working. Integration, coordination and information-sharing between various specialists and teams promote continuity of care as well as supporting patient self-care, improving healing rates and protecting at-risk patients (Wounds UK, 2016; 2019). It is important to keep patient medical records up to date so other team members are able to make informed decisions that will optimise care and implement any course of treatment prescribed.

# Importance of debridement

Debridement refers to the removal of necrotic tissue, slough, haematomas, eschar, debris, foreign bodies and infected tissue from a wound (Strohal et al, 2013). Some wounds should not be debrided, such as untreated calciphylaxis, active pyoderma gangrenosum, wounds with little or no blood flow, e.g. severe arterial disease. There are a number of reasons for debriding a wound (Box 2).

## Box 2: Reasons to debride a wound (Gray et al, 2010; Strohal et al, 2013; Davies et al, 2015)

- Devitalised tissue may mask or mimic signs of infection
- To determine the extent of tissue destruction and aid correct wound assessment
- To address the inflammatory response, reducing excess matrix metalloproteinase production and the likelihood of septic response
- To remove tissue acting as a physical barrier to healing
- To enable topical agents to be used effectively
- To reduce the risk of infection, as necrotic tissue may serve as a source of nutrients for bacteria
- To reduce odour
- To reduce excess moisture
- To stimulate wound edges and epithelialisation
- To reduce potential pain associated with devitalised tissue
- To improve quality of life.

Optimal debridement tailored to the individual should be an integral part of best practice (Wounds UK, 2008). Many practitioners operate within their professional competency range (Gray et al, 2010), which can result in them initially only considering autolytic debridement, which is slow and sometimes insufficient (Wolff and Hansson, 2003). Mechanical and sharp surgical debridements are fast and popular but can be unselective, painful, carry a risk of bleeding, require anaesthesia and must be performed by a skilled practitioner (Wolff and Hansson, 2003; Strohal et al, 2013; Mudge et al, 2014). By comparison to surgical debridement, LDT is:

- Easy to use
- Non-invasive
- Safe
- Relatively painless
- Does not cause an inflammatory response
- Often well accepted by the patient
- Not operator dependent (Sherman, 2002; Opletalová et al, 2012; Cazander et al, 2013; Cowan et al, 2013).

## BARRIERS TO LDT USE

The group agreed that LDT is currently underused in practice for several reasons:

- Allied healthcare professionals and patients may have concerns or misconceptions relating to the treatment. In many cases, education can address these issues.
- For licensing purposes, in the UK, LDT is considered a drug, unlike other wound care products, and is available on prescription.
- Although it is faster than other forms of non-surgical debridement, it has a higher unit cost than many wound care products; therefore, despite being cost-effective (Bennett et al, 2013) the clinician may have to argue their case with budget holders.

Systems are currently the major limiting factor in the improved use of LDT. The prescribing clinician needs to ensure, if the patient will move from hospital to community care, that the supply chain is set up to process the prescription, that other practitioners know when to order treatment, and that the viability of the product is considered to ensure continuity of patient care.

# Larval debridement therapy

## HISTORY

LDT — sometimes referred to as biosurgery — has been used for hundreds of years (Mumcuoglu et al, 2001; Cowan et al, 2013; Strohal et al, 2013). It was widely applied early in the 20th Century after Baer (1931) successfully used it to treat leg ulcers and osteomyelitis during the First World War. This form of therapy subsequently fell out of favour in the 1940s, following the development of antibiotics and modern surgical debridement, and became a last-resort treatment. With the rise in hard-to-heal wounds and antibiotic resistance, interest in LDT has increased in recent years (Sun et al, 2014).

## MODES OF ACTION

LDT uses *Lucilia sericata* (greenbottle fly) larvae, which have three modes of action:

- Debridement
- Antimicrobial
- Stimulation of healing (Gray et al, 2010; Strohal et al, 2013; Mudge et al, 2014).

Larvae use mechanical and biochemical debridement techniques to break down devitalised tissue (Gottrup and Jørgensen, 2011). Their mandibles disrupt cell membranes and their rough outer surface physically damages tissue as they move around (Gray et al, 2010). Their movement increases exudate production, irrigating the wound and releasing bacteria (Sherman, 2002). The proteolytic enzymes they secrete break down slough to produce semi-liquid tissue consisting of wound debris and organisms, which they ingest (Tian et al, 2013; Campbell and Campbell, 2014). Most bacteria are destroyed in the mid- and hindgut and the remainder are excreted within a peritrophic membrane (a film-like structure that separates food from midgut tissue), preventing contamination of the wound (Mumcuoglu et al, 2001). In addition to ingestion, larvae secrete antibacterial molecules and increase the pH level of the wound, making it unfavourable for bacterial growth and reducing wound bioburden (Thomas et al, 1999; Turner, 2017). Larvae are very effective against Gram-positive organisms but have little or no impact on Gram-negative bacteria (Table 1; Thomas et al, 1999; Steenvoorde and Jukema, 2004; Jaklic et al, 2008; Opletalová et al, 2012). Bowling et al (2007) reported that LDT eliminated MRSA infection in 92% of diabetic foot ulcers (DFUs) after an average of 19 days, proving faster and cheaper than treatment with vancomycin.

**Table 1: Organism susceptibility to LDT (Thomas et al, 1999; Mumcuoglu et al, 2001; Steenvoorde and Jukema, 2004; Jaklic et al, 2008; Opletalová et al, 2012; Cowan et al, 2013)**

Susceptible	Not susceptible
<ul style="list-style-type: none"><li>■ Methicillin-resistant <i>Staphylococcus aureus</i> (MRSA)</li><li>■ <i>Streptococcus</i> A and B</li><li>■ <i>S. aureus</i> (free, planktonic and biofilm)</li><li>■ <i>Pseudomonas</i> spp.</li><li>■ <i>P. aeruginosa</i> (planktonic and biofilm)</li></ul>	<ul style="list-style-type: none"><li>■ <i>Escherichia coli</i></li><li>■ Enterococcus</li><li>■ Proteus</li></ul>

Biofilms can be prevented, inhibited and broken down by larvae (van der Plas et al, 2008; Cazander et al, 2009a, 2009b; Gottrup and Jørgensen, 2011; Harris et al, 2013); *P. aeruginosa* and *S. aureus* biofilms were eliminated within 48 hours of larval application in *in vitro* studies (Mumcuoglu, 2001; Cowan et al, 2013). LDT is effective in conditions that impair or increase the likelihood of biofilms developing and spreading (Armstrong et al, 2005; Tian et al, 2013). Finally, larvae support healing by secreting/excreting growth-stimulating factors, peptides and amino acids (Gottrup and Jørgensen, 2011; Tian et al, 2013). These secretions and excretions enhance fibroblast production and migration through the extracellular matrix, induce matrix remodelling, coordinate cellular responses, support granulation and increase wound oxidation and pH (Prete, 1997; Wollina et al, 2002; Horobin et al, 2006; Marineau et al, 2011; Tian et al, 2013).

### FORMS OF TREATMENT

#### BioBag dressing

Larvae are sealed within a finely woven nylon mesh that remains intact throughout treatment. BioBag dressings are available in a number of sizes, so practitioners should select a dressing appropriate to the size and nature of the wound. Treatment can be delivered by any practitioner following basic training, such as a healthcare professional, nurse, GP. It is easy to apply, monitor and remove (Mudge et al, 2014), and so is suitable for use in community, primary and secondary care settings.

**Instructions:** Before application, cleanse the wound to remove any loose material and dressing residues. Protect the periwound skin with a zinc-based barrier cream (such as Sudocrem) or a zinc bandage. In the case of zinc allergy, use a suitable alternative, such as 3M™ Cavilon™ Durable Barrier Cream or Sorbaderm® Barrier Cream. Cover the wound margin but not the periwound skin with the BioBag. Place damp gauze over the top to moisten the larvae and cover this with an absorbent non-occlusive dressing secured with tape or a light bandage.

#### Loose larvae

This form of therapy will generally be prescribed within a specialist-led or -supported unit. Loose larvae are used when there would be insufficient BioBag contact with the wound and/or to uncover the depth of tissue damage, e.g. the debridement of sinuses, suture lines or between multiple toes (Steenvoorde and Jukema, 2004; Steenvoorde et al, 2005b; Blake et al, 2007) or where sharp debridement has proven insufficient (Gray et al, 2010). If there is a deep sinus, the necessary investigation will need to take place before treatment with LDT.

**Instructions:** Cleanse the wound and place strips of hydrocolloid around the periwound area to protect the skin and act as a border on which to fix the retention net. If the wound is small, a hole can be cut in the centre of the hydrocolloid dressing. Cut the retention net to size, place it on damp gauze and pour on the loose larvae. Invert the net onto the wound and secure it in place with waterproof tape. Place damp gauze over the top to moisten the larvae and cover this with an absorbent non-occlusive dressing secured with tape or a light bandage.

# The LDT pathway

The lower limb LDT wound care pathway (Figure 1), spans multiple care arenas and can be used to guide the development of a patient’s individual care pathway. The clinician should consider the complexity of the patient, the lower limb/foot, and the wound. LDT can be used in any healthcare setting; Sherman et al (2001) and Turner (2017) found it to be effective and safe in outpatient settings, including clinics, day care facilities and patients’ homes (dependant on suitability), even when administered by non-clinicians. With the correct support and education, patients can potentially moisten their LDT when they change their secondary dressing. Therapy should be considered adjunctive, as after successful debridement patients will need follow-on treatment to support wound healing. Optimum outcomes are dependent upon multidisciplinary working, good communication with patients and the consistent documentation of patient consent, treatment goals, plans and progress to support other practitioners in the delivery of care.

## 1: INITIAL PRESENTATION

On initial presentation, patients need to be assessed for red flags and, if present, their management escalated. Any existing diagnosis that may impede healing should be discussed with the relevant specialist. Patients without a known underlying diagnosis should be referred to a clinician or service for diagnosis, so an appropriate treatment plan can be devised. Patients should be referred to specialists for ongoing treatment if required.

## 2: HOLISTIC ASSESSMENT BY A PRACTITIONER WITH ADVANCED CORE ASSESSMENT SKILLS

If healing is not progressing at 2 weeks in lower leg wounds or within 48 hours for patients presenting with foot wounds (National Wound Care Strategy Programme, 2020), holistic assessment (Box 4), supported by the TIME (Tissue, Inflammation and Infection, Moisture, Edge) or TIMERS (Tissue, Inflammation and Infection, Moisture Balance, Edge, Repair and Regeneration, Social- and Patient-related) framework will inform a diagnosis and the most appropriate treatment (Dowsett and Newton, 2005; Ousey and Cook, 2011; Atkin et al, 2019).

Four overlapping factors contribute to wound complexity: patient-related factors, wound-related factors, healthcare professional-related factors and resource/treatment-related factors (European Wound Management Association, 2008; Wounds UK, 2019). If the patient, their limb or wound is complex, multidisciplinary team input is needed to decide upon the best treatment pathway. Patient location — e.g. prison or itinerant — should not limit access to treatment choices. Factors that may impede healing (Table 2), need to be assessed and managed where possible as part of the wound care plan (HSE, 2018; Adderley, 2019).

**Table 2: Factors that delay wound healing (Guo and DiPietro, 2010; Thomas Hess, 2011; Gilead et al, 2012; Cowan et al, 2013)**

Local factor	Systemic factor
<ul style="list-style-type: none"> <li>■ Poor oxygenation/ischaemia</li> <li>■ Infection or high bioburden</li> <li>■ Foreign body</li> <li>■ Vascular insufficiency</li> <li>■ Skin desiccation</li> <li>■ Maceration</li> <li>■ Necrosis</li> <li>■ Pressure</li> <li>■ Oedema</li> <li>■ Trauma</li> </ul>	<ul style="list-style-type: none"> <li>■ Older age</li> <li>■ Chronic diseases: coronary artery disease, peripheral vascular disease, cancer, diabetes, hypertension, chronic obstructive pulmonary disease</li> <li>■ Medications: corticosteroids, nonsteroidal anti-inflammatory drugs, chemotherapy</li> <li>■ Very high or low body mass index</li> <li>■ Lifestyle: alcohol consumption, smoking, poor mobility, psychosocial wellbeing</li> <li>■ Immunosuppression: cancer, radiotherapy, AIDS</li> <li>■ Malnutrition</li> <li>■ Stress</li> <li>■ Male androgens, e.g. testosterone</li> </ul>



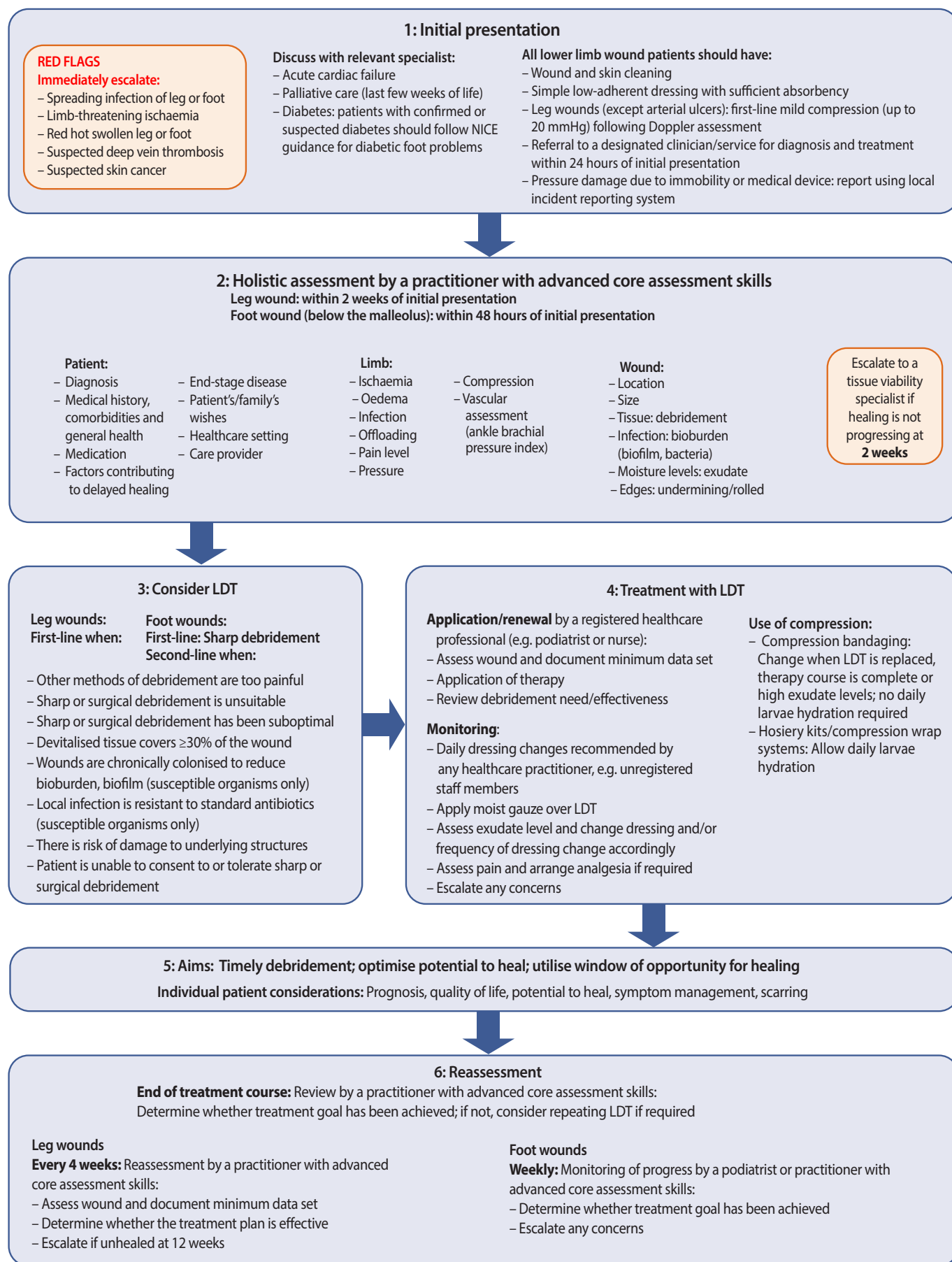


Figure 1. LDT wound care pathway (SIGN, 2010; NICE, 2016; National Wound Care Strategy Programme, 2020)

The location of a wound — lower limb or foot — should be clearly identified and the wound assessed. If devitalised tissue is present, the fastest safe form of debridement that is acceptable to the patient (or carer) should be selected (Table 3). The practitioner should consider (Gray et al, 2010):

- The treatment goal: removal of devitalised tissue that will delay healing, prevention of infection or symptom control
- Speed of debridement, based on time since the wound occurred, amount of devitalised tissue, anatomical location, further treatment (e.g. skin grafting)
- The most suitable debridement option
- The patient/their carer's treatment preference
- Whether they have the skills/competency to perform the procedure or need to refer the patient
- Ability to access treatments based on patient location.

### 3: CONSIDER LDT

LDT is appropriate to treat wounds with (Chadwick et al, 2015):

- Moist, sloughy/necrotic tissue
- Resloughing
- Signs of infection
- Poor progression to healing with other methods of debridement.

LDT should be considered first-line treatment for lower limb wounds in conjunction with other modes of therapy when speed, selectivity and bioburden are driving factors in management (Gray et al, 2011; Strohal, 2013). It should be considered as second-line in the management of foot ulcers following sharp debridement (Chadwick et al, 2015).

### 4-6: TREATMENT, AIMS AND REASSESSMENT

The type of wound a patient presents with will provide an indication of the optimal outcome:

- Swift debridement in patients with acute wounds that have the possibility of being complex
- Complex/hard-to-heal wounds where slough or necrotic tissue is present
- Prevention of infection in limb salvage
- Symptom management in patients with palliative wounds.

If a practitioner does not have advanced core tissue viability skills or is unable to prescribe a course of LDT, they should promptly refer the patient to a suitable practitioner.

If there are clinical signs or symptoms of infection, a swab should be sent to microbiology to identify the causative organism(s). In many healthcare environments this is now discouraged, but the results of wound culture provide information on the susceptibility of organism(s) present and ensure appropriate use of antibiotics to manage systemic or spreading infection. Consider cleaning the wound and surrounding area with a suitable cleanser or solution to remove any contamination. All suitable patients should be offered LDT, even in the presence of local infection.

**Table 3: Types of debridement for lower limb wounds (Chan et al, 2007; Paul et al, 2009; Gray et al, 2010; Marineau et al, 2011; Gilead et al, 2012; Opletalová et al, 2012; All Wales Tissue Viability Nurse Forum, 2013; Cowan et al, 2013; Strohal et al, 2013; Campbell and Campbell, 2014; NICE, 2019)**

Type of debridement	Indications	Advantages	Disadvantages
<b>Autolytic</b> Moisture-retaining dressings that use the body's enzymes and exudate to separate necrotic tissue from the wound bed	<ul style="list-style-type: none"> <li>Wounds where mechanical debridement is unavailable or contraindicated</li> <li>Exudative wounds with slough, i.e. that require absorptive dressings</li> </ul>	<ul style="list-style-type: none"> <li>Easy to use</li> <li>May result in cost savings due to fewer dressing changes</li> <li>Little or no pain</li> <li>No damage to healthy tissue</li> <li>Absorptive autolytic dressings can manage exudate</li> </ul>	<ul style="list-style-type: none"> <li>Risk of allergic reactions to ingredients in dressings</li> <li>Risk of inflammation</li> <li>Slow; often requires prolonged therapy</li> <li>Time-consuming and contraindicated for infected wounds</li> </ul>
<b>Enzymatic</b> Ointment, gel or dressing containing enzymes that soften and lift necrotic tissue	<ul style="list-style-type: none"> <li>Acute and chronic wounds with necrotic tissue or fibrin coatings</li> <li>Before sharp debridement</li> </ul>	<ul style="list-style-type: none"> <li>Easy to use</li> <li>May result in cost savings due to fewer dressing changes</li> <li>Little or no pain</li> <li>No damage to healthy tissue</li> </ul>	<ul style="list-style-type: none"> <li>Risk of allergic reactions to ingredients in dressings</li> <li>Risk of inflammation</li> <li>Slow; often requires prolonged therapy</li> <li>Enzymatic, hydrogel and occlusive dressings not suitable for high exudate levels</li> </ul>
<b>Jet lavage</b> Pressurised solution to irrigate and debride necrotic tissue	<ul style="list-style-type: none"> <li>Various wounds, including venous leg ulcers and post-surgical diabetic foot ulcers, with different types of tissue</li> </ul>	<ul style="list-style-type: none"> <li>Flexible modes of action</li> <li>Suitable for different wound conditions</li> </ul>	<ul style="list-style-type: none"> <li>Equipment not generally available in all treatment settings</li> <li>Cost of equipment is high</li> <li>Requires skilled staff, treatment room and anaesthesia</li> <li>May be painful</li> <li>Not suitable for home care</li> </ul>
<b>LDT</b> <i>Lucilia sericata</i> that secrete enzymes, which break down slough and destroy bacteria	<ul style="list-style-type: none"> <li>Wounds with devitalised tissue, including venous leg ulcers, arterial/ ischaemic leg ulcers, mixed venous-arterial leg ulcers, pressure ulcers, diabetic leg and foot ulcers, post-traumatic wounds (haematomas and dehiscence), non-healing surgical wounds, MRSA-infected wounds, deep wounds with sloughy cavities, chronic wounds, wounds with unclear margins, burns, pyoderma gangrenosum and calciphylaxis</li> <li>When fast and/or selective debridement is desirable, e.g. limb salvage</li> <li>Patients not suitable for surgical debridement, e.g. if older, bedbound, infirm, or surgical/sharp debridement is unacceptable due to pain</li> <li>To manage wound bioburden</li> <li>When other debridement methods are excluded due to peripheral arterial disease</li> <li>When patients express a preference for LDT and treatment is indicated</li> </ul>	<ul style="list-style-type: none"> <li>Fast application and action</li> <li>Reduces pain</li> <li>Reduces bacteria</li> <li>Disrupts biofilm</li> <li>Reduces malodour</li> <li>Promotes wound healing</li> <li>Selectively separates necrotic from healthy tissue</li> <li>Little or no side-effects</li> <li>Few resources needed</li> <li>Bagged larvae can be applied following minimal training</li> <li>Can be left in place for 3-5 days</li> <li>Can be used as an adjunct to other treatments, e.g. after pre-debridement, after suboptimal sharp/surgical debridement, before negative pressure wound therapy in chronic osteomyelitis or in addition to conventional treatment for infection</li> <li>Suitable for all age groups</li> </ul>	<ul style="list-style-type: none"> <li>May cause initial pain or a change in sensation; appropriate analgesia needs to be provided</li> <li>Contraindicated in patients with allergy to fly larvae</li> <li>Caution required with exposed blood vessels, malignant wounds and in areas at risk of bleeding</li> <li>Needs to be ordered in advance of application</li> </ul>
<b>Mechanical</b> <ul style="list-style-type: none"> <li>Hydrotherapy</li> <li>Monofilament debridement pads</li> </ul>	<ul style="list-style-type: none"> <li>Venous leg ulcers, diabetic foot ulcers, arterial ulcers, mixed aetiology ulcers, pressure ulcers, traumatic wounds</li> </ul>	<ul style="list-style-type: none"> <li>Fast</li> <li>Easy to use</li> <li>Modern products claim to cause little to no pain</li> <li>Limited damage to healthy tissue</li> <li>Monofilament debridement pads: convenient, well tolerated and cost-effective</li> </ul>	<ul style="list-style-type: none"> <li>Monofilament pad: not efficient if hard necrosis or thick, tenacious slough present</li> <li>Often does not result in 100% debridement</li> <li>Hydrotherapy: requires specific equipment which is costly to purchase</li> </ul>

Table 3 (Continued)			
Type of debridement	Indications	Advantages	Disadvantages
<p><b>Sharp debridement</b> Use of a scalpel, curette or scissors to remove non-viable tissue without creating a bleeding wound bed. Does not require local or general anaesthetic</p>	<ul style="list-style-type: none"> <li>Various acute and chronic wounds including pressure ulcers and diabetic foot ulcers</li> </ul>	<ul style="list-style-type: none"> <li>Fast</li> <li>Low staff and material costs</li> <li>Efficient at removing solid necrotic tissue and sloughy tissue</li> <li>Suitable for exudative wounds and some infected wounds</li> <li>Removes callous and refashions wound edges</li> <li>Removes local infection and decreases bioburden</li> </ul>	<ul style="list-style-type: none"> <li>Requires a competent clinician with specialist training</li> <li>Risk of infection if sterile conditions not ensured</li> <li>Risk of removing healthy tissue and damaging surrounding structures, particularly in the foot</li> <li>Risk of bleeding</li> <li>May be painful</li> </ul>
<p><b>Surgical debridement</b> Use of a scalpel, curette or scissors to cut down to healthy tissue. Requires local or general anaesthetic</p>	<ul style="list-style-type: none"> <li>Only use if other techniques are ineffective or the condition of the patient requires rapid, major intervention</li> <li>Presumed involvement of deep structures and complications</li> <li>Removal of a solid layer of necrotic tissue</li> <li>Clearing the wound bed prior to grafting</li> <li>When there is clear demarcation between viable and non-viable tissue</li> <li>Severe wound infection</li> </ul>	<ul style="list-style-type: none"> <li>Efficient in wounds with a solid layer of necrotic tissue</li> <li>Suitable for exudative wounds and some infected wounds</li> </ul>	<ul style="list-style-type: none"> <li>Requires skilled staff, treatment room and anaesthesia</li> <li>May be time-consuming</li> <li>Risk of removing healthy tissue and damaging surrounding structures, particularly in the foot</li> <li>Risk of bleeding and pain</li> <li>Risk of infection if sterile conditions not secured or if infective material is transferred to non-infected tissue via the scalpel</li> <li>Special precautions needed when treating functionally and cosmetically important areas</li> </ul>
<p><b>Ultrasonic</b> Sound wave application results in mechanical forces (acoustic streaming) and vapour bubbles (cavitation) that disrupt necrotic tissue</p>	<ul style="list-style-type: none"> <li>Various wounds, including chronic ulcers, with different types of tissue</li> </ul>	<ul style="list-style-type: none"> <li>Has a range of effects, from destruction to dislocation to physical modification</li> </ul>	<ul style="list-style-type: none"> <li>Equipment not generally available in various treatment settings</li> <li>Cost of equipment is high</li> <li>Not suitable for home care</li> </ul>

### Cautions and contraindications

Care should be taken in patients with risk factors (Box 3). There is a small risk of bleeding associated with dissolving devitalised tissue (Steenvoorde and van Doorn, 2008) and therapy should be stopped if there is visible, active bleeding. Before initiating treatment, areas exposed to high pressure should be offloaded and any pus drained. LDT treatment is not suitable for callus debridement. Treatment should not be applied to an exposed prosthetic or dry ischaemic toe. It is not appropriate for patients allergic to larvae, those with a psychological aversion (e.g. insect phobia), or an ethical objection (i.e. veganism) (All Wales Tissue Viability Nurse Forum, 2013; Campbell and Campbell, 2014).

### Approaching and prescribing LDT

There are misconceptions surrounding LDT (Table 4). Practitioners should avoid showing distaste when discussing or providing LDT to preserve patient dignity; patient acceptance is often good and feedback usually positive (Marineau et al, 2011; Opletalová et al, 2012; Campbell and Campbell, 2014). Information about LDT, the benefits, risks, implications and possible alternatives should be given to patients and informed consent obtained using local guidelines (Box 4). Written consent is preferable to verbal consent; to aid the consent process, there are patient-focused resources available to be used in practice on the BioMonde website (see page 15 for more information). Commonly three LDT applications are required to achieve wound bed preparation; therefore, practitioners need to plan for this. In some cases, the wound bed may be clear after only one or two applications. Instructions on the selection and application of LDT can be found on page 7. Management plans and instructions should be made available to all healthcare professionals likely to be involved in managing the patient's wound (All Wales Tissue Viability Nurse Forum, 2013).

**Box 3: Cautions and contraindications for LDT of lower limb wounds**

**Caution**

- ! Osteomyelitis
- ! Anticoagulant use (when the clotting marker is within an acceptable range)
- ! Visible underlying structures
- ! Plantar and heel wounds (unless offloaded)
- ! Carcinoma on the leg
- ! Fungating wounds
- ! End-stage renal disease
- ! Sinuses or fistulae (close supervision required)
- ! High volumes of exudate (highly absorbent dressings and regular dressing changes required)
- ! Dry necrotic eschar (rehydration or scoring with a scalpel is required prior to treatment)

**Contraindication**

- ✗ Wounds with a tendency to bleed
- ✗ Wounds close to an exposed major blood vessel
- ✗ Exposed prosthetic
- ✗ Dry ischaemic toe
- ✗ Anticoagulant use (when the clotting marker is not in an acceptable range)
- ✗ Conditions that cause dysfunctional blood clotting, e.g. haemophilia

**Table 4: Myths and truths about LDT**

Myths	Truths
✗ Larvae eat flesh	✓ Larvae release enzymes that dissolve non-viable tissue
✗ Larvae cause malodour	✓ Malodour is caused by microorganisms
✗ Larvae are dirty	✓ Larvae are produced in an aseptic process
✗ High volumes of exudate will drown the larvae	✓ Exudate can be managed by daily dressing changes
✗ Treatment causes pain	✓ Initial pain is linked to improvement and diminishes over time. The short-term use of appropriate analgesia prevents this being an issue
✗ Treatment causes bleeding	✓ The risk of bleeding is very small (Steenvoorde and van Doorn, 2008)
✗ The larvae will escape	✓ Most larvae are prescribed in bags ✓ Loose larvae are held in place with gauze taped over the wound
✗ Autolysis is a rapid and efficient form of debridement	✓ Larvae debride faster than other methods (Thomas, 2006; Dumville et al, 2009)
✗ Cannot be used on necrotic tissue	✓ Cannot be used on dry eschar but can be used on moist necrotic tissue
✗ Cannot be used after sharp debridement	✓ Can be used if clinician has not achieved the removal of all devitalised tissue
✗ <i>Pseudomonas</i> kills larvae	✓ Heavy <i>Pseudomonas</i> infections can impact larval viability and reduce the speed of debridement; however, the therapy can still be used (Cowan et al, 2013)
✗ Can only be used by specialists	✓ Is a standard treatment that can be used by generalists with core skills. It is easy for healthcare providers to apply and remove. Patients can self-care between BioBag applications by moistening the wound bed if they observe good hand hygiene
✗ Cannot be used in areas subject to high pressure as larvae may be squashed	✓ Can be used for foot wounds if offloaded (All Wales Tissue Viability Nurse Forum, 2013) ✓ Can be used under non-occlusive compression therapy (Davies et al, 2015)
✗ Cannot be used when infection is present	✓ Can be used when infection is present (Steenvoorde et al, 2007)

**Box 4: Consent: good practice**

- Provide the patient with verbal and written information about LDT
- Give the patient time to process this information
- Ask whether they have any questions or concerns about treatment
- Ask whether they agree to receive treatment
- Save details of consent in the patient's medical record.

## The LDT pathway

### Advice for patients

Positive verbal and body language should be used while preparing patients for LDT to avoid or minimise patient fear or disgust. Patient concerns should be addressed and their expectations managed (Table 5 and Box 5). Advise patients that larvae are an effective, safe and natural medical product produced under strict, aseptic conditions in a laboratory. Useful sources of patient information can be found on the BioMonde website.

**Table 5: Concerns and patient expectations relating to LDT**

Patient concern/comment	Appropriate clinical response
Maggots are dirty	Larvae are sterile medical products that clean the wound bed
Maggots smell	Larvae break down dead tissue, releasing bacteria that can smell. The smell should go when your dressings are changed
I'll feel the maggots wriggling around	You may feel a tickling, tingling or pulsating sensation but most people don't even know the larvae are there
The maggots will escape!	The larvae are secured within a bag/held in place by a system of dressings throughout treatment. The risk of them escaping is very small
Maggots will burrow into me and eat healthy as well as dead flesh	Larvae break down and eat dead tissue, leaving the healthy tissue alone. They will not burrow into your body as they need access to oxygen to live
They will cause my wound to bleed	Bleeding is very rare. The liquid produced from your wound may look dirty, pink or red, but this is the result of the treatment working. Your wound bed will be checked for bleeding between treatments
Treatment will hurt	Sometimes LDT increases pain. This is usually temporary and can generally be managed with painkillers. If you find paracetamol and/or ibuprofen are not strong enough, your GP will prescribe something stronger
People will know that I've got maggots in my wound and will avoid me	LDT is applied directly to the wound and is covered with bandages, so no one will know they are there
The maggots will become huge	The larvae are about the size of a grain of rice when applied. When the therapy is working, they will increase to a maximum of 1.2cm long
I can't live my life normally while having this treatment	You can perform daily tasks as normal; however, avoid sitting too close to the radiator or fire or submerging your bandage in water, as this can harm the larvae Wounds in an area exposed to high pressure, e.g. under your foot: You should avoid walking while having LDT because the larvae will be crushed. To help prevent this, you will be given additional treatment that will offload the pressure from this area
The liquid from my wound will leak	Bandages will be selected that can absorb the amount of liquid produced. These will be changed as often as needed to prevent any leakage

### Box 5: Guide to approaching treatment with patients

- Sit or stand in a relaxed and open position
- Smile or keep a neutral expression on your face
- Explain the importance of cleaning the wound, so healing can progress and/or symptoms will be better managed
- Explain that you feel LDT is the best treatment option for them
- Use the terms 'LDT' or 'LDT course' and not 'maggots' or 'maggot treatment/therapy' and make sure the patient understands these terms
- Advise them that larvae are a safe and natural form of treatment that will not damage the surrounding tissue
- Tell them it is important to complete the course of treatment, as this will give them the best chance of a good outcome
- Discuss the mode of action to dispel unhelpful myths and prepare them for any changes that may occur during treatment
- Talk about the benefits of treatment
- Ask whether they have any questions or concerns, both before and after treatment is applied
- Provide printed information they can refer back to or advise them where they can find information.

### DURING TREATMENT

Once a practitioner has initiated LDT treatment, community or primary care practitioners can provide ongoing management, with regular review by a practitioner with core tissue viability skills. A detailed handover is needed when treatment is shared or there is a transition of care to prepare nurses to provide LDT. Practical tips for the use of LDT are given in Box 6.

Order additional larvae at least 1 day before they are due to be applied, allowing sufficient time for internal procurement/pharmacy to process the prescription. Apply treatment within 24 hours of receipt, as viability is reduced after this time (Turner, 2017). The full treatment course should be administered to obtain the maximum benefit, even if the wound bed appears to be clear, because the larvae provide an antimicrobial environment conducive to tissue repair.

Care should be escalated if the patient is showing signs of infection or sepsis. Patients on LDT should be reassessed after a minimum of 5 days, unless the complexity of the patient necessitates earlier reassessment, e.g. an infected DFU.

#### Box 6: Practical tips for LDT use

- Do not disrupt treatment unless contraindications are present
- Leave larvae in place for the duration of each therapy (up to 4 days)
- Hydrate the larvae every day with damp gauze\*
- Check the larvae are moving and producing dark exudate during dressing changes
- Select non-occlusive secondary dressings suitable for the expected volume of exudate
- Avoid superabsorber dressings, as they reduce the oxygen available to larvae
- Avoid putting direct tight pressure over the LDT or overpacking the wound†
- Assess and document the status of the wound bed before and after each LDT application
- Double-bag used dressings, BioBags and loose larvae and treat as clinical waste (where possible)
- Allow sufficient time for prescriptions to be processed.

\*Unless compression bandages are being used. †Larvae can survive under four-layer compression up to 40 mmHg

### Further sources of information

1. All Wales Tissue Viability Nurse Forum (2013) *All Wales Guidance for the use of LDT*. Wounds UK, London. Available at: [http://www.welshwoundnetwork.org/files/6513/8632/3119/AWTVNFlarval\\_finalforweb\\_opt.pdf](http://www.welshwoundnetwork.org/files/6513/8632/3119/AWTVNFlarval_finalforweb_opt.pdf)
2. The Larval Academy: a free online accredited course, tailored specifically for healthcare professionals, that provides information on how LDT works, how it can be used to support wound management and how it should be applied. Register at: [www.larvalacademy.com](http://www.larvalacademy.com)
3. The BioMonde website ([www.biomonde.com/en](http://www.biomonde.com/en)) has information for healthcare professionals, patients and carers. This includes:
  - Clinical papers and guidelines
  - Case studies
  - Application and care instructions
  - Patient information guide.

# Expected changes as treatment progresses

---

A change in exudate volume and colour should be expected as treatment progresses (Marineau et al, 2011). LDT increases the volume of exudate produced, and absorbent non-occlusive secondary dressings may be required to protect the larvae and periwound skin. As devitalised tissue breaks down, patients' exudate may become 'dirty', brown, pink or red. This is not a result of bleeding; bleeding rarely occurs with this therapy (Steenvoorde and van Doorn, 2008).

Malodour is often associated with the initial stages of treatment due to the release of secretions/excretions and is often worse if a large volume of devitalised tissue is present in the wound. Any malodour will be significantly improved following dressing removal/change and should decrease as treatment progresses. LDT reduced odour in 58% of malodourous ulcers in a study by Wolff and Hansson (2003).

Pain or discomfort is the most frequently reported side-effect of therapy (Wolff and Hansson, 2003; Dumville et al, 2009; Gilead et al, 2012; Mudge et al, 2014). Patients with pre-existing pain, vascular problems, wounds secondary to autoimmune conditions, pyoderma gangrenosum, carcinoma and lymphoma are more likely to report LDT-associated pain (Sherman, 2009; Gilead et al, 2012). The presence of diabetes reduces pain associated with treatment (Steenvoorde et al, 2005a). Improvements in the wound can reduce pain; 25% of participants in a study by Wolff and Hansson (2003) reported less pain during LDT. Pain or discomfort during treatment can be managed with painkillers. Prescribers should make a note on the patient's medical record to advise that additional or supplementary analgesia may be required.

A short-term inflammatory response to treatment has been observed in some patients (Marineau et al, 2011). However, research suggests larval secretions have anti-inflammatory effects, and therefore promote healing (Pritchard and Nigam, 2013).

## Maximising patient quality of life

Advise patients that they can perform most activities as normal while the LDT is in place, but they should avoid submerging the dressing in water, sitting too close to sources of heat and walking on foot wounds, as the larvae may be damaged. Give the patient extra bandages in case their dressings get wet while bathing. Consider prescribing a non-occlusive protector; this can be worn when showering or bathing to prevent the bandages and LDT getting wet and reduce the risk of falls. If the patient's bandages are very bulky, post-operative/wound care shoes may be needed. These can be prescribed for or purchased by the patient.

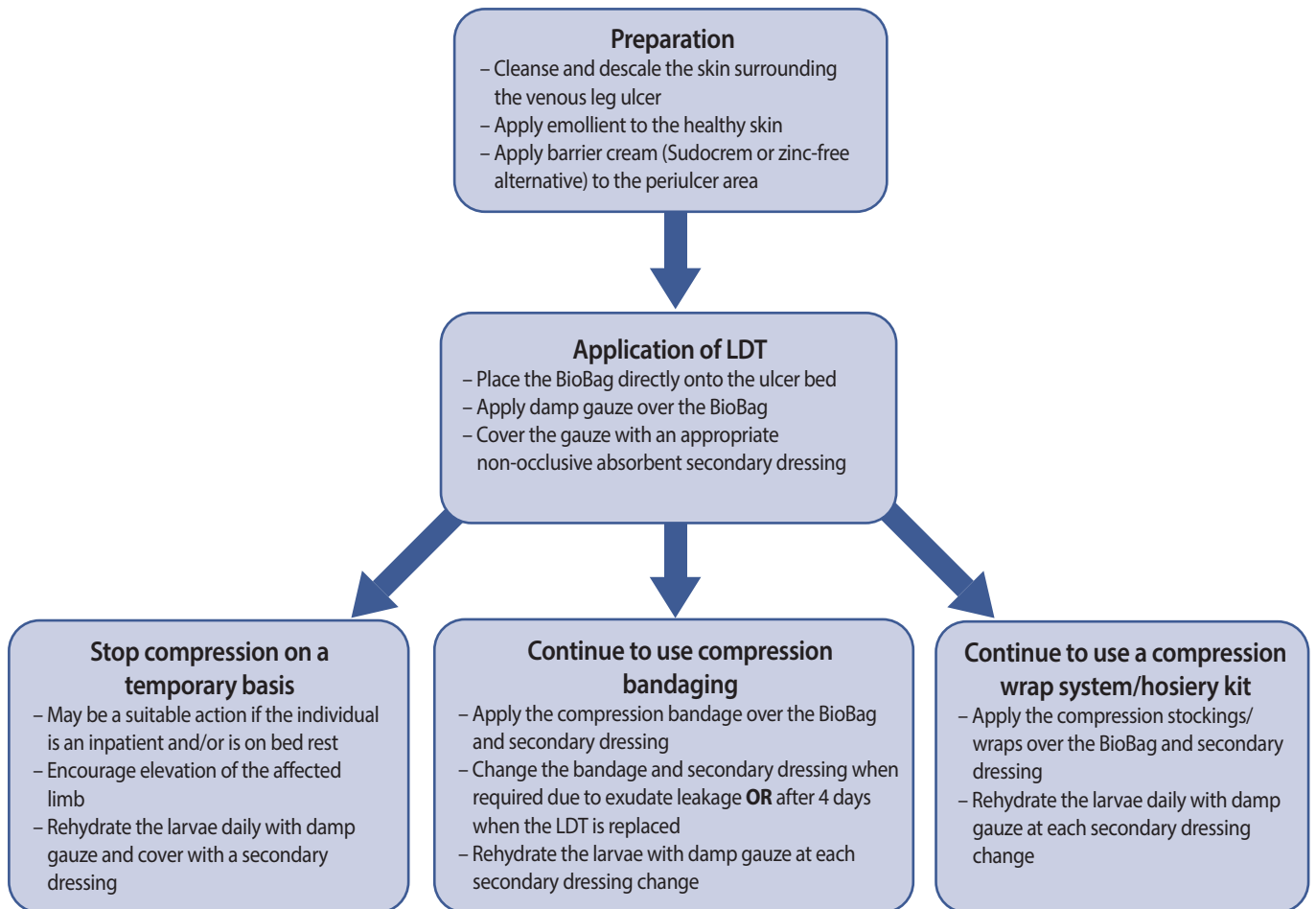
## Compression

In many cases compression therapy can be continued during LDT, as larvae can survive under four-layer compression bandages of up to 40 mmHg. The form of compression may need to be changed. Figure 2 outlines how to use compression bandaging and wrap systems/hosiery kits with LDT.

The risks of stopping prescribed compression during LDT are:

- Increase in pain
- Increase in exudate
- Delayed healing.





**Figure 2.** The use of compression in lower limb ulcers with LDT

### Ongoing management

Debridement is a component of the wound care cycle, and a step-up and step-down approach may be needed. Slough/devitalised tissue can be episodic; its reappearance does not mean treatment has failed and in these instances LDT should be reapplied. Treatment should only be stopped once the desired outcome has been achieved, which — depending on the complexity of the patient, limb and wound — may be total granulation of the wound bed or a percentage reduction in devitalised tissue.

# Use in practice

---

LDT can be used to debride a wide variety of lower limb wounds, as a 'stand alone' treatment or in conjunction with other debridement methods. Its clinical application and supporting evidence are reviewed in this section.

## VENOUS, ARTERIAL AND MIXED VENOUS-ARTERIAL ULCERS

There is strong evidence supporting the fast and effective debridement of venous, arterial and mixed venous-arterial leg ulcers with LDT (Wolff and Hansson, 2003; Dumville et al, 2009; Gilead et al, 2012; Mudge et al, 2014; Sun et al, 2014). A meta-analysis of 12 studies found LDT to be more effective and efficient than conventional treatments (Sun et al, 2014). Significantly shorter debridement times have been reported for LDT versus hydrogel (Dumville et al, 2009; Mudge et al, 2014), with one application being effective in 72% of cases in one study (Wolff and Hansson, 2003). LDT successfully debrided 82–96.9% of ulcers in three studies including a total of 541 patients (Wolff and Hansson, 2003; Gilead et al, 2012; Mudge et al, 2014). It also reduced malodour in 58% of foul-smelling ulcers (Wolff and Hansson, 2003).

## VENOUS LEG ULCERS

Venous leg ulcers (VLUs) are the most common type of leg ulcer, affecting around 1% of the population, and they have a recurrence rate of about 70% (Chapman, 2017). In cases where fast debridement is desirable, the addition of LDT to compression should be considered. Davies et al (2015) found that LDT improved the debridement of hard-to-heal VLUs treated with multilayer compression bandages and the larvae did not appear to be harmed. They concluded that LDT might expedite wound bed preparation prior to other procedures, such as pinch skin grafting. Experts on the panel have experienced reductions in *Pseudomonas*/chronic localised infection and increased VLU healing rates when adequate debridement is combined with compression therapy. An example of LDT use in a leg ulcer is given in Case Study 1.

## CRITICAL LIMB ISCHAEMIA

Patients with critical limb ischaemia (CLI) need to be under the care of the vascular team. They require referral without delay and should undergo revascularisation wherever possible. In the presence of peripheral vascular disease, circulation should be assessed before debridement is commenced, to determine the extent of arterial compromise (Tweedie et al, 2014), as an ankle brachial pressure index <0.6 has a negative impact on outcome (Igari et al, 2013).

LDT can aid debridement in patients with CLI and has been reported to have good outcomes when combined with revascularisation. Nishijima et al (2017) found a significantly higher rate of healing with LDT than conventional treatment (86% versus 38%;  $P=0.035$ ) but no difference in amputation-free survival or ambulatory capability at 6 months. In older people with peripheral arterial disease, LDT removed >90% of necrotic tissue from 98.5% of foot and leg ulcers in 2–10 days (Campbell and Campbell, 2014). Treatment led to successful outcomes in 63% of revascularised patients (Igari et al, 2013). Nishijima et al (2017) concluded that LDT resulted in effective debridement and granulation in patients with CLI and is a valid adjuvant after revascularisation.

Multidisciplinary team decisions are required to ensure the optimal timing of interventions in the management of critically ischaemic lower limb wounds (Foot in Diabetes UK, 2014). Patients should be revascularised whenever possible before debridement is initiated. Quality of life, clinical outcome and limb salvage are dependent on the clinical effectiveness of treatment (Tweedie et al, 2014). If autolysis has already started, revascularisation and debridement should be implemented in the same week. If the patient does not respond to one course of LDT, alternative debridement should be started. Debridement of dry eschar should be avoided until revascularisation has been established.

### Case Study 1. Venous leg ulcer (Sophie Belson, Leg Ulcer Clinic, Lydney Hospital, Gloucestershire Care Services)

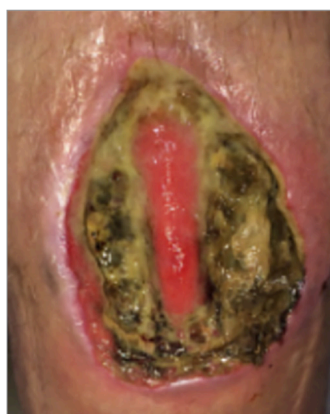

Figure 1

A 35-year-old woman with extensive venous leg ulcers on her right leg secondary to intravenous drug use developed spontaneous ulcers in her left leg, which she did not disclose to community healthcare practitioners for several months. She had a history of intravenous drug use, multiple cases of deep vein thrombosis and anaemia.

On presentation to the leg ulcer specialist nurse, the patient's left leg ulcer measured 7.3x5.6cm, was 1.5cm deep, had a strong malodour and was 90% slough (Figure 1). The patient had been managing the ulcer with adhesive foam dressings. As rapid debridement was needed, the nurse selected loose larvae. Both the patient and nurse were familiar with this treatment, and the

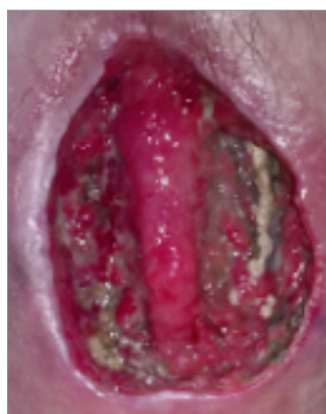

Figure 2

patient was very keen for it to be used following its successful application to her previous leg ulcer.

After 2 days there was significantly less slough covering the wound bed (Figure 2). There was also a reduction in malodour and pain.

LDT was discontinued and the decrease in wound pain enabled the patient to tolerate negative pressure wound therapy. Almost 3 months later, as a result of follow-on treatment with negative pressure wound therapy and compression, there was good progression to wound closure (Figure 3).

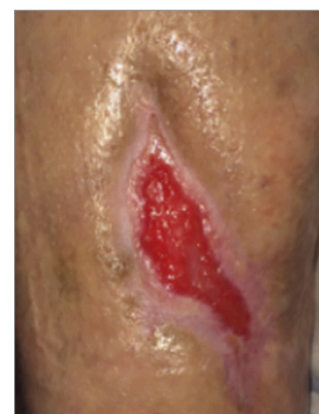

Figure 3

### PRESSURE ULCERS

Pressure ulcers increase patient morbidity and mortality, as well as being associated with high healthcare costs. Higher levels of complete pressure ulcer debridement (80% in <5 weeks versus 48% after 5.5 weeks;  $P=0.021$ ) and significant reductions in necrotic tissue ( $P=0.05$ ), wound area ( $P=0.001$ ) and granulation tissue ( $P<0.001$ ) have been found with LDT versus conventional therapy (Sherman, 2002). Rapid debridement with LDT was also found in a recent study in which 15 out of 36 pressure ulcers were completely cleared of necrotic tissue within a week, with a further 10 ulcers being debrided within 2 weeks (Polat et al, 2017).

LDT can be used to treat heel or malleolus pressure ulcers as long as the limb is offloaded. It can also be used in bedbound patients if the affected area is offloaded and the patient's positioning is regularly checked. The National Institute for Health and Care Excellence (NICE; 2014) recommends LDT be considered for the debridement of pressure ulcers if there is associated vascular insufficiency or if debridement by other means is inappropriate.

### DIABETIC FOOT ULCERS

LDT may be helpful in people with diabetic foot ulcers (DFUs) whose wounds need to be controlled rapidly (Opletalová et al, 2012). LDT should be used as second-line treatment but in many cases is used as a last resort. A recent consensus statement suggested that if DFUs require rapid debridement of devitalised tissue, LDT could be considered first-line as a stand-alone option or alongside other debridement methods (Chadwick et al, 2015). Case Study 2 is an example of the use of LDT to manage a DFU.

#### Case Study 2. Diabetic foot ulcer (Clinical specialist podiatrist team, Diabetic Centre, Trafford General)

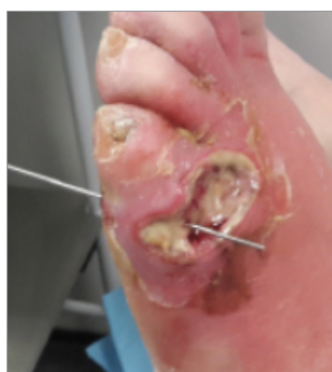

Figure 1

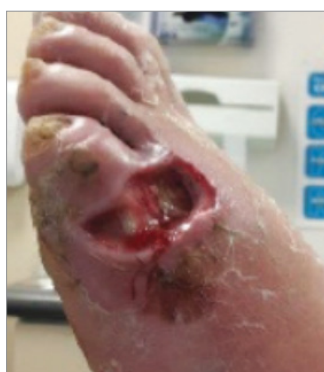

Figure 2

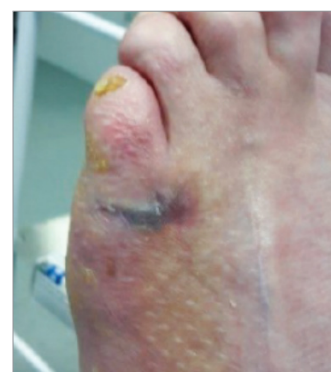

Figure 3

A 55-year-old man with a history of type 2 diabetes presented to A&E during the weekend, requesting antibiotics to treat a diabetic foot ulcer caused by pressure from his boot. The ulcer showed signs of infection, was very tender, and inflammation was spreading up the leg. The patient self-referred to the diabetic centre the next day, as the ulcer was showing no signs of improvement, and he was admitted to hospital for intravenous antibiotic treatment.

Examination revealed the ulcer was tracking through the dorsum to the planter of the foot. It was initially dressed with Aquacel Ag. As the condition of the ulcer deteriorated, the patient became worried he would lose a limb, or at best

three toes. Following assessment (Figure 1), the use of LDT was discussed with the patient and it was agreed this was the best treatment option. A BioBag was applied and the ulcer dressed as recommended in the daily care plan.

The BioBag was removed on day 4, revealing exposed tendon and a fully debrided wound (Figure 2). There was a reduction in swelling and inflammation in the surrounding area. The foot was dressed with Sorbsan Ag and Mepilex.

The wound progressed to healing within 9 weeks of LDT application (Figure 3). The patient was pleased that amputation had been avoided and impressed by how rapidly LDT had worked.

Meta-analyses have found a 53% higher chance of wound healing, significantly reduced healing time ( $P=0.001$ ) and improved healing ( $P=0.013$ ) of DFUs with LDT than conventional therapy (Tian et al, 2013; Wilasrusmee et al, 2014). In the first multicentre RCT there was a 51% reduction in necrosis with LDT versus a 27% reduction with hydrogel, plus improved granulation and a faster healing rate (Markevich et al, 2000); findings that were supported by Sherman et al (2003). Armstrong et al (2005) reported 6-month healing rates of 58% with LDT versus 33% with conventional therapy in non-ambulatory patients with neuroischaemic DFUs.

Other reported benefits in DFU management include:

- Significantly more antibiotic-free days compared to standard therapy ( $P=0.001$ ) (Armstrong et al, 2005; Tian et al, 2013)

- Lower prevalence of infection (60% versus 80%) (Armstrong et al, 2005)
- Noticeable reduction in odour after several applications of LDT (Markevich et al, 2000)
- Significant reduction in length of ward stay (12.5 days versus 19.8 days) (Paul et al, 2009)
- Lower amputation rates compared to standard therapy ( $P=0.02$ ) (Tian et al, 2013) and surgical debridement (20% versus 38%) (Paul et al, 2009)
- Lower treatment costs with LDT (US\$292.82) than conventional therapy (US\$490) (Wilasrusmee et al, 2014).

### LIMB SALVAGE

Amputation has a huge impact on patient quality of life and the associated costs are high (Marineau et al, 2011). In England in 2014–15, the estimated cost of inpatient care for lower limb amputation in people with diabetes was £41.7 million, with post-amputation care costing £20.8 million (Kerr, 2017).

LDT has been associated with limb salvage in several studies of at-risk patients (Gilead et al, 2012; Campbell and Campbell, 2014). In ‘lower-extremity hospice’ patients with peripheral vascular disease, LDT significantly increased the number of antibiotic-free days ( $P=0.0001$ ) and reduced high-level amputations by two-thirds ( $P=0.03$ ) when compared to standard wound care (Armstrong et al, 2005).

LDT may aid limb salvage by reducing necrotic tissue, gangrene and bioburden, which contribute to the risk of lower limb amputation (Gilead et al, 2012; Campbell and Campbell, 2014). It may also help prevent further deterioration in the condition of the wound, limb and patient (Gilead et al, 2012). Armstrong et al (2005) advocate the use of LDT as ideal and cost-effective in individuals for whom the goal is delaying the onset of infection and high-level amputation.

### PRE- AND POST-SURGERY

Surgical skin grafting and other methods of treatment that support wound closure require the wound bed to be clean and granulated (Schultz et al, 2003). Nishijima et al (2017) reported more favourable wound bed preparation and successful graft take following LDT versus conventional treatment in patients who had undergone mid-foot amputation. Several studies have found LDT useful for quickly debriding wounds, with investigators recommending its use before skin grafting and other surgery (Dumville et al, 2009; Gilead et al, 2012; Opletalová et al, 2012). An informed multidisciplinary team approach is required for the use of LDT before surgical grafts.

LDT can be used as an adjunct with surgical debridement. It separates healthy from devitalised tissue, enabling easier surgical debridement (Sherman and Shimoda, 2004) and can be used following the removal of large pieces of necrotic tissue by surgical debridement (Gilead et al, 2012).

Various surgical wounds can be debrided with LDT (Fleischmann et al, 2004). It is regularly used to clean wounds resulting from saphenous vein harvesting for coronary artery bypass graft (Tweedie et al, 2014). There are reports of its successful application in post-surgical wound infection (Fleischmann et al, 2004). LDT is useful in the management of dehiscence, and complex sloughy cavities resulting from surgery (Smith et al, 2015; World Union of Wound Healing Societies, 2018).

### STUMP WOUNDS/AMPUTATION SITES

The factor that has the greatest impact on patient quality of life following amputation is the ability to walk with a prosthesis (Davie-Smith et al, 2017). Prosthetics can cause sloughy wounds that pose various challenges. Timely debridement is essential as it prevents the patient from becoming wheelchair-bound again, reduces the risk of further tissue damage and loss, and enhances patient quality of life.

The use of LDT to debride stump wounds is widely accepted in the UK (Harker, 2006). It can be used in cases where surgical revision is not an option (Harker, 2006) and may prevent the need for further amputation (Breeze, 2016).

### HAEMATOMAS

Haematomas consist of coagulated blood that has adhered to the wound bed and often have a degree of undermining. LDT is a very effective treatment option, as larvae can penetrate below the level of a scalpel, so LDT can be used instead of, or following, sharp debridement. Practitioners should be mindful that the debridement of haematomas may stimulate greater bleeding; therefore, the patient's bleeding risk needs to be assessed (Thompson-McHale, 2015). Loose larvae may be more effective but should not be used if there is uncertainty about blood vessels or delicate structures underneath the haematoma (Rafter, 2012; Thompson-McHale, 2015). Patients should be advised that treatment will result in malodour and high volumes of exudate and is only part of their therapy. An example of the use of LDT to treat haematoma is given in Case Study 3. There is the potential to use it as an adjunct to negative pressure wound therapy.

#### Case Study 3. Haematoma (Christina Harris, Sarah Wolffe and Hannah Tinnuche, University Hospital of Wales, Cardiff & Vale Acute)

An 80-year-old woman was admitted to the trauma and orthopaedic ward following a fall in her nursing home. She presented with a 15x8cm haematoma on the gaiter area of her right leg. She had a history of COPD, osteoarthritis, rheumatoid lung disease and heart disease, for which she was taking warfarin.

The tissue viability nurse reviewed the haematoma and recognised it had the potential to delay discharge back to the nursing home. Atrauman and a dry dressing were initially applied to keep the wound dry and prevent adherence.

At initial review, despite the edges starting to demarcate, the wound was still covered by the haematoma (Figure 1). Quick debridement was required but — due to the patient's age — anaesthetic was deemed a potential risk; therefore, surgical intervention was not an option. The tissue viability nurse decided to use LDT and ordered two BioBags in preparation for consecutive treatments.

Eight days later, the LDT had completely debrided the haematoma (Figure 2). The patient had been unaware of the treatment while *in situ* and had experienced no pain. It was decided that a third BioBag should be applied to stimulate the wound bed and promote granulation and epithelialisation.

When the third BioBag was removed, only healthy tissue was visible and the wound edges had started to contract (Figure 3). The wound was covered with

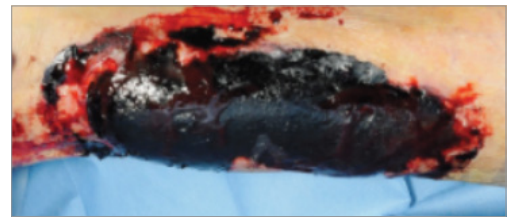


Figure 1

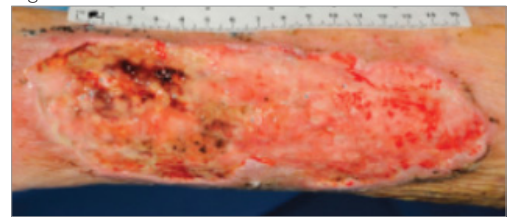


Figure 2

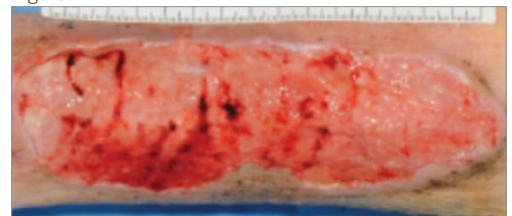


Figure 3

Atrauman and the patient was discharged. The clinicians and patient were extremely pleased with the outcome.

### OTHER WOUNDS

In patients receiving palliative care, healing may not be an option, but minimisation of symptoms associated with the wound, such as odour and exudate, should inform care decisions. LDT can be used to manage necrosis and odour associated with certain types of tumour and fungating lesions when surgery is not an option (Sherman et al, 2007; Whitaker et al, 2007; Campbell and Campbell, 2014).

Calciphylaxis can result in painful ulcers that are slow to heal and at high risk of infection and sepsis. Most cases occur in end-stage renal disease and 1-year mortality is up to 80% (Shih et al, 2018). Patients should be referred to a specialist and any underlying issues identified and addressed cautiously. LDT can be used as a precursor to other therapy, such as negative pressure, in the presence of calciphylaxis (Shih et al, 2018), but disease should be under control before starting LDT treatment.

Pyoderma gangrenosum commonly causes ulceration of the lower limbs or trunk, but again disease should be under control before starting LDT treatment. In addition to treating the underlying systemic disease, LDT can be used to manage necrotic tissue and biofilm. Treatment may also reduce malodour, pain and exudate associated with this condition (Din et al, 2018).

The off-license use of LDT in infants and children with stubborn sloughy wounds can prove useful. Considerations in practice are given in Box 7. Several case studies outlining the successful use of LDT in paediatric patients have been published; one on the treatment of a post-traumatic amputation wound and another on the management of purpura fulminans (Orkiszewski et al, 2006; Rogers, 2009). Such treatment is generally only instigated for children being managed within a specialist care facility. LDT is appropriate in cases where scarring is a concern, as use in practice suggests it results in lower levels of scarring compared to surgery and skin grafts.

Off-label and uncommon uses of LDT include disinfection, drainage reduction, odour control, determination of tissue viability, stimulation of epithelialisation in clean but non-healing wounds, acute burns, and the palliative management of necrotic tumours and odour (Sherman et al, 2007; Campbell and Campbell, 2014; Din et al, 2018).

#### Box 7: Considerations for paediatric use of LDT

- Consent needs to be obtained from the person who has parental responsibility for the child
- Ankle and foot orthoses/splints should not be worn during LDT, rendering the child immobile for the duration of treatment
- The child may need to be admitted to hospital for treatment to:
  - Ensure compliance with immobility
  - Ensure the dressing is kept in place
  - Promptly remove LDT if the child cannot tolerate treatment
- LDT should be changed after 3 days; by 4 days, larval movement is more likely to be felt and lead to sleep disturbances or the child trying to remove the dressing.

# The case for prescribing LDT

## Box 8: The clinical and cost-effectiveness case for prescribing LDT

- Debrides quickly, reducing length of treatment and number of procedures
- Is selective, preserving healthy tissue
- Is safe, with lower risks of bleeding, pain and infection than surgical and mechanical debridement; discomfort or pain - the most common side-effect - is often transient and can usually be managed with analgesia
- Reduces bioburden, and therefore infection risk.

### CLINICAL EFFICACY

Health providers should deliver evidence-based treatment to patients and, when deciding on the best treatment for an individual, should take into account quality of life, safety and the effectiveness of care. LDT's modes of action make it safe and effective, with the potential to enhance patient quality of life (Box 8).

It has yet to be demonstrated whether faster debridement is associated with shorter healing times or improved healing rates, but swift optimisation of the wound bed might be expected to reduce the risk of a wound becoming hard-to-heal. It should be noted that the evidence in support of reduced time to healing and improved healing rates appears to be more closely associated with DFUs; Dumville et al (2009) and Opletalová et al (2012) found LDT did not increase healing rates in other types of wounds.

### COST-EFFECTIVENESS

Cost per unit of treatment, length of treatment, number of procedures, the likelihood and cost of infection and adverse events affect the cost-effectiveness of debridement. The unit cost of LDT is high compared to many other wound care products but clinical- and cost-effectiveness studies have concluded that LDT is effective when compared to sharp, surgical, mechanical and autolytic debridement (Wayman et al, 2000; Thomas, 2006; All Wales Tissue Viability Nurse Forum, 2013; Bennett et al, 2013; Wilasrusmee et al, 2014). Bennett et al (2013) compared LDT with other forms of debridement using a model representing the typical treatment of a single patient and using parameters for clinical effectiveness. They calculated incremental cost-effectiveness ratios based on the difference in costs incurred and benefits provided by the different forms of debridement and found LDT to be dominant (Table 6).

**Table 6: Base case incremental results of LDT compared to alternative debridement therapies (Bennett et al, 2013)**

Debridement comparison made with LDT	Incremental cost	Incremental QALYs	ICER
vs. surgical	-£3,373	0.0015	Dominant
vs. sharp	-£1,638	0.0020	Dominant
vs. hydrosurgical	-£2,268	0.0008	Dominant
vs. mechanical (ultrasound)	-£45	0.0055	Dominant
vs. hydrogel	-£26	0.0009	Dominant
vs. honey	-£176	0.0008	Dominant

ICER = incremental cost-effectiveness ratio; QALYs = quality-adjusted life years (based on £20,000 per year)

The question of cost and who will pay for treatment can pose an issue; if LDT is prescribed in secondary care, treatment will come out of the hospital's budget; if prescribed in the community, it will come under the GP's budget. There is a degree of decision-making on the wards, and prescribing clinicians should confidently put forward the case for LDT as a clinically cost-effective option when appropriate. At baseline daily treatment costs of £25, Thomas (2006) estimated that the NHS could save around £160 million annually if LDT was used as the treatment of choice for all sloughy and infected wounds.



# Conclusion

---

LDT is a rapid, cost-effective and highly selective form of treatment that can be used in any healthcare setting as part of a wound care plan. It should be used as first line in the debridement of lower leg wounds and second line in foot wounds when speed, selectivity and bioburden are important factors in care. The proposed pathway places LDT clearly within the wider wound care arena and is in line with the lower limb clinical work stream of the National Wound Care Strategy Programme.

Multidisciplinary teamwork is needed to ensure the full course of prescribed therapy is administered and that optimal outcomes are achieved. Once the goal of therapy has been accomplished, patients should receive follow-on treatment, such as topical negative wound pressure and dressings, to support wound healing.

Hurdles to the use of LDT in practice can be overcome through patient and practitioner education, presenting clinical- and cost-effectiveness data to budget-holders, and by creating systems to ensure the uninterrupted supply and viability of treatment. LDT should be initiated early in the wound management process when indicated to achieve optimal results.

# References

- Adderley U (2019) Editorial: The National Wound Care Strategy Programme. *Wound Care Today*. February 2019. Available at: [www.woundcare-today.com/journals/issue/february-2019/article/national-wound-care-strategy-programme](http://www.woundcare-today.com/journals/issue/february-2019/article/national-wound-care-strategy-programme) (accessed 08.11.2019)
- All Wales Tissue Viability Nurse Forum (2013) *All Wales Guidance for the use of Larval Debridement Therapy*. Wounds UK, London. Available at: <https://bit.ly/2l51Sfn> (accessed 23.09.2019)
- Atkin L (2019) National Wound Care Strategy Programme: clinical work stream: lower limb update. *Wounds International* 15(2): 14
- Atkin L, Bucko Z, Conde Montero E et al (2019) Implementing TIMERS: The race against hard-to-heal wounds. *J Wound Care* 28(3 Suppl 3): S1–49
- Armstrong DG, Salas P, Short B et al (2005) Maggot therapy in 'lower-extremity hospice' wound care: fewer amputations and more antibiotic-free days. *J Am Podiatr Med Assoc* 95(3): 254–7
- Baer WS (1931) The treatment of chronic osteomyelitis with the maggot (larva of the blow fly). *J Bone Jt Surg Am* 13: 438–75
- Bennett H, Sewell B, Anderson P et al (2013) Cost-effectiveness of interventions for chronic wound debridement: an evaluation in search of data. *Wounds UK* 9(4 Suppl): 3–11
- Blake FAS, Abromeit N, Bubenheim M (2007) The biosurgical wound debridement: experimental investigation of efficiency and practicability. *Wound Repair Regen* 15(5): 756–61
- Bowling FL, Sagami EV, Boulton SM (2007) Larval therapy: a novel treatment in eliminating methicillin resistant *Staphylococcus aureus* from diabetic foot ulcers. *Diabetes Care* 30(2): 370–1
- Breeze LK (2016) The use of larval debridement therapy in preventing further amputation. *Wounds UK* 12(2): 60–4
- Campbell N, Campbell D (2014) A retrospective, quality improvement review of maggot debridement therapy outcomes in a foot and leg ulcer clinic. *Ostomy Wound Manage* 60(7): 16–25
- Cazander G, van Veen KEE, Bernards AT, Juekema GN (2009a) Do maggots have an influence on bacterial growth? A study on the susceptibility of strains of six different bacterial species to maggots of *Lucilia sericata* and their excretions/secretions. *J Tissue Viability* 18(3): 80–7
- Cazander G, van Veen KE, Bouwman LH et al (2009b) The influence of maggot excretions on PAO1 biofilm formation on different biomaterials. *Clin Orthop Relat Res* 467(2): 536–45
- Cazander G, Pritchard DI, Nigam Y et al (2013) Multiple actions of *Lucilia sericata* larvae in hard-to-heal wounds. *BioEssays* 35(12): 1083–92
- Chadwick P, McCordle J, Ricci E et al (2015) Appropriate use of larval debridement therapy in diabetic foot management: consensus recommendations. *Diabetic Foot Journal* 18(1): 37–42
- Chan B, Cadarette S, Wodchis W et al (2017) Cost-of-illness studies in chronic ulcers: a systematic review. *J Wound Care* 26(Suppl 4): S4–14
- Chapman S (2017) Venous leg ulcers: evidence review. *Evidently Cochrane*. October 2017. Available at: [www.evidentlycochrane.net/venous-leg-ulcers-evidence/](http://www.evidentlycochrane.net/venous-leg-ulcers-evidence/) (accessed 08.11.2019)
- Cowan LJ, Stechmiller JK, Phillips P et al (2013) Chronic wounds, biofilms and use of medicinal larvae. *Ulcers*: 10.1155
- Davie-Smith F, Coulter E, Kennon B et al (2017) Factors influencing quality of life following lower limb amputation for peripheral occlusive disease: a systematic review of the literature. *Prosthet Orthot Int* 41(60): 537–47
- Davies CE, Woolfrey G, Hogg N et al (2015) Maggots as a wound debridement agent for chronic venous leg ulcers under graduated compression bandages: a randomised controlled trial. *Phlebology* 30(10): 693–9
- Din RS, Tsiaras WG, Mostaghimi A (2018) Two cases of maggot debridement therapy in pyoderma gangrenosum. *JAAD Case Rep* 4(10): 1027–9
- Dowsett C, Newton H (2005) Wound bed preparation: TIME in practice. *Wounds UK* 1(3): 58–70
- Dumville J, Worthly G, Bland JM et al (2009) Larval therapy for leg ulcers (VenUS II): randomised controlled trial. *BMJ* 338: b773
- European Wound Management Association (2008) *Position Document: Hard-to-heal wounds: a holistic approach*. London: MEP Ltd. Available at: [www.woundsinternational.com](http://www.woundsinternational.com) (accessed 08.11.2019)
- Fleischmann W, Grassberger M, Sherman R (eds) (2004) *Maggot Therapy: A Handbook of Maggot-Assisted Wound Healing*. Stuttgart: G Thieme Verlag
- Foot in Diabetes UK in association with the College of Podiatry (2014) *Principles of debridement: the diabetic foot*. SB Communications. Available at: <https://bit.ly/33sabTG> (accessed 08.11.19)
- Gilead L, Mumcuoglu KY, Ingher A (2012) The use of maggot debridement therapy in the treatment of chronic wounds in hospitalised and ambulatory patients. *J Wound Care* 21(2): 78–85
- Gottrup F, Jørgensen B (2011) Maggot debridement: an alternative method for debridement. *Eplasty* 11: e33
- Gray D, Acton C, Chadwick P et al (2010) Consensus guidance for the use of debridement techniques in the UK. *Wounds UK* 6(4): 77–84
- Gray TA, Rhodes S, Atkinson RA, et al (2018) Opportunities for better value wound care: a multiservice, cross-sectional survey of complex wounds and their care in a UK community population. *BMJ Open* 8: e019440
- Guest JF, Ayoub N, McIlwraith T et al (2015) Health economic burden that wounds impose on the National Health Service in the UK. *BMJ Open* 5: e009283
- Guest JF, Vowden K, Vowden P (2017) The health economic burden that acute and chronic wounds impose on an average clinical commissioning group/health board in the UK. *J Wound Care* 26(6):292–303
- Guest JF, Fuller GW, Vowden P, Vowden KR (2018a) Cohort study evaluating pressure ulcer management in clinical practice in the UK following initial presentation in the community: costs and outcomes. *BMJ Open* 8(7): e021769
- Guest JF, Fuller GW, Vowden P (2018b) Venous leg ulcer management in clinical practice in the UK: Costs and outcomes. *Int Wound J* 15(1): 29–37
- Guo S, DiPietro LA (2010) Factors affecting wound healing. *J Dent Res* 89(9): 219–29
- Harker J (2006) *Wound healing complications associated with lower limb amputation*. World Wide Wounds September 2006. Available at: [www.worldwidewounds.com/2006/september/Harker/Wound-Healing-Complications-Limb-Amputation.html](http://www.worldwidewounds.com/2006/september/Harker/Wound-Healing-Complications-Limb-Amputation.html) (accessed 08.11.2019)
- Harris LG, Nigam Y, Sawyer J et al (2013) *Lucilia sericata* chymotrypsin disrupts protein adhesion-mediated staphylococcal biofilm formation. *Appl Environ Microbiol* 79(4): 1393–5
- Health Service Executive (2018) *HSE National Wound Management Guidelines 2018*. Dublin: HSE. Available at: [www.hse.ie/eng/services/publications/nursingmidwifery%20services/wound-management-guidelines-2018.pdf](http://www.hse.ie/eng/services/publications/nursingmidwifery%20services/wound-management-guidelines-2018.pdf) (accessed 08.11.2019)
- Horobin AJ, Shakesheff KM, Pritchard DI (2006) Promotion of human dermal fibroblast migration, matrix remodelling, and modification of fibroblast morphology within a novel 3D model by *Lucilia sericata* larval secretions. *J Invest Dermatol* 126(6): 1410–8
- Igari K, Toyofuku T, Uchiyama H, et al (2013) Maggot debridement therapy for peripheral arterial disease. *Ann Vasc Dis* 6(2): 145–9
- Jaklic D, Lapanje A, Zupancic K et al (2008) Selective antimicrobial activity of maggots against pathogenic bacteria. *J Med Microbiol* 57(Pt 5): 617–25
- Kerr M (2017) *Diabetic Foot Care in England: An Economic Study*. Insight Health Economics. Available at: <https://bit.ly/2qx6mnh> (accessed 08.11.2019)
- Marineau M, Herrington MT, Swenor KM, Eron LJ (2011) Maggot debridement therapy in the treatment of complex diabetic wounds. *Hawaii Med J* 70(6): 121–4
- Markevitch YO, McLeod-Roberts J, Mousely M, Molloy E (2000) Maggot therapy for diabetic neuropathy foot wounds. *Diabetologica* 43(Suppl 1): A15
- Martin D, Pitetti KH (2007) *Maggot debridement therapy in the treatment of nonhealing chronic wounds*. Proceedings of the 3rd Annual GRASP Symposium, Wichita State University, 2007
- Mudge E, Price P, Walkley N, Harding KG (2014) A randomised controlled trial of larval therapy for the debridement of leg ulcers: Results of a multicentre, randomized, controlled, open, observer blind, parallel group study. *Wound Rep Regen* 22(1): 43–51
- Mumcuoglu KY (2001) Clinical applications for maggots in wound care. *Am J Clin Dermatol* 12(4): 219–27
- Mumcuoglu KY, Ingber A, Gilead L et al (1999) Maggot therapy for the treatment of intractable wounds. *Int J Dermatol* 38(8): 623–7
- Mumcuoglu KY, Miller J, Mumcuoglu M et al (2001) Destruction of bacteria in the digestive tract of the maggot of *Lucilia sericata* (Diptera: Calliphoridae). *J Med Entomol* 38(2): 161–6
- National Institute for Health and Care Excellence (2014) CG179: Pressure ulcers: prevention and management. London: NICE. Available at: [www.nice.org.uk/guidance/cg179](http://www.nice.org.uk/guidance/cg179) (accessed 08.11.2019)
- National Institute for Health and Care Excellence (2016) Clinical Guideline - Diabetic foot problems: prevention and management. London: NICE. Available at: [www.nice.org.uk/guidance/ng19](http://www.nice.org.uk/guidance/ng19) (accessed 08.11.2019)
- National Institute for Health and Care Excellence (2019) MTG17. *The Debrisoft monofilament debridement pad for use in acute or chronic wounds*. London: NICE. Available at: [www.nice.org.uk/](http://www.nice.org.uk/)

- guidance/mtg17 (accessed 08.11.2019)
- National Wound Care Strategy Programme (2020) Lower Limb Ulcers. Draft recommendations. Available at: [www.ahsnnetwork.com/about-academic-health-science-networks/national-programmes-priorities/national-wound-care-strategy-programme](http://www.ahsnnetwork.com/about-academic-health-science-networks/national-programmes-priorities/national-wound-care-strategy-programme) (accessed 08.11.2019)
- NHS Improvement (2019) *Stop the Pressure. Overview*. Available at: <http://nhs.stopthepressure.co.uk> (accessed 08.11.2019)
- Nishijima A, Goshō M, Yoshida R et al (2017) Effective wound bed preparation using maggot debridement therapy for patients with critical limb ischaemia. *J Wound Care* 26(8): 483-9
- Opletalová K, Blaizot X, Mourgeon B et al (2012) Maggot therapy for wound debridement. *Arch Dermatol* 148(4): 432-8
- Orkiszewski M, Madej J, Killan T (2006) The use of maggot therapy as an adjunct to surgical debridement: a paediatric case report. *World Wide Wounds* March 2006. Available at [www.worldwidewounds.com/2006/march/Orkiszewski/Maggot-Therapy-Paediatric-Surgery.html](http://www.worldwidewounds.com/2006/march/Orkiszewski/Maggot-Therapy-Paediatric-Surgery.html) (accessed 08.11.2019)
- Ousey K, Cook L (2011) Understanding the importance of holistic wound assessment. *Practice Nurs* 22(6): 308-14
- Paul IAG, Ahmad NW, Lee HL et al (2009) Maggot debridement therapy with *Lucilia cuprina*: a comparison with conventional debridement in diabetic foot ulcers. *Int Wound J* 10: 91-4
- Polat E, Kutlubay Z, Sirekbasan S (2017) Treatment of pressure ulcers with larvae of *Lucilia sericata*. *Turk J Phys Med Rehabil* 63(4): 307-12
- Prete P (1997) Growth effects of *Phaenicia sericata* larval extracts on fibroblasts: mechanism for wound healing by maggot therapy. *Life Sci* 60(8): 505-10
- Pritchard DI, Nigam Y (2013) Maximising the secondary beneficial effects of larval debridement therapy. *J Wound Care* 22(11): 610-1, 164-6
- Prompers L, Huijberts M, Apelqvist J et al (2008) Delivery of care to diabetic patients with foot ulcers in daily practice: Results of the Eurodial Study, a prospective cohort study. *Diabet Med* 25(6): 700-7
- Rafter L (2012) Debridement of a traumatic haematoma using larval therapy. *Wounds UK* 8(1): 81-8
- Rogers A (2009) Maggots for the management of purpura fulminans in a paediatric patient. *Wounds UK* 5(4): 141-5
- Royal College of Nursing (2017) *Safe and Effective Staffing: Nursing Against the Odds*. London: Royal College of Nursing. Available at: [www.rcn.org.uk/professional-development/publications](http://www.rcn.org.uk/professional-development/publications) (accessed 12.11.2019)
- Schultz GS, Sibbald RG, Falanga V et al (2003) Wound bed preparation: a systematic approach to wound management. *Wound Repair Regen* 11(Suppl 1): S1-S7
- Sherman RA (2002) Maggot versus conservative debridement therapy for the treatment of pressure ulcers. *Wound Repair Regen* 10(4): 208-14
- Sherman RA (2003) Maggot therapy for treating diabetic foot ulcers unresponsive to conventional therapy. *Diabetes Care* 26(2): 446-51
- Sherman RA (2009) Maggot therapy takes us back to the future of wound care: new and improved maggot therapy for the 21st century. *J Diabetes Sci Technol* 3(20): 336-44
- Sherman RA, Shapiro CE, Yang RM (2007) Maggot therapy for problematic wounds: uncommon and off-label applications. *Adv Skin Wound Care* 20(11): 602-10
- Sherman RA, Sherman J, Gilead L et al (2001) Maggot debridement therapy in outpatients. *Arch Phys Med Rehabil* 82(9): 1226-9
- Sherman RA, Shimoda KJ (2004) Presurgical maggot debridement of soft tissue wounds is associated with decreased rates of postoperative infection. *Clin Infect Dis* 39(7): 1067-70
- Sherman RA, Wyole F, Vulpe M (1995) Maggot therapy for treating pressure ulcers in spinal cord injury patients. *J Spinal Cord Med* 18(2): 71-4
- Shih AF, Little AJ, Panse G et al (2018) Maggot therapy for calciphylaxis wound debridement complicated by bleeding. *JAAD Case Rep* 4(4): 396-8
- Scottish Intercollegiate Guidelines Network (2010) SIGN Guideline 120: *Management of chronic venous leg ulcers*. Edinburgh: SIGN. [www.sign.ac.uk/assets/sign120.pdf](http://www.sign.ac.uk/assets/sign120.pdf) (accessed 08.11.2019)
- Smith N, Overland J, Greenwood J (2015) Local management of deep cavity wounds – current and emerging therapies. *Chronic Wound Care Manage Res* 2: 159-70
- Steenvoorde P, Budding T, Oskam J (2005a) Determining pain levels in patients treated with maggot debridement therapy. *J Wound Care* 14(10): 485-8
- Steenvoorde P, Jacobi CE, Oskam J (2005b) Maggot debridement therapy: free-range or contained? An in vivo study. *Adv Skin Wound Care* 18(8): 430-5
- Steenvoorde P, Jacobi CE, van Doorn L, Oskam J (2007) Maggot debridement therapy of infected ulcers: patient and wound factors influencing outcome – a study of 101 patients with 117 wounds. *Ann R Coll Surg Engl* 89(6): 596-602
- Steenvoorde P, Jukema GN (2004) The antimicrobial activity of maggots in vivo results. *J Tissue Viability* 14(3): 97-101
- Steenvoorde P, van Doorn LP (2008) Maggot debridement therapy: serious bleeding can occur: report of a case. *J Wound Ostomy Continence Nurse* 35(4): 412-4
- Stroh R, Apelqvist J, Dissemont J et al (2013) EWMA Document: Debridement. *J Wound Care* 22(Suppl 1): S1-S2
- Sun X, Jiang K, Chen J et al (2014) A systematic review of maggot debridement therapy for chronically infected wounds and ulcers. *Int J Infect Dis* 25: 32-7
- Thomas S (2006) Cost of managing chronic wounds in the U.K. with particular emphasis on maggot debridement therapy. *J Wound Care* 15(10): 465-9
- Thomas S, Andrews AM, Hay NP, Bourgoise S (1999) The anti-microbial activity of maggot secretions: results of a preliminary study. *J Tissue Viabil* 9(4): 127-32
- Thomas Hess C (2011) Checklist for factors affecting wound healing. *Skin and Wound Care* 24(4): 192
- Thompson-McHale S (2015) Haematomas: management and treatment. *Wound Essentials* 10(1): 24-8
- Tian X, Liang XM, Song GM et al (2013) Maggot debridement therapy for the treatment of diabetic foot ulcers: a meta-analysis. *J Wound Care* 22(9): 462-9
- Turner J (2017) Debriding chronic wounds with larval therapy: the new answer for biosurgery in the outpatient wound clinic? *Today's Wound Clinic* 11(7): Available at: [www.todayswoundclinic.com/articles/debriding-chronic-wounds-larval-therapy-new-answer-biosurgery-outpatient-wound-clinic](http://www.todayswoundclinic.com/articles/debriding-chronic-wounds-larval-therapy-new-answer-biosurgery-outpatient-wound-clinic) (accessed 07.10.2019)
- Tweedie B, Vig S, Vowden S, Tyrer J (2014). *Larval debridement therapy: vascular wound management*. Wounds UK; 10(4 Suppl). Available at: [www.wounds-uk.com](http://www.wounds-uk.com) (accessed 08.11.2019)
- Van der Plas MJ, Jukema GN, Wai SW et al (2008) Maggot excretions/secretions are differently effective against biofilms of *Staphylococcus aureus* and *Pseudomonas aeruginosa*. *J Antimicrob Chemother* 61(1): 117-22
- Wayman J, Nitojogi V, Walker A, et al (2000) The cost effectiveness of larval therapy in venous ulcers. *J Tissue Viability* 10(3): 91-4
- Whitaker IS, Twine C, Whitaker MJ et al (2007) Larval therapy from antiquity to the present day: mechanisms of action, clinical applications and future potential. *Postgrad Med J* 83(980): 409-13
- White R (2008) Tissue viability in tomorrow's NHS. *J Wound Care* 17(3): 97-9
- Wilasrusmee C, Marjareonrungrung M, Eamkong S et al (2014) Maggot therapy for chronic ulcer: A retrospective cohort and meta-analysis. *Asian J Surg* 37(3): 138-47
- Wolff H, Hansson C (2003) Larval therapy – an effective method of ulcer debridement. *Clin Exp Dermatol* 28(20): 134-7
- Wollina U, Liebold K, Schmidt WD et al (2002) Biosurgery supports granulation and debridement in chronic wounds – clinical data and remittance spectroscopy measurement. *Int J Dermatol* 41(10): 635-9
- World Union of Wound Healing Societies (2018) *Consensus document: Surgical wound dehiscence: improving prevention and outcomes*. London: Wounds International. Available at: [www.woundsinternational.com](http://www.woundsinternational.com) (accessed 08.11.2019)
- Wounds UK (2008) *Best Practice Statement: Optimising wound care*. Wounds UK, Aberdeen. Available at: [www.wounds-uk.com](http://www.wounds-uk.com) (accessed 08.11.2019)
- Wounds UK (2016) *Best Practice Statement: Holistic management of venous leg ulceration*. London: Wounds UK. Available at: [www.wounds-uk.com](http://www.wounds-uk.com) (accessed 08.11.2019)
- Wounds UK (2019) *Best Practice Statement: Addressing complexities in the management of venous leg ulcers*. Wounds UK, London. Available at: [www.wounds-uk.com](http://www.wounds-uk.com) (accessed 08.11.2019)

